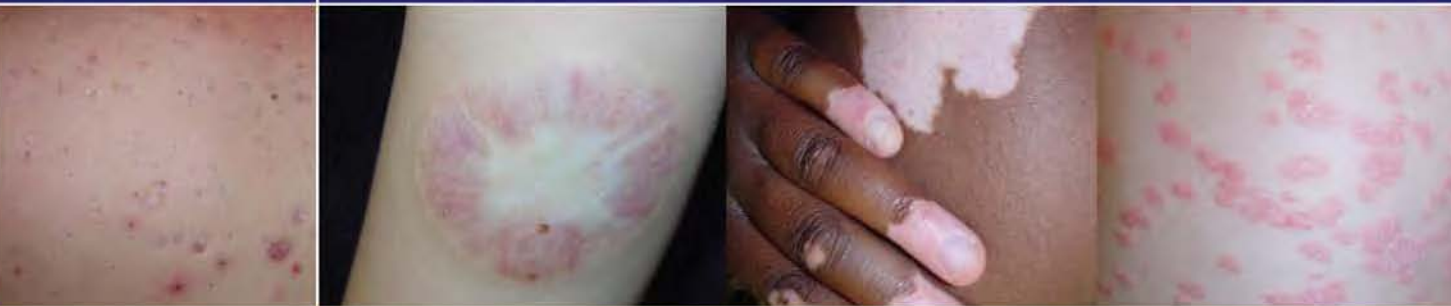

Illustrated Manual of  
**Pediatric  
Dermatology**  
Diagnosis and Management



**Susan Bayliss Mallory**  
Alanna Bree  
Peggy Chern



**Taylor & Francis**  
Taylor & Francis Group

Illustrated Manual of  
**Pediatric  
Dermatology**



# Illustrated Manual of Pediatric Dermatology

## Diagnosis and Management

---

### **Susan Bayliss Mallory MD**

Professor of Internal Medicine/Division of Dermatology  
and Department of Pediatrics  
Washington University School of Medicine  
Director, Pediatric Dermatology  
St. Louis Children's Hospital  
St. Louis, Missouri, USA

### **Alanna Bree MD**

St. Louis University  
Director, Pediatric Dermatology  
Cardinal Glennon Children's Hospital  
St. Louis, Missouri, USA

### **Peggy Chern MD**

Department of Internal Medicine/Division of Dermatology  
and Department of Pediatrics  
Washington University School of Medicine  
St. Louis, Missouri, USA



**Taylor & Francis**

Taylor & Francis Group

LONDON AND NEW YORK



© 2005 Taylor & Francis, an imprint of the Taylor & Francis Group

First published in the United Kingdom in 2005

by Taylor & Francis,  
an imprint of the Taylor & Francis Group,  
2 Park Square, Milton Park  
Abingdon, Oxon OX14 4RN, UK

Tel: +44 (0) 20 7017 6000

Fax: +44 (0) 20 7017 6699

Website: [www.tandf.co.uk](http://www.tandf.co.uk)

All rights reserved. No part of this publication may be reproduced, stored in a retrieval system, or transmitted, in any form or by any means, electronic, mechanical, photocopying, recording, or otherwise, without the prior permission of the publisher or in accordance with the provisions of the Copyright, Designs and Patents Act 1988 or under the terms of any licence permitting limited copying issued by the Copyright Licensing Agency, 90 Tottenham Court Road, London W1P 0LP.

Although every effort has been made to ensure that all owners of copyright material have been acknowledged in this publication, we would be glad to acknowledge in subsequent reprints or editions any omissions brought to our attention.

British Library Cataloguing in Publication Data

Data available on application

Library of Congress Cataloging-in-Publication Data

Data available on application

ISBN 1-85070-753-7

Distributed in North and South America by

Taylor & Francis  
2000 NW Corporate Blvd  
Boca Raton, FL 33431, USA

*Within Continental USA*

Tel: 800 272 7737; Fax: 800 374 3401

*Outside Continental USA*

Tel: 561 994 0555; Fax: 561 361 6018

E-mail: [orders@crcpress.com](mailto:orders@crcpress.com)

Distributed in the rest of the world by

Thomson Publishing Services

Cheriton House

North Way

Andover, Hampshire SP10 5BE, UK

Tel: +44 (0) 1264 332424

E-mail: [salesorder.tandf@thomsonpublishingservices.co.uk](mailto:salesorder.tandf@thomsonpublishingservices.co.uk)

Composition by Parthenon Publishing

Printed and bound by T.G. Hostench S.A., Spain

# CONTENTS

---

Preface	vii
Dedication	ix
Chapter	
1. Principles of Clinical Diagnosis	1
2. Neonatal Dermatology	9
3. Papular and Papulosquamous Disorders	33
4. Eczematous Dermatoses	49
5. Acne and Acneiform Disorders	71
6. Bullous Disorders	81
7. Bacterial and Spirochetal Diseases	95
8. Viral and Rickettsial Diseases	119
9. Fungal Diseases	149
10. Infestations and Environmental Hazards	163
11. Hypersensitivity Disorders/Unclassified Disorders	177
12. Photodermatoses and Physical Injury and Abuse	199
13. Drug Eruptions	217
14. Pigmentary Disorders	229
15. Collagen Vascular Diseases	257
16. Vascular and Lymphatic Diseases	275
17. Tumors, Cysts, and Growths	297
18. Hair Disorders	335
19. Nail Disorders	359
20. Genodermatoses and Syndromes	369
21. Therapy	391
Index	411



# PREFACE

---

Pediatric dermatology is an exciting area of medicine. When children are young, they cannot give a history. In fact, pediatrics is said to be much like veterinary medicine! The practitioner must use sharp observational skills to assess a problem. For example, rather than asking a 1 year old if they scratch or if a rash itches, merely observing the child scratching in the office or seeing excoriations on the skin will lead a physician to the correct conclusion. Thus, looking for clues further sharpens one's visual skills.

This book is a synopsis of basic pediatric dermatology. The approaches that we use are practical ones which we have found to be simple basic approaches to problems that pediatricians and dermatologists see in their practices. This book is aimed at the common problems seen in medical offices with some added information about unique conditions in pediatric dermatology.

Teaching at a pediatric tertiary care hospital, we find that pediatric and family practice residents ask us frequently which book they might purchase for their library. Mainly, they are interested in a book that has good photographs so that they can visually recognize skin diseases combined with a practical, concise text.

Our purpose in writing this book was to produce a manual of high-quality photographs which can easily aid the pediatric house officer and primary care physician in the diagnosis of pediatric skin diseases. In addition, we have tried to provide a pertinent, easy to read outline with easily applied suggestions on treatment. Realistic criteria for referring patients are also outlined and a few pertinent references are given.

We hope that you enjoy this text and that it can be of benefit to all who read it.

Susan Bayliss Mallory MD  
Alanna Bree MD  
Peggy Chern MD



# DEDICATION

---

We would like to dedicate this book to our children and patients who have been a great source of learning not only about pediatrics but also about pediatric dermatology.

For Susan Bayliss Mallory, my children, Elizabeth and Meredith, have been a source of joy and encouragement as well as keeping me grounded. My parents, Milward William Bayliss MD and Jeanette Roedell Bayliss were always encouraging me to study and learn. God has been an ever-loving omniscient presence in my life and has been my source of inspiration.

For Alanna Bree, to all of my many teachers, especially my first teachers – my parents, Al and Shirley Flath. Most importantly, to my husband, Doug, and children Sam and Kendyl for their unconditional love and constant support.

For Peggy Chern, to my parents, Henry and Myra Chern, and to Matt Shaw for their support and encouragement.

Others who have been a major source of help and inspiration have been: General Elbert DeCoursey MD, Esther DeCoursey, Jere Guin MD, Arthur Eisen MD and Lynn Cornelius MD.

Special thanks to the following physicians who helped review the manuscript: Chan-Ho Lai, Pam Weinfeld, Jason Fung, Tony Hsu, Angela Spray, D. Russell Johnson, Alison Klenk, Margaret Mann and Yadira Hurley.



# PRINCIPLES OF CLINICAL DIAGNOSIS

## GENERAL

- Diagnosis of cutaneous disorders in infants and children requires careful inspection of skin, hair and nails
- Skin disorders of infants are different from skin disorders in adults
  1. For example, erythema toxicum neonatorum is only seen in newborns
  2. Skin of a young child tends to form blisters more easily (e.g. insect bites or mastocytomas)
- Determining morphology of skin lesions, their color and distribution will help generate a differential diagnosis
  1. This includes the patient's age, race, sex, details of previous treatments and duration of the problem
  2. Focus attention on the particular morphology
  3. Physicians should be sensitive to the anxieties that parents might have and address these issues appropriately
    - a. While taking a family history, note whether a family member has a similar but more severe disorder that may cause concern (e.g. psoriasis). Talking about these issues will let the parent know that you understand their concerns
  4. Developmental aspects, previous illnesses and previous surgery are important points in the history
  5. Newborn history should include the prenatal period, pregnancy and delivery

## HISTORY

- Take a thorough history of events surrounding the skin disorder (Table 1.1)

**Table 1.1 Interviewing and treating pediatric dermatology patients**

1. Children are different from adults. Learn the differences.
2. Approach patients cautiously. Sit across the room and talk to the parents before examining the child. This gives them time to 'size you up'.
3. Speak directly to the child as if he/she understands what you are saying. Make eye contact with the child.
4. Keep the parent in the room for procedures as much as possible unless it interferes with the procedure or the parent wishes to step out of the room.
5. Conservative management is best. Try to use the lowest effective dose of medication for the shortest time.
6. Avoid new therapies which do not have a proven track record in pediatrics until adequate clinical trials are performed.
7. Do not use treatments which may decrease growth or mental development.
8. Anticipatory guidance and emotional support are helpful especially in chronic disorders (e.g. alopecia areata, atopic dermatitis).

Adapted from Honig PJ. Potential clinical management risks in pediatric dermatology. Risk Management in Dermatology, Part II. AM Medica Communications LTS: New York, 1988: 6



- a. Maternal history may quickly lead to a diagnosis in some cases (e.g. maternal HIV or systemic lupus erythematosus)
6. Evaluation of young children requires a modified approach, depending upon the age of the child
  - a. Establish a positive relationship with not only the parent but also the child
  - b. Gain eye contact with the child at his own level. This is less threatening than standing over him in an intimidating manner
  - c. Sit and talk to the parents without making any movements toward the young child. This allows time for him/her to observe your actions ('size you up') before speaking with them directly
  - d. Refrain from using a loud voice or touching the child until he feels comfortable. These are techniques which pediatricians know very well
  - e. Allow the child to play with small toys in the room. This is a way to distract him and allows one to observe his interactions, which could help with developmental history
  - f. Obviously, young children cannot always answer specific questions. However, carefully observing the child may reveal answers to questions not even asked (e.g. observing scratch marks on a 6-month-old child obviates the necessity of asking whether the child is scratching)
7. School age children (5–10 years) can answer questions directly and are sometimes very informative
  - a. Engaging them in conversation about school or an interest, such as a pet, may put the child at ease quickly
8. Adolescents can give a history and should be given instructions, giving the adolescent the ability to take care of his own skin, demonstrating his maturity and ability to care for his own health

1. Additional lighting with high-intensity examination lights
  2. Side-lighting may demonstrate subtle elevations or depressions
- A magnifying glass may enlarge tiny variations of the skin
  - Examination of the genitalia should not be overlooked; have an assistant or parent in the room, not only for the comfort of the patient but also for legal purposes
  - Mucous membranes should also be examined, specifically looking for ulcers, white spots or pigmented lesions that may reflect a primary skin disorder
  - Teeth should be examined for evidence of enamel dysplasia (pitting), infection or general hygiene

## TERMINOLOGY

- The description of lesions is important to help determine whether lesions are primary (initial) lesions or secondary lesions
- Primary lesions are *de novo* lesions which are most representative of the disorder (Table 1.2)
- Secondary lesions occur with time and demonstrate other changes (Table 1.3)
- Configuration describes the pattern of lesions on the skin (Table 1.4)
- Distribution describes where the lesions are found. Examples: localized, generalized, patchy, symmetric, asymmetric, segmental, dermatomal, or following Blaschko lines
- Number of lesions: single, grouped or multiple
- Color of lesions: red, pink, blue, brown, black, white, yellow or a variation of these colors (Table 1.5)
- Regional patterns if lesions are found primarily in a certain distribution (Table 1.6). Examples: photosensitive eruptions are seen on the face and arms with sun exposure; tinea versicolor tends to be on the upper chest and back

## PHYSICAL EXAMINATION

- Include the entire skin surface including hair, nails and oral mucosa
- Adequate lighting is important, preferably natural lighting through a window

## DISEASES

- In a pediatric dermatological practice, 35 diseases account for more than 90% of the diagnoses seen in patients (Table 1.7)

**Table 1.2 Primary lesions**

<i>Primary (initial) lesions</i>	<i>Description</i>
Macule	Flat; any change in color of the skin < 1 cm in size
Patch	Flat lesion > 1 cm in size
Papule	Solid elevated lesion < 1 cm diameter; greatest mass above skin surface
Nodule	Solid elevated lesion > 1 cm diameter; greatest mass below skin surface
Tumor	Solid elevated lesion > 2 cm diameter; greatest mass below skin surface
Plaque	Raised, flat, solid lesion > 1 cm; may show epidermal changes
Wheal	Raised, solid, edematous papule or plaque without epidermal change
Vesicle	Fluid-filled (clear) < 1 cm diameter, usually < 0.5 cm
Bulla	Fluid-filled (clear) > 1 cm diameter
Pustule	Vesicle or bulla with purulent fluid
Cyst	Cavity lined with epithelium containing fluid, pus, or keratin
Comedone	Plugged sebaceous follicle containing sebum, cellular debris and anaerobic bacteria
Petechiae	Extravasated blood into superficial dermis appearing as tiny red macules
Purpura	Extravasated blood into dermis and/or subcutaneous tissues associated with inflammation; may or may not be palpable

**Table 1.3 Secondary lesions**

<i>Secondary lesions</i>	<i>Description</i>
Crust	Collection of dried serum, blood, pus and damaged epithelial cells
Exudate	Moist serum, blood or pus from either an erosion, blister or pustule
Eschar	Dark or black plaque overlying an ulcer; seen in tissue necrosis
Scale	Dry, flaky surface with normal/abnormal keratin; present in proliferative or retention disorders
Lichenification	Accentuation of normal skin lines caused by thickening, primarily of the epidermis, due to scratching or rubbing
Excoriation	Localized damage to skin secondary to scratching
Erosion	Superficial depression from loss of surface epidermis
Ulcer	Full-thickness loss of epidermis, some dermis and subcutaneous fat, which results in a scar when healed
Fissure	Linear crack in the skin, down to the dermis
Atrophy	Thinning or loss of epidermis and/or dermis Epidermal atrophy may be very subtle, showing only fine wrinkling of the skin with increased underlying vascular prominence Dermal atrophy shows little if any epidermal change but shows depressions, reflecting loss of dermis or subcutaneous tissue
Scar	Healed dermal lesion caused by trauma, surgery, infection
Papillomatous	Surface with minute finger-like projections
Friable	Skin bleeds easily after minor trauma
Pedunculated	Papule or nodule on a stalk with a base usually smaller than the papule or nodule
Filiform	Finger-like, usually associated with warts on the face

**Table 1.4 Configuration of skin lesions**

<i>Configuration</i>	<i>Description</i>
Annular	Round lesion with an active margin and a clear center (e.g. granuloma annulare, tinea corporis)
Linear	Lesion occurring in a line (e.g. poison ivy dermatitis, excoriations)
Grouped	Lesions of any morphology located close together (e.g. molluscum)
Target	Dark, dusky center with erythematous border and lighter area in between (e.g. erythema multiforme)
Arciform	Semicircular
Gyrate/polycyclic	Lesions which were annular and/or arched and have moved and become joined
Serpiginous	Snake-like margins (e.g. urticaria, creeping eruption)
Herpetiform	Appearing like an eruption of herpes simplex virus with tightly grouped vesicles or pustules (e.g. dermatitis herpetiformis)
Zosteriform/ dermatomal	Following a dermatome (e.g. herpes zoster)
Segmental	Following a body segment (e.g. hemangioma)
Reticulated	Net-like pattern (e.g. livedo reticularis)
Umbilicated	Surface has round depression in center (e.g. molluscum contagiosum)

**Table 1.5 Other descriptive terms**

<i>Characteristic</i>	<i>Examples</i>
Color	Pink – caused by increase in blood flow or interstitial fluid Red – caused by increased blood or dilated blood vessels Purple – caused by increased blood or dilated blood vessels Violaceous – lavender, bluish pink Depigmented – complete loss of pigment Hypopigmented – partial loss of pigment Brown – increase in melanin in epidermis Gray/blue – increase in melanin in dermis or subcutaneous tissue Black – intensely concentrated melanin Yellow – associated with lipids or sebaceous glands
Border	Circumscribed – limited in space by something drawn around or confining an area Diffuse – spreading, scattered
Palpation	Smooth – surface not different from surrounding skin Uneven – felt in scaly or verrucous lesions Rough – feels like sandpaper

- Reaction patterns help group disorders together (Table 1.8)
  1. Examples are eczematous eruptions: atopic dermatitis, allergic contact dermatitis
  2. Examples are papulosquamous disorders: psoriasis, seborrheic dermatitis

## DIAGNOSTIC TESTS

### Potassium hydroxide examination

Potassium hydroxide (KOH) examination is used for suspected fungal infections of skin, hair and nails

**Table 1.6 Regional patterns and diagnosis****Scalp**

Seborrheic dermatitis  
Tinea capitis  
Alopecia areata  
Psoriasis  
Nevus sebaceus  
Aplasia cutis congenita

**Face**

Contact dermatitis  
Perioral dermatitis  
Pityriasis alba  
Acne  
Milia  
Photosensitivity disorders

**Trunk**

Tinea corporis  
Tinea versicolor  
Pityriasis rosea  
Psoriasis

**Extremities**

Psoriasis (also scalp and nails)  
Scabies (also groin and waistline)  
Granuloma annulare  
Erythema nodosum  
Erythema multiforme  
Dyshidrotic eczema  
Gianotti–Crosti syndrome  
Cutis marmorata

**Nails**

Psoriasis  
Alopecia areata  
Twenty nail dystrophy  
Lichen planus  
Ingrown toenail

**Oral**

Lichen planus  
Mucocele  
Geographic tongue  
Stevens–Johnson syndrome

**Genital/groin**

Lichen sclerosus  
Condyloma acuminata  
Acrodermatitis enteropathica  
Intertrigo

- Scrapings (using a scalpel blade) from a scaly lesion are placed on a clean glass slide
- Nail scrapings can be obtained by scraping with a scalpel blade or small dermal curette underneath the nail for keratinous subungual debris
- Place scrapings on a glass slide

**Table 1.7 Most common dermatoses in children**

Acne  
Alopecia areata  
Atopic dermatitis (eczema)  
Café au lait macules  
Capillary malformation (port wine stain)  
Condyloma acuminata  
Contact dermatitis  
Drug eruption  
Epidermal cyst  
Folliculitis  
Granuloma annulare  
Hemangioma  
Herpes simplex  
Ichthyosis  
Impetigo  
Keloid  
Keratosis pilaris  
Mastocytosis  
Milia  
Molluscum  
Nevi  
Pityriasis alba  
Postinflammatory hyperpigmentation  
Postinflammatory hypopigmentation  
Psoriasis  
Pyogenic granuloma  
Scabies  
Seborrhea  
Telangiectasias  
Tinea capitis  
Tinea corporis  
Tinea versicolor  
Urticaria  
Viral exanthem  
Vitiligo  
Warts

- Apply a few drops of 10–20% KOH
- Apply a cover slip
- Heat the slide to facilitate dissolution of the cell walls or allow the slide to sit for 15–20 min without heating
- If 20% KOH in dimethylsulfoxide (DMSO) is used, heating is unnecessary
- KOH can also be formulated in ink-based preparations which darken the hyphae for easier identification (examples: Chlorazole fungal stain from Delasco Dermatologic Lab and Supplies, Inc ([www.delasco.com](http://www.delasco.com)), or Swartz–Lampkin solution)
- Examine microscopically at 10× or 20× power with the condenser in the lowest position

**Table 1.8 Common dermatologic diagnoses by reaction pattern**

<b>Eczematous</b>	<b>Infiltrative pattern</b>	Erythema multiforme
Atopic dermatitis (eczema)	Nodular	Erythema annulare centrifugum
Infantile eczema	Erythema nodosum	
Nummular eczema	Pyogenic granuloma	<b>Acneiform</b>
Allergic contact dermatitis	Juvenile xanthogranuloma	Acne vulgaris
Dermatophytosis	Cyst	Steroid-induced acne
Diaper dermatitis	Papular	Perioral dermatitis
Scabies	Granuloma annulare	Rosacea
	Mastocytosis	
<b>Papulosquamous</b>	Xanthomas	<b>Verrucous</b>
Psoriasis	Molluscum contagiosum	Warts
Seborrheic dermatitis		Nevus sebaceus
Pityriasis rosea		Epidermal nevus
Syphilis	<b>Atrophy and/or sclerosis</b>	
Lichen planus	Scleroderma	<b>Erosive</b>
	Morphea	Acrodermatitis enteropathica
<b>Vesiculobullous</b>	Lichen sclerosus	Epidermolysis bullosa
Impetigo	Lipoatrophy	
Herpes simplex virus	Aplasia cutis congenita	
Varicella-zoster virus	<b>Vascular reactions/erythema</b>	
Epidermolysis bullosa	Urticaria	
Miliaria	Vasculitis	
Scabies	Viral exanthem	

- Demonstration of hyphae or spores confirms the diagnosis of tinea
- Oral lesions suspected of *Candida* can be scraped in a similar fashion to demonstrate the typical pseudohyphae or budding yeast forms

### Scabies preparation

Scrape a burrow or unexcoriated papule, and apply KOH or mineral oil to the slide before microscopic examination

- Best areas to find mites: wrists, in between fingers, or along sides of feet of infants
- Examine at 4× power to demonstrate mites, eggs or scybala (feces)

### Pediculosis

This can be confirmed by finding a live louse on the skin or scalp, or by demonstrating nits on the hair shafts

- Affected hairs can be cut with scissors, placed on a glass slide and covered with immersion oil or KOH to demonstrate nits

### Fungal cultures

Fungal cultures confirm a diagnosis of tinea capitis, tinea corporis or onychomycosis

- Using appropriate fungal culture media (Sabouraud's agar, Mycosel agar) allows for identification of fungal species
- Dermatophyte Test Media (DTM) can be used in the office for easy identification of dermatophytes, but does not speciate fungi

### Tzanck smear

This is used for diagnosis of herpes simplex or varicella-zoster virus

- Remove vesicle roof with a scalpel blade and place on a glass slide
- The base of the lesion is gently scraped and transferred to a slide, then stained with a Giemsa or Wright stain
- Multinucleated giant epithelial cells under 40× microscopy are diagnostic for herpes virus or varicella-zoster infections

## Wood's lamp examination

A Wood's lamp emits long-wave ultraviolet light

- Screening for fungal scalp infections caused by *Microsporum* species shows green fluorescence of affected hair shafts
  1. It is important to verify that the actual hair shaft is causing fluorescence, which can easily be seen with a magnifying lens
  2. Lint, scales and other debris on the scalp also fluoresce and should not be confused with tinea
- Hypopigmentation or depigmentation can be accentuated (e.g. tuberous sclerosis patches) and delineated, particularly in light-skinned patients
- *Corynebacterium minutissimum*, which causes erythrasma, fluoresces a coral red color
- Urine of patients with certain types of porphyria fluoresces pink

## Bacterial cultures

- Purulent material from representative lesions are swabbed with a soft sterile swab, inserted into the appropriate tube and sent to the laboratory

## Viral culture

This requires a special transport medium, which is available at most large hospitals

- Blister fluid and the base of the lesion should be swabbed or aspirated and then inoculated into the appropriate media

## Skin biopsy

Skin biopsy is carried out for routine histopathologic or immunofluorescence examination

- Topical anesthetic can be applied to the skin prior to biopsy to reduce the pain of the needle stick for local anesthesia
- Punch biopsies or elliptical biopsies should demonstrate all three levels of the cutis (epidermis, dermis and subcutaneous fat)

- Shave biopsies (saucerization) may be indicated for more superficial lesions
- Biopsy is best done by a physician who is trained in the knowledge of which areas are best biopsied and what histology is expected
- Immunofluorescence may be indicated for certain connective tissue disorders or bullous diseases and requires special transport media

## Diascopy

Diascopy is performed by placing a glass slide over the skin lesions with light pressure

- Vascular lesions typically show characteristic blanching with refilling once the slide has been removed
- Granulomatous disorders such as sarcoidosis may demonstrate an apple jelly color

## References

- Brodtkin RH, Janniger CK. Common clinical concerns in pediatric dermatology. *Cutis* 1997; 60: 279–30
- Eichenfield LF, Frieden IJ, Esterly NB, eds. *Textbook of Neonatal Dermatology*. WB Saunders: Philadelphia, 2001
- Eichenfield LF, Funk A, Fallon-Friedlander S, Cunningham BB. A clinical study to evaluate the efficacy of ELA Max (4% liposomal lidocaine) as compared with eutectic mixture of local anesthetics cream for pain reduction of venipuncture in children. *Pediatrics* 2002; 109: 1093–9
- Freedberg IM, Eisen AZ, Wolff K, et al., eds. *Fitzpatrick's Dermatology in General Medicine*, 6th edn. McGraw Hill: New York, 2003
- Harper J, Oranje A, Prose N, eds. *Textbook of Pediatric Dermatology*. Blackwell Science Oxford: UK, 2000
- Lewis EJ, Dahl MV, Lewis CA. On standard definitions: 33 years hence. *Arch Dermatol* 1997; 133: 1169
- Renzi C, Abeni D, Picardi A, et al. Factors associated with patient satisfaction with care among dermatological outpatients. *Br J Dermatol* 2001; 145: 617–23
- Schachner LA, Hansen RC, eds. *Pediatric Dermatology*, 3rd edn. Mosby (Elsevier): New York, 2003
- Sybert VP. *Genetic Skin Disorders*. Oxford University Press: New York, 1997



# NEONATAL DERMATOLOGY

## COMMON CUTANEOUS FINDINGS

### Vernix caseosa

#### Major points

- Common finding in the neonatal period
- Characteristic white to gray, greasy covering on the skin surface of the newborn (Figure 2.1)
- Thickness increases with gestational age
- Considered a protective covering and mechanical barrier to bacteria
- Lipid composition is variable depending on gestational age
- Discoloration and odor can indicate fetal distress and/or intrauterine infection

#### Pathogenesis

- Composed of shed epidermal cells, sebum and lanugo hairs
- Variable lipid composition of cholesterol, free fatty acids and ceramide

#### Diagnosis

- Clinical diagnosis

#### Differential diagnosis

- Ichthyoses (disorders of keratinization) if atypical

#### Treatment

- None needed

#### Prognosis

- Sheds without therapy during the first week of life

#### References

Hoeger PH, Schreiner V, Klaassen IA, et al. Epidermal barrier lipids in human vernix caseosa: corresponding

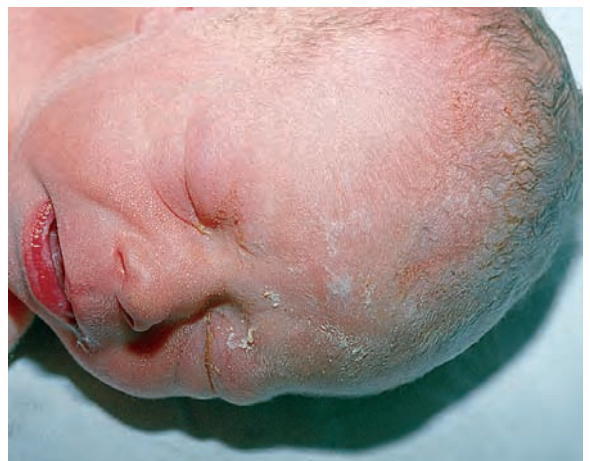ceramide pattern in vernix and fetal skin. Br J Dermatol 2002; 146: 194–201

Joglekar VM. Barrier properties of vernix caseosa. Arch Dis Child 1980; 55: 817

### Cutis marmorata

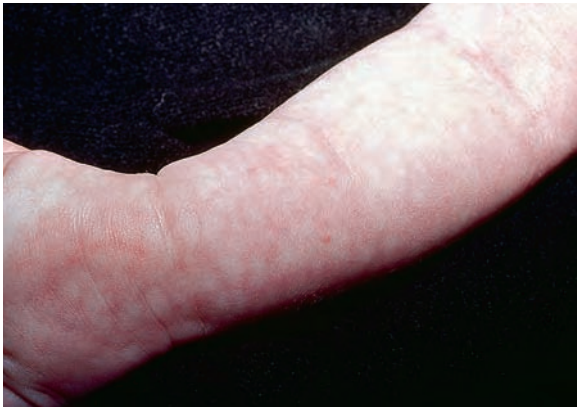
#### Major points

- Transient mottling of the skin in the newborn period
- Normal physiologic response to ambient temperature changes; accentuates with decreased temperatures and improves with rewarming
- Symmetrical, blanchable, red–blue reticulated mottling of trunk and extremities. (Figure 2.2)
- More common in premature infants, but also affects full-term newborns



**Figure 2.1** Vernix caseosa – cheesy white material in a newborn





**Figure 2.2** Cutis marmorata – reticulated vascular normal pattern in an infant

- Improves with increasing age; typically resolves by 1 year

#### *Pathogenesis*

- Physiologic vascular reaction based on immature autonomic control of the vascular plexus in response to temperature changes
- Postulated to be caused by increased sympathetic tone with delayed vasodilatation in response to a flux in temperature resulting in dilatation of capillaries and small venules
- Persistent cases associated with Down syndrome, trisomy 18, hypothyroidism, Cornelia de Lange syndrome, congenital heart disease

#### *Diagnosis*

- Clinical findings

#### *Differential diagnosis*

- Cutis marmorata telangiectatica congenita
- Livedo reticularis caused by collagen vascular disorder

#### *Treatment*

- Maintain even temperature of infant and surroundings

#### *Prognosis*

- Generally resolves spontaneously as vasomotor responses mature
- May require further evaluation for underlying disorder if persistent beyond 6 months of age and does not respond to warming (e.g. thyroid disorder, heart disease)

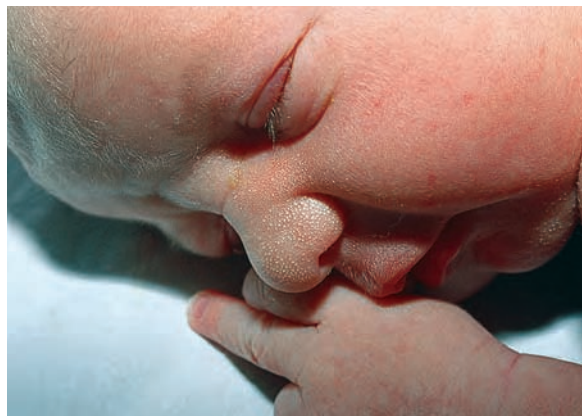#### *References*

- Devillers ACA, De Waard-Van der Spek, Oranje AP. Cutis marmorata telangiectatica congenita. Clinical features in 35 cases. Arch Dermatol 1999; 134: 34–8
- Ercis M, Balci S, Atakan N. Dermatological manifestations in 71 Down syndrome children admitted to a clinical genetics unit. Clin Genet 1996; 50: 317–20
- Treadwell PA. Dermatoses in newborns. Am Fam Physician 1997; 56: 443–50

### **Sebaceous gland hyperplasia**

#### *Major points*

- Prominent sebaceous glands present in the newborn period
- Affects up to 50% of term infants; less common in premature infants
- Characteristic pinpoint yellow papules with no surrounding erythema (Figure 2.3)
- Location: nose, cheeks, upper lip and forehead



**Figure 2.3** Sebaceous gland hyperplasia seen in a newborn

#### *Pathogenesis*

- Caused by maternal androgen stimulation of sebaceous glands that occurs in the final month of gestation

#### *Diagnosis*

- Clinical findings
- Histology: enlarged sebaceous gland with a widened sebaceous duct

### Differential diagnosis

- Milia
- Neonatal acne

### Treatment

- None required or recommended

### Prognosis

- Spontaneous resolution during the first few months of life

### Reference

Rivers JK, Friederiksen PC, Dibin C. A prevalence survey of dermatoses in the Australian neonate. *J Am Acad Dermatol* 1990; 23: 77–81

## Milia

### Major points

- Occurs in up to 40% of infants, most commonly on the face
- Known as Epstein's pearls when they occur in the oral cavity; affect up to 85% of newborns
- 1–2 mm white, firm papules on the face, but can also occur on the trunk, extremities, genitalia and oral mucosa (Figure 2.4)
- Can occur at sites of scars

### Pathogenesis

- Keratinous cyst originating from vellus hair follicle
- Results from retention of keratin within the lowest portion of the infundibulum of the pilosebaceous unit at the level of the sebaceous duct

### Diagnosis

- Clinical findings
- Histology: identical to epidermal cysts except for smaller size; lined by stratified epithelium; contains laminated keratin

### Differential diagnosis

- Neonatal acne
- Sebaceous hyperplasia
- Molluscum contagiosum

### Treatment

- No intervention required
- Incision and expression rarely required

### Prognosis

- Typically resolves within weeks to months
- Can be associated with syndromes: type I oral–facial–digital syndrome, hereditary trichodysplasia, pachyonychia congenita

### References

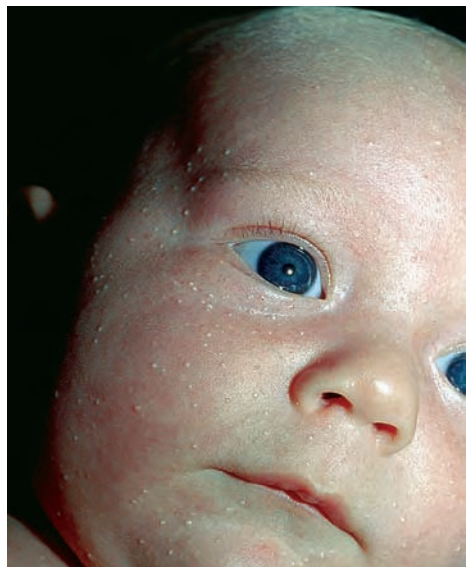- Akinduro OM, Burge SM. Congenital milia in the nasal groove. *Br J Dermatol* 1994; 130: 800
- Bridges AG, Lucky AW, Haney G, Mutasim DF. Milia en plaque of the eyelids in childhood: case report and review of the literature. *Pediatr Dermatol* 1998; 15: 282–4
- Langley RG, Walsh NM, Ross JB. Multiple eruptive milia: report of a case, review of the literature, and a classification. *J Am Acad Dermatol* 1997; 37: 353–6
- Larralde de Luna M, Paspas ML, Ibargoyen J. Oral–facial–digital type I syndrome of Papillon-Leage and Psaume. *Pediatr Dermatol* 1992; 9: 52–6
- Stefanidou MP, Panayotides JG, Tosca AD. Milia en plaque: a case report and review of the literature. *Dermatol Surg* 2002; 28: 291–5

## Erythema toxicum neonatorum

Synonym: toxic erythema of the newborn

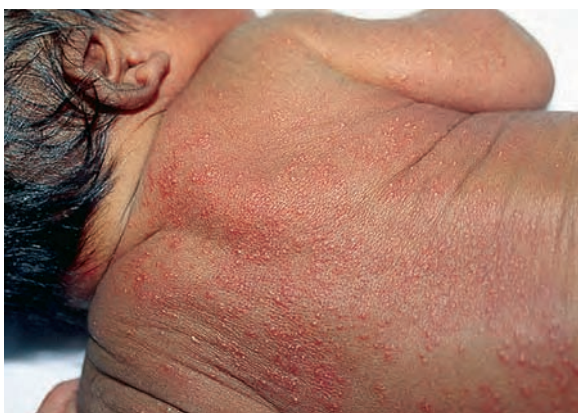### Major points

- Occurs in 40–70% of full-term infants



**Figure 2.4** Milia – multiple white papules on the face

- Rarely affects preterm infants or infants weighing <2500 g
- Characteristic eruption with macular erythema and discrete, scattered yellow papules and pustules with surrounding erythematous wheals (Figure 2.5)
- Location: primarily face, trunk and extremities with sparing of the palms and soles
- Typically occurs on day 1–2 of life; not present at birth
- Waxing/waning course over 1 month and can occur in crops
- Can be associated with a peripheral eosinophilia



**Figure 2.5** Erythema toxicum neonatorum – erythematous papules and pustules on the back

### Pathogenesis

- Unknown but several unproven hypotheses, including a transient graft-versus-host reaction against maternal lymphocytes

### Diagnostics

- Clinical findings
- Scrape a pustule; Wright stain of contents reveals numerous eosinophils and rare neutrophils
- Histology: subcorneal or intracorneal pustules filled with numerous eosinophils and some neutrophils within the follicle; exocytosis of eosinophils in the follicular epithelium; eosinophils and edema of the perifollicular papillary dermis

### Differential diagnosis

- Transient neonatal pustular melanosis
- Congenital candidiasis

- Staphylococcal impetigo
- Neonatal herpes simplex
- Scabies

### Treatment

- No treatment necessary

### Prognosis

- Self-limited course typically over 1–4 weeks

### References

- Bassukas ID. Is erythema toxicum neonatorum a mild self-limited acute cutaneous graft-versus-host reaction from maternal-to-fetal lymphocyte transfer? *Med Hypoth* 1992; 38: 334
- Marchini G, Stabi B, Kankes K, et al. AQP1 and AQP3, psoriasin, and nitric oxide synthases 1–3 are inflammatory mediators in erythema toxicum neonatorum. *Pediatr Dermatol* 2003; 20: 377–84
- Mengesha YM, Bennett ML. Pustular skin disorders: diagnosis and treatment. *Am J Clin Dermatol* 2002; 3: 389–400
- Nanda S, Reddy BSN, Ramji S, Pandhi D. Analytical study of pustular eruptions in neonates. *Pediatr Dermatol* 2002; 19: 210–15
- Schwartz RA, Janniger CK. Erythema toxicum neonatorum. *Cutis* 1996; 58: 153–5
- VanPraag MC, VanRooy RW, Folkers E, et al. Diagnosis and treatment of pustular disorders in the neonate. *Pediatr Dermatol* 1997; 14: 131–43
- Wagner A. Distinguishing vesicular and pustular disorders in the neonate. *Curr Opin Pediatr* 1997; 9: 396–405

## Transient neonatal pustular melanosis

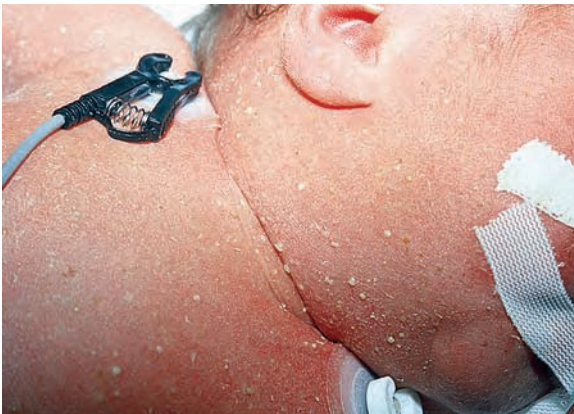### Major points

- Self-limited, benign dermatosis of the newborn
- Occurs in 0.2–4% of all term infants; 4.4% of Black infants affected, 0.6% of White infants affected
- Lesions may be present *in utero* and are almost always present at birth
- Location: distributed diffusely on trunk, face, extremities and palms and soles
- Three stages:
  1. 1–5 mm, fragile pustules present at birth; may not be evident at birth due to rupture with birth trauma or initial cleaning (Figure 2.6)

2. Resolution of pustules with surrounding fine white collarettes of scale
  3. Hyperpigmented macules represent postinflammatory hyperpigmentation (Figure 2.7); this stage may not be present in light-skinned infants
- All three lesion types can be present at any stage of presentation

### Pathogenesis

- Unknown; possible variant of erythema toxicum



**Figure 2.6** Transient neonatal pustular melanosis – pustular phase at birth

### Diagnosis

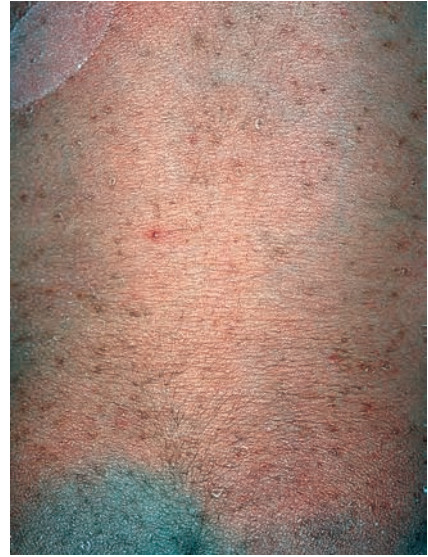- Clinical findings
- Scrape pustule and stain with Wright stain; reveals many neutrophils and rare eosinophils
- Histology
  1. Hyperpigmented macules: basilar hyperpigmentation; no dermal melanin
  2. Pustules: intracorneal or subcorneal collections of neutrophils with a few eosinophils

### Differential diagnosis

- Erythema toxicum neonatorum
- Miliaria
- Acropustulosis of infancy
- Staphylococcal impetigo
- Candidiasis

### Treatment

- No treatment necessary



**Figure 2.7** Transient neonatal pustular melanosis – hyperpigmented phase

### Prognosis

- Pustules resolve over a few days
- Hyperpigmented macules resolve over several weeks to months
- No systemic associations

### References

- Ramamurthy RS, Reveri M, Esterly NB, et al. Transient neonatal pustular melanosis. *J Pediatr* 1976; 88: 831–5
- Van Praag MC, Van Rooij RW, Folkers E, et al. Diagnosis and treatment of pustular disorders in the neonate. *Pediatr Dermatol* 1997; 14: 131–43
- Wagner A. Distinguishing vesicular and pustular disorders in the neonate. *Curr Opin Pediatr* 1997; 9: 396–405

## Neonatal cephalic pustulosis

### Major points

- Presents with monomorphic inflammatory papules and pustules on the face, scalp and neck during the first month of life
- Comedones are absent
- Lesions are not follicular
- Male/female ratio is 1 : 1

### Pathogenesis

- Lesions may be induced by inflammatory reaction to *Malassezia furfur* or *M. sympodialis*



### Diagnosis

- Potassium hydroxide preparation shows *Malassezia* sp.
- Histology: neutrophilic inflammation and yeast

### Differential diagnosis

- Infantile acne
- Erythema toxicum neonatorum
- Transient neonatal pustular melanosis
- Eosinophilic pustulosis

### Treatment

- Resolves spontaneously without treatment
- Ketoconazole or miconazole cream twice a day for 1–2 weeks

### Prognosis

- Transient and resolves without residual scarring

### References

- Bernier V, Weill FX, Hirigoyen V, et al. Skin colonization by *Malassezia* species in neonates: a prospective study and relationship with neonatal cephalic pustulosis. Arch Dermatol 2002; 138: 215–18
- Niamba P, Weill FX, Sarlangue J, et al. Is common neonatal cephalic pustulosis (neonatal acne) triggered by *Malassezia sympodialis*? Arch Dermatol 1998; 134: 995–8
- Rapelanoro R, Mortureux P, Couprie B, et al. Neonatal *Malassezia furfur* pustulosis. Arch Dermatol 1996; 132: 190–3

## Umbilical granuloma

### Major points

- Pink papule or nodule within the umbilical stump that bleeds easily (Figure 2.8)
- Develops at the site of the umbilical cord remnant after it falls off
- Clinically resembles a pyogenic granuloma

### Pathogenesis

- Inadequate healing at umbilical stump with subsequent endothelial cell proliferation and inflammation (granulation tissue)
- Not true granuloma

### Diagnosis

- Clinical findings
- Histology: endothelial cell proliferation without atypia

### Differential diagnosis

- Omphalomesenteric duct cyst/umbilical polyp
- Patent urachus

### Treatment

- Silver nitrate application
- Cryocautery, ligature and excision have been reported to be successful

### Prognosis

- Can resolve spontaneously but usually requires treatment
- Persistence indicates the presence of an umbilical remnant

### References

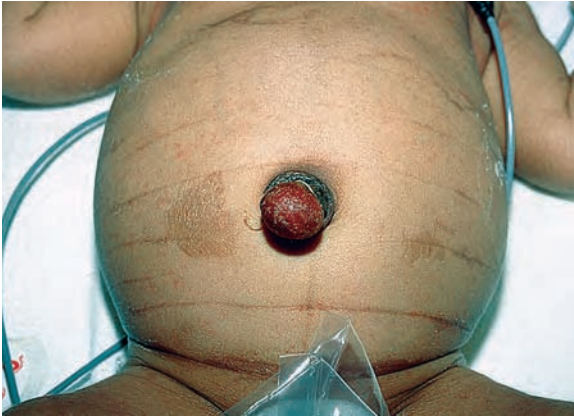
- Campbell J, Beasley SW, McMullin N, Hutson JM. Clinical diagnosis of umbilical swellings and discharges in children. Med J Aust 1986; 145: 450–3
- Donlon CR, Furdon SA. Assessment of the umbilical cord outside of the delivery room. Part 2. Adv Neonatal Care 2002; 2: 187–97

## OTHER CUTANEOUS DISORDERS

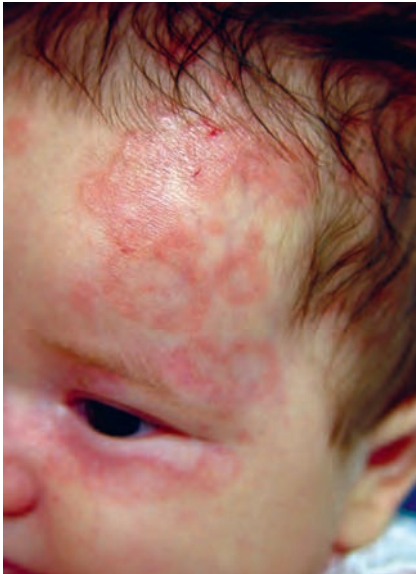### Neonatal lupus erythematosus

#### Major points

- Cutaneous findings seen in 50% with two variants: papulosquamous (most common) and annular (See Chapter 15)
- Location most common on the face and scalp with characteristic patterns:
  1. 'Raccoon eyes' or 'owl-like' periocular involvement
  2. 'Headband' distribution with lesions on the forehead and bilateral temporal areas (Figure 2.9)
- Skin lesions rarely present at birth and usually develop in the first few weeks of life after light exposure
- New lesions can continue to appear for up to 6 months and then fade with waning of the maternal autoantibodies
- Congenital heart abnormalities (most common is congenital heart block) occur in up to 30% of affected infants and have up to 20% mortality rate; appropriate work-up mandatory if diagnosis suspected



**Figure 2.8** Umbilical granuloma – vascular nodule on the umbilicus



**Figure 2.9** Neonatal lupus erythematosus – typical annular lesions on the face

- Other findings: thrombocytopenia, cholestatic liver enzyme elevation, anticardiolipin antibodies, thrombosis, hypocalcemia, pneumonia
- Transient brain computerized tomography (CT) abnormalities, spastic paraparesis, myasthenia gravis, and neurologic symptoms caused by vasculopathy of the central nervous system (CNS)

### Pathogenesis

- 95% of mothers have anti-Ro (SS-A) autoantibodies and 60–80% have anti-La (SS-B)

autoantibodies, and occasionally anti-RNP autoantibodies

1. The majority of mothers are asymptomatic
  2. Mothers are affected by mild systemic lupus erythematosus or Sjögren syndrome
- IgG autoantibodies are transplacentally passed to the fetus and bind to autoantigens, causing cellular cytotoxicity and inflammation
  - Skin lesions resolve with waning maternal autoantibodies
  - Cardiac inflammation causes permanent scarring in conduction system of the heart

### Diagnosis

- Clinical findings confirmed by blood tests
- Serologic studies: anti-Ro (SS-A), anti-La (SS-B), anti-RNP, anti-DNA, anticardiolipin antibodies, antinuclear antibodies and rheumatoid factor may be positive
- Histology: epidermal atrophy, basal vacuolar changes, dermal edema and superficial mucin with minimal lymphocytic inflammation
- Direct immunofluorescence: linear IgG, IgM and C3 along the basement membrane zone in up to 60% of cases

### Differential diagnosis

- Erythema multiforme
- Tinea corporis
- Urticaria
- Bullous pemphigoid
- Annular erythema of infancy
- Erythema annulare centrifugum

### Treatment

- Broad-spectrum sunblock daily
- Topical steroids: low- or high-potency depending on severity
- Oral corticosteroids (rarely needed)
- Pulsed dye laser for residual telangiectasias after antibodies undetectable
- Congenital heart block: cardiology consultation intravenous immunoglobulins (IVIG), pacemaker as indicated

### Prognosis

- Skin lesions resolve in 1–2 years with occasional residual dyspigmentation, telangiectasias and mild scarring

- Transient liver and brain CT abnormalities
- Congenital heart block: 50% require a pacemaker; 15% mortality
- Recurrent pancytopenia has been reported in the neonatal period, and may be related to ribonuclear protein and Smith autoantibodies
- Small increased risk of associated disorders later: juvenile rheumatoid arthritis, Hashimoto thyroiditis, congenital hypothyroidism, diabetes mellitus, psoriasis, nephritic syndrome and iritis

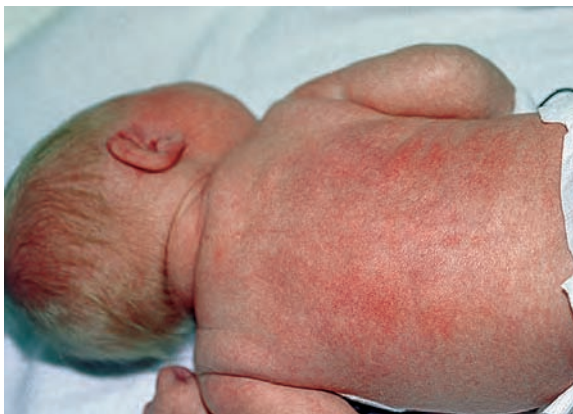## References

- Arkachaisri T, Lehman TJ. Systemic lupus erythematosus and related disorders of childhood. *Curr Opin Rheumatol* 1999; 11: 384–92
- Brucato A, Cimaz R, Stramba-Badiale M. Neonatal lupus. *Clin Rev Allergy Immunol* 2002; 23: 279–99
- Buyon JP, Clancy RM. Neonatal lupus: review of proposed pathogenesis and clinical data from the US-based Research Registry for Neonatal Lupus. *Autoimmunity* 2003; 36: 41–50
- Buyon JP, Clancy RM. Neonatal lupus syndromes. *Curr Opin Rheumatol* 2003; 15: 535–41
- Cimaz R, Spence DL, Homberger L, Silverman FD. Incidence and spectrum of neonatal lupus erythematosus: a prospective study of infants born to mothers with anti-Ro autoantibodies. *J Pediatr* 2003; 142: 678–83
- High WA, Costner MI. Persistent scarring, atrophy, and dyspigmentation in a preteen girl with neonatal lupus erythematosus. *J Am Acad Dermatol* 2003; 48: 626–8
- Prendiville JS, Cabral DA, Poskitt KJ, Au S, Sargent MA. Central nervous system involvement in neonatal lupus erythematosus. *Pediatr Dermatol* 2003; 20: 60–7
- Sandborg CI. Childhood systemic lupus erythematosus and neonatal lupus syndrome. *Curr Opin Rheum* 1998; 10: 481–7
- Silverman ED, Laxer RM. Neonatal lupus erythematosus. *Rheum Dis Clin* 1997; 23: 599–618

## Subcutaneous fat necrosis

### Major points

- Presents with asymptomatic subcutaneous nodules or erythematous plaques in otherwise healthy full-term and post-term infants at 1–6 weeks of life (Figure 2.10)
- Often follows a difficult delivery with perinatal complications such as hypothermia and asphyxia
- Location: typically involves the cheeks, shoulders, buttocks, thighs and legs
- Can develop calcification, fluctuance or ulceration
- Can develop hypercalcemia with symptoms of irritability, vomiting, failure to thrive and seizures as well as nephrocalcinosis up to 5 months after initial presentation



**Figure 2.10** Subcutaneous fat necrosis – erythematous firm patches on the back

### Pathogenesis

- Unknown with several hypotheses
  1. Localized hypoxic injury to fat secondary to trauma
  2. Increased saturated fatty acid : unsaturated fatty acid ratio in newborn that predisposes to crystallization with hypothermia
  3. Hypothermia

### Diagnosis

- Clinical findings
- Histology: lobular panniculitis with patchy areas of fat necrosis and fat cyst formation, polymorphous inflammation and typical needle-shaped clefts

### Differential diagnosis

- Traumatic panniculitis
- Post-steroid panniculitis
- Sclerema neonatorum

### Treatment

- Treatment usually unnecessary
- Aspiration of fluctuant lesions

- Hypercalcemia requires appropriate treatment and may include hydration, furosemide, intravenous corticosteroids and etidronate

### Prognosis

- Most infants have resolution of lesions within 1–2 months
- Subcutaneous atrophy can occur
- Monitor for hypercalcemia for 6 months after initial presentation of skin lesions (can be fatal), especially if lesions are extensive

### References

- Bachrach LK, Lum CK. Etidronate in subcutaneous fat necrosis of the newborn. *J Pediatr* 1999; 135: 530
- Burden AD, Krafchik BR. Subcutaneous fat necrosis of the newborn: a review of 11 cases. *Pediatr Dermatol* 1999; 16: 384–7
- Cook JS, Stone MS, Hansen JR. Hypercalcemia in association with subcutaneous fat necrosis of the newborn: studies of calcium-regulating hormones. *Pediatrics* 1992; 90: 3
- Hicks MJ, Levy ML, Alexander J, Flaitz CM. Subcutaneous fat necrosis of the newborn and hypercalcemia: a case report and review of the literature. *Pediatr Dermatol* 1993; 10: 271–6
- Mather MK, Sperling LC, Sau P. Subcutaneous fat necrosis of the newborn. *Int J Dermatol* 1997; 36: 435–52

## Sclerema neonatorum

### Major points

- Characteristic widespread thickening and induration of the skin in critically ill newborns (e.g. sepsis, hypoglycemia and metabolic acidosis)
- May occur up to 4 months of age
- Presents with sudden onset of rapid hardening of the skin that starts distally and progresses to involve the skin diffusely but with sparing of the palms, soles and genitalia
- No pitting of the skin is noted with pressure
- Skin becomes bound-down with mask-like facies and immobile joints

### Pathogenesis

- Etiology unknown; hypothesis of cold injury and secondary solidification of the tissue due to enzymatic dysfunction

### Diagnosis

- Clinical findings in typical setting
- Histology: identical to subcutaneous fat necrosis

### Differential diagnosis

- Subcutaneous fat necrosis of newborn
- Restrictive dermopathy
- Systemic sclerosis
- Stiff skin syndrome

### Treatment

- Supportive measures to reverse the underlying disorder: temperature control, hydration, electrolyte balance and aggressive antibiotic therapy
- Systemic corticosteroid use is controversial
- Exchange transfusions

### Prognosis

- High infant mortality related to the underlying condition
- Skin changes can resolve with treatment of the underlying disorder
- Worse prognosis with thrombocytopenia, neutropenia, and progressive acidosis

### References

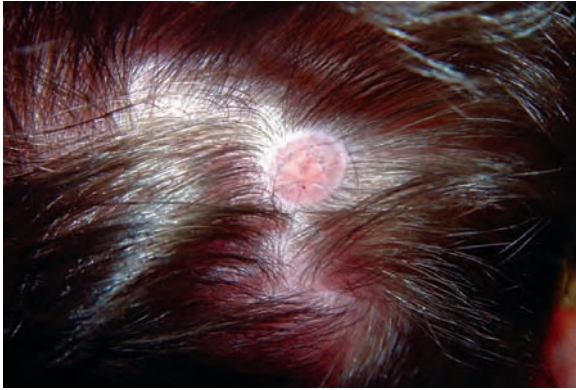- Battin M, Harding J, Gunn A. Sclerema neonatorum following hypothermia. *J Paediatr Child Health*. 2002; 38: 533–4
- Burden AD, Krafchik BR. Subcutaneous fat necrosis of the newborn: a review of 11 cases. *Pediatr Dermatol* 1999; 16: 384–7
- Requena L, Sanchez Yus E. Panniculitis. Part II. Mostly lobular panniculitis. *J Am Acad Dermatol* 2001; 45: 325–61, quiz 362–4

## Aplasia cutis congenita

### Major points

- Occurs in approximately 1 : 5000 births
- Characterized by the absence of skin (i.e. epidermis, dermis and/or subcutaneous tissues) in localized or widespread areas at birth
- Location: most common on the scalp (Figure 2.11)
- May be an isolated finding, associated with underlying defects or seen with other isolated anomalies, syndromes and chromosomal disorders
- Lesion types:
  1. Membranous





**Figure 2.11** Aplasia cutis congenita – typical location on the vertex of the scalp

- a. Most common presentation
- b. Typically well-circumscribed, atrophic, 1–5 cm defects
- c. Can be solitary (75%) or multiple (25%) in a linear distribution
- d. Can be bullous, eroded, ulcerated or scar-like
- e. May have an associated ‘hair collar sign,’ suggestive of associated cranial dysraphism
- f. Location: vertex of the scalp or face
2. Stellate
  - a. Midline scalp with associated underlying bony defects and vascular malformations
  - b. Can also be seen as large defects on the face or trunk with associated disorders and multiple extracutaneous findings
- Proposed classification system:
  1. Group 1: aplasia cutis congenita (ACC) of scalp without multiple anomalies
  2. Group 2: ACC of scalp with associated limb anomalies (shortening, club feet) called Adams–Oliver syndrome
  3. Group 3: ACC of scalp with associated epidermal and sebaceous nevi
  4. Group 4: ACC overlying embryologic malformations
  5. Group 5: ACC associated with fetus papyraceus or placental infarcts
  6. Group 6: ACC associated with epidermolysis bullosa (Figure 2.12)
  7. Group 7: ACC of the extremities without epidermolysis bullosa
  8. Group 8: ACC due to teratogens
  9. Group 9: ACC associated with syndromes or malformations

### Pathogenesis

- Unknown
- Proposed etiologies include: developmental, genetic, vascular insufficiency, trauma, teratogens, infection
- Most cases are sporadic; some show autosomal dominant or autosomal recessive inheritance patterns

### Diagnosis

- Clinical findings
- Histology: thinned or absent epidermis; thinned dermis with loose connective tissue and collagen disarray; thinned subcutis; small or absent appendages

### Differential diagnosis

- Trauma
- Neonatal herpes simplex infection
- Encephalocele
- Dermoid cyst
- Goltz syndrome (focal dermal hypoplasia)
- Incontinentia pigmenti
- Amniotic band syndrome

### Treatment

- Daily cleansing and topical antibiotic application if ulcerated
- Surgical excision, grafting, hair transplantation if indicated
- Genetic counseling recommended

### Prognosis

- Excellent if isolated lesion
- Most small skin lesions heal completely without treatment, as do small underlying bony defects; asymptomatic scars persist for life
- Risk of infection high with exposed dura
- Hemorrhage and death can occur from associated intracranial anomalies (rare)
- Associated syndromes and defects with variable prognosis

### References

- Benjamin LT, Trowers AB, Schachner LA. Giant aplasia cutis congenita without associated anomalies. *Pediatr Dermatol* 2004; 21: 150–3
- Casanova D, Amar E, Bardot J, Magalon G. Aplasia cutis congenita. Report on 5 family cases involving the scalp. *Eur J Pediatr Surg* 2001; 11: 280–4

Colon-Fontanez F, Fallon Friedlander S, Newbury R, Eichenfield LF. Bullous aplasia cutis congenita. *J Am Acad Dermatol* 2003; 48: S95–8

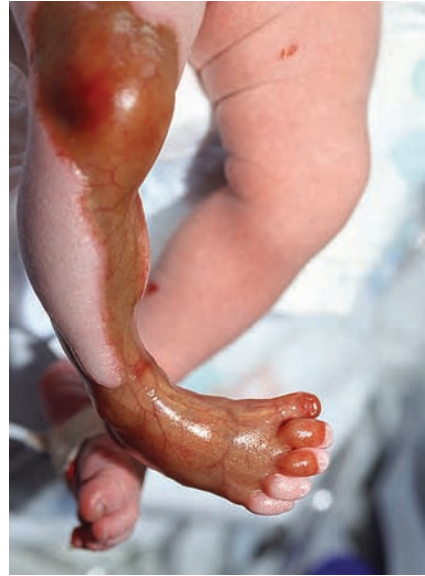Drolet B, Prendiville J, Golden J, et al. 'Membranous aplasia cutis' with hair collars. Congenital absence of skin or neuroectodermal defect? *Arch Dermatol* 1995; 131: 1427–31

Frieden IJ. Aplasia cutis congenita: a clinical review and proposal for classification. *J Am Acad Dermatol* 1986; 14: 646

Koshy CE, Waterhouse N, Peterson D. Large scalp and skull defect in aplasia cutis congenita. *Br J Plast Surg* 2000; 53: 619–22

Maman E, Maor E, Kachko L, Carmi R. Epidermolysis bullosa, pyloric atresia, aplasia cutis congenita: histopathological delineation of an autosomal recessive disease. *Am J Med Genet* 1998; 78: 127–33

Mempel M, Abeck D, Lange I, Strom K, et al. The wide spectrum of clinical expression in Adams–Oliver syndrome: a report of two cases. *Br J Dermatol* 1999; 140: 1157–60



**Figure 2.12** Aplasia cutis congenita – associated with dystrophic epidermolysis bullosa on the leg

## Nevus sebaceus of Jadassohn

### Major points

- Characteristic yellowish hairless plaque on the scalp (Figure 2.13)
- More prominent in the newborn period because of maternal hormone influence, becoming less obvious during childhood, but then more apparent and papillomatous with pubertal hormonal influences
- Location: head and neck
- Usually isolated but can be associated with other syndromes and anomalies
- Occurs in 0.3% of newborns

### Pathogenesis

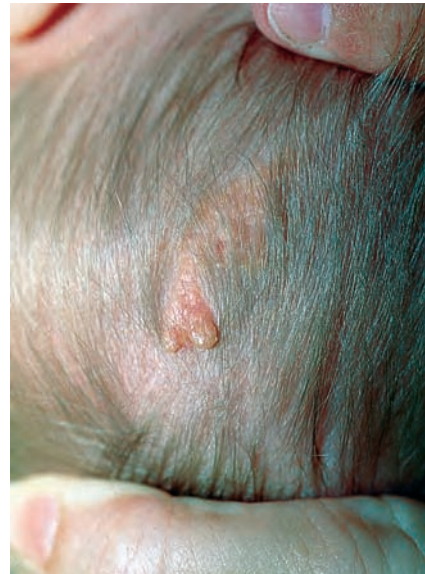- Localized developmental anomaly of appendageal structures

### Dagnosis

- Clinical findings
- Histology: mild acanthosis and papillomatosis with immature and malformed pilosebaceous units

### Differential diagnosis

- Epidermal nevus
- Aplasia cutis congenita
- Encephalocele
- Juvenile xanthogranuloma
- Verruca vulgaris



**Figure 2.13** Nevus sebaceus of Jadassohn – yellow papules in a hairless patch

### Treatment

- Observe for clinical change, since there is a low risk of malignant tumors
- Elective surgical excision, usually recommended around puberty when lesions become more apparent and annoying

### Prognosis

- Lesions persist throughout life
- Potential for secondary tumors within these lesions: syringocystadenoma papilliferum, basal cell carcinoma. Variably reported risk, up to 30%, of benign and malignant neoplastic growths, but probably very low risk for malignant growths

### References

- Beer GM, Widder W, Cierpka K, et al. Malignant tumors associated with nevus sebaceous: therapeutic consequences. *Aesthetic Plast Surg* 1999; 23: 224–7
- Chun K, Vazquez M, Sanchez JL. Nevus sebaceous: clinical outcome and considerations for prophylactic excision. *Int J Dermatol* 1995; 34: 538–41
- Cribier B, Scrivener Y, Grosshans E. Tumors arising in nevus sebaceous: a study of 596 cases. *J Am Acad Dermatol* 2000; 42: 263–8
- Dunkin CS, Abouzeid M, Sarangapani K. Malignant transformation in congenital sebaceous naevi in childhood. *J R Coll Surg Edinb* 2001; 46: 303–6
- Santibanez-Gallerani A, Marshall D, Duarte AM, et al. Should nevus sebaceous of Jadassohn in children be excised? A study of 757 cases, and literature review. *J Craniofac Surg* 2003; 14: 658–60

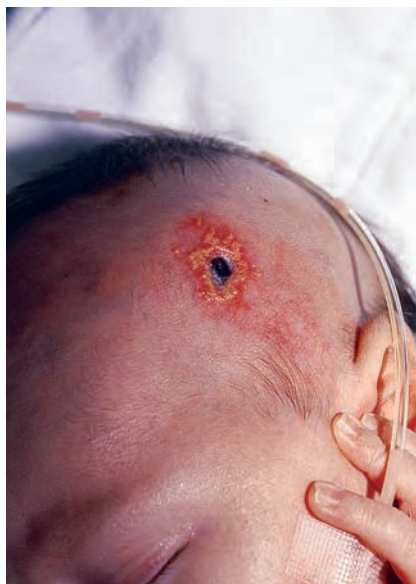## Neonatal scars

### Major points

- The number of neonatal scars is related to gestational age and length of time spent in an intensive care unit
- Scarring can occur with amniocentesis, chorionic villus sampling, fetal monitoring, arterial or venous punctures, catheter insertions, heel sticks, chest tubes, adhesives and extravasated intravenous fluids (Figure 2.14)
- Amniocentesis scars occur in <1% of neonates whose mothers underwent amniocentesis; risk decreases during second trimester; scars are usually not apparent for weeks to months after birth
- If less than 29 weeks' gestational age at birth, anetoderma can develop at sites of monitors and adhesives; presents as atrophic scars on the anterior trunk and proximal extremities

### Pathogenesis

- Caused by multiple procedures performed *in utero* or in the neonatal intensive care unit



**Figure 2.14** Neonatal scar caused by intravenous fluid extravasation

### Diagnosis

- Consistent clinical history
- Clinical findings

### Differential diagnosis

- Congenital dimples
- Congenital sinus tracts
- Aplasia cutis congenita
- Focal dermal hypoplasia (Goltz syndrome)

### Treatment

- None effective
- Red lesions (vascular component) can be treated with vascular laser with variable results

### Prognosis

- Most commonly small and inconspicuous, but can be large with underlying fibrosis
- Can develop secondary calcified papules and hypertrophic scars
- Puncture sites can rarely become secondarily infected with abscess or gangrene

### References

- Cambiaghi S, Restano L, Cavalli R, Gellmetti C. Skin dimpling as a consequence of amniocentesis. *J Am Acad Dermatol* 1998; 39: 888–90

Cartlidge PHT, Fox PE, Rutter N. The scars of newborn intensive care. *Early Hum Dev* 1990; 21: 1–10

Prizant TL, Lucky AW, Frieden IJ, et al. Spontaneous atrophic patches in extremely premature infants. *Arch Dermatol* 1996; 132: 671–4

Todd DJ. Anetoderma of prematurity. *Arch Dermatol* 1997; 133: 789

## Dermal erythropoiesis

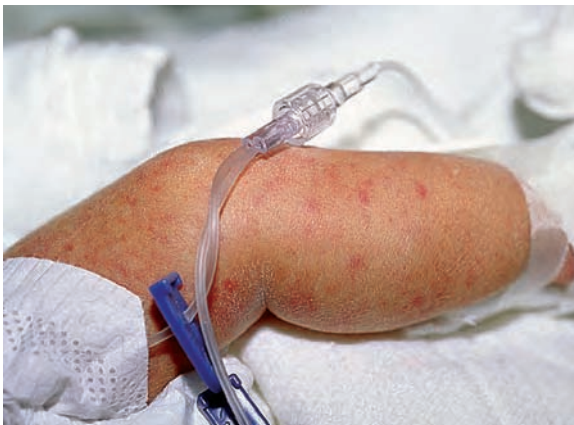Synonyms: extramedullary hematopoiesis, blueberry muffin baby

### Major points

- Hematopoiesis occurs in the skin during embryonic development
- Persistence of this process in the neonate can be seen in healthy newborns but typically results from intrauterine infection or hematologic dyscrasias
- Characteristically produces a generalized eruption with purpuric infiltrative papules primarily on the head, neck and trunk (Figure 2.15)

### Pathogenesis

- Causes: intrauterine infections such as rubella, cytomegalovirus (CMV), coxsackievirus, parvovirus, toxoplasmosis, varicella virus, HIV
- Hematologic dyscrasias: hemolytic disease of the newborn (Rh incompatibility or ABO incompatibility), spherocytosis, twin to twin transfusion



**Figure 2.15** Dermal erythropoiesis caused by neonatal infection

## Diagnosis

- Clinical findings
- Histology: superficial and deep dermal perivascular infiltration with myeloid and erythroid cells
- Work-up for underlying cause: complete blood count, TORCH serologies, viral cultures and Coombs test

## Differential diagnosis

- Diffuse neonatal hemangiomatosis
- Congenital leukemia
- Metastatic infiltration: neuroblastoma, rhabdomyosarcoma, Langerhans cell histiocytosis
- Coagulation/platelet defects

## Treatment

- None needed for skin involvement

## Prognosis

- Skin lesions resolve spontaneously over several weeks
- Overall prognosis dependent on the underlying cause

## References

- Baselga E, Drolet BA, Esterly NB. Purpura in infants and children. *J Am Acad Dermatol* 1997; 37: 673–705
- Epps RE, Pittelkow MR, Su WP. TORCH syndrome. *Semin Dermatol* 1995; 14: 179–86
- Evole-Buselli M, Hernandez-Marti MJ, Gasco-Lacalle B, et al. Neonatal dermal hematopoiesis associated with diffuse neonatal hemangiomatosis. *Pediatr Dermatol* 1997; 14: 383–6

## NEONATAL INFECTIONS

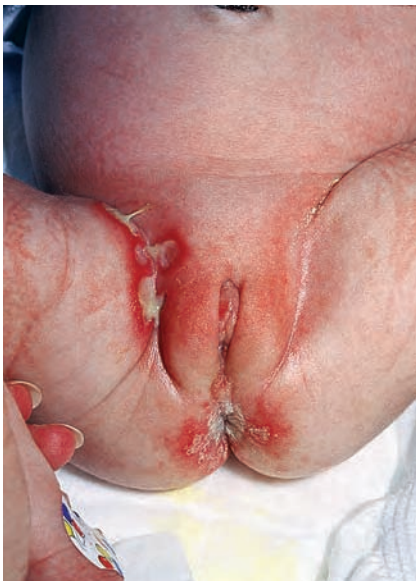### Herpes neonatorum

#### Major points

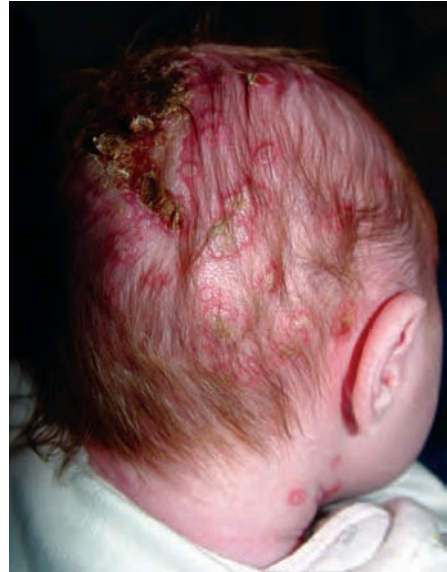- Presentation is variable and depends on route and time of exposure, virulence and maternal immunity (Chapter 8)
- Primary congenital (intrauterine) infection:
  1. 5% of herpes simplex virus (HSV) infections in the newborn period
  2. Acquired *in utero*
  3. Exposure via ascending infection or viremia
  4. Can lead to intrauterine fetal death



5. Newborn will have specific cell-mediated immunity (i.e. lymphocyte transformation) to HSV at birth, as opposed to infants who are infected at the time of labor and delivery
6. 70% have vesicles and 30% have scars at birth
7. CNS involvement: >50% have microcephaly, 60% have chorioretinitis
- Primary neonatal infection:
  1. 95% of HSV infections in newborn period
  2. HSV is acquired perinatally (85%) or postnatally (10%)
  3. Risk of perinatal infection is 50% with primary maternal infection but only 5% with recurrent maternal infection
  4. Postnatal exposure can be from maternal infection (e.g. genital or extragenital), other family members or health-care workers
  5. Incubation period highly variable: 30% have symptoms at birth; the rest appear in the first 6 weeks of life
  6. Characteristic patterns:
    - a. Skin, mouth and eye lesions – vesicles, erosions or ulcers typically on scalp or presenting part; oral vesicles, erosions or ulcers; conjunctivitis or keratitis; CNS involvement symptoms are often delayed or absent (Figures 2.16 and 2.17)



**Figure 2.16** Herpes neonatorum in a 28-day-old neonate



**Figure 2.17** Herpes neonatorum with a positive culture for herpes simplex virus-1

- b. CNS disease – cutaneous lesions present in 60%; focal encephalitis or meningoencephalitis with irritability, lethargy, fever or seizures
- c. Disseminated disease – cutaneous lesions in 77%; affects liver, adrenals, lung and brain with symptoms suggestive of neonatal sepsis

### *Pathogenesis*

- Caused by HSV type 1 or 2; most often transmitted from an infected mother
- Intrauterine, perinatal (during delivery) or postnatal (after delivery) transmission; or by postnatal contact with those with viral shedding or active lesions
- Recurrent maternal infection confers some degree of passive immunity to the neonate

### *Diagnosis*

- Viral cultures from skin and oral mucosal lesions, nasopharynx, conjunctivae, urine, plasma and cerebrospinal fluid (CSF)
- Tzanck smear of vesicles: multinucleated epithelial giant cells
- Direct fluorescent antibody for HSV-1 or -2
- Serology for HSV antibodies: rising IgG titers are sensitive and specific for infection, whereas IgM titers are not sensitive in the newborn

- Polymerase chain reaction for HSV is highly sensitive
- CSF: lymphocytic pleocytosis, elevated protein and red blood cell count indicative of CNS involvement
- Imaging: CT or magnetic resonance imaging (MRI) of the brain if indicated
- Histology: intraepidermal vesicles, ballooning and reticular degeneration with secondary acantholysis and eosinophilic intranuclear inclusion bodies

### Differential diagnosis

- Congenital infections: varicella, syphilis, enterovirus, parainfluenza, adenovirus, toxoplasmosis, CMV, bacterial sepsis
- Bullous impetigo
- Erythema toxicum neonatorum
- Transient neonatal pustular melanosis
- Sucking blister
- Incontinentia pigmenti
- Langerhans cell histiocytosis

### Treatment

- Systemic antiviral therapy:
  1. Acyclovir 30 mg/kg per day intravenously every 8 h for cutaneous-only disease; adjust for renal disease
  2. Acyclovir 60 mg/kg per day intravenously every 8 h for congenital disease, CNS or disseminated disease; adjust for renal disease
  3. Vidarabine 30 mg/kg per day intravenously every 12 h or foscarnet 40 mg/kg per day intravenously every 12 h
- Prevent secondary bacterial infection of the eroded lesions with topical mupirocin or antibiotic ointments

### Prognosis

- Intrauterine infection can result in fetal demise; nearly 100% of congenital HSV survivors have significant neurologic delay
- Cutaneous-only disease has nearly 100% survival; 40% will have ocular sequelae
- CNS infection is more severe with HSV-2 infection; 50% mortality rate if untreated, 15% mortality rate if treated; approximately 75% have permanent neurologic disease and 20% have persistent ocular disease

- Neonatal disseminated infection: 75% mortality rate if untreated and 50% mortality rate if treated; 40% will have CNS sequelae

### References

- Enright AM, Prober CG. Neonatal herpes infection: diagnosis, treatment and prevention. *Semin Neonatol*, 2002; 7: 283–91
- Jacobs RF. Neonatal herpes simplex virus infections. *Semin Perinatol* 1998; 22: 64–71
- Kimberlin DW. Neonatal herpes simplex infection. *Clin Microbiol Rev* 2004; 17: 1–13
- Kohl S. The diagnosis and treatment of neonatal herpes simplex virus infection. *Pediatr Ann* 2002; 31: 726–32
- Trizna Z, Tyring SK. Antiviral treatment of diseases in pediatric dermatology. *Dermatol Clin* 1998; 16: 539–52

## Congenital varicella and infantile herpes zoster

### Major points

- Most infants exposed to varicella *in utero* (i.e. mother had varicella during pregnancy) are normal with no sequelae (Chapter 8)
- Disease manifestations depend on the time of exposure and maternal immune response
- Congenital varicella syndrome (fetal varicella syndrome or varicella embryopathy):
  1. Fetal exposure before 20 weeks of gestation with greatest risk from 13 to 20 weeks
  2. 9% reported risk of developing disease with exposure
  3. Presents with dermatomal lesions: denuded or scarred with associated underlying tissue hypoplasia
  4. Additional findings: low birth weight, neurologic (e.g. hydrocephalus, retardation, seizures), ophthalmologic (e.g. chorioretinitis, cataracts, nystagmus), musculoskeletal (e.g. extremity hypoplasia and paresis), gastrointestinal and genitourinary anomalies
- Neonatal varicella:
  1. Due to fetal exposure near the time of delivery with maternal infection between 5 days prior to and 2 days following delivery
  2. 23–62% risk of developing disease with exposure
  3. Cutaneous findings from 1 to 16 days postpartum: papulovesicular lesions which can become hemorrhagic or necrotic

4. High risk for disseminated disease: pneumonitis, hepatitis, encephalitis
- Infantile herpes zoster:
  1. Develops during first year of life after *in utero* varicella exposure
  2. 2% of infants exposed to intrauterine varicella will develop infantile herpes zoster
  3. Clinical findings: papulovesicles in dermatomal pattern, typically thoracic area

### Pathogenesis

- Maternal varicella infection with viremia leads to fetal exposure to the varicella zoster virus (VZV)
- Infantile herpes zoster is caused by reactivation of dormant virus in the sensory dorsal root ganglia

### Diagnosis

- Consistent maternal history
- Clinical findings
- Congenital:
  1. Viral culture of amniotic fluid or fetal blood for VZV
  2. Prenatal serology and cultures are neither sensitive nor specific for diagnosing fetal infection
- Neonatal:
  1. Tzanck smear of vesicle shows multinucleated epithelial giant cells
  2. Direct fluorescent antibody for VZV
  3. Viral culture

### Differential diagnosis

- Aplasia cutis congenita
- Epidermolysis bullosa
- Neonatal infections: HSV, candidiasis, *Staphylococcus aureus*
- Erythema toxicum neonatorum
- Transient neonatal pustular melanosis

### Treatment

- Intrauterine exposure
  1. Varicella zoster immunoglobulin (VZIG) given within 5 days to nonimmune mothers with recent VZV exposure
  2. Acyclovir is considered safe for pregnant women who are infected and may minimize the risk of disease in the newborn
- Congenital varicella
  1. Supportive

2. Ultrasound anomalies include fetal hydrops, polyhydramnios, microcephaly and limb hypoplasia
- Neonatal varicella
    1. VZIG
    2. Acyclovir
    3. Isolation
  - Infantile herpes zoster
    1. No specific therapy needed if immunocompetent
    2. Consider systemic acyclovir, especially if there are hemorrhagic or disseminated lesions

### Prognosis

- Most exposures during pregnancy result in no fetal sequelae
- Intrauterine infection may lead to fetal demise
- Neonatal varicella – 10–30% mortality

### References

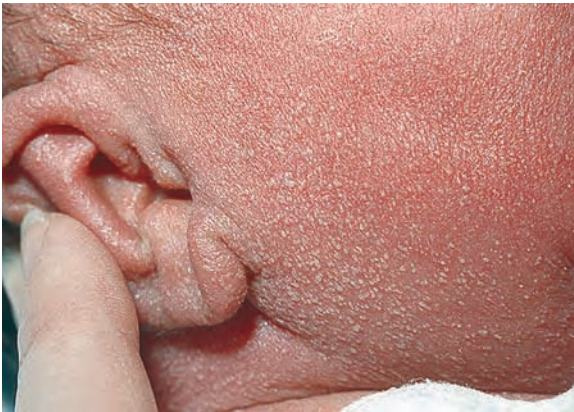- Enders G, Miller E, Cradock-Watson J, et al. Consequences of varicella and herpes zoster in pregnancy: prospective study of 1739 cases. *Lancet* 1994; 343: 1548–51
- Harger JH, Ernest JM, Thurnau GR, et al. Frequency of congenital varicella syndrome in a prospective cohort of 347 pregnant women. *Obstet Gynecol* 2002; 100: 260–5
- Nathwani D, Maclean A, Conway S, Carrington D. Varicella infections in pregnancy and the newborn. A review prepared for the UK Advisory Group on Chickenpox on behalf of the British Society for the Study of Infection. *J Infect* 1998; 36 (Suppl 1): 59–71
- Sauerbrei A, Wutzler P. Neonatal varicella. *J Perinatol* 2001; 21: 545–9
- Sauerbrei A, Wutzler P. The congenital varicella syndrome. *J Perinatol* 2000; 20: 548–54
- Tseng HW, Liu CC, Wang SM, et al. Complications of varicella in children: emphasis on skin and central nervous system disorders. *J Microbiol Immunol Infect* 2000; 33: 248–52

### Candidiasis

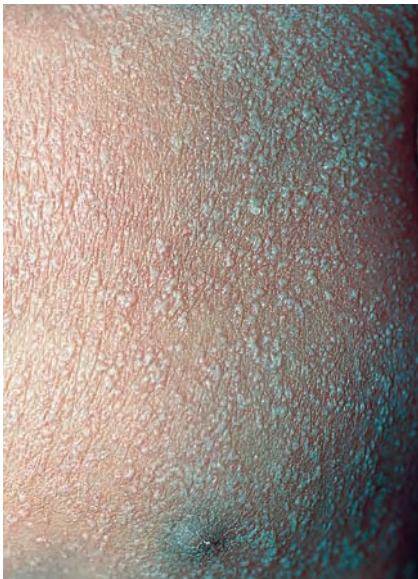#### Major points

- Congenital candidiasis
  1. Caused by ascending vaginal infection of *Candida albicans* with *in utero* exposure or direct inoculation during labor and delivery
  2. Cervical sutures and retained intrauterine devices are risk factors for infection

3. Lesions typically appear on the first day of life, presenting with generalized erythematous papulovesicular eruption leading to desquamation (Figures 2.18 and 2.19)
4. Often involves palms, soles and oral mucosa (thrush)
5. Can have respiratory and gastrointestinal involvement from aspiration of infected amniotic fluid
6. Rare development of systemic disease



**Figure 2.18** Congenital candidiasis – close-up of pustules, associated with candida septicemia



**Figure 2.19** Congenital candidiasis – sheets of pustules in a 3-day-old with only cutaneous involvement

- Neonatal candidiasis
  1. Caused by postnatal colonization of *Candida albicans*
  2. More common in low-birth-weight infants (<1500 g)
  3. Develop classic mucocutaneous eruption with satellite lesions and diaper area involvement
  4. Dissemination to the lungs, meninges and urinary tract with sepsis more common in low-birth-weight infants

### Pathogenesis

- Caused by vertical transmission with intrauterine chorioamnionitis or direct inoculation of *Candida albicans*, typically from the mother

### Diagnosis

- Potassium hydroxide preparation from skin scrapings reveals budding yeasts and pseudo-hyphae (Chapter 9)

### Differential diagnosis

- Neonatal herpes infection
- Erythema toxicum neonatorum
- Transient neonatal pustular melanosis
- Miliaria
- Staphylococcal scalded skin syndrome

### Treatment

- Topical: nystatin cream or imidazole cream  
 BID for cutaneous disease is typically sufficient
- Fluconazole 3–6 mg/kg per day PO for severe skin involvement
- Disseminated disease:
  1. Amphotericin B 0.5–1.0 mg/kg per day IV or
  2. Fluconazole 5 mg/kg per day IV or
  3. 5-fluorocytosine 50–150 mg/kg per day PO
- Intravenous fluconazole for preterm, low-birth-weight infants at risk for systemic candidiasis

### Prognosis

- Excellent for only cutaneous disease with rapid resolution over 1 week with topical therapy alone
- Disseminated disease carries a worse prognosis with increased risk of renal and CNS involvement, as well as sepsis and death



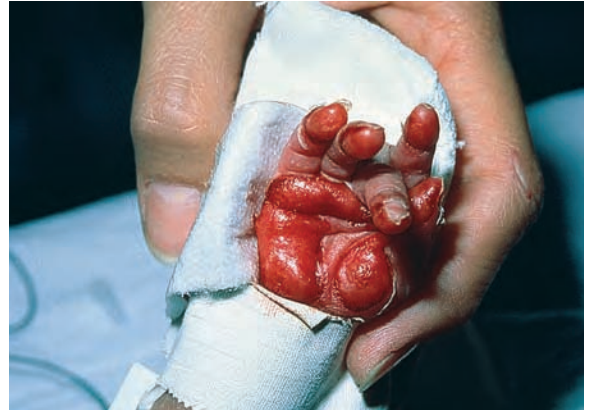## References

- Darmstadt GL, Dinulos JG, Miller Z. Congenital cutaneous candidiasis: clinical presentation, pathogenesis, and management guidelines. *Pediatrics* 2000; 105: 438–44
- Kaufman D. Strategies for prevention of neonatal invasive candidiasis. *Semin Perinatol* 2003; 27: 414–24
- Pradeepkumar VK, Rajadurai VS, Tan KW. Congenital candidiasis: varied presentations. *J Perinatol* 1998; 18: 311–16

## Congenital syphilis

### Major points

- 50–60% of infants are asymptomatic at birth
- 2–6 weeks after birth is the most common age of onset for those infants infected in the third trimester
- Early congenital syphilis is clinically similar to presentation of exaggerated secondary syphilis in an adult (Chapter 7)
- Early disease
  1. Usually apparent by 3 months of age but can be up to 2 years
  2. Presenting signs:
    - a. Syphilitic rhinitis (snuffles)
    - b. ‘Barber’ pole umbilical cord (red and blue with white streaks)
    - c. Cutaneous lesions: condyloma lata, mucous patches, petechiae, hemorrhagic vesicles/bullae on palms and soles (Figure 2.20), or diffuse papulosquamous eruption involving the palms/soles and resembling that of secondary syphilis (Figure 7.29)
    - d. Other systemic findings: meningioencephalitis, chorioretinitis, hepatosplenomegaly, lymphadenopathy (especially epitrochlear), low birth weight, prematurity, anemia, thrombocytopenia, respiratory distress and osteochondritis
- Late disease (very rare)
  1. Develops >2 years of age
  2. Cutaneous findings: rhagades, gummata
  3. Extracutaneous findings:
    - a. Neurosyphilis
    - b. Interstitial keratitis
    - c. Sensorineural hearing loss
    - d. Bony changes (saddle nose, frontal bossing, saber shins, syphilitic arthritis, Clutton joints (effusions of the knees),



**Figure 2.20** Congenital syphilis – acquired early in pregnancy; with hepatosplenomegaly, respiratory distress and erosions of palms and soles (previously published in *Pediatric Dermatology* 1989; 6: 51–2)

Higoumenaki sign (thickening of the inner third of the clavicle)

- e. Oral deformities: mulberry molars and Hutchinson pegged central incisors
- f. Paroxysmal cold hemoglobinuria
4. Hutchinson triad includes: interstitial keratitis, Hutchinson incisors, cranial nerve VIII deafness

### Pathogenesis

- Infection with spirochete *Treponema pallidum* during gestation
- Invades via placenta to infect multiple fetal organs
- Adheres to endothelial cells and causes vasculitis

### Diagnosis

- Consistent maternal history
- Clinical findings
- Spirochete identification from placenta, umbilical cord or a mucocutaneous lesion: dark field microscopy or direct fluorescent antibody
- Maternal and infant serology: infant nontreponemal titer >4 times maternal titer indicates true neonatal infection; treponemal serologies are more specific, especially IgM FTA-ABS or VDRL on CSF
- Long-bone radiologic evaluation for osteochondritis
- Histology: swelling of vascular endothelium and lymphoplasmocytic perivascular inflammation

### Differential diagnosis

- Congenital candidiasis
- Scabies
- Psoriasis
- Epidermolysis bullosa

### Treatment

- Establish status of CNS involvement by examining CSF
- Aqueous crystalline penicillin G 50 000 units/kg per dose intravenously every 12 h for first 7 days of life, then every 8 h thereafter to complete a 10-day course; infants and children are dosed at 200 000–300 000 units/kg per day divided every 4–6 h for 10 days

### Prognosis

- 25–40% intrauterine fetal death
- High risk for preterm birth and neurologic sequelae
- Skin lesions typically resolve with postinflammatory hypo- and hyperpigmentation

### References

- Evans HE, Frenkel LD. Congenital syphilis. *Clin Perinatol* 1994; 21: 149–62
- Hollier LM, Cox SM. Syphilis. *Semin Perinatol* 1998; 22: 323–31
- Parish JL. Treponemal infections in the pediatric population. *Clin Dermatol* 2000; 18: 687–700
- van Voorst Vader PC. Syphilis management and treatment. *Dermatol Clin* 1998; 16: 699–711
- Wicher V, Wicher K. Pathogenesis of maternal–fetal syphilis revisited. *Clin Infect Dis* 2001; 33: 354–63

## NEONATAL DEFECTS

### Nasal glioma

#### Major points

- Typically presents at birth
- Firm bluish or red swelling on the nasal root with overlying telangiectasias (Figure 2.21)
- Composed of ectopic neural tissue
- Regarded as a variant of encephalocele; intracranial connection not always present
- Does not increase in size with crying or Valsalva maneuver

- Majority are external; 30% can be intranasal or with oropharyngeal extension

### Pathogenesis

- Evagination of neuroectodermal tissue via a developmental abnormality of the nasofrontal fontanelle
- Failure of complete retraction during formation of dura leads to isolation of this tissue upon suture closure; a stalk may connect to the underlying brain through the foramen caecum

### Diagnosis

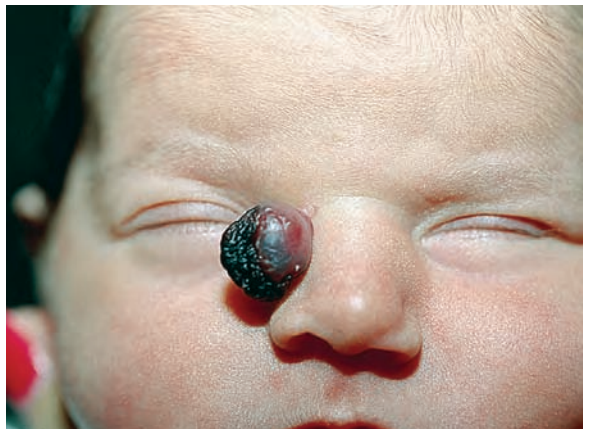- Imaging: CT or MRI recommended prior to biopsy
- Histology: collections of astrocytes embedded in dense connective tissue trabeculae with occasional striated muscle

### Differential diagnosis

- Encephalocele
- Hemangioma
- Nasal dermoid cyst
- Lacrimal duct cyst
- Neuroblastoma
- Rhabdomyosarcoma

### Treatment

- Evaluate with MRI
- Treatment is surgical by experienced pediatric surgeons in collaboration with neurosurgeons as needed



**Figure 2.21** Nasal glioma resembling a hemangioma but with a connection through the cranium in a newborn

### Prognosis

- Excellent with appropriate resection
- Recurrences occasional

### References

- El Shabrawi-Caelen L, White WL, Soyer HP, et al. Rudimentary meningocele: remnant of a neural tube defect? *Arch Dermatol* 2001; 137: 45–50
- Paller AS, Pensler JM, Tomita T. Nasal midline masses in infants and children. *Arch Dermatol* 1991; 127: 362–6
- Rahbar R, Resto VA, Robson CD, et al. Nasal glioma and encephalocele: diagnosis and management. *Laryngoscope* 2003; 113: 2069–77

## Encephalocele

### Major points

- Cystic structure on the midline face
- Presents in the neonatal period with nasal broadening (67%) or as a soft, blue pulsatile mass that transilluminates on the nasal bridge
- Increases in size with crying, Valsalva maneuver, or external compression of the jugular veins
- Associated with facial clefting and other midline defects

### Pathogenesis

- Herniation of brain tissue through the skull with connection to the underlying brain

### Diagnosis

- Image with MRI
- Biopsy of the skin lesion not recommended, owing to the connection with the subarachnoid space which could lead to CSF rhinorrhea and infection
- Histology: similar to nasal glioma

### Differential diagnosis

- Hemangioma
- Nasal glioma
- Dermoid cyst
- Hypertelorism

### Treatment

- Evaluation with MRI or CT scan is essential
- Surgical excision is recommended by a skilled pediatric neurosurgeon and otolaryngologist

### Prognosis

- Lesions persist if not surgically corrected and may become infected

### References

- Brown MS, Sheridan-Pereira M. Outlook for the child with a cephalocele. *Pediatrics* 1992; 90: 914–19
- Davis DA, Cohen PR, George RE. Cutaneous stigmata of occult spinal dysraphism. *J Am Acad Dermatol* 1994; 31: 892–6
- El Shabrawi-Caelen L, White WL, Soyer HP, et al. Rudimentary meningocele: remnant of a neural tube defect? *Arch Dermatol* 2001; 137: 45–50
- Hoving EW. Nasal encephaloceles. *Childs Nerv Syst* 2000; 16: 702–6
- Hunt JA, Hobar PC. Common craniofacial anomalies: facial clefts and encephaloceles. *Plast Reconstruct Surg* 2003; 112: 606–15
- Paller AS, Pensler JM, Tomita T. Nasal midline masses in infants and children. *Arch Dermatol* 1991; 127: 362–6

## Congenital dermal sinus

### Major points

- Cutaneous sign of potential spinal dysraphism
- Midline epithelium-lined tract most common in occipital or lumbar area
- Typically associated with a dermoid or epidermal cyst
- Presents as a dimple with an opening visible on the skin
- Tuft of hair may arise from the sinus tract
- A cord may extend from the dimple to the bony defect

### Pathogenesis

- Occurs as a result of a developmental abnormality in the separation of the neuroectoderm and the cutaneous ectoderm

### Diagnosis

- Characteristic skin findings
- Imaging studies: MRI

### Differential diagnosis

- Pilonidal sinus

### Treatment

- Excision of area only after appropriate imaging

### Prognosis

- 30% of patients are asymptomatic
- Complications: repeated meningitis or space-occupying symptoms
- In the absence of complications, surgical removal leads to resolution of symptoms and minimizes the risk of meningitis

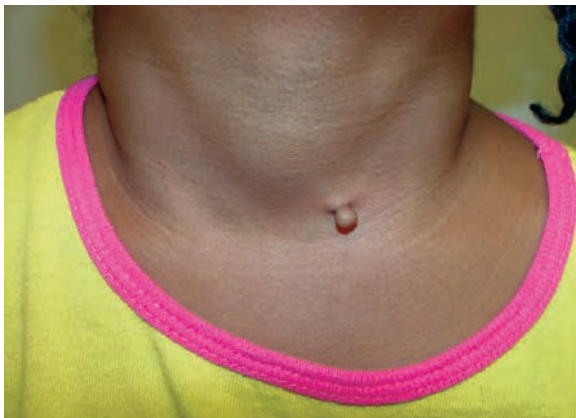### References

- Pacheco-Jacome E, Ballesteros MC, Jayakar P, et al. Occult spinal dysraphism: evidence-based diagnosis and treatment. *Neuroimag Clin North Am* 2003; 13: 327–34, xii
- Saito H, Ogonuki R, Yanadori A, et al. Congenital dermal sinus with intracranial dermoid cyst. *Br J Dermatol* 1994; 130: 235–7
- Schijman E. Split spinal cord malformations: report of 22 cases and review of the literature. *Childs Nerv Syst* 2003; 19: 96–103

## Branchial cleft cyst/sinus

### Major points

- Cysts or sinus tracts on the lateral aspect of the neck which are deep to sternocleidomastoid muscle (Figure 2.22)
- May be unilateral or bilateral
- Usually present at birth or become obvious in early childhood
- Can be apparent on the cutaneous surface or drain into the pharynx
- Most cases are sporadic, but familial cases have been reported



**Figure 2.22** Branchial cleft with skin tag

### Pathogenesis

- Branchial cysts are epithelial cysts arising from incomplete closure of the branchial clefts in embryologic development, most commonly the second or third branchial clefts
- Branchial sinuses are remnants of branchial clefts with depressions

### Diagnosis

- Histology: cyst lined by stratified squamous epithelium and ciliated columnar epithelium on deeper portions; wall of cyst can be surrounded by heavy lymphoid infiltrate

### Differential diagnosis

See Table 17.2

### Treatment

- Preoperative imaging to assess for a fistulous connection to the posterior pharynx
- Surgical excision

### Prognosis

- If untreated, cyst may have persistent mucoid discharge or become infected

### References

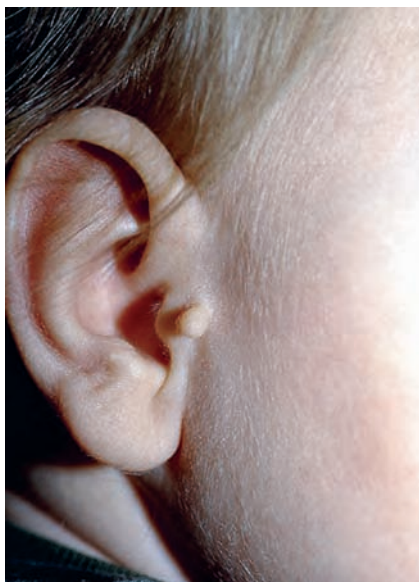- Eastlack JB, Howard RM, Frieden IJ. Congenital midline cervical cleft: case report and review of the English language literature. *Pediatr Dermatol* 2000; 17: 118–22
- Glosser JW, Pires CA, Feinberg SE. Branchial cleft or cervical lymphoepithelial cysts: etiology and management. *J Am Dent Assoc* 2003; 134: 81–6
- Mukherji SK, Fatterpekar G, Castillo M, et al. Imaging of congenital anomalies of the branchial apparatus. *Neuroimag Clin North Am* 2000; 10: 75–93, viii
- Vaughan TK, Sperling LC. Diagnosis and surgical treatment of congenital cartilaginous rests of the neck. *Arch Dermatol* 1991; 127: 1309–10

## Preauricular cyst/sinus

Synonyms: ear pits, congenital auricular fistula

### Major points

- An epithelial cyst, sinus, or swelling in preauricular region
- Common, occurs in 1% of the population
- Autosomal dominant or sporadic



**Figure 2.23** Accessory tragus

- Most cases are bilateral and asymptomatic
- May become infected and drain purulent material
- Associated defects include deafness and renal abnormalities

#### *Pathogenesis*

- Due to incomplete fusion of the first two branchial arches with epithelial entrapment

#### *Diagnosis*

- Imaging, preferably CT, defines the lesion
- Histology: cysts and sinus tracts are lined by stratified squamous epithelium

#### *Differential diagnosis*

- Epidermal cyst
- See Table 17.2

#### *Treatment*

- Most lesions are asymptomatic and do not require treatment
- Secondarily infected cysts can be treated with antibiotics
- Excision is indicated if there is chronic inflammation, drainage or infection

#### *Prognosis*

- Lesion persists throughout life

#### *References*

- Leung AK, Robson WL. Association of preauricular sinuses and renal anomalies. *Urology* 1992; 40: 259–61
- Marres HA, Cremers CW. Congenital conductive or mixed deafness, preauricular sinus, external ear anomaly, and commissural lip pits: an autosomal dominant inherited syndrome. *Ann Otol Rhinol Laryngol* 1991; 100: 928–32
- Moreland RF, Elston DM. Photo quiz. Preauricular pit. *Cutis* 2001; 68: 324, 353–4
- O'Mara W, Guarisco L. Management of the preauricular sinus. *J LA State Med Soc* 1999; 151: 447–50

### **Accessory tragus**

#### *Major points*

- Presents with round, pedunculated, skin-colored papule, occurring anywhere along the line from the tragus to the lateral commissure of the mouth (Figure 2.23)
- Can be unilateral or bilateral; single or multiple
- Familial cases have been reported

#### *Pathogenesis*

- Anomalous migration of the dorsal portion of the first branchial arch

#### *Diagnosis*

- Clinical findings
- Histology: polypoid lesion with numerous hair follicles, small sebaceous glands and often cartilaginous core; eccrine glands, nerve fibers and Pacinian corpuscles may also be present

#### *Differential diagnosis*

- Skin tag
- Preauricular cyst/sinus
- Goldenhar syndrome (oculoauriculovertebral syndrome)

#### *Treatment*

- Surgical excision

#### *Prognosis*

- Usually asymptomatic, may need surgery

#### *References*

- Ban M, Kamiya H, Yamada T, Kitajima Y. Hair follicle nevi and accessory tragi: variable quantity of adipose tissue in

connective tissue framework. *Pediatr Dermatol* 1997; 14: 433–6

Jansen T, Romiti R, Altmeyer P. Accessory tragus: report of two cases and review of the literature. *Pediatr Dermatol* 2000; 17: 391–4

Resnick KI, Soltani K, Berstein JE, Fathizadeh A. Accessory tragus and associated syndromes involving the first branchial arch. *J Dermatol Surg Oncol* 1981; 7: 39–41

Tadini G, Cambiaghi S, Scarabelli G, et al. Familial occurrence of isolated accessory tragi. *Pediatr Dermatol* 1993; 10: 26





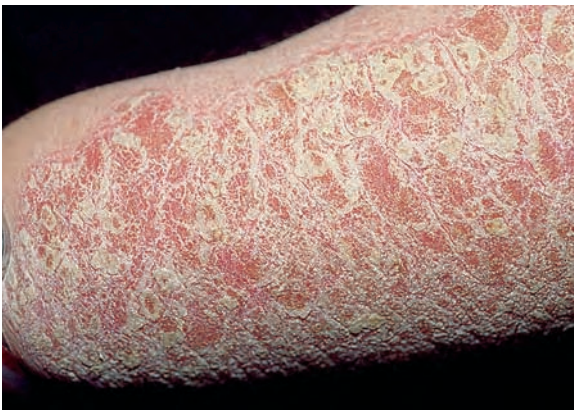## PAPULAR AND PAPULOSQUAMOUS DISORDERS

---

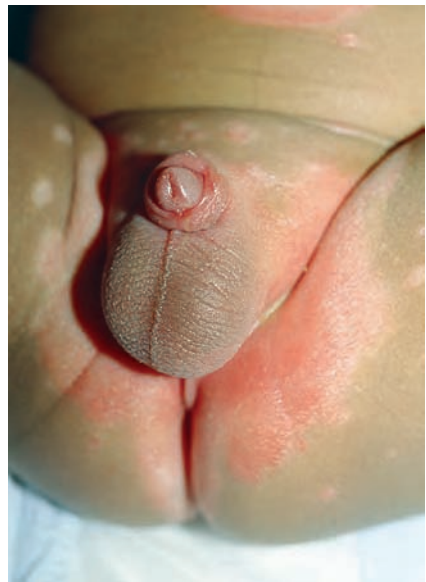### Psoriasis

#### *Major points*

- Affects approximately 1–3% of the population
  - <1% of all cases develop in infancy with reports of congenital presentation; 37% develop lesions prior to 20 years of age; peak age of onset is 15–25 years
  - Variable course triggered or exacerbated by drugs (e.g. antimalarials, withdrawal of steroids), trauma (e.g. surgery, physical, sunburn) or infections (e.g. streptococcal, HIV)
  - Classic lesions are well-circumscribed erythematous plaques with overlying silvery scale that produces pinpoint bleeding when removed (Auspitz sign) (Figure 3.1)
  - Koebner or isomorphic phenomenon can develop in sites of trauma, often producing linear lesions
- Infantile psoriasis
    1. Most common in the diaper area; sharply demarcated and involves skin folds (Figure 3.2)
    2. Can also affect face, scalp, palms and soles
    3. Periumbilical involvement common
    4. Can progress quickly to erythroderma
  - Guttate psoriasis
    1. Common presentation in children and adolescents
    2. Abrupt development of numerous small plaques on the trunk and proximal extremities; can have follicular accentuation (Figure 3.3)

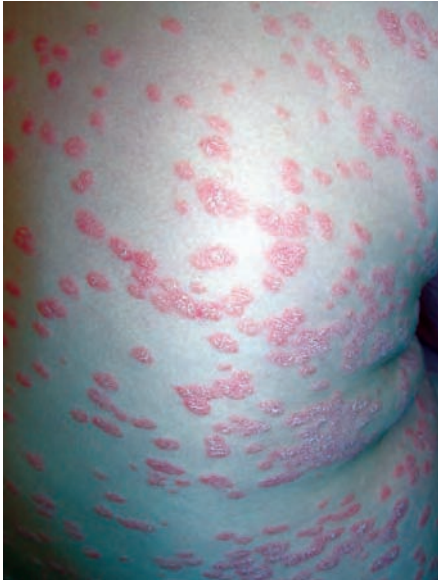

**Figure 3.1** Psoriasis – classic erythematous plaque with silvery scale



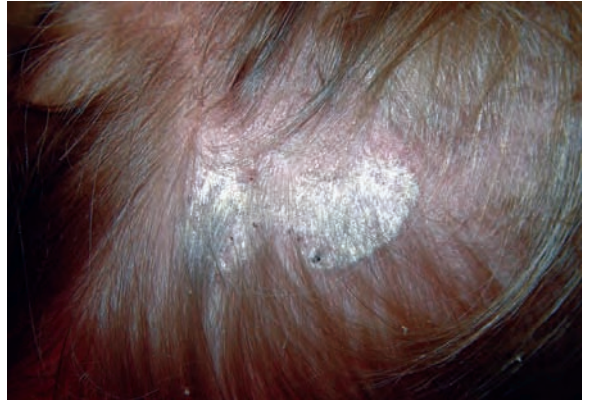**Figure 3.2** Psoriasis – diaper area involved with mild scaling and erythematous plaques



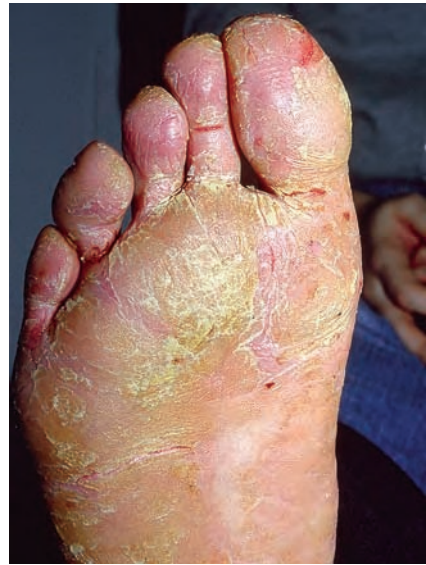

**Figure 3.3** Guttate psoriasis – numerous drop-like erythematous scaly papules

- 3. Can be initial presentation of psoriasis vulgaris; increased likelihood of developing typical psoriasis within 5 years
- Plaque psoriasis (psoriasis vulgaris)
  1. Typical silvery-scaled pink plaques; children often have finer scale than adults; may be pruritic
  2. Plaque-type variants: annular, figurate, follicular, linear
  3. Scalp involvement (common): frontal hairline and retroauricular crease involvement; can have thick scale surrounding clumps of matted hair (pityriasis amiantacea) (Figure 3.4)
  4. Flexural involvement occurs in 44% of pediatric cases: axillae, umbilicus, gluteal cleft, inguinal creases, perineum, labia and penis
  5. Facial involvement common
- Pustular/erythrodermic psoriasis
  1. Very rare in the pediatric age group; more common in males <2 years old
  2. Localized variants:
    - a. Palmoplantar pustulosis: pustules on palms and soles turn to brown macules, then desquamate (Figure 3.5)
    - b. Digital acropustulosis (acrodermatitis continua of Hallopeau): swelling of the nail folds with glazed erythema, pustules and



**Figure 3.4** Scalp psoriasis – thick, scaly plaques without significant hair loss

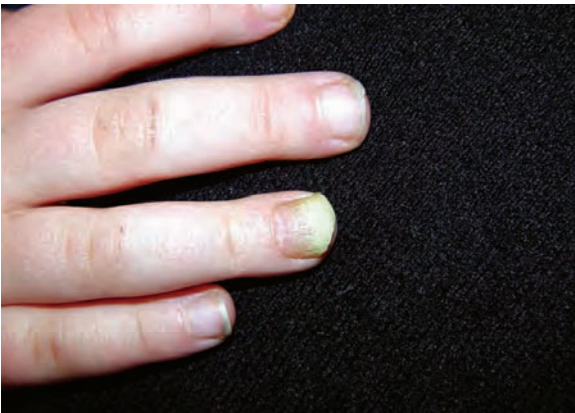

**Figure 3.5** Psoriasis of the palms and soles with marked thickening and fissuring

desquamation of the fingertips with nail dystrophy

3. Generalized variants:
  - a. Acute generalized pustular psoriasis (von Zumbusch): diffuse erythroderma with overlying pustules and lakes of pus which later form sheets of desquamation; often accompanied by fever and constitutional symptoms
  - b. Annular pustular psoriasis: erythematous, annular plaques with pustules and desquamation at the periphery

- c. Generalized pustular variant has been associated with lytic bone lesions and capillary leak syndrome/acute respiratory distress syndrome
- 4. Associated findings: alopecia, geographic tongue, nail dystrophy, arthritis, lytic bone lesions, osteomyelitis, renal failure and jaundice
- Nail psoriasis (Chapter 19)
  1. Occurs in 15–79% of children with cutaneous signs of psoriasis
  2. Rarely the initial presentation of childhood psoriasis
  3. Pitting of the nail plate is most common; rarely can involve all 20 nails (Figure 3.6)
  4. Other findings: discoloration, onycholysis, distal subungual debris and oil spotting
  5. Periungual psoriasis can lead to marked nail dystrophy with hyperkeratosis and crumbling of the nail plate
  6. Psoriatic nail changes are seen in 80% of children with psoriatic arthritis



**Figure 3.6** Nail psoriasis with pitting

- a. Oligoarthritis of the interphalangeal joints is the most common presentation in childhood
  - b. Asymmetric distal interphalangeal joint involvement
  - c. Arthritis mutilans with sacroileitis
  - d. Symmetric arthritis
  - e. Ankylosing spondylitis
  - 4. Can have associated eye inflammation (e.g. conjunctivitis, uveitis, episcleritis)
- Pathogenesis**
- Etiology not known; probably complex interactions of the vasculature, immune system and epidermis
  - Genetic susceptibility
    1. HLA Cw6, B57, DR7 with early-onset type
    2. HLA B27 with pustular variant
    3. HLA B13 or B17 with guttate and erythrodermic type
    4. HLA B8, Bw35, Cw7, DR3 with palmoplantar psoriasis
    5. Increased risk if first-degree relative affected; increased in monozygotic twins
  - Immune system activation
    1. Antigen presentation by Langerhans cells leading to T-cell activation
    2. Role of activated CD4+ T-helper cells in initiation
    3. Role of activated CD8+ T-helper cells in establishment and maintenance
    4. Th1 cytokine profile: interferon- $\gamma$ , interleukin-2, tumor necrosis factor (TNF)- $\alpha$
    5. Neutrophil accumulation
    6. Lesional increase in antimicrobial peptides ( $\beta$ -defensins)
    7. Often precipitated by a pharyngeal or perianal streptococcal infection; caused by superantigen stimulation of T lymphocytes
  - Keratinocyte proliferation
    1. May be T-cell activated, cytokine-mediated or a primary defect of keratinocyte proliferation
    2. Reduced keratinocyte cell-cycle time
    3. Reduced apoptosis: increased Bcl-2
    4. Leads to hyperproliferation and keratinocyte hyperplasia: increased keratins 6, 16 and 17 plus reduced keratins 1, 2 and 10
- Diagnosis**
- Clinical diagnosis
  - Histology: regular epidermal hyperplasia, parakeratosis, intracorneal neutrophils (Munro

microabscesses), diminished granular layer, keratinocyte mitoses, intraepidermal neutrophils (spongiform pustules of Kugoj), thinned suprapapillary plate, dilated vessels in the dermal papillae, perivascular lymphocytic infiltrate, mild erythrocyte extravasation

### Treatment

- Avoid triggering factors
- Topical treatments
  1. Liberal emollients
  2. Topical corticosteroids (moderate to ultrapotent)
  3. Calcipotriene
  4. Exfoliants
  5. Anthralin
  6. Coal tar preparations
  7. Topical retinoids
  8. Topical immunomodulators: tacrolimus, pimecrolimus
- Phototherapy
  1. Ultraviolet B (UVB)
  2. Oral psoralen and ultraviolet A (PUVA, not recommended for those <11 years of age) or topical PUVA
- Systemic therapy for severe disease: methotrexate, cyclosporine, oral retinoids, immunomodulators (anti-TNF agents)

### Differential diagnosis

- Eczema
- Seborrheic dermatitis
- Pityriasis rosea
- Drug eruption
- Tinea
- Secondary syphilis
- Candidiasis
- Acute generalized pustular dermatosis
- Staphylococcal scalded skin syndrome

### Prognosis

- Chronic skin condition with intermittent exacerbations and remissions
- Typically partially responsive to topical therapy alone
- Unpredictable; may spontaneously resolve or persist into adulthood
- Systemically treated psoriasis can lead to side-effects associated with the medications

### References

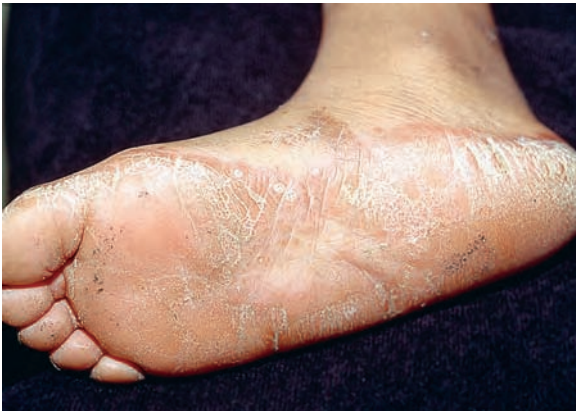- Cassandra M, Conte E, Cortez B. Childhood pustular psoriasis elicited by the streptococcal antigen: a case report and review of the literature. *Pediatr Dermatol* 2003; 20: 506–10
- Leman J, Burden D. Psoriasis in children: a guide to its diagnosis and management. *Paediatr Drugs* 2001; 3: 673–80
- Liao PB, Robinson R, Howard R, et al. Annular pustular psoriasis – most common form of pustular psoriasis in children: report of three cases and review of the literature. *Pediatr Dermatol* 2002; 19: 19–25
- Morris A, Rogers M, Fischer G, Williams K. Childhood psoriasis: a clinical review of 1262 cases. *Pediatr Dermatol* 2001; 18: 188–98
- Rogers M. Childhood psoriasis. *Curr Opin Pediatr* 2002; 14: 404–9

### Pityriasis rubra pilaris

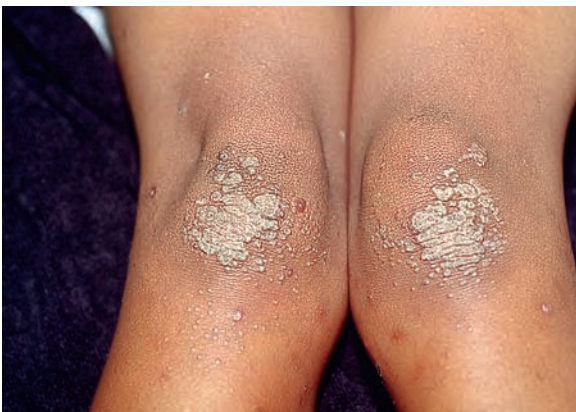#### Major points

- Chronic skin disorder with variable clinical spectrum
- Most cases are sporadic; familial cases with autosomal dominant pattern
- Characterized by salmon-orange plaques with classic ‘islands of sparing’ and perifollicular ‘nutmeg grater’ papules with palmoplantar keratoderma
- Clinically defined classification
  1. Type I: Classic type, adult onset
  2. Type II: Atypical type, adult onset
  3. Type III: Classic type, juvenile onset
    - a. Accounts for 10% of all reported cases
    - b. Usually develops within first decade
    - c. Typically begins on scalp, face and neck with palmoplantar keratoderma followed by development of characteristic coalescent plaques on trunk and extremities (Figure 3.7)
    - d. Facial skin taut with ectropion
    - e. Nails thickened and dystrophic
  4. Type IV: Localized or circumscribed juvenile onset
    - a. Accounts for 25% of all reported cases; 60% of all childhood cases
    - b. Typically prepubertal children
    - c. Presents with hyperkeratotic follicular papules coalescent to plaques over the elbows and knees (Figure 3.8)
    - d. May have palmoplantar keratoderma

5. Type V: Atypical type, juvenile onset
  - a. Accounts for 5% of all cases
  - b. Typically develops in the first 2 years of life; may be seen at birth; often familial
  - c. Presents with widespread erythema and folliculocentric papules
  - d. Variable palmoplantar keratoderma
  - e. May have associated arthropathy
- May be associated with underlying HIV



**Figure 3.7** Pityriasis rubra pilaris – palmar keratoderma with typical yellow, waxy appearance



**Figure 3.8** Pityriasis rubra pilaris – juvenile type with keratotic plaques on the knees

### Pathogenesis

- Unknown etiology
- Increased epidermal cell proliferation
- Reduced levels of retinol-binding protein that is a specific carrier of vitamin A

### Diagnosis

- Characteristic clinical findings
- Histology: alternating ortho- and parakeratosis in a 'geometric' pattern, superficial follicular plugging, acanthosis, hypergranulosis, variable spongiosis, perinuclear vacuolation and mild superficial lymphohistiocytic infiltrate

### Differential diagnosis

- Psoriasis
- Atopic dermatitis
- Lichen planus
- Lichen nitidus
- Viral exanthem
- Kawasaki disease
- Nonbullous congenital ichthyosiform erythroderma

### Treatment

- Treatment is often difficult
- Topical treatments
  1. Emollients
  2. Exfoliants
  3. Topical corticosteroids
  4. Calcipotriene
- Systemic therapy
  1. Systemic retinoids
  2. Methotrexate
  3. Cyclosporine

### Prognosis

- Type III and IV disease may resolve spontaneously within 3 years of onset
- Type V persists throughout life

### References

- Albert MR, Mackool BT. Pityriasis rubra pilaris. *Int J Dermatol* 1999; 38: 1–11
- Allison DS, El-Azhary RA, Calobrisi SD, Dicken CH. Pityriasis rubra pilaris in children. *J Am Acad Dermatol* 2002; 47: 386–9
- Griffith WA. Pityriasis rubra pilaris. *J Am Acad Dermatol* 1984; 10: 1086–8
- Menni S, Brancalone W, Grimalt R. Pityriasis rubra pilaris in a child seropositive for the human immunodeficiency virus. *J Am Acad Dermatol* 1992; 27: 1009
- Terasaki K, Kanekura T, Saruwatari H, Kanzaki T. Classical juvenile pityriasis rubra pilaris in a patient with Down syndrome. *Clin Exp Dermatol* 2004; 29: 49–51



## Pityriasis rosea

### Major points

- Acute, transient papulosquamous disorder of unknown etiology
- Peak incidence: 20–24 years old; 45% of cases in patients <19 years old, 4% <4 years old; rare reports in patients <2 years old
- Preceding viral prodrome in some cases
- Presents with ‘herald patch’ as the initial lesion: oval pink macule which becomes an annular plaque developing a collarette of scale (Figures 3.9 and 3.10)
- Similar lesions then develop on the trunk and proximal extremities over 1–3 weeks
- May be pruritic
- Lesions oriented parallel to skin lines and show a ‘school of minnows’ pattern in the flank area and a ‘Christmas-tree’ pattern on the back
- May have oral lesions
- Variant lesion types: vesicular, pustular, purpuric and erythema multiforme-like
- Variant patterns: inverse, atypical (inverse with acrofacial lesions) and localized

### Pathogenesis

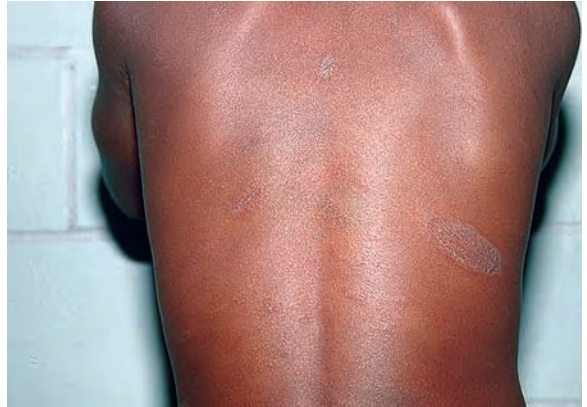- Unknown etiology
- Epidemiologic data support a viral etiology, possibly human herpes virus-6 (HHV-6) and -7 (HHV-7), cytomegalovirus (CMV), Epstein–Barr virus (EBV) or parvovirus B19 virus

### Diagnosis

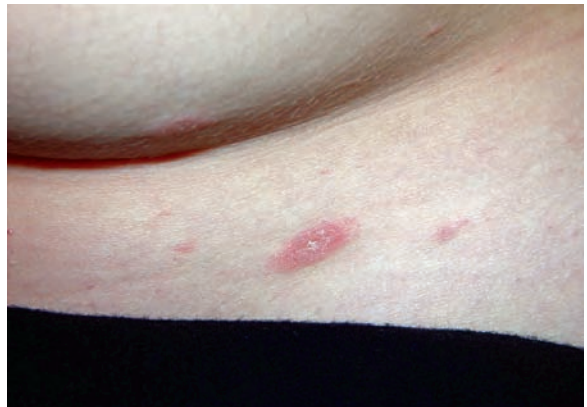- Clinical findings
- Histopathology: mounding parakeratosis, focal spongiosis, exocytosis of lymphocytes, dyskeratosis, papillary dermal edema, upper dermal erythrocyte extravasation, lymphocytic infiltrate in upper dermis

### Treatment

- None usually required
- Symptomatic therapy
  1. Topical steroids
  2. Erythromycin
  3. UVB phototherapy
  4. Oral steroids (short course)



**Figure 3.9** Pityriasis rosea – herald patch with typical ‘fir tree’ distribution of secondary lesions



**Figure 3.10** Pityriasis rosea – typical oval lesion with trailing collarette of scale

### Differential diagnosis

- Tinea
- Secondary syphilis
- Psoriasis
- Nummular eczema
- Drug eruption
- Graft-versus-host disease

### Prognosis

- Self-limited
- Resolves with or without therapy over 4–12 weeks
- May result in postinflammatory hypo- or hyperpigmentation

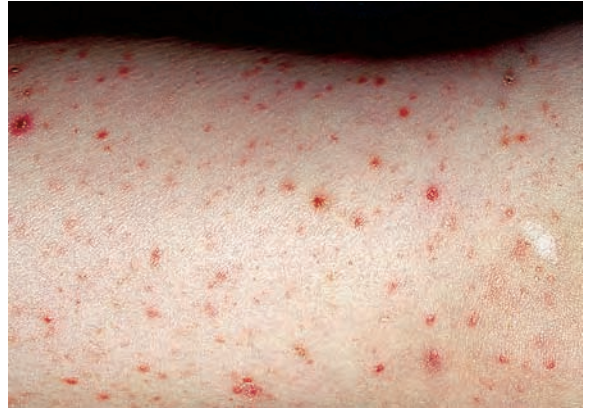## References

- Chuh AA. The association of pityriasis rosea with cytomegalovirus, Epstein–Barr virus and parvovirus B19 infections – a prospective case control study by polymerase chain reaction and serology. *Eur J Dermatol* 2003; 13: 25–8
- Imamura S, Ozaki M, Oguchi M, et al. Atypical pityriasis rosea. *Dermatologica* 1985; 171: 474–7
- Sharma PK, Yadav TP, Gautam RM, et al. Erythromycin in pityriasis rosea: a double-blind, placebo-controlled clinical trial. *J Am Acad Dermatol* 2000; 42: 241–4
- Watanabe T, Kawamura T, Jacob SE, et al. Pityriasis rosea is associated with systemic active infection with both human herpesvirus-7 and human herpesvirus-6. *J Invest Dermatol* 2002; 119: 793–7

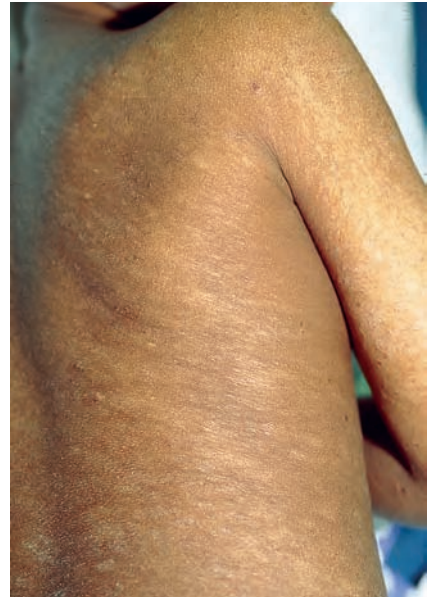## Pityriasis lichenoides

### Major points

- Disease entity encompasses pityriasis lichenoides et varioliformis acuta (PLEVA) and pityriasis lichenoides chronica (PLC), which are thought to be on a clinicopathological spectrum
- Variable clinical presentation
- Typically occurs in children and young adults
- Pityriasis lichenoides et varioliformis acuta (PLEVA) (synonym: Mucha–Habermann disease)
  1. Polymorphous eruption of diffuse reddish-brown macules, papules and varicella-like vesicles with abrupt onset (Figure 3.11)
  2. Lesions progress with ulceration, crusting, central petechiae and necrosis
  3. Usually involves the trunk and flexural surfaces of proximal extremities
  4. Crops of new lesions develop over weeks to months
  5. Can resolve with hyper- or hypopigmentation, and depressed scars
  6. May be accompanied by fever, malaise, lymphadenopathy and arthritis
  7. Papulonecrotic variant: rare, severe form; associated with high fever and constitutional symptoms; acute onset of large nodules with hemorrhagic necrosis and ulceration; may be fatal
- Pityriasis lichenoides chronica (PLC)
  1. Can arise *de novo* or may evolve from PLEVA
  2. Lesions are pink–brown macules and papules with thin centrally adherent scales (Figure 3.12)



**Figure 3.11** Pityriasis lichenoides et varioliformis acuta with generalized erythematous and necrotic papules



**Figure 3.12** Pityriasis lichenoides chronica with hypopigmentation and scaling

3. Resolves with postinflammatory hypo- or hyperpigmentation
4. Indolent and persistent course

### Pathogenesis

- Unknown etiology
- Hypotheses include:
  1. Response to foreign antigens: infectious agents and drugs
  2. Cutaneous T-cell lymphoproliferative disorder

## Diagnosis

- Clinical findings
- Histology: lymphocytic vasculitis with lichenoid reaction pattern
  1. PLEVA: parakeratosis, variable erosion/ulceration, spongiosis, basal vacuolar change, exocytosis of lymphocytes and erythrocytes, epidermal necrosis, papillary dermal edema, dense perivascular wedge-shaped papillary dermal infiltrate of lymphocytes (mostly CD8+), endothelial swelling, extravasated erythrocytes
  2. PLC: Confluent parakeratosis, mild spongiosis, focal necrotic keratinocytes, mild lymphocytic (mostly CD4+) interface and perivascular inflammation, limited erythrocyte extravasation
- Recommend biopsy of persistent or clinically atypical lesions to rule out progression to malignancy (rare)

## Differential diagnosis

- Pityriasis rosea
- Psoriasis
- Secondary syphilis
- Lichen planus
- Arthropod reaction
- Lymphomatoid papulosis
- Drug eruption
- Varicella
- Vasculitis
- Erythema multiforme

## Treatment

- Topical treatments
  1. Topical low or mid-strength corticosteroids
  2. Coal tar preparations
- Phototherapy
  1. Ultraviolet B (UVB)
  2. Psoralen + ultraviolet A (PUVA) - not recommended <11 years old
- Systemic therapies
  1. Oral antihistamines
  2. Oral antibiotics: erythromycin, tetracycline
  3. Methotrexate (low dose)
  4. Systemic corticosteroids

## Prognosis

- Most cases resolve over several months
- 25% of patients will have recurrences with a chronic relapsing course over years

- Rare subset progresses to lymphomatoid papulosis or T-cell lymphoma

## References

- Gelmetti C, Rigoni C, Alessi E, et al. Pityriasis lichenoides in children: a long-term follow-up of eighty-nine cases. *J Am Acad Dermatol* 1990; 23: 473–8
- Ito N, Ohshima A, Hashizume H, et al. Febrile ulceronecrotic Mucha–Habermann's disease managed with methylprednisolone semipulse and subsequent methotrexate therapies. *J Am Acad Dermatol* 2003; 49: 1142–8
- Margo C, Crowson AN, Kovatich A, Burns F. Pityriasis lichenoides: a clonal T-cell lymphoproliferative disorder. *Hum Pathol* 2002; 33: 788–95
- Romani J, Puig L, Fernandez-Figueras MT, de Moragas JM. Pityriasis lichenoides in children: clinicopathologic review of 22 patients. *Pediatr Dermatol* 1998; 15: 11–16

## Lymphomatoid papulosis

### Major points

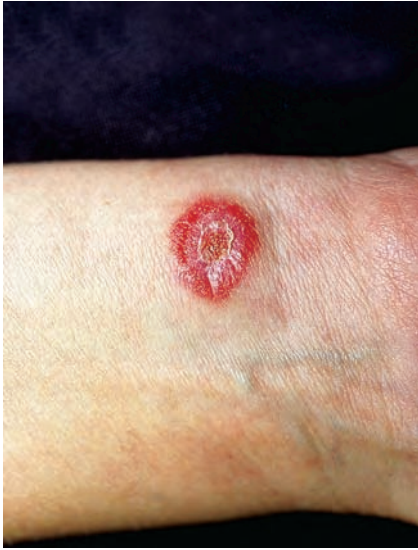- Recurrent self-healing papulonodular eruption with risk of malignant transformation
- Rare in children
- Presents with recurrent crops of red–brown papules and nodules with variable crusting, ulceration and necrosis (Figure 3.13)
- Lesion variants: pustular and vesicular
- Occurs primarily on trunk and proximal extremities
- Lesions involute spontaneously over weeks to months
- May resolve with pigmentary change or scarring

### Pathogenesis

- T-cell lymphoproliferative disorder
- Majority of cells are CD4+; a few cells may be CD30+
- 60% of lesions have clonal T-cell populations

### Diagnosis

- Clinical diagnosis
- Histopathology important in establishing diagnosis
- Three histologic subtypes:
  1. Type A: mixed cellular, wedge-shaped infiltrate with large atypical lymphocytes
  2. Type B: band-like or perivascular inflammation with epidermotropism, lymphocytes with cerebriform nuclei



**Figure 3.13** Lymphomatoid papulosis – 1 cm erythematous nodule on the wrist

3. Type C: single population of large atypical CD 30+ lymphocytes

#### *Differential diagnosis*

- Pityriasis lichenoides
- Arthropod reaction
- Pseudolymphoma
- Anaplastic large cell lymphoma

#### *Treatment*

- Potent topical or intralesional corticosteroids for individual lesions
- Phototherapy: UVB and PUVA (not recommended for <11 years of age)
- Oral antibiotics: erythromycin and tetracycline
- Systemic corticosteroids
- Methotrexate

#### *Prognosis*

- May spontaneously regress
- May persist with recurrences over many years
- 5–20% progress to an associated malignant form: cutaneous T-cell lymphoma anaplastic large cell lymphoma, Hodgkin disease
- Requires careful long-term follow-up

#### *References*

Paulli M, Berti E, Rosso R, et al. CD30/Ki-1-positive lymphoproliferative disorders of the skin clinicopathologic

correlation and statistical analysis of 86 cases: a multicentric study from the European Organization for Research and Treatment of Cancer Cutaneous Lymphoma Project Group. *J Clin Oncol* 1995; 13: 1343–54

Rifkin S, Valderrama E, Lipton JM, Karayalcin G. Lymphomatoid papulosis and Ki-1+ anaplastic large cell lymphoma occurring concurrently in a pediatric patient. *J Pediatr Hematol Oncol* 2001; 23: 321–3

VanNeer FJ, Toonstra J, VanVoorstVader PC, et al. Lymphomatoid papulosis in children: a study of 10 children registered by the Dutch Cutaneous Lymphoma Working Group. *Br J Dermatol* 2001; 144: 351–4

Zackheim HS, Jones C, Leboit PE, et al. Lymphomatoid papulosis associated with mycosis fungoides: a study of 21 patients including analyses for clonality. *J Am Acad Dermatol* 2003; 49: 620–3

Zirbel GM, Gellis SE, Kadin ME, Esterly NB. Lymphomatoid papulosis in children. *J Am Acad Dermatol* 1995; 33: 741–8

## **Cutaneous T-cell lymphoma**

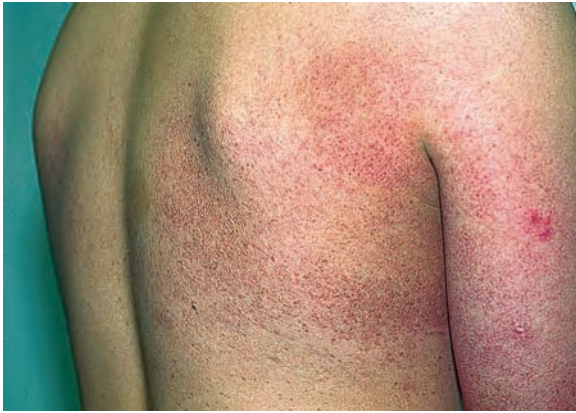Synonym: mycosis fungoides

#### *Major points*

- Cutaneous neoplasm with an indolent progression and late involvement of the lymph nodes, bone marrow and viscera
- Typically a disease of adults but reported with increasing frequency in childhood and adolescence
- Presents with a solitary or a few scaly pink patches and plaques on the lower trunk or buttocks; may have a surrounding hypopigmented halo; can progress with increased infiltration of the plaques and eventual development of pink nodules and tumors that can ulcerate (Figure 3.14)
- Hypopigmented variant (seen in up to 24% of childhood cases) presents with hypopigmented macules and patches on the trunk and extremities
- Can present with concurrent lymphomatoid papulosis, which is more common in childhood and seen in up to 18% of cases
- Variable progression through the clinical stages: patch, plaque, tumor
- Sezary syndrome (leukemic variant) with erythroderma and lymphadenopathy; rare in children
- TNMB staging: skin (T), lymph nodes (N), viscera (V) and peripheral blood (B)



1. Skin
  - a. T1: <10% body surface area (BSA)
  - b. T2: >10% BSA
  - c. T3: tumors
  - d. T4: erythroderma
2. Lymph nodes
  - a. N0: no involvement
  - b. N1: clinically palpable only
  - c. N2: pathologic involvement only
  - d. N3: both clinical and pathologic involvement



**Figure 3.14** Cutaneous T-cell lymphoma – presenting as poikiloderma in a teenager

3. Viscera
  - a. V0: not involved
  - b. V1: involved
4. Blood
  - a. B0: not involved
  - b. B1: involved
  - c. 'B' does not affect the staging
5. Stages
 

a. Stage IA	T1, N0, M0
b. Stage IB	T2, N0, M0
c. Stage IIA	T1–2, N1, M0
d. Stage IIB	T3, N0–1, M0
e. Stage IIIA	T4, N0, M0
f. Stage IIIB	T4, N1, M0
g. Stage IVA	T1–4, N2–3, M0
h. Stage IVB	T1–4, N0–3, M1

### Pathogenesis

- Malignant neoplasm of T-helper cells with monoclonal proliferation of CD4+ cells most common, can also be CD8+ cell proliferation

- Cause of malignant transformation unknown; HTLV-1, HTLV-5 and HHV-8 have been implicated as possible causes

### Diagnosis

- Clinical findings; diagnosis is often delayed for many years because of nonspecific cutaneous lesions
- Skin biopsy imperative: histology depends on stage of disease
  1. Patch stage
    - a. Sparse infiltrate of lymphocytes tagging along the basal cell layer either in small groups or singly as 'a string of beads'
    - b. Limited epidermotropism (i.e. lymphocytes ascending in the epidermis)
    - c. Rare Pautrier microabscesses (i.e. clusters of closely apposed lymphocytes in the epidermis without spongiosis)
  2. Plaque stage
    - a. More dense infiltration of lymphocytes along the epidermis and within the papillary dermis with aggregation around vessels and adnexae
    - b. Increased numbers of atypical lymphocytes with classic cerebriform nuclei
    - c. Conspicuous epidermotropism
    - d. Increased number of Pautrier microabscesses
  3. Tumor stage
    - a. Deep monomorphic infiltration of atypical lymphocytes throughout the dermis and into the subcutaneous tissue
    - b. Increased number of mitoses
    - c. Epidermotropism and Pautrier microabscesses are rare
- T-cell receptor rearrangements by polymerase chain reaction (PCR)
- Staging work-up should include complete blood count, serum chemistries including renal and liver functions, chest X-ray, lymph node biopsy if palpable lymphadenopathy

### Differential diagnosis

- Eczema
- Psoriasis
- Tinea corporis
- Pityriasis lichenoides
- Lymphomatoid papulosis

### Treatment

- Depends on symptoms, degree of cutaneous involvement, and presence of systemic involvement
- Main treatment goals are symptomatic relief and control of the disease
- Treatment has not been shown to prevent the progression of disease
  1. Topical antipruritics
  2. Potent or ultrapotent topical corticosteroids
  3. Topical retinoids (e.g. Targretin)
  4. PUVA
  5. Topical nitrogen mustard
  6. Oral RXR-receptor retinoids (e.g. Targretin)

### Prognosis

- Typical slow progression from cutaneous to systemic involvement
- 95% disease-specific survival at 5 years
- 93% disease-specific survival at 10 years
- Complete remissions are rare but reported

### References

- Crowley JJ, Nikko A, Varghese A, et al. Mycosis fungoides in young patients: clinical characteristics and outcome. *J Am Acad Dermatol* 1998; 38: 696–701
- Garzon MC. Cutaneous T cell lymphoma in children. *Semin Cutan Med Surg* 1999; 18: 226–32
- Neuhaus IM, Ramos-Caro FA, Hassanein AM. Hypopigmented mycosis fungoides in childhood and adolescence. *Pediatr Dermatol* 2000; 17: 403–6
- Quaglino P, Zaccagna A, Verrone A, et al. Mycosis fungoides in patients under 20 years of age: report of 7 cases, review of the literature and study of the clinical course. *Dermatology* 1999; 199: 8–14
- Wain EM, Orchard GE, Whittaker SJ, et al. Outcome in 34 patients with juvenile-onset mycosis fungoides: a clinical, immunophenotypic, and molecular study. *Cancer* 2003; 98: 2282–90
- Whittam LR, Calonje E, Orchard G, et al. CD8-positive juvenile onset mycosis fungoides: an immunohistochemical and genotypic analysis of six cases. *Br J Dermatol* 2000; 143: 1199–204

## Lichen planus

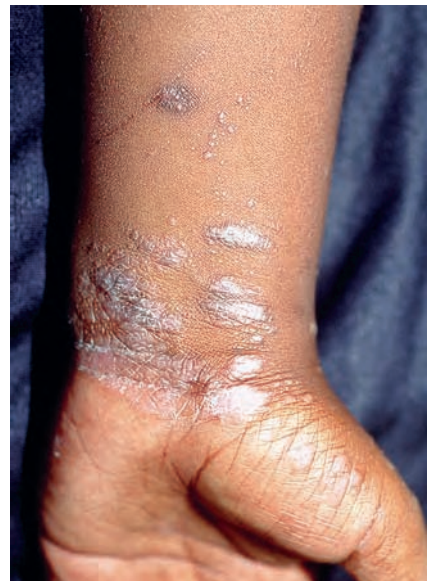### Major points

- 2–3% of all cases occur in children

- Characterized by purple, polygonal, planar, pruritic papules (Figure 3.15)
- May have overlying Wickham striae (superficial white reticulate pattern)
- Commonly occurs on the volar wrists, sacral area and pretibial surfaces
- May display Koebner phenomenon (development at sites of trauma)
- Oral mucosa (uncommon in children): white reticulate pattern on buccal mucosa
- Nail involvement in children is uncommon; may present with trachyonychia or twenty-nail dystrophy
- Clinical variants: linear, hypertrophic, annular, follicular, erosive, bullous and actinic
- Typically resolves with prominent postinflammatory hyperpigmentation

### Pathogenesis

- Unknown etiology
- Possible genetic susceptibility with familial cases reported
- Evidence for a cell-mediated immune response
- Increased prevalence in adults with hepatitis C; may cause presentation of viral antigens to antigen-presenting cells leading to the induction of effector T cells with cytotoxic activity



**Figure 3.15** Lichen planus – violaceous flat-topped papules with white Wickham striae

### Diagnosis

- Clinical diagnosis (usually)
- Histology: hyperkeratosis, wedge-shaped hypergranulosis, variable acanthosis with saw-toothing of the rete ridges, band-like lymphohistiocytic infiltrate at the dermal–epidermal junction, basal layer damage causing Caspary–Joseph spaces, Civatte bodies and colloid bodies, variable melanin incontinence

### Differential diagnosis

- Lichenoid drug eruption
- Lichen nitidus
- Lichen simplex chronicus
- Psoriasis
- Granuloma annulare
- Sarcoidosis

### Treatment

- Mid-strength or potent topical corticosteroids
- Oral antihistamines
- Oral corticosteroids
- Oral retinoids
- Phototherapy: UVB, PUVA (not recommended for <11 years of age)

### Prognosis

- Typically resolves within 1–12 months
- 10–20% will have intermittent recurrences for many years
- Residual pigmentary changes can be disfiguring

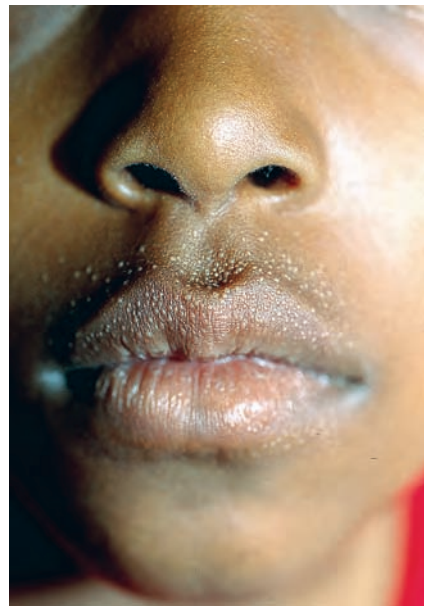
### References

- Alam F, Hamburger J. Oral mucosal lichen planus in children. *Int J Paediatr Dent* 2001; 11: 209–14
- Eisen D. The clinical manifestations and treatment of oral lichen planus. *Dermatol Clin* 2003; 21: 79–89
- Kabbash C, Laude TA, Weinberg JM, Silverberg NB. Lichen planus in the lines of Blaschko. *Pediatr Dermatol* 2002; 19: 541–5
- Nocente R, Ceccanti M, Bertazzoni G, et al. HCV infection and extrahepatic manifestations. *Hepato-Gastroenterology* 2003; 50: 1149–54
- Peluso AM, Tosti A, Piraccini BM, Cameli N. Lichen planus limited to the nails in childhood: case report and literature review. *Pediatr Dermatol* 1993; 10: 36–9
- Sharma R, Maheshwari V. Childhood lichen planus: a report of fifty cases. *Pediatr Dermatol* 1999; 16: 345–8

## Lichen nitidus

### Major points

- Uncommon, benign dermatosis of childhood
- Male/female ratio >1
- Discrete pinpoint, shiny, skin-colored or hypopigmented papules (Figure 3.16)
- Location: trunk and extremities, penis
- Typically asymptomatic but may be pruritic
- May display Koebner phenomenon: linear lesions in areas of trauma



**Figure 3.16** Lichen nitidus – hypopigmented tiny papules

- Rare associated oral and nail involvement
- Rarely lesions can be vesicular, hemorrhagic or purpuric

### Pathogenesis

- Unknown etiology
- Considered a variant of lichen planus

### Diagnosis

- Clinical findings
- Histology: ‘ball and claw’ circumscribed lymphohistiocytic infiltrate within 2–3 dermal papillae; can have thinning of the overlying epidermis; claw-like extension of the rete ridges;

multinucleate giant cells within inflammatory infiltrate

### Differential diagnosis

- Papular eczema
- Molluscum contagiosum
- Planar warts
- Keratosis pilaris
- Eruptive vellus hair cysts
- Lichen planus

### Treatment

- No therapy usually required
- Symptomatic relief with topical corticosteroids and topical/oral antihistamines
- For severe, persistent cases: PUVA (not recommended <11 years), systemic steroids or oral retinoids

### Prognosis

- Variable course
- Spontaneous resolution occurs in 69% of patients within 1 year
- May be persistent and unresponsive to therapy for many years

### References

- Arizaga AT, Gaughan MD, Bang RH. Generalized lichen nitidus. *Clin Exp Dermatol* 2002; 27: 115–17
- Kubota Y, Kiryu H, Nakayama J. Generalized lichen nitidus successfully treated with an antituberculous agent. *Br J Dermatol* 2002; 146: 1081–3
- Lestringant GG, Piletta P, Feldmann R, et al. Coexistence of atopic dermatitis and lichen nitidus in three patients. *Dermatology* 1996; 192: 171–3
- Sanders S, Collier de AH, Scott R, et al. Periappendageal lichen nitidus: report of a case. *J Cutan Pathol* 2002; 29: 125–8
- Soroush V, Gurevitch AW, Peng SK. Generalized lichen nitidus: case report and literature review. *Cutis* 1999; 64: 135–6

## Elastosis perforans serpiginosa

Synonym: perforating elastosis

### Major points

- Male/female ratio >1
- Typically presents at >20 years of age

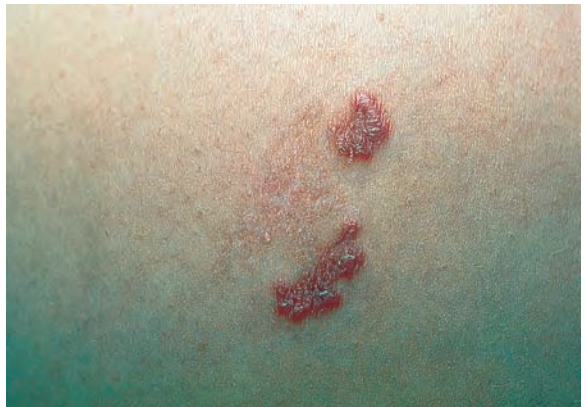- Clinical presentation with asymptomatic, skin-colored to red keratotic papules in a linear, arcuate or serpiginous array; most common on neck but can involve upper extremities, face or trunk (Figure 3.17)
- Can demonstrate Koebner phenomenon
- 25% of cases associated with disorder: Down syndrome, Ehlers–Danlos syndrome, Marfan syndrome, pseudoxanthoma elasticum, osteogenesis imperfecta, cutis laxa, Rothmund–Thomson syndrome, systemic sclerosis, morphea, acrogeria, XYY syndrome and chronic renal disease
- Has been described associated with D-penicillamine therapy
- Familial cases reported with an autosomal dominant inheritance pattern suspected

### Pathogenesis

- Unknown etiology
- Histologic transepidermal elimination of fragmented elastic fibers may be a common pathway for elimination of abnormal elastic fibers; keratinocytes with elastin receptors can be found surrounding eliminated elastic material

### Diagnosis

- Clinical findings, especially in presence of associated disorders
- Histopathology: acanthosis of the epidermis; central channel through the epidermis with an overlying keratinous plug and elimination of fragmented eosinophilic elastic fibers and



**Figure 3.17** Elastosis perforans serpiginosa with typical keratotic, grouped papules



basophilic nuclear debris; papillary dermis contains increased coarse elastic fibers that are easily seen on elastic stains; variable amount of inflammation and foreign body giant cells

### *Differential diagnosis*

- Porokeratosis of Mibelli
- Granuloma annulare
- Tinea corporis
- Sarcoidosis
- Lichen planus
- Cutaneous larva migrans

### *Treatment*

- Typically not required; limited effectiveness
- Keratolytic agents
- Topical retinoids
- Cryotherapy
- Lasers

### *Prognosis*

- Slowly enlarges
- Typically resolves spontaneously over 5–10 years
- With associated disorder, the overall prognosis is based on the specific disease entity

### *References*

- Mehta RK, Burrows NP, Payne CM, et al. Elastosis perforans serpiginosa and associated disorders. *Clin Exp Dermatol* 2001; 26: 521–4
- Outland JD, Brown TS, Callen JP. Tazarotene is an effective therapy for elastosis perforans serpiginosa. *Arch Dermatol* 2002; 138: 169–71
- Saxena M, Tope WD. Response of elastosis perforans serpiginosa to pulsed CO<sub>2</sub>, Er:YAG, and dye lasers. *Dermatol Surg* 2003; 29: 677–8
- Sehgal VN, Jain S, Thappa DM, et al. Perforating dermatoses: a review and report of four cases. *J Dermatol* 1993; 20: 329–40
- Wu JJ, Wagner AM. A case of elastosis perforans serpiginosa. *Cutis* 2002; 69: 423–5

## **Porokeratosis**

### *Major points*

- Clinically variable disease of keratinization
- Classic lesion: papule or plaque with a thin, keratotic, thread-like border, resembling ‘Great Wall of China’ (Figure 3.18)

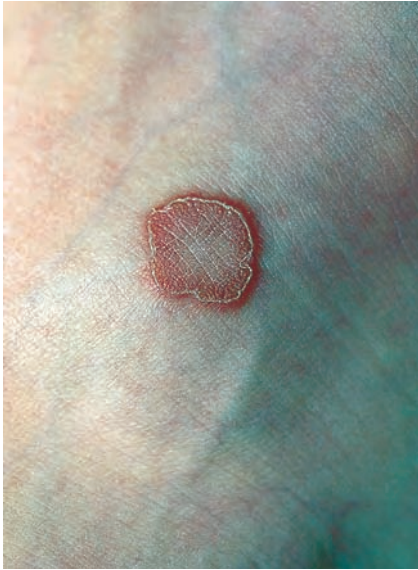- Porokeratosis of Mibelli
  1. Male/female ratio >1
  2. Onset in infancy or adolescence
  3. Presents with solitary, localized annular plaque with a distinctive keratotic border
  4. Typically occurs on the legs
- Linear porokeratosis
  1. Presents in infancy or childhood; can be congenital
  2. Classic porokeratotic plaques distributed in the lines of Blaschko (Figure 3.19)
  3. Most common on an extremity
  4. Can coexist with disseminated superficial actinic porokeratosis
  5. Rare risk of malignant degeneration
- Punctate porokeratosis
  1. Noted during adolescence or adulthood
  2. Characterized by small discrete keratotic papules on the palms and soles in association with linear porokeratosis or porokeratosis of Mibelli
- Porokeratosis palmaris et plantaris disseminata
  1. Occurs during childhood or adolescence
  2. Develops multiple keratotic papules on the palms and soles initially, then spreads diffusely on the trunk and extremities with areas of confluence; male/female ratio >1, autosomal dominant
- Disseminated superficial actinic porokeratosis (DSAP)
  1. Most common type
  2. Develops in mid-adulthood typically
  3. Widespread small keratotic papules on sun-exposed areas, usually lower legs

### *Pathogenesis*

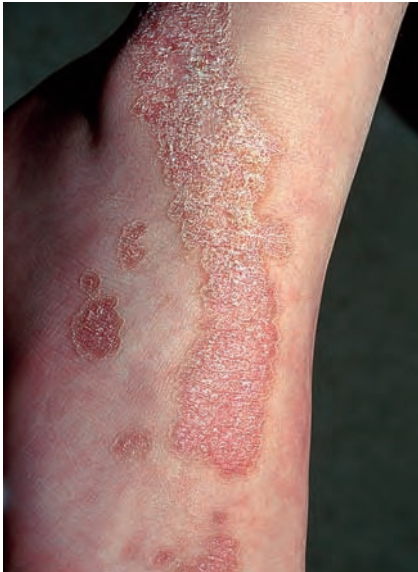- Unknown etiology
- Genetic susceptibility; autosomal dominant in some cases
- Hypothesis: proliferation of aberrant keratinocyte clone
- Overexpression of p53 tumor suppressor protein
- May be due to loss of heterozygosity

### *Diagnosis*

- Clinical findings
- Histology: pathognomonic cornoid lamella (parakeratotic column) overlying a reduced or absent granular layer



**Figure 3.18** Porokeratosis – classic thin-edged scale resembling the ‘Great Wall of China’



**Figure 3.19** Porokeratosis – linear type following Blaschko lines

### Differential diagnosis

- Elastosis perforans serpiginosa
- Tinea corporis
- Lichen striatus
- Lichen sclerosus
- Granuloma annulare

- Morphea
- Punctate keratoderma

### Treatment

- Variable results with topical 5-fluorouracil, surgical excision, cryotherapy, CO<sub>2</sub> laser ablation, dermabrasion, exfoliants, topical and systemic retinoids

### Prognosis

- Chronic and persistent course
- Linear variant has a small risk of malignant degeneration to squamous cell carcinoma in later life

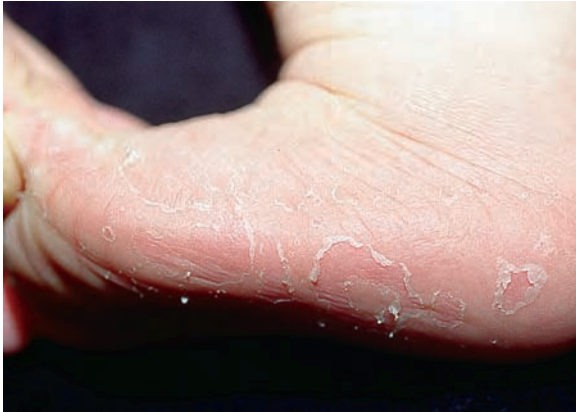### References

- Boente MC, López-Baró AM, Frontini MV, Asial RA. Linear porokeratosis associated with disseminated superficial actinic porokeratosis: a new example of type II segmental involvement. *Pediatr Dermatol* 2003; 20: 514–18
- Fisher CA, LeBoit PE, Frieden IJ. Linear porokeratosis presenting as erosions in the newborn period. *Pediatr Dermatol* 1995; 12: 318–22
- Flanagan N, Boyadjiev SA, Harper J, et al. Familial craniosynostosis, anal anomalies, and porokeratosis: CAP syndrome. *J Med Genet* 1998; 35: 763–6
- Pierson D, Bandel C, Ehrig T, Cockerell C. Benign epidermal tumors and proliferations: porokeratosis. In *Dermatology*. Bologna JL, Jorizzo JL, Rapini RP, et al. eds. Mosby: New York, 2003: 1707–9
- Silver SG, Crawford RI. Fatal squamous cell carcinoma arising from transplant-associated porokeratosis. *J Am Acad Dermatol* 2003; 49: 931–3
- Suh DH, Lee HS, Kim SD, et al. Coexistence of disseminated superficial porokeratosis in childhood with congenital linear porokeratosis. *Pediatr Dermatol* 2000; 17: 466–8

## Keratolysis exfoliativa

### Major points

- Chronic superficial desquamative dermatosis (Figure 3.20)
- Acral variant (synonym: lamellar dyshidrosis)
  1. Presents with recurrent peeling of the palms and soles with circinate or annular exfoliation
  2. No antecedent primary lesions
  3. No associated hyperhidrosis
- Diffuse variant (synonyms: keratolysis exfoliativa congenita, familial continual skin peeling)



**Figure 3.20** Keratolysis exfoliativa – nonerythematous chronic scaling on the feet, not associated with tinea

1. Can be noninflammatory or associated with congenital erythroderma
2. Sporadic, but has been described in families; autosomal recessive inheritance suspected
3. Presents with chronic, superficial peeling over large areas of the body, often sparing the palms and soles
4. Typically begins at birth or early childhood
5. Usually asymptomatic, although may have associated stinging and burning

### *Pathogenesis*

- Unknown etiology

### *Diagnosis*

- Consistent clinical history and examination
- Histopathology reveals hyperkeratosis and epidermal separation at the stratum corneum–granular layer interface

### *Differential diagnosis*

- Juvenile plantar dermatosis
- Dyshidrotic eczema
- Atopic dermatitis
- Tinea
- Sunburn
- Virus-induced exfoliation
- Congenital ichthyosiform erythroderma
- Netherton syndrome

### *Treatment*

- No effective treatment available
- Topical steroids, keratolytics and retinoids tend to be ineffective

### *Prognosis*

- Typically lifelong with spontaneous, continual peeling
- Can worsen during the summer months

### *References*

- Hashimoto K, Hamzavi I, Tanaka K, Shwayder T. Acral peeling skin syndrome. *J Am Acad Dermatol* 2000; 43: 1112–19
- Lee HJ, Ha SJ, Ahn WK, et al. Clinical evaluation of atopic hand-foot dermatitis. *Pediatr Dermatol* 2001; 18: 102–6
- Mevorah B, Orion E, de Viragh P, et al. Peeling skin syndrome with hair changes. *Dermatology* 1998; 197: 373–6
- Tastan HB, Akar A, Gur AR, Deveci S. Peeling skin syndrome. *Int J Dermatol* 1999; 38: 208–10
- Tolat SN, Gharpuray MB. Skin peeling syndrome. *Cutis* 1994; 53: 255–7



# ECZEMATOUS DERMATOSES

## ECZEMATOUS DERMATITIS

### General

- Eczema is a general term, often used interchangeably with dermatitis
- Results from inflammation of superficial dermis and epidermal spongiosis leading to crusting, oozing and sometimes cracking (fissures)

## ATOPIC DERMATITIS

### Major points

- One of the most common skin disorders of childhood
- Inherited disorder, presumably autosomal dominant
- Often associated with either a family or a personal history of other 'allergic' conditions (e.g. asthma or allergic rhinitis)
- The word 'atopy' comes from the Greek word meaning 'without place, unusual.' Described by Coca and Cooke in 1923
- Characteristics
  1. Diagnosis is made clinically by recognizing a combination of features. No single diagnostic criterion exists, but there is a constellation of features (Table 4.1)
  2. Crusty, oozing, eruption with frequent secondary changes from scratching (Figure 4.1)
  3. Pruritus is a hallmark and can be severe, often set off by certain environmental or psychological causes

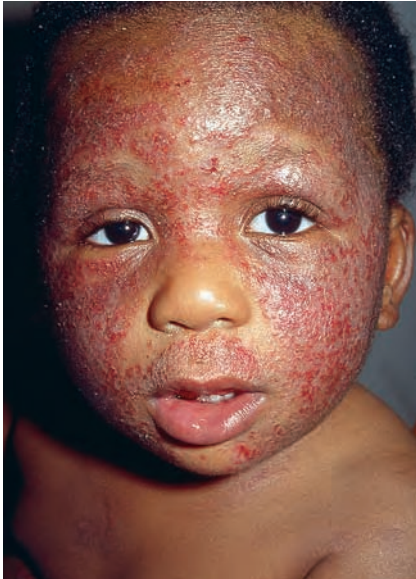**Table 4.1 Criteria for the diagnosis of atopic dermatitis in children**

### Major features

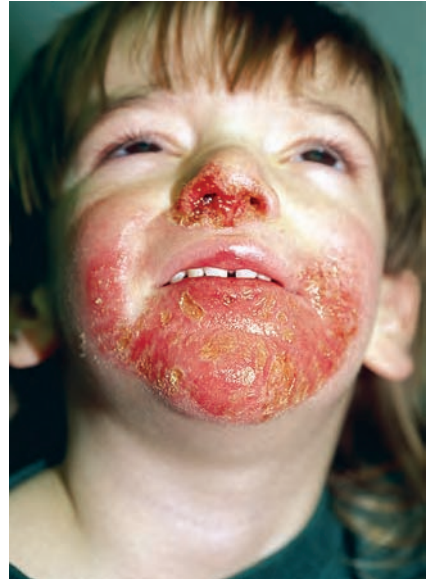1. Pruritus
2. Typical morphology and distribution
  - Facial and extensor involvement during infancy and early childhood
  - Flexural lichenification in childhood or adolescence
3. Chronic or chronically relapsing dermatitis
4. Personal or family history of atopy

### Minor or less specific features

1. Xerosis
2. Periauricular fissures
3. Ichthyosis
4. Hyperlinear palms
5. Keratosis pilaris
6. IgE reactivity (increased serum IgE, RAST, or prick test positivity)
7. Hand or foot dermatitis
8. Cheilitis
9. Scalp dermatitis
10. Susceptibility to cutaneous infections (especially *Staphylococcus aureus* and herpes simplex)
11. Perifollicular accentuation (especially in darkly pigmented races)
12. Dennie's lines (Figure 4.12)
13. Pityriasis alba (Figure 4.13)

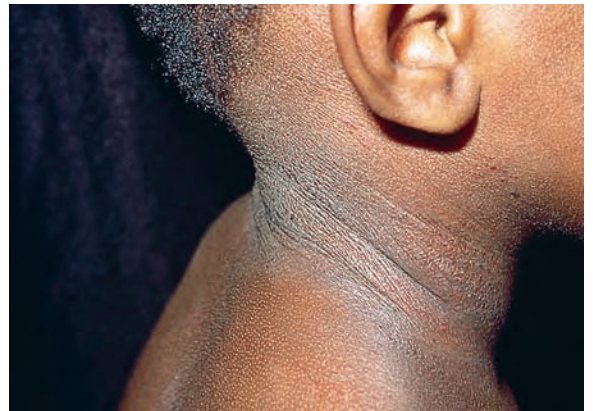

**Figure 4.1** Infantile eczema – typical facial, oozing pruritic plaques



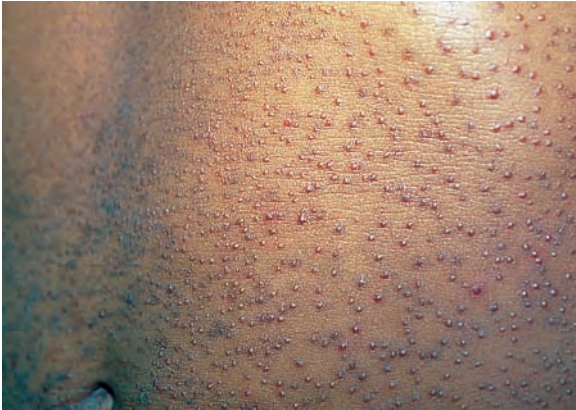**Figure 4.2** Secondly – infected atopic dermatitis with *Staphylococcus aureus*

- a. Itching often intensifies in the evening and disrupts sleep patterns
- b. Threshold for itching is low and often prolonged
4. Distribution often depends on the age of the child (e.g. infants have significant facial involvement, older children have flexural involvement)
5. Lesions can be follicular and papular
6. More susceptible to viral infections (e.g. molluscum contagiosum, warts, herpes simplex) and staphylococcal infections (Figure 4.2)
7. Types of eczema
  - a. Generalized – this can become erythrodermic, and usually denotes more severe involvement
  - b. Infantile eczema (from infants to 2 years) – distribution primarily on cheeks, face, extensor surfaces of arms and legs; tends to spare diaper area
  - c. Childhood eczema (from about 2 years to puberty) – tends to occur on flexural areas (antecubital fossae, popliteal fossae, hands and feet) (Figures 4.3 and 4.4)
  - d. Adult/teenage eczema (puberty through adulthood) – occurs in flexural areas, hands

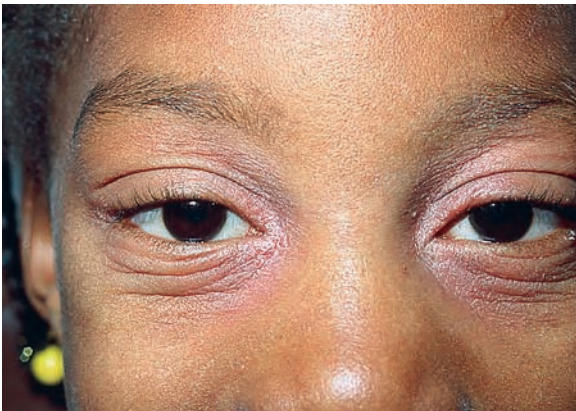

**Figure 4.3** Childhood eczema – lichenified, pruritic plaque on the neck

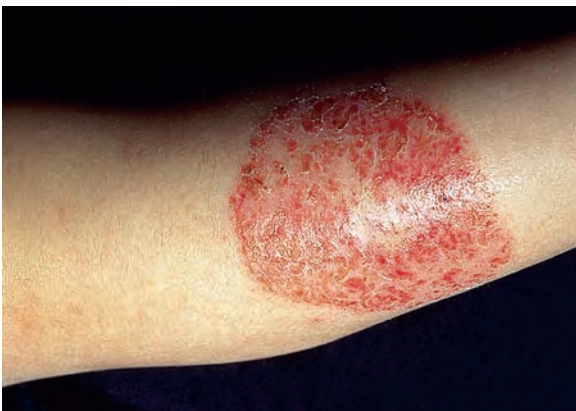- and face, especially eyelids (Figure 4.5)  
Face has typical central pallor
- e. Nummular eczema  
Coin-shaped, oozing plaques with minute papules and vesicles at the periphery (Figure 4.6); generally scattered over the body, but may be mainly localized to one area, such as the legs; plaques usually >1 cm; pruritus common but variable; staphylococcal infections commonly play a role



**Figure 4.4** Follicular eczema – multiple keratotic, pruritic, follicular papules

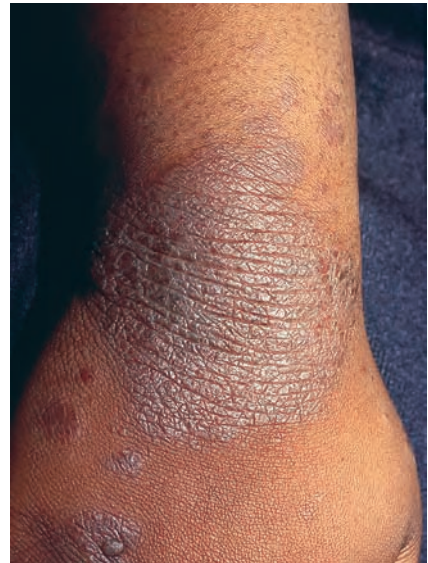


**Figure 4.5** Eyelid eczema with accentuation of skin markings



**Figure 4.6** Nummular eczema – typical round, oozing plaque

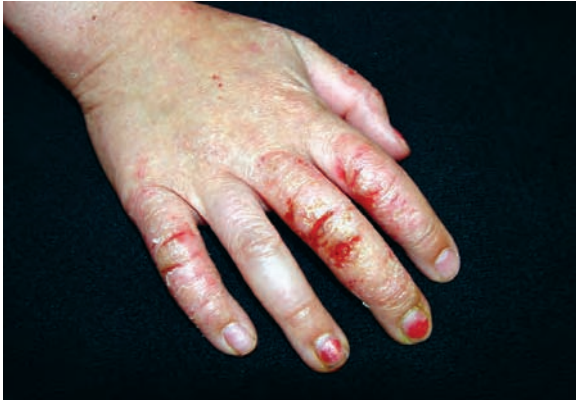- f. Lichen simplex chronicus  
Thickened lichenified plaques with accentuated skin markings caused by chronic scratching (Figure 4.7); nodules are called prurigo nodularis



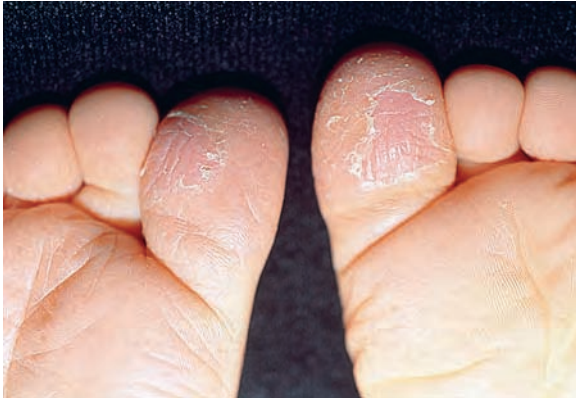**Figure 4.7** Lichen simplex chronicus with typical lichenification

- g. Dyshidrotic eczema  
Bilateral hand and/or foot dermatitis with characteristic tiny vesicles along the sides of fingers or toes with intense itching (Figure 4.8); frequent relapses
- h. Juvenile plantar dermatitis ('sweaty sock syndrome')  
Scaling, cracking, fissuring of both plantar feet, especially the big toe (Figure 4.9); spares toewebs
- i. Frictional lichenoid dermatitis  
Papular eruption of elbows in patients aged ~4–12 years; discrete 1–2 mm lichenoid skin-colored papules (Figure 4.10); pruritus occasional; considered to be secondary to trauma
- j. Autoeczematization ('id' reaction)  
Acute pruritic dermatitis that develops at a site distant from the primary inflammatory focus and is not caused by the primary inciting event; papulovesicular lesions





**Figure 4.8** Dyshidrotic eczema affecting the hands with tiny, pruritic vesicles

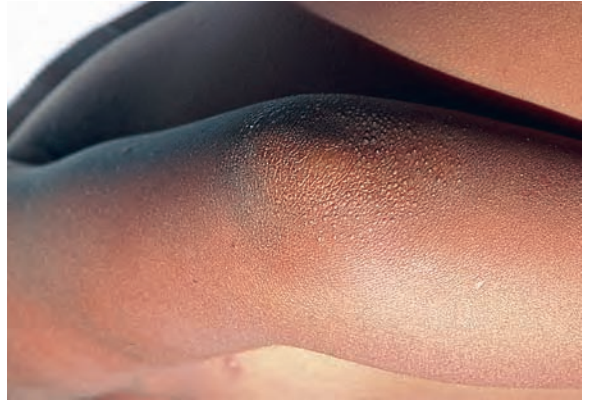

**Figure 4.9** Juvenile plantar dermatosis – shiny, glazed toes with scaling

scattered over the body; can evolve into scaly oozing plaques; infection, wounding, or irritation can precipitate; diagnosis of exclusion; example: papular eruption with tinea capitis

### *Pathogenesis*

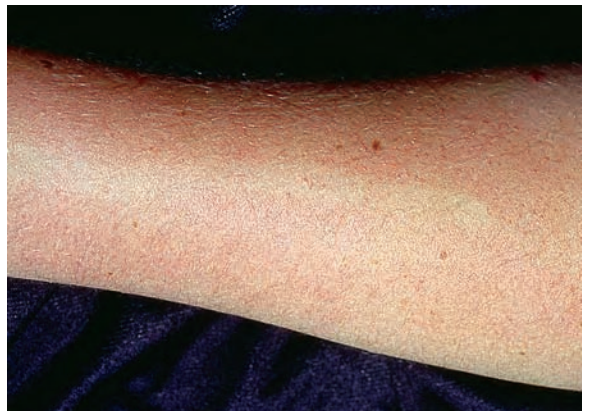- Etiology is multifactorial
- Clinical factors:
  1. Primary lesion is subclinical and may be papular or erythematous
  2. Xerosis (dry skin), which most atopic patients have, is caused by reduced water content of the stratum corneum, with decreased secretion of sebum and sweat
    - a. Dry, ichthyotic skin may result in loss of epidermal barrier and a higher incidence of



**Figure 4.10** Frictional lichenoid dermatitis – lichenoid papules on elbows and knees

irritation from certain stimuli such as wool clothing, soaps, etc

- b. In winter months, in cool climates, or in dry climates, the skin is prone to increased dryness, often causing exacerbations
3. Vasomotor responses
  - a. Unusual reaction patterns such as a tendency to vasoconstriction
  - b. White dermatographism is produced by stroking erythematous or normal-appearing skin in an atopic patient. Instead of the stroked area turning red (normal), it turns white, demonstrating vasoconstriction (Figure 4.11)
  - c. Facial skin, particularly around the nose, may be pale

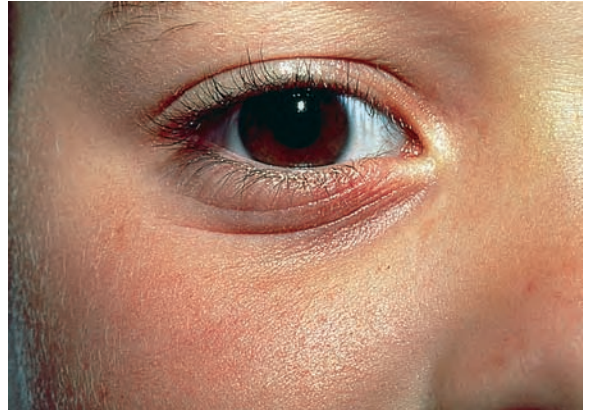

**Figure 4.11** White dermatographism – reactive vasoconstriction after stroking the skin in an atopic patient

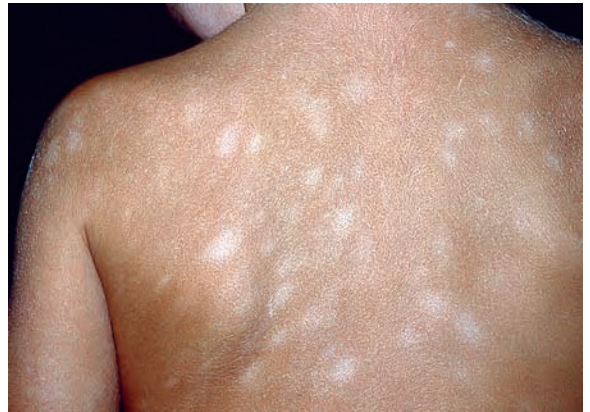- d. Distal extremities may have a lower skin temperature
- 4. Sensitivity
  - a. Patients are more sensitive to irritation by wool, detergents and certain chemicals
  - b. Localization of dermatitis may be a clue to certain irritants (e.g. hand dermatitis in a frequent hand washer)
- 5. Humoral immunity: elevated IgE levels
- 6. Cell-mediated immunity
  - a. Increased susceptibility to viral infections (herpes simplex, vaccinia, molluscum contagiosum)
  - b. Anergy can be demonstrated with increased frequency
  - c. Numbers of T helper (Th) > T suppressor (Ts) cells
  - d. Chemotactic defects of polymorphonuclear leukocytes and monocytes
- Molecular factors
  1. Keratinocytes primed to react to antigenic stimuli by producing preformed interleukin (IL)-1, followed by more IL-1 produced by endothelial cells and macrophages
  2. Secondary cytokines (tumor necrosis factor (TNF)- $\alpha$ , IL-6, IL-8) are then produced
  3. T lymphocytes bind to endothelial cells and migrate into the dermis and epidermis, producing damage to the epidermal barrier
  4. Antigens are presented to stimulated Langerhans cells
  5. Imbalance of Th2 > Th1 lymphocytes
    - a. Th1 cells produce interferon- $\alpha$ , IL-1, IL-2, TNF- $\beta$
    - b. Th2 cells produce IL-4, IL-5, IL-6, IL-10
  6. Cytokines of Th2 cells are self-amplifying and inhibit Th1 responses
  7. T cells in atopic dermatitis are responsive to IL-4, which suppresses IFN- $\gamma$ , with subsequent promotion of B-cell proliferation and increased IgE production
  8. IL-4 stimulates mast cells to release histamine
  9. Vicious cycle caused by repeated stimulation, abnormal responses and cytokine release

### Diagnosis

- Clinical diagnosis (see Table 4.1)
- Laboratory: no specific laboratory criteria
  1. Allergy testing (prick tests)



**Figure 4.12** Dennie's lines – extra skin folds on lower lid



**Figure 4.13** Pityriasis alba – hypopigmented slightly scaly patches

- a. Food allergies in minority of patients
- b. Inhalant allergies in some patients
- 2. Blood tests
  - a. Complete blood count – may see increase in numbers of eosinophils
  - b. Serum IgE may be slightly or markedly elevated
  - c. Radioallergosorbent test (RAST) may help define some allergies
- Histology: variable spongiosis and lymphocytic infiltration of the upper dermis and epidermis; acanthosis, hyperkeratosis; thick-walled blood vessels in papillary dermis

### Differential diagnosis

- Scabies
- Seborrheic dermatitis

- Immunodeficiencies
- Langerhans cell histiocytosis
- Acrodermatitis enteropathica
- Psoriasis
- Contact dermatitis
- Phenylketonuria

### Treatment

- Eliminate precipitating factors
  1. Bathing can be performed once daily, but excessive bathing causes increased dryness
    - a. Apply ointments immediately after patting skin dry
    - b. Oils in bath are messy, and make children slippery to handle; may be useful for older children
    - c. Tepid temperature is best; avoid very hot water; do not make the water too cool, causing the child to shiver
    - d. Soap should be kept to a minimum, and applied only to excessively dirty areas
    - e. Superfatted soaps (e.g. Dove<sup>®</sup>, Tone<sup>®</sup>) or soapless cleansers (e.g. Cetaphil<sup>®</sup>, Aquanil<sup>®</sup>) are best
  2. Excessive sweating, whether heat- or exercise-induced, can cause itching
  3. Temperature extremes (hot and humid, or cold and dry) can increase itching
  4. Avoid coarse or irritating clothing (e.g. wool)
- Emollients are necessary to decrease dryness (which can lead to itching)
- Topical corticosteroids reduce pruritus and inflammation
  1. Hydrocortisone 1% or 2.5% ointment (class 6–7 steroids) for mild inflammation
  2. Mid-strength steroids (class 3–5) (triamcinolone 0.1% ointment) only in isolated areas for young children
  3. High-potency steroids may be indicated for hand or foot dermatitis because of the thickness of the stratum corneum. Be careful to avoid dorsa of hands and feet with high-potency steroids
- Antipruritics
  1. Antihistamines (see Chapter 21)
- Topical tacrolimus 0.03% for children aged 2–15 years BID, or 0.1% for children aged >15 years BID or pimecrolimus 1% for children aged >2 years BID

- Antibiotics
  1. Antistaphylococcal drugs
    - a. Topical agents (e.g. mupirocin) may be helpful for the short term, but some topical antibiotics (e.g. neomycin, bacitracin) can sensitize the skin and cause further allergic contact dermatitis
    - b. Oral antibiotics may be given in short courses to reduce staphylococcal infections of the skin
    - c. Frequent use of antibiotics can lead to resistant bacteria
- Systemic corticosteroids
  1. Short courses for acute, severe exacerbations may be indicated
  2. Long-term oral steroids are not recommended
- Referral to a dermatologist is recommended for severe and moderately severe cases uncontrolled by standard measures
- Hospitalization is indicated only if not controlled by methods at home
- Consider psychological stresses and counseling if unresponsive to treatment
- For severe, recalcitrant cases consider phototherapy (PUVA, UVB), IFN- $\gamma$ , or immunosuppressive drugs (e.g. cyclosporine, methotrexate)

### Prognosis

- Half of the cases of typical atopic dermatitis improve by 2 years of age
- Most improve by teenage years
- Patients tend to have dry, sensitive skin throughout life
- <10% of patients have lifelong problems

### References

- Eichenfield LF, Hanifan JM, Luger TA, et al. Consensus conference on pediatric atopic dermatitis. *J Am Acad Dermatol* 2003; 49: 1088–95
- Eichenfield LF, Lucky AW, Boguniewicz M, et al. Safety and efficacy of pimecrolimus (ASM 981) cream 1% in the treatment of mild and moderate atopic dermatitis in children and adolescents. *J Am Acad Dermatol* 2002; 46: 495–504
- Feingold, S, Huang C, Kristol L, et al. Eczemas. *Curr Probl Dermatol* 1998; 10: 41–92
- Hanifin JM, Cooper KD, Ho VC, et al. Guidelines of care for atopic dermatitis. *J Am Acad Dermatol* 2004; 50: 391–404



Nghiem P, Pearson G, Langley RG. Tacrolimus and pimecrolimus: from clever prokaryotes to inhibiting calcineurin and treating atopic dermatitis. *J Am Acad Dermatol* 2002; 46: 228–41

Ong PY, Ontake T, Brandt C, et al. Endogenous antimicrobial peptides and skin infections in atopic dermatitis. *N Engl J Med* 2002; 347: 1151–60

Patel RR, Vander Straten MR, Korman NJ. The safety and efficacy of tacrolimus therapy in patients younger than 2 years with atopic dermatitis. *Arch Dermatol* 2003; 139: 1184–6

Proceedings of an International Consensus Conference on Atopic Dermatitis. Understanding atopic dermatitis: pathophysiology and etiology. *J Am Acad Dermatol* 2001: S1–S68

Resnick SD, Hornung R, Konrad TR. A comparison of dermatologists and generalists, management of childhood atopic dermatitis. *Arch Dermatol* 1996; 132: 1047–52

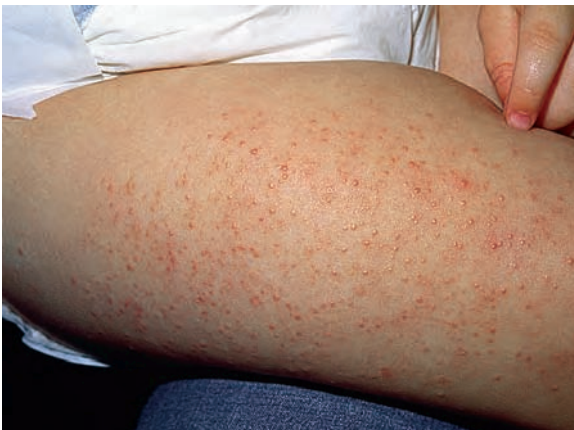Ricci G, Patrizi A, Neri I, et al. Frequency and clinical role of *Staphylococcus aureus* overinfection in atopic dermatitis in children. *Pediatr Dermatol* 2003; 20: 529–30

Rothe MJ, Grant-Kels JM. Atopic dermatitis, an update. *J Am Acad Dermatol* 1996; 35: 1–13

## KERATOSIS PILARIS

### Major points

- Common papular eruption of childhood which tends to continue into adulthood but may improve



**Figure 4.14** Keratosis pilaris – keratotic, follicular, slightly erythematous papules on upper legs

- Prominent follicular plugs over extensor surfaces of extremities, especially upper arms, upper legs, buttocks and cheeks (Figure 4.14)
- Erythema may be seen, especially if the areas have been rubbed or irritated
- Dryness aggravates the condition
- Associated with atopic disorders: atopic dermatitis, hay fever, asthma, allergic rhinitis
- Rarely extensive and generalized
- More common in people of northern European or Celtic ancestry

### Pathogenesis

- Cause unknown
- Considered a disorder of keratinization because a keratinous plug is produced by abnormal follicular epithelium
- May be a response to dryness, and is seen more commonly in cold dry climates

### Diagnosis

- Clinical presentation

### Differential diagnosis

- Acne
- Folliculitis
- Molluscum contagiosum
- Warts
- Milia
- Lichen spinulosus
- Follicular mucinosis

### Treatment

- Lubricants or emollients can improve dry skin, especially if applied after a bath or after wetting of the skin
- Topical keratolytics
  1. Lactic acid preparations such as ammonium lactate 5–12% (e.g. LacHydrin®)
  2. Urea creams (e.g. Carmol-20® OTC)
  3. Topical retinoids (e.g. adapalene cream) may be reserved for severe involvement in a patient who is very compliant, as it can actually aggravate dryness and irritation
- Treatment takes time and should be used twice daily for at least a month, except retinoids (used once daily, at bed time) before results can be expected



- Class 6–7 topical steroids may be indicated for inflammation; do not recommend long-term usage, but only for temporarily decreasing irritation

### Prognosis

- Chronic condition which responds poorly to treatment. Parents should be educated on what to expect
- During adolescence, lesions on the face may improve
- Improvement may occur in more humid environments

### References

Lateef A, Schwartz RA. Keratosis pilaris. *Cutis* 1999; 63: 205–7

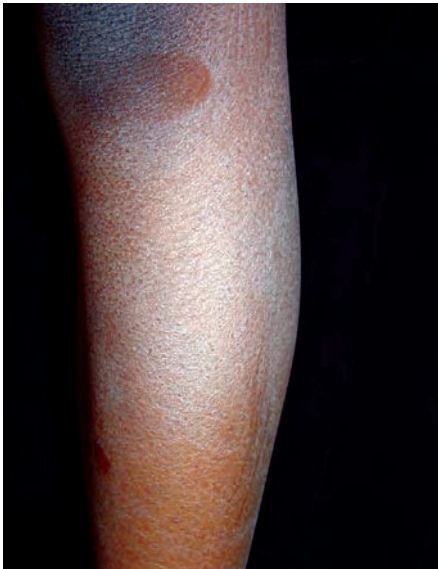Oranje AP, Van Osch LDM, Oosterwijk JC. Keratosis pilaris atrophicans. *Arch Dermatol* 1994; 130: 500–2

## XEROSIS

Synonyms: winter eczema, erythema cracquele, asteatotic eczema

### Major points

- Clinical characteristics
  1. Dryness, scaling (Figure 4.15)



**Figure 4.15** Xerosis – ashy appearance on black skin

2. Cracking
  3. Hands or lower legs most frequently involved
  4. Pruritus if severe
  5. Frequently occurs in winter in cool climates
- Physical examination
    1. Superficial reticular cracks in skin appear like a ‘dried river bed’ (Figure 4.16)
    2. Fissures may be mildly erythematous

### Pathogenesis

- Associated with dryness and dehydration of the epidermis
- Low humidity
- Mainly in atopic individuals

### Diagnosis

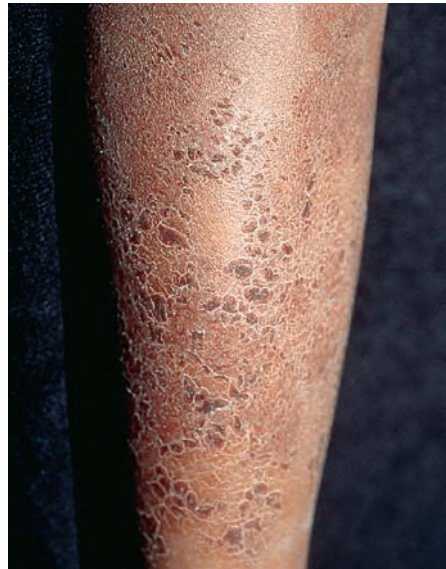- Clinical characteristics

### Differential diagnosis

- Atopic dermatitis
- Contact dermatitis
- Irritant dermatitis
- Ichthyosis vulgaris

### Treatment

- Avoid harsh, drying soaps
- Hydration of the stratum corneum with a daily bath with plain water only



**Figure 4.16** Eczema cracquele – extremely dry skin aggravated by soap and water

- Use mild soaps, superfatted soaps (e.g. Dove, Tone, etc.) or non-soaps (e.g. Cetaphil) only where needed (groin, axillae)
- Increase ambient humidity with humidifier in house or child's room
- Emollients should be liberally used (e.g. petroleum jelly, Eucerin®, Aquaphor®)
- Emollients best applied after bath when skin is moist as well as several times a day
- Unscented moisturizers are best in order to avoid contact sensitivity
- Mild topical corticosteroids (0.5–1% hydrocortisone) in ointment base for erythema only

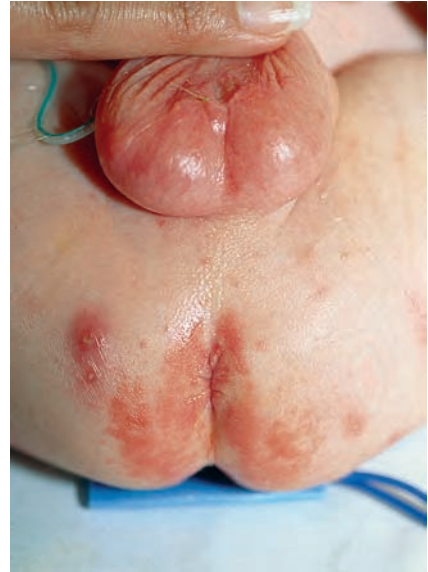### Reference

Hara M, Kikuchi K, Watanabe M, et al. Senile xerosis: functional, morphological, and biochemical studies. *J Geriatr Dermatol* 1993; 3: 111–20

## ECZEMATOUS DERMATITIS WITH IMMUNODEFICIENCIES

### Major points

- Eczematous dermatitis associated with immunodeficiencies looks similar to atopic dermatitis, but is usually more severe and does not respond well to therapy
- Dermatitis can be the first sign of:
  1. Wiskott–Aldrich syndrome
  2. Severe combined immunodeficiency
  3. Hyperimmunoglobulin E syndrome
- Characteristics
  1. Generalized, eczematous dermatitis with scaling, erythema, pruritus
  2. Bacterial infections are common (Figure 4.17)
    - a. Impetigo
    - b. Furuncles
    - c. Otitis media
    - d. Pneumonia
  3. Fungal infections common
    - a. Candidiasis
  4. Diarrhea
  5. Failure to thrive
  6. If a sibling has died after live viral vaccine, this may be a clue
  7. Petechiae – suggests Wiskott–Aldrich syndrome in a male



**Figure 4.17** Eczematous dermatitis in chronic granulomatous disease with abscess formation

### Pathogenesis

See Atopic dermatitis

### Diagnosis

- Laboratory
  1. Wiskott–Aldrich syndrome
    - a. Deficiency of sialoporphin (glycoprotein) on the surface of lymphocytes and platelets
    - b. Low or absent antibodies to blood group antigens A and B
    - c. Increased IgA and IgE
    - d. Decreased IgM
    - e. Splenomegaly
    - f. Hepatomegaly
    - g. Adenopathy
    - h. Thrombocytopenia with petechiae and purpura
    - i. Defects in cell-mediated immunity
    - j. Platelet dysfunction
    - k. X-linked recessive
  2. Hyperimmunoglobulin E syndrome (Job syndrome)
    - a. Marked elevated serum IgE levels (>10 times normal)
    - b. Eosinophilia
    - c. Neutrophil chemotaxis abnormal
    - d. Sinopulmonary infections

- e. Coarse facial features in some patients
- f. Recurrent staphylococcal infections of skin, lungs, joints, etc.
- 3. Severe combined immunodeficiency syndrome
  - a. Decreased levels of IgG, IgM, IgD, IgA, IgE
  - b. Lymphopenia
  - c. Defects in cell-mediated immunity
  - d. Adenosine deaminase deficiency, and others

### Treatment

- Usual treatment for atopic dermatitis with topical steroids, emollients, etc
- Infections should be treated with appropriate antibiotics
- Fresh frozen plasma or whole blood for severe life-threatening illnesses
- Bone marrow transplantation when indicated

### References

- Arbiser JL. Genetic immunodeficiencies: cutaneous manifestations and recent progress. *J Am Acad Dermatol* 1995; 33: 82–9
- Badour K, Zhang J, Siminovitch KA. The Wiskott–Aldrich syndrome protein: forging the link between actin and cell activation. *Immunol Rev* 2003; 192: 98–112
- Berron-Ruiz A, Berron-Perex R, Ruiz-Maldonado R. Cutaneous markers of primary immunodeficiency diseases in children. *Pediatr Dermatol* 2000; 17: 91–6
- Bonilla FA, Geha RS. 12. Primary immunodeficiency diseases. *J Allergy Clin Immunol* 2003; 111(Suppl 2): S571–81
- Buckley RH. The hyper-IgE syndrome. *Clin Rev Allergy Immunol* 2001; 20: 139–54
- Dave S, Thappa DM, Karthikeyan K. Disseminated and disfiguring molluscum contagiosum in a child. *Pediatr Dermatol* 2003; 20: 436–9
- Erlewyn-Lajeunesse MD. Hyperimmunoglobulin-E syndrome with recurrent infection: a review of current opinion and treatment. *Pediatr Allergy Immunol* 2000; 11: 133–41
- Lindgren ML, Kobrynski L, Rasmussen SA, et al. Applying public health strategies to primary immunodeficiency diseases: a potential approach to genetic disorders. *Morbid Mortal Weekly Rep* 2004; 53: 1–29
- Mueller BJ, Pizzo PA. Cancer in children with primary or secondary immunodeficiencies. *J Pediatr* 1995; 126: 1–10
- Paller AS. Immunodeficiency syndromes. *Dermatol Clin* 1995; 13: 65–71
- Ratko TA, Cummings JP, Blebea J, Matuszewski KA. Clinical gene therapy for nonmalignant disease. *Am J Med* 2003; 115: 560–9
- Rosen FS, Cooper MD, Wedgwood RJP. The primary immunodeficiencies. *N Engl J Med* 1995; 333: 431–40
- Schurman SH, Candotti F. Autoimmunity in Wiskott–Aldrich syndrome. *Curr Opin Rheumatol* 2003; 15: 446–53
- Stewart DM, Tian L, Nelson DL. Linking cellular activation to cytoskeletal reorganization: Wiskott–Aldrich syndrome as a model. *Curr Opin Allergy Clin Immunol* 2001; 1: 525–33
- Thrasher AJ, Burns S, Lorenzi R, Jones GE. The Wiskott–Aldrich syndrome: disordered actin dynamics in haematopoietic cells. *Immunol Rev* 2000; 178: 118–28

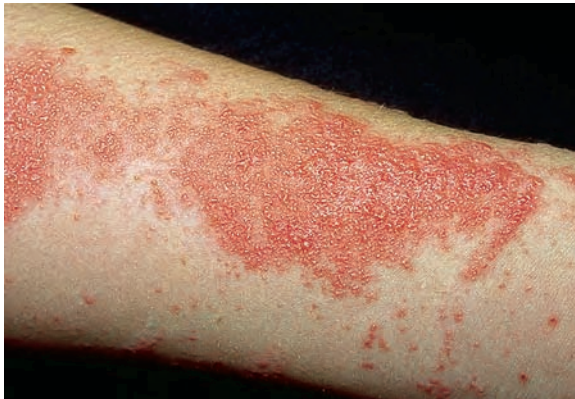## ALLERGIC CONTACT DERMATITIS

### Major points

- Characteristics
  1. First exposure does not cause a reaction
  2. Reaction begins 12–96 h after subsequent exposure if already allergic
  3. Lesions can persist up to 3 weeks
  4. Pruritus may vary from mild to severe
- Clinical pattern and shape give clues to offending antigen (Table 4.2)
  1. Linear configuration with sharp borders (Figure 4.18)
  2. Individual lesions are pruritic, erythematous papules or papulovesicles which may become vesicular with oozing, weeping and crusting
  3. Erythema with scaling in chronic cases
  4. Edema may be prominent especially around the face and groin
  5. Urticaria-like eruption can occur
  6. Heat, sweating and friction accentuate the reaction
- Major causes in childhood
  1. *Toxicodendron* – poison ivy/oak/sumac (Figure 4.19)
    - a. Most common allergic contact dermatitis in the USA
    - b. Sensitizing substance is an oleoresin called urushiol
    - c. Typical lesions in spring, summer, fall
    - d. Pruritic, erythematous streaks with vesicles are typical
    - e. Erythematous patches, papules can occur

**Table 4.2 Contact dermatitis history**

1. Determine the onset – exact time and location of appearance of lesions
2. Course of dermatitis – progression, recurrence, remission
3. Topical medicines used
4. Previous therapy and response
5. Work exposure – relation to work, days off, vacation, duties
6. Other persons having similar dermatitis
7. Hobbies – chemical exposure
8. Topical cosmetics – perfumes, soaps, sunscreens, toothpaste, nail polish, hair dyes, etc.
9. Plant exposure – poison ivy, chrysanthemums, weeds, etc.
10. Chemical exposure – work and home
11. Water exposure – hand washing, job-related
12. Clothing history – underwear, jewelry, watches, earrings, belts, snaps
13. Atopic history – asthma, eczema, personal and/or family history
14. Immune status

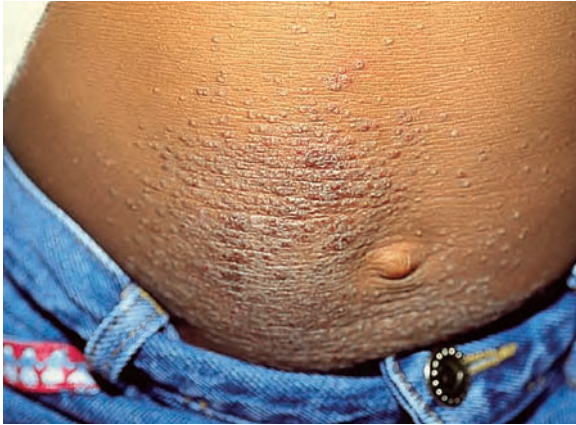**Figure 4.18** Poison ivy dermatitis – linear streaks of vesicles and erythema

2. Nickel
  - a. Common in children who wear earrings for pierced ears, metal belt buckles, metal zippers, metal snaps, or metal buttons
  - b. Erythema, scaling, crusting and pruritus on earlobes from earrings or around umbilicus

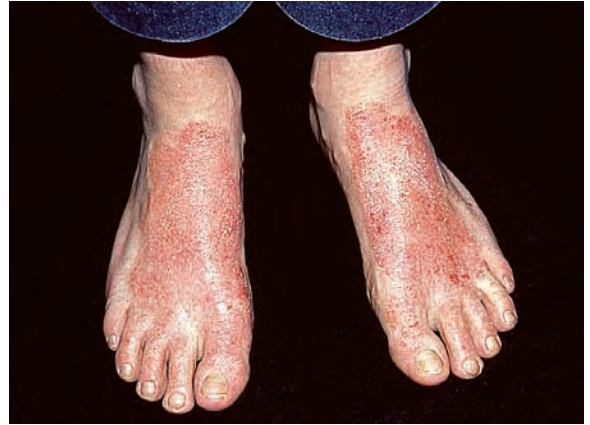**Figure 4.19** Poison ivy plant – leaves of three, let them be

- from snaps or belt buckles (Figure 4.20 and 4.21)
- c. Infants may have involvement from snaps on undershirts
3. Rubber/adhesives, causes:
  - a. Antioxidants: paraphenylenediamine, hydroquinone
  - b. Accelerators: mercaptobenzothiazole, thiuram, carbamate
4. Shoe dermatitis – acute or subacute dermatitis on dorsal feet (Figure 4.22); toewebs spared, causes:
  - a. Rubber (most common)
  - b. Chromates (in leather)
  - c. Glutaraldehyde (in leather)
  - d. Adhesives
  - e. Dyes
5. Adhesive tape dermatitis caused by rubber or colophony: well-demarcated area where adhesive tape is applied
6. Cosmetics
  - a. Acute or subacute (may require detective work)
  - b. Parabens
  - c. Perfumes – can be generalized or localized
  - d. Deodorants – in axillae
  - e. Nail lacquers – may see reaction around the eyes from zlacquer which was not completely dried and patient rubbed the eyelids
  - f. Eye products
  - g. Lipstick – rim of erythema around lips

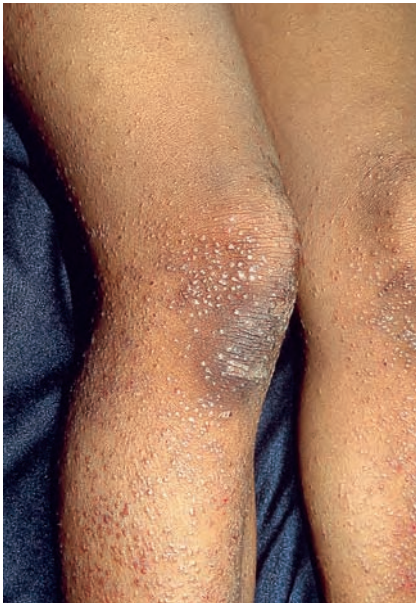



**Figure 4.20** Nickel dermatitis – typical distribution from a snap on the pants or belt buckle



**Figure 4.22** Shoe dermatitis – typical distribution on dorsal feet



**Figure 4.21** Autoeczematous dermatitis 'id reaction' – generalized eczematous changes from nickel dermatitis

7. Formaldehyde – used in clothing (permanent-press fabric finishes); periaxillary area
8. Benzocaine – over-the-counter (OTC) topical anesthetics
9. Caines/diphenhydramine (e.g. Benadryl®) – topical anesthetics
10. Neomycin – topical antibiotics; increased sensitivity if applied to broken skin
11. Mercury – e.g. Merthiolate®, Mercurochrome®

### Pathogenesis

- Delayed-type hypersensitivity reaction (type IV)
  1. Afferent (induction) phase (5–25 days)
  2. First contact; allergen penetrates skin and acts as hapten, binding to skin proteins
  3. Helper T cells activated
  4. Langerhans cells recognize antigen as nonself and present it to T lymphocytes
  5. Langerhans cells with hapten move from epidermis to lymph nodes
  6. Naïve T cells differentiate into clones of effector cells directed at foreign antigen
  7. Results in committed sensitized T cells reactive to specific antigen
- Elicitation reaction (24–48 hours)
  1. Re-exposure results in accumulation of effector cells which produce numerous cytokines (e.g. IFN- $\gamma$ , TNF, etc.) and mediators which result in dermatitis in areas limited to skin contact

### Diagnosis

- Laboratory – not indicated. Refer to dermatologist for evaluation if diagnosis unclear
- Skin patch tests (T.R.U.E. tests) (Tables 4.3 and 4.4)
  1. Helpful for difficult cases
  2. Patches applied to normal nonhairy skin (back or upper arms) for 48 h; read at 72 h and 5 days
  3. False-positive reactions often seen in atopic patients

**Table 4.3 Patch testing T.R.U.E. Test (Glaxo Dermatology)**

<i>Standard allergens</i>	<i>Found in:</i>
1. Nickel sulfate	Jewelry, belt buckles, eyeglass frames, alloys, orthopedic appliances, money, scissors, eating utensils
2. Wool alcohols	Cosmetics, creams, lotions, ointments, soaps (cross-reacts with lanolin)
3. Neomycin sulfate	Topical antibiotics, first-aid creams, eardrops, nosedrops
4. Potassium dichromate	Tanning solutions for leather, cement, photography solutions, paints, glues, pigments and some detergents
5. Caine mix	Topical anesthetics
6. Fragrance mix	Toiletries, soaps, perfumes, shampoo, scented products, industrial cutting fluids
7. Colophony (rosin)	Used by violinists, ball players, bowlers; in cosmetics, adhesives, lacquers, varnishes, paper and industrial products
8. Epoxy resin	Uncured epoxy resin, nail products
9. Quinolone mix	Topical antimicrobial medicated creams, medicated bandages and veterinary products
10. Balsam of Peru	Perfumes, flavoring in drinks, tobacco, topical medications, dental agents
11. Ethylenediamine dihydrochloride	Stabilizer for some creams; found in rubber, color photography solutions, epoxy catalyst systems and some antifreeze solutions (cross-reacts with hydroxyzine, aminophylline)
12. Cobalt dichloride	Some paints, cement, metal, metal-plated objects
13. <i>Para-tert</i> butylphenol formaldehyde resin	Leather finishes (shoes), paper fabrics, furniture, glues
14. Paraben mix	Preservative in numerous creams, cosmetics, industrial oils, glues
15. Carba mix	Rubber, rubber glues, vinyl, pesticides
16. Black rubber mix	Rubber antioxidant, hair dyes
17. Cl+Me- Isothiazolinone	Preservative found in cosmetics, medications, household cleaning products, industrial fluids and greases
18. Quaternium 15	Stabilizer, formaldehyde releaser found in cosmetics, creams, lotions
19. Mercaptobenzothiazole	Shoes, rubber accelerator, antifreeze, cutting oils, flea and mosquito repellants
20. Paraphenylenediamine	Hair dyes, inks, photodevelopers, textile dyes
21. Formaldehyde	Clothes, textiles, preservatives, disinfectants, dental plastics, glues, nail polishes, adhesives, shampoo Formaldehyde releasers: Quaternium 15, imidiazoyl urea, Bronopol
22. Mercapto mix	Rubber, glues, coolants, industrial products
23. Thimerosal	Preservative in vaccines, contact lens solutions, eye cosmetics, nose and ear drops
24. Thiuram mix	Rubber, disinfectant, lubricating oils, fungicide

**Table 4.4 Patch test materials/nickel detection kits can be ordered**

Glaxo Dermatology (T.R.U.E. Test)

5 Moore Drive

Research Triangle Park, NC 27709, USA

[www.truetest.com/](http://www.truetest.com/)

Hermal Pharmaceutical Laboratories, Inc.

Route 145

Oak Hill, NY 12460, USA

(518) 475-0175

[www.hermal.de/english/index.html](http://www.hermal.de/english/index.html)

Allerderm Labs Inc.

28 Glen Drive

Mill Valley, CA 94941, USA

(415) 381-0106

[www.allerderm.com](http://www.allerderm.com)

- Histology:
  1. Multilocular intraepidermal spongiotic vesicles
  2. Eosinophils in dermis and epidermis
  3. Langerhans cells in the epidermis associated with lymphocytes
  4. Immunohistochemical studies show primarily memory T-helper lymphocytes, although T-suppressor cells can be noted
- Nickel detection kit: dimethylglyoxime in a 10% aqueous solution of ammonia – turns pink on contact with nickel (see Table 4.4)

### *Differential diagnosis*

- Atopic dermatitis
- Irritant contact dermatitis
- Autoeczematization

### *Treatment*

- Avoidance of contactant
  1. Education
  2. Give patients a list of objects or products which contain allergens
  3. Wash skin with plain water if known allergen is contacted
- Acute dermatitis with oozing and weeping, vesicles or bullae
  1. Compresses with Burrow's solution (e.g. Domeboro®, Blurobor®) for 15 min
  2. Apply shaken lotion of calamine three times a day for drying effect

3. Avoid topical diphenhydramine or caines which are added to some products
4. Topical corticosteroids
  - a. Medium to ultra-potent steroids (class 1–4) for about 5–7 days used two or three times a day then taper to lowest strength to keep erythema and itching under control
5. Oral antipruritics (see doses in Chapter 21), diphenhydramine (Benadryl), hydroxyzine (Atarax®), cetirizine (Zyrtec®), fexofenadine (Allegra®)
6. Systemic corticosteroids
  - a. Oral prednisone 0.5–2 mg/kg per day tapered over 10–21 days for widespread or severe involvement
  - b. Barrier creams: Stokogard® (OTC)–linoleic acid dimer, Hollister Moisture Barrier Ointment® (OTC by Hollister Inc., Libertyville® IL) and Theraseal®

### *Prognosis*

- Most patients recover from acute hypersensitivity in 14–21 days
- Hyposensitization injections not effective and may be unsafe
- Oral hyposensitization used mainly for workers in forest industry who cannot avoid contact with toxicodendrons (of questionable value)
- Wash skin and clothes with water and soap immediately after contact
- Most contact allergens bind to the epidermis and set up response within 0.5–2 h of contact
- Chronic exposure to allergens such as rubber, perfumes, preservatives which are not obvious, would benefit from patch testing by a dermatologist skilled in this technique

### *References*

- Bourke J, Coulson I, English J. Guidelines for care of contact dermatitis. *Br J Dermatol* 2001; 145: 877–85
- Drake LA, Dorner W, Goltz RW, et al. Guidelines of care for contact dermatitis. *J Am Acad Dermatol* 1995; 32: 109–13
- Mallory SB. The pediatric patient. In *Practical Contact Dermatitis*. Guin JD, ed. McGraw-Hill, 1995: 603–21
- Maouad M, Fleischer AB, Sherertz EF, Feldman SR. Significance–prevalence index number: a reinterpretation and enhancement of data from the North American Contact Dermatitis Group. *J Am Acad Dermatol* 1999; 41: 573–6



Sharma V, Beyer DJ, Paruthi S, Nopper AJ. Prominent pruritic periumbilical papules: allergic contact dermatitis to nickel. *Pediatr Dermatol* 2002; 19: 106–9

Silverberg NB, Licht J, Friedler S, et al. Nickel contact hypersensitivity in children. *Pediatr Dermatol* 2002; 19: 110–13

Wildemore JK, Junkins-Hopkins JM, James WD. Evaluation of the histologic characteristics of patch test confirmed allergic contact dermatitis. *J Am Acad Dermatol* 2003; 49: 243–8

## IRRITANT CONTACT DERMATITIS

### Major points

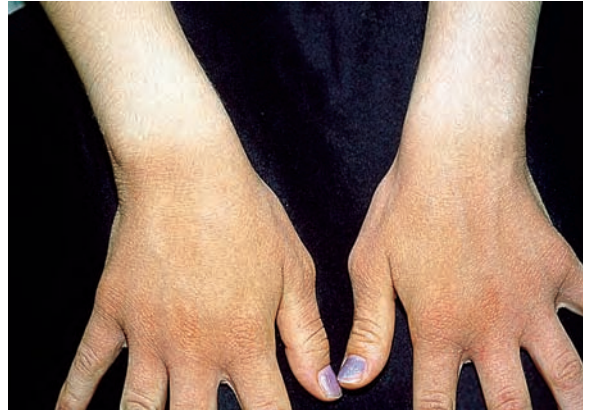- In general, all people will react to an irritant if applied in a high enough concentration
  1. People with atopic dermatitis are more susceptible to irritant dermatitis, especially in dry climates
  2. Skin of infants can redden quickly when irritated
- Characteristic erythematous, pruritic patches and plaques with ill-defined borders
- Common causes:
  1. Hands repeatedly exposed to water, cleansers, or soaps show fissuring or a 'glazed' appearance (Figure 4.23)
  2. Bubble baths, bleaches, detergents, solvents, acids, alkalis
  3. Lip-licking habit – wetting and drying caused by saliva
  4. Thumb-suckers in toddlers
  5. Perioral area in babies – foods, dribbling saliva and rubbing the area
  6. Diaper area secondary to multiple factors such as wetting, maceration, urine, feces
- Severe forms: chemical burns (alkalis, acids) with vesiculation, necrosis, or ulceration
- Chronic irritant dermatitis usually lacks vesicles and is characterized by dryness and chapping

### Pathogenesis

- Wetting and drying causes decreased lipids in the epidermis with a resultant break in the epidermal barrier
- Occurs more commonly in atopic patients

### Diagnosis

- Clinical findings



**Figure 4.23** Irritant contact dermatitis – caused by excessive hand washing

- Histology: mild to moderate epidermal spongiosis; epidermal necrosis; usually does not contain eosinophils (as in allergic causes); perivascular lymphocytes and neutrophils

### Differential diagnosis

- Atopic dermatitis
- Allergic contact dermatitis

### Treatment

- Avoid offending agents
- Occlusive pastes (zinc oxide paste) or barrier creams (e.g. Desitin®)
- Emollients (e.g. petrolatum)
- Steroids of low to moderate potency

### Prognosis

- Benign condition but usually reappears if same circumstances occur

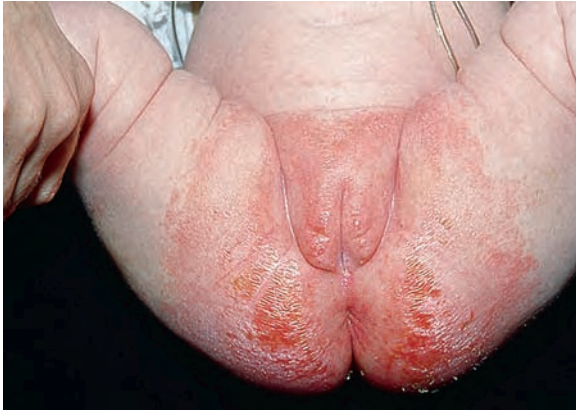### References

Weedon D. *Skin Pathology*. Churchill Livingstone: New York, 1997: 88–9

## DIAPER DERMATITIS

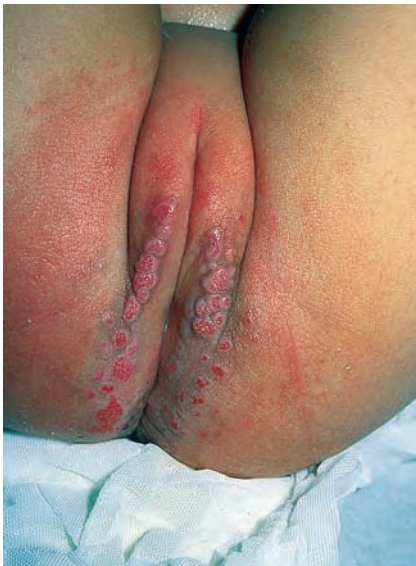### Major points

- Irritant diaper dermatitis (chafing dermatitis)
  1. Involves convex surfaces of buttocks, upper thighs, abdomen (Figure 4.24)



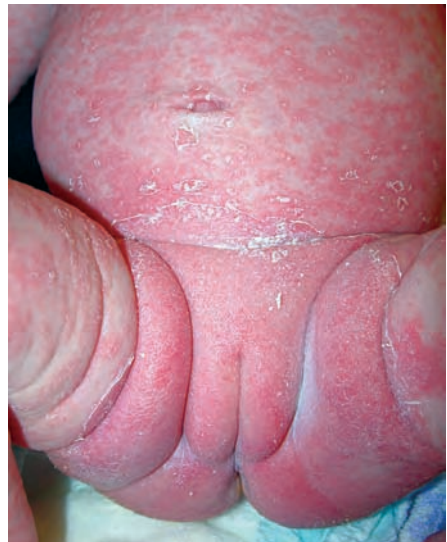**Figure 4.24** Diaper dermatitis (irritant) – caused by infrequent diaper changes

- a. Sparing inguinal folds
- b. Common between 7 and 12 months of age
- 2. Ulcerative form
  - a. Marked erythema
  - b. Shallow or deep ulcers (Jacquet ulcers) (Figure 4.25)
  - c. Most frequent around perianal area
  - d. Commonly follows diarrhea
- *Candida albicans* dermatitis
  - 1. Beefy-red, confluent erythema (Figure 4.28)
  - 2. Involves inguinal creases

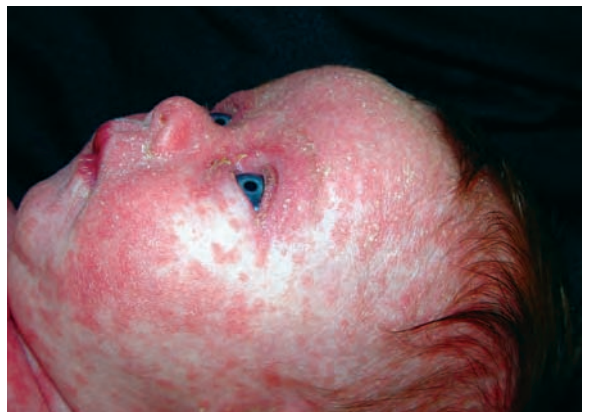

**Figure 4.25** Jacquet ulcers – caused by chronic moisture in an incontinent child

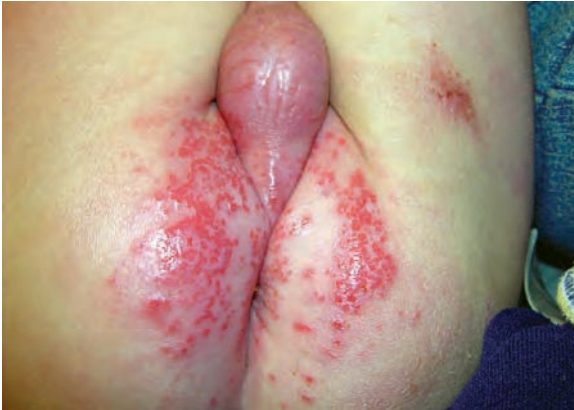- 3. Satellite red papules or pustules at the periphery are common
- 4. Frequently occurs after diaper dermatitis has lasted >72 h
- 5. KOH: budding yeast and pseudohyphae
- 6. Commonly seen with thrush (oral candidiasis)
- Seborrheic dermatitis
  - 1. Involves inguinal folds (Figure 4.26)
  - 2. Yellowish-pink scale
  - 3. Cradle cap can be prominent on scalp and a clue to correct diagnosis (Figure 4.27)
  - 4. Typical lesions present elsewhere



**Figure 4.26** Seborrheic dermatitis – erythematous scaling in the diaper area



**Figure 4.27** Seborrheic dermatitis – erythematous scaling on the face



**Figure 4.28** Candidal diaper dermatitis – satellite erythematous papules

### Pathogenesis

- Moisture, maceration, occlusion and possibly *Candida* and bacteria play a role, causing damage to the epidermis
- Elevation in pH of skin allows fecal lipases and proteases to further irritate skin

### Diagnosis

Clinical presentation

### Differential diagnosis

- Langerhans cell histiocytosis
- Atopic dermatitis
- Immunodeficiencies
  1. HIV – uncommon presentation with granulomatous component
  2. Severe combined immunodeficiency – usually generalized, eczematous eruption
- Psoriasis
- Bullous impetigo
- Granuloma gluteale infantum

### Treatment

- Remove contactants (urine and feces)
- Eliminate wetness and maceration
  1. Frequent diaper changes with absorptive gel disposable diapers
  2. Air dry if possible
  3. Change diapers in middle of night so baby does not sleep all night with wet diapers
- Protective maintenance with barrier creams can be used once dermatitis has cleared

- Minimize irritants
  1. Use water with or without mild soap
  2. Avoid diaper wipes which may contain alcohol, propylene glycol or perfumes
  3. Use soft washcloth or soft paper towel for cleaning
- Candidal infections
  1. Topical antifungal therapy (e.g. nystatin, miconazole, ketoconazole, clotrimazole) with every diaper change until clear
- Erythema
  1. Hydrocortisone cream or ointment 1%, 3–4 times a day until clear (usually <7 days)
  2. Avoid steroids stronger than class 7 in diaper area

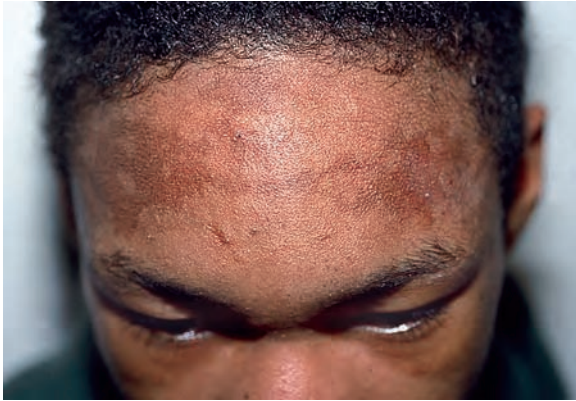### References

- Berg RW, Milligan MC, Sarbaugh FC. Association of skin wetness and pH with diaper dermatitis. *Pediatr Dermatol* 1994; 11: 18–20
- Janniger CK, Thomas I. Diaper dermatitis: an approach to prevention employing effective diaper care. *Cutis* 1993; 52: 153–5
- Jordan WE, Lawson KD, Berg RW, et al. Diaper dermatitis: frequency and severity among a general infant population. *Pediatr Dermatol* 1986; 3: 198–207
- Singalavanija S, Frieden IJ. Diaper dermatitis. *Pediatr Review* 1995; 16: 142–7
- Sires UI, Mallory SB. Diaper dermatitis. *Postgraduate Med* 1995; 98: 79–86
- Wilson PA, Dallas MJ. Diaper performance: maintenance of healthy skin. *Pediatr Dermatol* 1990; 7: 179–84

## SEBORRHEIC DERMATITIS

### Major points

- Age:
  1. Infancy: usually begins 4–6 weeks of age with cradle cap (Figure 4.27)
  2. Adolescents: dry, fine, flaky desquamation of scalp, mid-face and eyebrows (Figure 4.29)
- Location:
  1. Scalp, mid-face, mid-chest, perineum
  2. Less common areas: forehead, anterior chest, axillae, umbilicus, intertriginous areas
  3. Facial involvement in adolescents along nasolabial folds



**Figure 4.29** Seborrheic dermatitis – in a teenager, often seen on the central face

4. Lesions have greasy, yellowish scale with slightly salmon-colored, erythematous base which can be easily removed
5. Blepharitis – erythema and scaling along lid margins
6. Pruritus slight or absent
7. Persistent recalcitrant seborrhea may be early sign in HIV infection
8. Rare cause of erythroderma in infants

#### Pathogenesis

- Mechanism unknown
- Excess sebum accumulation
- Increased quantities of *Pityrosporum ovale* (*Malessezia furfur*) are seen in sites of seborrheic dermatitis and may contribute to the disorder

#### Diagnosis

- Clinical features are typical
- Histology: parakeratosis of the follicular infundibulum; perifollicular collections of neutrophils and lymphocytes in stratum corneum; acanthosis with mild to moderate spongiosis

#### Differential diagnosis

- Atopic dermatitis
- Contact dermatitis
- Psoriasis
- Dermatophyte infection
- Langerhans cell histiocytosis
- Scabies
- Immunodeficiency diseases (severe combined immunodeficiency, HIV infection)

- Tinea capitis
- Rosacea
- *Candida* infection
- Systemic lupus erythematosus

#### Treatment

- Low-potency topical steroid creams (class 5–7) twice a day, usually necessary for <7 days
- Shampoos
  1. Keratolytic tar shampoos – sulfur or salicylic acid (e.g. T-gel®)
  2. Zinc pyrithione (e.g. Head & Shoulders®)
  3. Selenium sulfide 2.5% shampoo (e.g. Selsun®)
  4. 2% ketoconazole shampoo (e.g. Nizoral®)
- Mineral oil in scalp for a few hours then shampoo and scrub with soft brush
- Blepharitis – warm compresses, non-irritating baby shampoo, mechanical removal of scales, topical sulfacetamide ointment (e.g. Sulamyd®)
- Topical antifungal agents BID (e.g. Micatin®, Lotrimin®)

#### Prognosis

- Usually clears with topical corticosteroids, but tends to recur

#### References

- Heng MCY, Henderson CL, Barker DC, Habberfelde G. Correlation of *Pityrosporum ovale* density with clinical severity of seborrheic dermatitis as assessed by a simplified technique. *J Am Acad Dermatol* 1990; 23: 82–6
- Mimouni K, Mukamel M, Zeharia A, Mimouni M. Prognosis of infantile seborrheic dermatitis. *J Pediatr* 1995; 127: 744–6
- Tolleson A, Frithz A, Berg A, Karlman G. Essential fatty acids in infantile seborrheic dermatitis. *J Am Acad Dermatol* 1993; 28: 957–61
- Williams ML. Differential diagnosis of seborrheic dermatitis. *Pediatr Review* 1986; 7: 204–11

## INTERTRIGO

#### Major points

- Superficial inflammatory dermatitis which occurs in skin folds where there is apposition of the skin (e.g. folds of the neck of infants or axillae)
- Skin develops well-demarcated erythematous, macerated patches which are often secondarily



infected with *Candida* or bacteria (e.g. streptococci) (Figure 4.30)

- Obesity, diabetes, immunosuppression are predisposing factors

#### Pathogenesis

- Caused by friction, heat and moisture
- May be a form of seborrheic dermatitis

#### Diagnosis

- Clinical appearance is typical
- KOH prep shows budding yeast and pseudohyphae
- Culture may demonstrate *Candida*

#### Differential diagnosis

See Seborrheic dermatitis

#### Treatment

- Eliminate causes of maceration (e.g. obesity)
- Keep skin dry with air drying and dusting powders (not in infants because of inhalation)
- For inflammation, hydrocortisone 1% cream TID
- For secondary infection with *Candida*, a topical antifungal agent TID (e.g. clotrimazole, miconazole)
- For secondary bacterial infections: oral antibiotics or topical mupirocin

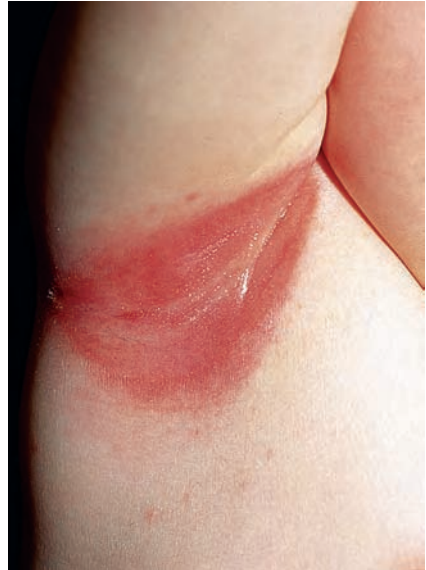#### Prognosis

- Excellent if skin apposition decreases

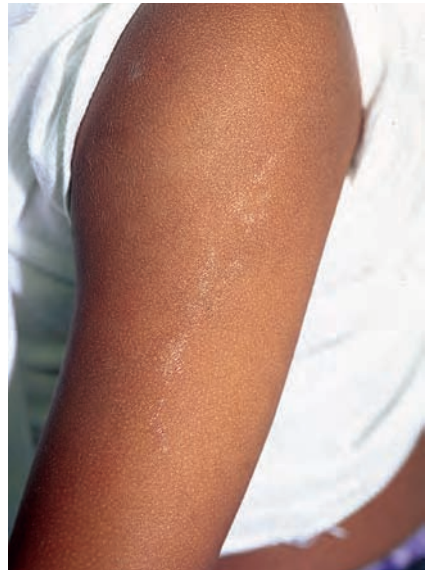#### References

Garcia Hidalgo L. Dermatological complications of obesity. *Am J Clin Dermatol* 2002; 3: 497–506

Honig PJ, Frieden IJ, Kim HJ, Yan AC. Streptococcal intertrigo: an underrecognized condition in children. *Pediatrics* 2003; 112: 1427–9



**Figure 4.30** Intertrigo – erythema and maceration in the axilla



**Figure 4.31** Lichen striatus – hypopigmented linear papules following Blaschko lines

## LICHEN STRIATUS

#### Major points

- Self-limited, unilateral, asymptomatic, linear dermatitis which is sudden in onset
- Linear, shiny, hypopigmented or erythematous papules which occur in streaks following lines of Blaschko (Figure 4.31)
- May have fine scale on surface or hypopigmented papules
- Usually limited to one extremity, but can affect the face
- Asymptomatic
- Common in ages 2–12 years; more common in girls
- Starts proximally and spreads distally in a linear fashion

- Lesions last 3 months to 3 years (mean 9 months), then flatten and resolve

### *Pathogenesis*

- Unknown etiology

### *Diagnosis*

- Clinical characteristics are typical
- Histology: lichenoid dermatitis limited to 3–4 dermal papillae with perieccrine lymphocytic involvement
- Skin biopsy is rarely indicated

### *Differential diagnosis*

- Epidermal nevus
- Lichen nitidus
- Contact dermatitis
- Lichen planus
- Psoriasis
- Gianotti–Crosti syndrome
- Porokeratosis
- Verruca plana

### *Therapy*

- Treatment usually unnecessary
- Low-strength topical steroids (class 5–7) may be beneficial to hasten resolution
- Patient education as to course of the disease

### *Prognosis*

- Spontaneous resolution

### *References*

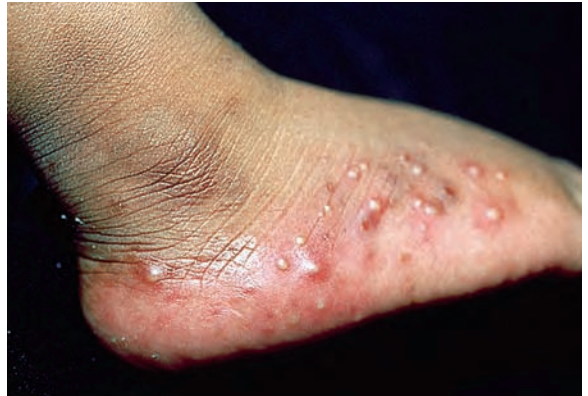- Kennedy D, Rogers M. Lichen striatus. *Pediatr Dermatol* 1996; 13: 95–99
- Patrizi A, Neri I, Fiorentini C, et al. Simultaneous occurrence of lichen striatus in siblings. *Pediatr Dermatol* 1997; 14: 293–5
- Tosti A, Peluso AM, Misciali C, Cameli N. Nail lichen striatus: clinical features and long-term follow-up of five patients. *J Am Acad Dermatol* 1997; 36: 908–13

## **ACROPUSTULOSIS OF INFANCY**

### *Major points*

- Seen most commonly in 15–18-month old Black male infants

- Presents as pustules or vesicles on palms and soles or along sides of hands and feet (Figure 4.32)
- May be present at birth but more common in infancy
- Occurs in recurrent crops until 2–3 years of age
- Extremely pruritic
- Pustules resolve with scale and hyperpigmentation
- Cultures of the pustules are sterile



**Figure 4.32** Acropustulosis of infancy – typical intensely pruritic papules and pustules along the sides of the feet

### *Pathogenesis*

- Cause unknown

### *Diagnosis*

- Clinical presentation, rule out other disorders (e.g. scabies)

### *Differential diagnosis*

- Scabies
- Dyshidrotic eczema
- Contact dermatitis

### *Treatment*

- Moderate potency topical steroids (class 3–6) two or three times a day during outbreaks
- Oral antihistamines: hydroxyzine, diphenhydramine
- If no relief from the above therapy, refer to a dermatologist

### *Prognosis*

- Eruption lasts several months to several years, slowly becoming less symptomatic, then abates



---

## References

- Braun-Falco M, Stachowitz S, Schnopp C, et al. Infantile acropustulosis successfully controlled with topical corticosteroids under damp tubular retention bandages. *Acta Dermato-Venereologica* 2001; 81: 140–1
- Dorton DW, Kaufmann M. Palmoplantar pustules in an infant. Acropustulosis of infancy. *Arch Dermatol* 1996; 132: 1365–6
- Dromy R, Raz A, Metsker A. Infantile acropustulosis. *Pediatr Dermatol* 1991; 8: 284–7
- Mancini AJ, Frieden IJ, Paller AS. Infantile acropustulosis revisited: history of scabies and response to topical corticosteroids. *Pediatr Dermatol* 1998; 15: 337–41
- Prendiville JS. Infantile acropustulosis – how often is it a sequela of scabies? *Pediatr Dermatol* 1995; 12: 275–6
- Wagner A. Distinguishing vesicular and pustular disorders in the neonate. *Curr Opin Pediatr* 1997; 9: 396–405



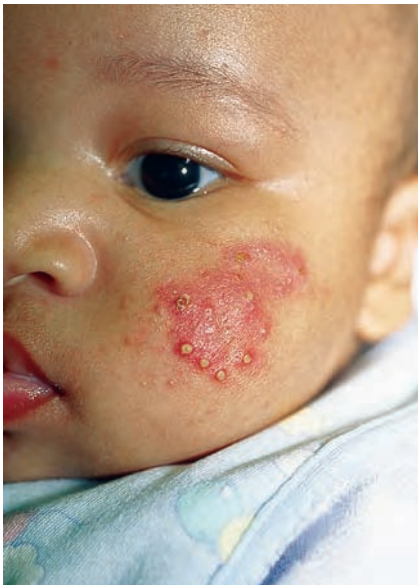# ACNE AND ACNEIFORM DISORDERS

---

## Early-onset acne

### Major points

- Neonatal acne (neonatal cephalic pustulosis)
  1. Inflammatory papules on cheeks, face and scalp in first 2–3 weeks of life (Figure 5.1)
  2. No associated comedones
- Infantile acne
  1. Onset prior to 2 years of age
  2. Male/female ratio >1
  3. Facial involvement only
  4. No identifiable underlying endocrine abnormality

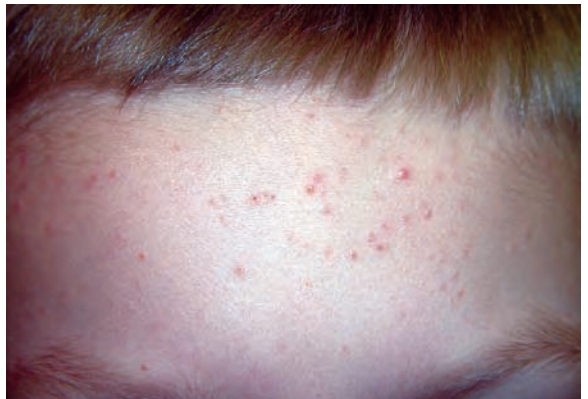

**Figure 5.1** Neonatal acne – grouped papules, pustules and comedones at 2 months of age

5. Resolves without treatment
- Prepubertal acne
    1. Onset after 2 years of age
    2. Male/female ratio <1
    3. Facial, chest, back involvement (Figure 5.2)
    4. Uncommon underlying endocrinopathy; only noted when other signs of virilization are also present

### Pathogenesis

- Considered to be caused by androgen excess or sensitivity to androgens
- An enlarged zona reticularis in the fetal adrenal gland produces increased levels of dehydroepiandrosterone (DHEA) and dehydroepiandrosterone sulfate (DHEAS) until 6 months of age
- Testosterone production from the male gonads is also increased until 12 months of age



**Figure 5.2** Childhood acne in a 6-year-old boy without evidence of androgen excess

### Diagnosis

- Clinical examination
- If severe, signs of virilization or rapid growth, a work-up for an underlying endocrine disorder should be pursued
- Hand X-ray for bone age is a good screening evaluation

### Differential diagnosis

- Miliaria rubra
- Neonatal cephalic pustulosis

### Treatment

- Varies depending on the severity and risk for scarring
- Topical retinoids (e.g. adapalene)
- Topical antibiotics (e.g. benzoyl peroxide or erythromycin)
- Systemic antibiotics (e.g. erythromycin)
- Systemic isotretinoin (rarely needed)

### Prognosis

- Neonatal and infantile types often resolve spontaneously without treatment
- Prepubertal subset has a higher risk of scarring and often requires treatment
- Higher incidence and increased severity of adolescent acne vulgaris
- Monitor for development of endocrine abnormality

### References

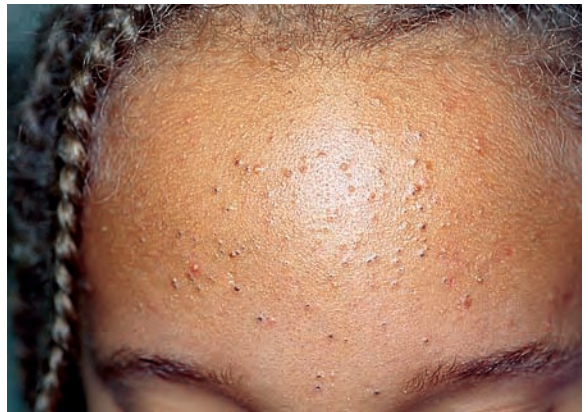- Chew EW, Bingham A, Burrows D. Incidence of acne vulgaris in patients with infantile acne. *Clin Exp Dermatol* 1990; 15: 376–7
- Cunliffe WJ, Baron SE, Coulson IH. A clinical and therapeutic study of 29 patients with infantile acne. *Br J Dermatol* 2001; 145: 463–6
- Lucky AW. A review of infantile and pediatric acne. *Dermatology* 1998; 196: 95–7

## Acne vulgaris

### Major points

- Most prevalent skin disorder in pediatrics
  1. Affects 40% of children aged 8–10 years
  2. Affects 85% of adolescents aged 15–17 years

- Lesion types:
  1. Comedones: obstructive lesions
    - a. Microcomedone: microscopic plugging of the hair follicle that is the precursor lesion to acne vulgaris
    - b. Open comedone (blackhead): plugging at the follicular opening; cellular plug of stratum corneum with oxidized melanin within the follicle (Figure 5.3)

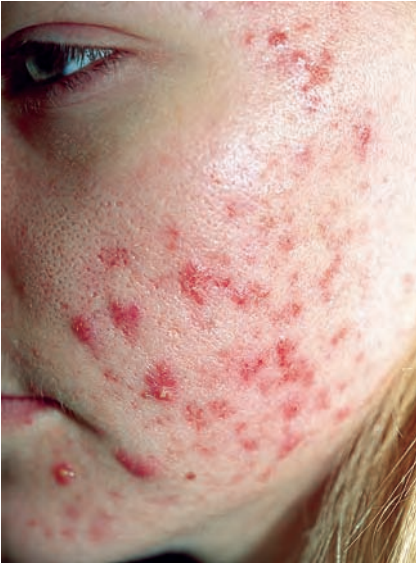

**Figure 5.3** Comedonal acne – on forehead with open and closed comedones

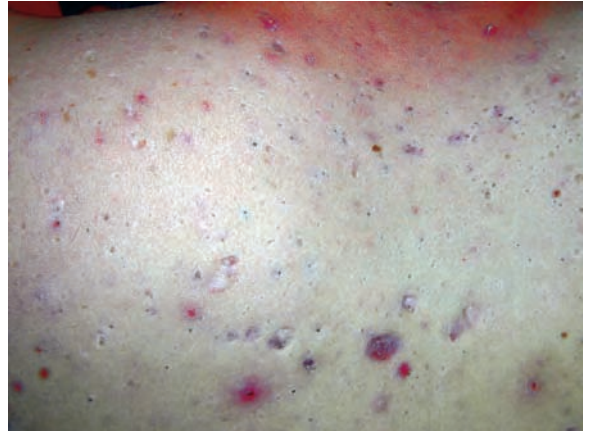
- c. Closed comedone (whitehead): plugging of the pilosebaceous unit just below the follicular opening with cystic swelling of the duct; filled with cellular debris
2. Inflammatory lesions: papules, pustules, cysts, sinus tracts (Figures 5.4–5.6)
  3. Scars: depressed, pitted, macular, papular, hypertrophic, keloidal
- Acne is one of the earliest stages of adrenarche
  - Lesion type often correlates with pubertal stage
    1. Comedonal acne is predominant type in prepubertal children
    2. Inflammatory acne is more prevalent in adolescents
  - Develops in areas with high numbers of pilosebaceous units: face, chest, back
  - Increased severity often predicted by earlier onset and positive family history of scarring acne

### Pathogenesis

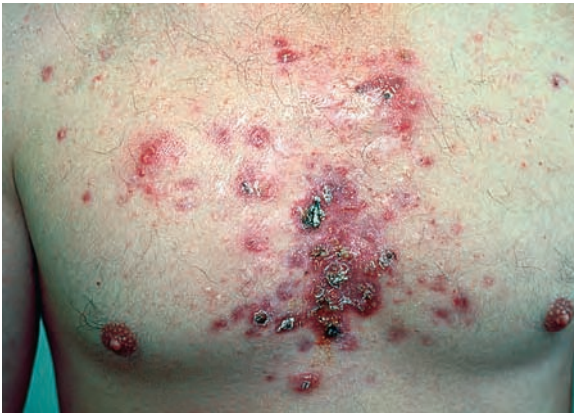- Acne development is a complex process that involves four main contributing factors



**Figure 5.4** Papulopustular acne – numerous erythematous papules and pustules on the face



**Figure 5.6** Inflammatory acne with comedones, erythematous papules and nodules on the back of a teenager



**Figure 5.5** Cystic acne on the chest with erythematous nodules, crusts and scarring

1. Abnormal keratinization and obstruction of the pilosebaceous unit
  - a. Initial lesion is a microcomedone; caused by obstruction of the follicular opening with the accumulation of cellular debris
  - b. Obstruction is due to abnormal keratinization of the cells lining the follicle with delayed shedding and increased cohesiveness
2. Hormonal stimulation and increased sebum production
  - a. Increased secretion and accumulation of sebum within the follicle which is stimulated by increased adrenal and gonadal androgens that occur with adrenache
  - b. Polycystic ovary syndrome, a heterogeneous disorder with altered gonadotropin secretion, hyperandrogenism (acne, hirsutism and virilization), chronic anovulation, obesity and insulin resistance
3. Bacterial overgrowth
  - a. *Propionibacterium acnes* overgrows within the dilated follicle
  - b. Bacterial lipases convert accumulated sebum triglycerides into free fatty acids that cause inflammation
  - c. *P. acnes* also releases other proteolytic enzymes and chemotactic factors that further stimulate inflammation and recruitment of polymorphonuclear cells (PMNs)
4. Inflammatory reaction
  - a. Inflammatory cells including PMNs are recruited to the area
  - b. Ingestion of bacteria by PMNs causes release of hydrolytic enzymes that causes rupture of the follicular wall
  - c. This leads to intense inflammation and a surrounding foreign body reaction



### Diagnosis

- Clinical findings

### Differential diagnosis

- Drug-induced acne
- Chemical-induced acne
- Rosacea
- Gram-negative folliculitis
- Pityrosporum folliculitis

### Treatment

- Topical retinoids: important for normalizing keratinization (e.g. tretinoin, adapalene)
- Topical keratolytics: salicylic acid, azelaic acid
- Topical benzoyl peroxide preparations
- Topical antibiotics: clindamycin, erythromycin
- Systemic antibiotics for inflammatory lesions
  1. Doxycycline, tetracycline and minocycline most commonly used in those >9 years of age
- Systemic retinoids for severe cystic acne or early scarring
- Oral contraceptives

### Prognosis

- Can have significant impact on social interactions and self-esteem and can lead to depression in severe cases
- May produce significant scarring in inflammatory and cystic lesions
- Can rarely be associated with an underlying endocrine disorder

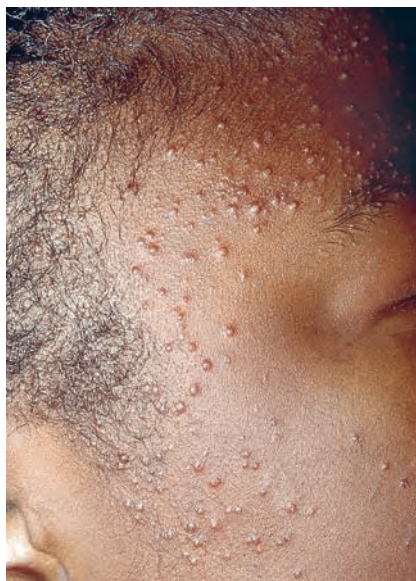### References

- Cunliffe WJ, Holand DB, Clark SM, Stable GI. Comedogenesis: some new aetiological, clinical and therapeutic strategies. *Br J Dermatol* 2000; 142: 1084–91
- Harper JC, Thiboutot DM. Pathogenesis of acne: recent research advances. *Adv Dermatol* 2003; 19: 1–10
- Lee DJ, VanDyke GS, Kim J. Update on pathogenesis and treatment of acne. *Curr Opin Pediatr* 2003; 15: 405–10
- Leyden JJ. A review of the use of combination therapies for the treatment of acne vulgaris. *J Am Acad Dermatol* 2003; 49: S200–10
- Lucky AW, Biro FM, Simbartl LA, et al. Predictors of severity of acne vulgaris in young adolescent girls: results of a five-year longitudinal study. *J Pediatr* 1997; 130: 30–9
- Weiss JS. Current options for topical treatment of acne vulgaris. *Pediatr Dermatol* 1997; 14: 480–8

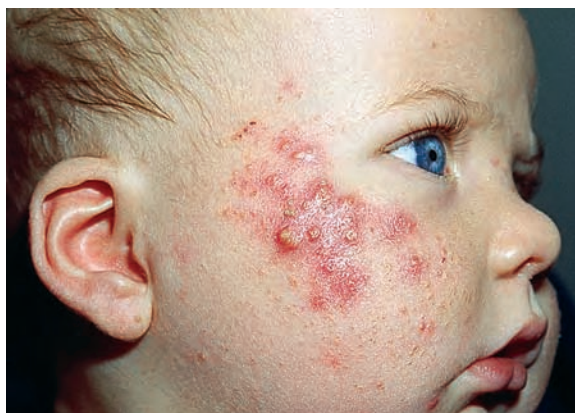## Drug-induced acne

### Major points

- Acneiform eruption precipitated by medication
- Associated drugs: adrenocorticotrophic hormone, systemic corticosteroids (Figure 5.7), topical steroids under occlusion (Figure 5.8), androgens, anticonvulsants (e.g. phenytoin, phenobarbital), lithium, isoniazid, bromide and iodides



**Figure 5.7** Acne aggravated by steroids with multiple pustules arising simultaneously



**Figure 5.8** Acne in an infant caused by potent topical steroids on the face

- Medications can be the sole cause of an acneiform eruption or can exacerbate underlying acne vulgaris
- Drug-induced lesions are typically monomorphic, papulopustular and diffuse, involving the shoulders and upper arms
- Comedones are typically absent

### *Pathogenesis*

- Variable, depending on drug; steroids affect keratinization, while androgens stimulate sebaceous gland activity

### *Diagnosis*

- Clinical examination and history

### *Differential diagnosis*

- Acne vulgaris
- Folliculitis

### *Treatment*

- Discontinuation or tapering of offending agent if possible
- Topical agents (e.g. benzoyl peroxide, antibiotics)
- Oral antibiotics

### *Prognosis*

- Typically resolves without residua after discontinuation of the causative agent

### *References*

Guillot B. Adverse skin reactions to inhaled corticosteroids. Expert Opin Drug Saf 2002; 1: 325–9

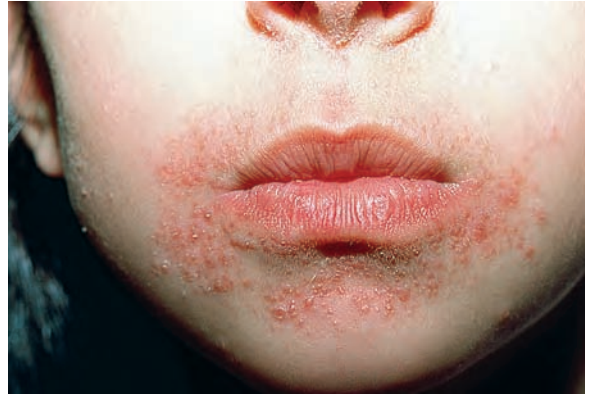Shaw JC. Acne: effect of hormones on pathogenesis and management. Am J Clin Dermatol 2002; 3: 571–8

## **Perioral dermatitis**

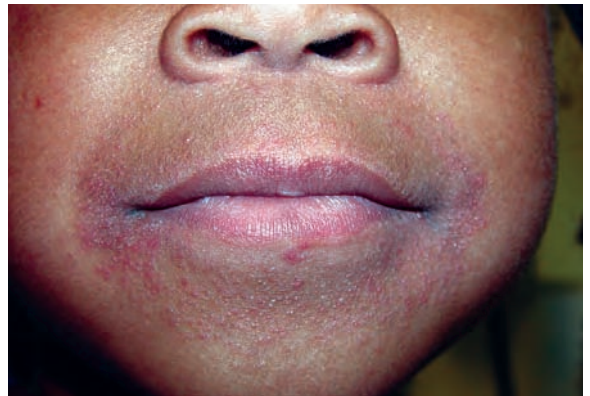Synonym: periorificial dermatitis

### *Major points*

- Common acneiform eruption in children
- Presents with erythema, scaling, skin-colored papules and pinpoint pustules around the mouth with sparing of the vermillion border (Figures 5.9 and 5.10)
- Granulomatous lesions can involve the entire face, and be concentrated in perioral, perinasal,



**Figure 5.9** Perioral dermatitis – with acneiform papules around the mouth aggravated by topical steroids



**Figure 5.10** Perioral dermatitis – with tiny erythematous papules

periocular and possible genital areas with monomorphic coalescent papules

- Symptoms include stinging/burning and occasional pruritus

### *Pathogenesis*

- Unknown etiology
- Known to be induced by use of topical steroids on the face
- Also exacerbated by fluorinated toothpaste and other substances

### *Diagnosis*

- Clinical findings
- Histology: spongiosis of the follicular infundibulum with lymphocytic exocytosis and perivascular lymphohistiocytic inflammation

### Differential diagnosis

- Atopic dermatitis
- Seborrheic dermatitis
- Contact/irritant dermatitis
- Rosacea
- Planar warts
- Sarcoidosis

### Treatment

- Eliminate aggravating/precipitating topical agents, especially topical steroids
- Topical antibiotics (e.g. metronidazole, clindamycin)
- Systemic antibiotics (e.g. erythromycin) – may be needed for 2 months of continuous therapy

### Prognosis

- Intermittent course
- Can worsen after withdrawal of precipitating agent
- Recurrences are not uncommon
- Responds well to therapy in 1–3 months

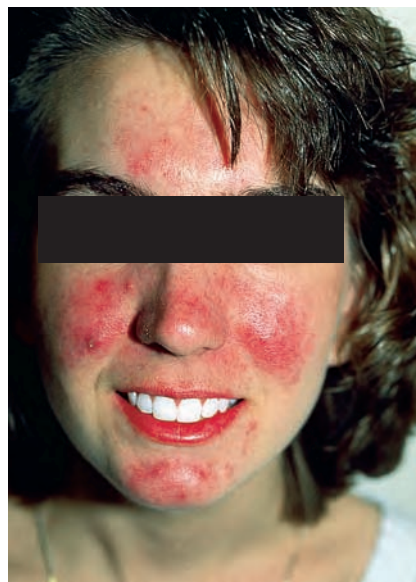### References

- Knautz MA, Leshner JL. Childhood granulomatous periorificial dermatitis. *Pediatr Dermatol* 1996; 13: 131–4
- Laude TA, Salvemini JN. Perioral dermatitis in children. *Semin Cutan Med Surg* 1999; 18: 206–9
- Manders SM, Lucky AW. Perioral dermatitis in childhood. *J Am Acad Dermatol* 1992; 27: 688–92
- Urbatsch AJ, Frieden I, Williams ML, et al. Extrafacial and generalized granulomatous periorificial dermatitis. *Arch Dermatol* 2002; 138: 1354–8

## Rosacea

### Major points

- Rare condition in childhood
- Can present with chronic and intermittent facial erythema, flushing, telangiectasias and papulopustular eruption (Figure 5.11)
- Eye involvement including blepharitis, conjunctivitis and episcleritis may occur
- Comedones are absent
- Typically involves the cheeks and chin
- Most children have an associated family history of rosacea



**Figure 5.11** Rosacea associated with easy blushing in a teenage girl

### Pathogenesis

- Unknown but probably multifactorial
- Questionable role of *Demodex folliculorum*
- Chronic topical steroid application can lead to rosacea-like eruption (steroid-induced acne)

### Diagnosis

- Clinical features
- Histology variable; most common findings include vascular dilatation and perivascular and perifollicular lymphocytic infiltrates

### Differential diagnosis

- Perioral dermatitis
- Acne vulgaris
- Folliculitis
- Sarcoidosis
- Discoid lupus erythematosus
- Papular granuloma annulare

### Treatment

- Topical antibiotics (e.g. metronidazole, clindamycin)
- Systemic antibiotics (e.g. erythromycin, tetracycline, doxycycline, minocycline)
- Discontinuation of topical steroids

### Prognosis

- Intermittent and chronic course

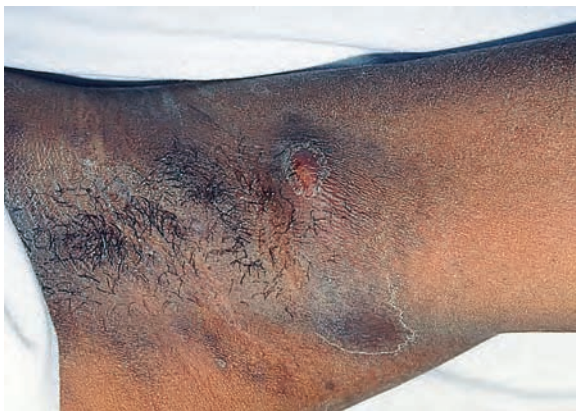### References

- Drolet B, Paller AS. Childhood rosacea. *Pediatr Dermatol* 1992; 9: 22–6
- Howard R, Tsuchiya A. Adult skin disease in the pediatric patient. *Dermatol Clin* 1998; 16: 593–608
- Morras PG, Santos SP, Imedio IL, et al. Rosacea-like demodicidosis in an immunocompromised child. *Pediatr Dermatol* 2003; 20: 28–30
- Weston WL, Morelli JG. Steroid rosacea in prepubertal children. *Arch Pediatr Adolesc Med* 2000; 154: 62–4

## Hidradenitis suppurativa

### Major points

- Chronic scarring disease of the apocrine glands that occurs after puberty
- Occurs in apocrine gland-bearing areas of the skin including the axillae, inframammary fold, inguinal area and anogenital region (Figure 5.12)
- More common in Blacks
- Male/female ratio <1
- Obesity is a predisposing factor
- Presents with tender, suppurative nodules and abscesses which heal with fibrosis leading to sinus tracts and bridging hypertrophic scars
- Associated with other follicular occlusion diseases: acne conglobata, dissecting cellulitis of the scalp, pilonidal cysts



**Figure 5.12** Hidradenitis suppurativa – with multiple draining cysts in the axilla

### Pathogenesis

- Disrupted keratinization with follicular hyperkeratosis and plugging of the apocrine duct leading to dilatation of the duct with perifolliculitis, abscess formation, destruction of the pilosebaceous unit ending in fibrosis
- Secondary bacterial infection can occur with staphylococci, streptococci and Gram-negative organisms

### Diagnosis

- Typical clinical presentation

### Differential diagnosis

- Furunculosis
- Lymphadenitis
- Keratinaceous cysts
- Ulcerative colitis

### Treatment

- Topical antibiotics
- Benzoyl peroxide preparations
- Systemic antibiotics
- Systemic retinoids
- Intralesional triamcinolone for inflamed lesions
- Excision of the affected area

### Prognosis

- Disease severity is variable
- Mild disease can remit with age
- Severe disease can be chronic with relapses and significant morbidity

### References

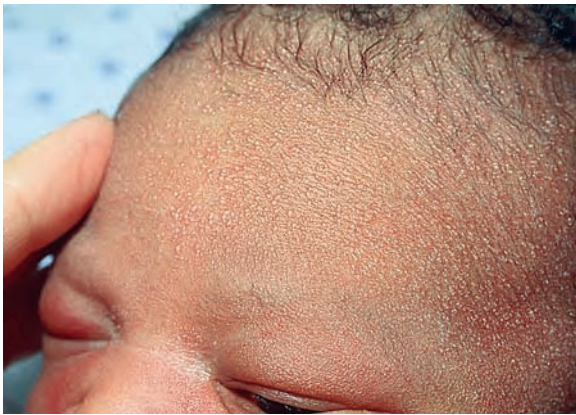- Adams DR, Gordon KB, Devenyi AG, Ioffreda MD. Severe hidradenitis suppurativa treated with infliximab infusion. *Arch Dermatol* 2003; 139: 1540–2
- Mengesha YM, Holcombe TC, Hansen RC. Prepubertal hidradenitis suppurativa: two case reports and review of the literature. *Pediatr Dermatol* 1999; 16: 292–6
- Palmer RA, Keefe M. Early-onset hidradenitis suppurativa. *Clin Exp Dermatol* 2001; 26: 501–3
- Slade DE, Powell BW, Mortimer PS. Hidradenitis suppurativa: pathogenesis and management. *Br J Plast Surg* 2003; 56: 451–61
- Wiseman MC. Hidradenitis suppurativa: a review. *Dermatol Ther* 2004; 17: 50–4



## Miliaria

### Major points

- Miliaria crystallina
  1. Presents as generalized small clear vesicles that are easily ruptured with no surrounding erythema (Figure 5.13)
  2. Accentuated in intertriginous areas
  3. Can be congenital or develop in the first few weeks of life
  4. Can follow sunburn

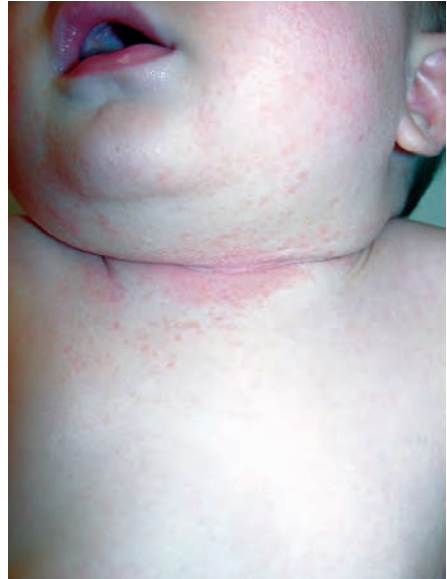

**Figure 5.13** Miliaria crystallina in a newborn from overheating

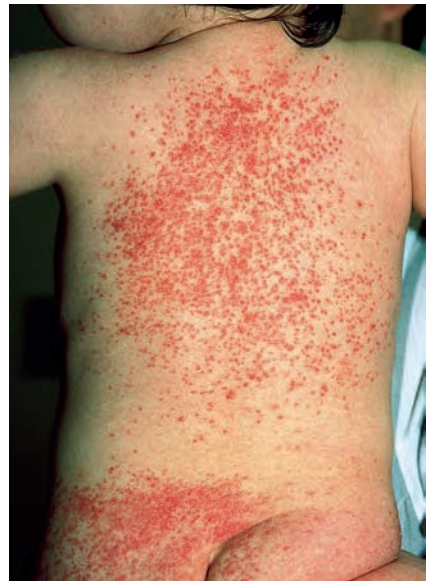- Miliaria rubra (prickly heat, heat rash)
  1. Common in febrile, overheated infants or in hot weather
  2. Presents with generalized 1–3 mm nonfollicular papules, vesicles and pustules with an erythematous base (Figures 5.14 and 5.15)
  3. Accentuated in intertriginous areas and in areas of occlusion
- Miliaria profunda
  1. Clinically appears as erythematous-based papules and pustules
  2. Can prevent adequate sweating leading to hyperthermia in older children

### Pathogenesis

- Caused by obstruction of the eccrine ducts that leads to retention of sweat in the skin
- Level of obstruction of the eccrine duct determines the clinical presentation



**Figure 5.14** Miliaria rubra – typical ‘prickly heat’ around the neck of a child in the summer



**Figure 5.15** Miliaria rubra/pustulosa – caused by lying in bed for several days with a febrile illness

1. Miliaria crystallina: subcorneal or intracorneal (superficial)
2. Miliaria rubra: intraepidermal



3. Miliaria profunda: at the dermal–epidermal junction
- Secondary inflammatory response can develop if there is deeper obstruction
- Questionable role of extracellular polysaccharide substance of *Staphylococcus epidermidis* causing duct occlusion

### Diagnosis

- Clinical findings
- Histologic findings:
  1. Miliaria crystallina: intra- or subcorneal vesicles that contain few neutrophils
  2. Miliaria rubra: spongiosis and spongiotic vesicles with surrounding lymphocytic infiltrate; variable papillary dermal edema; can have amorphous casts that are PAS-positive within the intraepidermal sweat duct
  3. Miliaria profunda: similar to miliaria rubra with subepidermal vesiculation and deeper inflammation involving the lower epidermis and upper dermis

### Differential diagnosis

- Neonatal acne
- Neonatal infections: *Candida*, *Staphylococcus* and herpes simplex

### Treatment

- Limit bundling of infants; recommend light-weight clothing
- Cooler ambient temperatures; air-conditioning
- Cool baths
- Avoidance of excessive heat and occlusion

### Prognosis

- Lesions resolve spontaneously with avoidance of overheating
- Obstruction of sweat ducts in miliaria profunda can lead to hyperthermia and heat stroke

### References

- Feng E, Janniger CK. Miliaria. *Cutis* 1995; 55: 213–16
- Gan VN, Hoang MP. Generalized vesicular eruption in a newborn. *Pediatr Dermatol* 2004; 21: 171–3
- Mowad CM, McGinley KJ, Foglia A, Leyden JJ. The role of extracellular polysaccharide substance produced by *Staphylococcus epidermidis* in miliaria. *J Am Acad Dermatol* 1995; 33: 729–33

Sellheyer K, Medenica M, Stein SL. Vesicular eruption on the trunk and in intertriginous folds. *Arch Dermatol* 2004; 140: 231–6

Van Praag MC, Van Rooij RW, Folkers E, et al. Diagnosis and treatment of pustular disorders in the neonate. *Pediatr Dermatol* 1997; 14: 131–43

Wenzel FG, Horn TD. Nonneoplastic disorders of the eccrine glands. *J Am Acad Dermatol* 1998; 38: 1–17

## Hyperhidrosis

### Major points

- Sweating beyond what is necessary to maintain thermal regulation
- May be primary (idiopathic, essential) or secondary to diseases or drugs
- May be localized, regionalized or generalized
- Frequently socially embarrassing and occupationally disabling
- Generalized hyperhidrosis caused by febrile illnesses, neoplastic disease, neurologic diseases, metabolic disorders and drugs
- Localized hyperhidrosis includes primary or focal hyperhidrosis, unilateral circumscribed, intrathoracic neoplasms, olfactory hyperhidrosis, gustatory hyperhidrosis, spinal cord injuries, Frey syndrome and others

### Pathogenesis

- Eccrine sweat glands assist in maintenance of body temperature in response to heat exposure or exercise as a function of the sympathetic nervous system
- Sweat glands are innervated by sympathetic postganglionic fibers mediated by acetylcholine
- Stimuli include thermal or emotional stimuli (more common on palms, soles and forehead)

### Diagnosis

- Clinical findings

### Differential diagnosis

- Miliaria

### Treatment

- Aluminum chloride (Drysol® 20%)
- Anti-anxiety medications: diazepam (Valium®), fluoxetine (Prozac®)
- Systemic anticholinergic agents: Robinul®

- Iontophoresis
- Botulinum toxin (Botox<sup>®</sup>)
- Surgical excision of axilla eccrine/apocrine glands
- Sympathectomy

### *Prognosis*

- Usually lifelong
- May improve in middle age

### *Reference*

Stolman LP. Treatment of hyperhidrosis. J Drugs Dermatol 2003; 2: 521–7

# BULLOUS DISORDERS

---

## GENERAL

- Blisters in children are generally caused by:
  1. Acute eczematous dermatitis (e.g. contact dermatitis)
  2. Viral infections (e.g. herpes simplex)
  3. Bacterial infections (e.g. bullous impetigo)
  4. Mechanobullous genetic diseases (e.g. epidermolysis bullosa)
  5. Immunobullous disorders (e.g. chronic bullous dermatosis of childhood)
- When taking a history, it is important to determine whether trauma played a role in blister formation, and when the blisters began. This helps distinguish the mechanobullous disorders (genetic blistering disorders which usually start at birth) from acquired blistering disorders
- Although most blisters are fragile and break spontaneously, blisters on the palms and soles have a thick stratum corneum covering and may appear deeper and not rupture
- Blisters in the mouth are superficial and do not stay intact long, because of the lack of stratum corneum in the oral mucosa

## IMMUNOBULLOUS DISORDERS

### General

- Immunobullous diseases in childhood are uncommon but should be considered if the blistering condition has been persistent for longer than a month, particularly if unresponsive to antibiotic therapy

- Characterized by the presence of autoantibodies to components of the skin
- Diagnosis is made by correlating the histologic findings with the direct immunofluorescence (DIF)
- Blisters may appear flaccid, tense or may present as erosions

### References

- Fine J-D. Management of acquired bullous skin diseases. *N Engl J Med* 1995; 333: 1475–84
- Weston WL, Morelli JG, Huff JC. Misdiagnosis, treatments, and outcomes in the immunobullous diseases in children. *Pediatr Dermatol* 1997; 14: 264–72

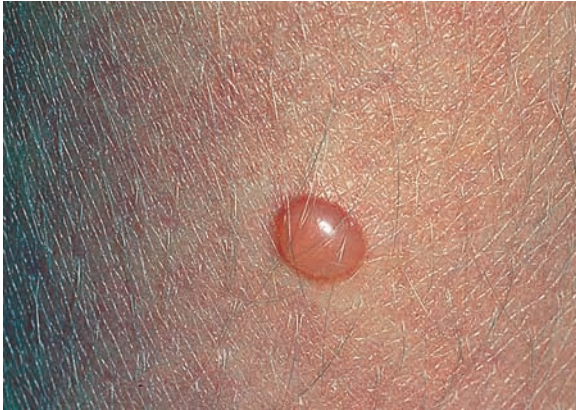## Pemphigus

### General

- Autoimmune blistering disease of the skin and mucous membranes with intraepidermal blisters, acantholysis and circulating IgG directed against cell surfaces of keratinocytes
- Four major types: pemphigus vulgaris, pemphigus foliaceus, paraneoplastic pemphigus and fogo selvagem
- Very rare in childhood

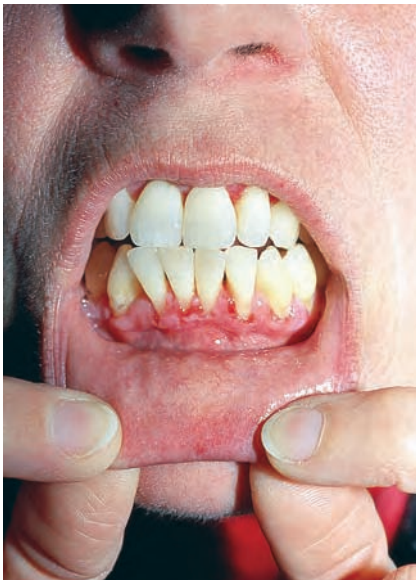### Major points

- Pemphigus vulgaris (PV)
  1. Blisters occur in lower epidermis, just above the basal layer
  2. Painful fragile flaccid blisters occur anywhere on the body, and arise on normal or erythematous skin (Figure 6.1)
  3. Intact blisters are sparse; erosions are common



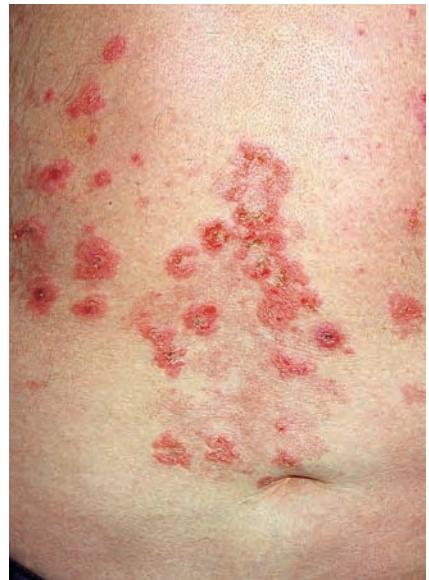**Figure 6.1** Pemphigus vulgaris – in an 11-year-old girl

4. Nikolsky sign is positive (application of lateral pressure to the periphery of an active lesion causing extension of the blister)
5. Excessive granulation tissue may be seen in intertriginous areas, on scalp or face
6. Mucous membrane lesions (particularly in the mouth) occur prior to skin involvement and affect the majority of patients (Figure 6.2)
7. Erosions may involve the pharynx or the larynx, causing hoarseness
8. Associations: myasthenia gravis and/or thymoma



**Figure 6.2** Pemphigus vulgaris – in a young adult with erosions in the mouth

9. Antigen is desmoglein 3
- Neonatal pemphigus displays clinical, histologic, and immunopathologic signs of PV
    1. Neonatal PV occurs when maternal IgG crosses the placenta, causing disease in the neonate
    2. Remits when maternal antibodies decrease (~6–12 months)
    3. May be mild or severe
  - Pemphigus foliaceus (PF) (superficial pemphigus)
    1. Superficial blisters occur in granular layer
    2. Scaly, crusted erosions, often on an erythematous base, located in seborrheic distribution (face, scalp, upper trunk) (Figure 6.3)
    3. Primary lesions: small flaccid blisters which are painful or burn
    4. Disease may stay localized for years or progress rapidly to exfoliative erythroderma
    5. Sun and heat may exacerbate
    6. Oral lesions rare
    7. Antigen is desmoglein 1
  - Fogo selvagem (endemic pemphigus foliaceus)
    1. Endemic in rural Brazil
    2. Affects children <14 years in 25% of cases, two-thirds are <30 years old
    3. Occurs along inland river beds where black fly *Simulium nigrimanum* is endemic
  - Pemphigus erythematosus



**Figure 6.3** Pemphigus foliaceus – in a young adult

1. Localized variant of pemphigus foliaceus, usually on face, associated with lupus erythematosus
- Paraneoplastic pemphigus
  1. Very rare in childhood
  2. Associated with neoplasms mainly of lymphoid tissue (e.g. leukemia, lymphoma, thymoma, benign lymphoid tumors)
  3. DIF shows IgG and C3 in between keratinocytes and linear or granular pattern along the basement membrane zone (BMZ)
  4. Indirect immunofluorescence is positive in other desmosome-containing tissues
  5. Clinical:
    - a. Severe oral and conjunctival erosions with erythematous blistering
    - b. Polymorphic lesions with blisters and erosions, may resemble erythema multiforme (Figure 6.4)
- Drug-induced pemphigus can be caused by penicillamine or captopril, and resolves when medicine stopped; DIF positive; antigen is desmoglein 3

### Pathogenesis

- IgG autoantibodies are directed against desmosomes in epidermis, interfering with calcium-sensitive adhesional function. Acantholysis is in areas of deposition of IgG (See Table 6.1)

### Diagnosis

- DIF is positive for IgG on the cell surfaces of keratinocytes in perilesional skin
- In PV and pemphigus foliaceus (PF), 75% will have circulating antiepithelial cell surface IgG found on indirect immunofluorescence
- Correlation between titer of circulating anti-cell surface antibodies and disease activity
- Histology:
  1. PV shows suprabasilar blister with acantholysis, leaving a 'row of tombstones' where basal cells stay attached to the basement membrane by hemidesmosomes
  2. PF shows acantholysis in the granular layer
  3. Paraneoplastic pemphigus shows a combination of PV and erythema multiforme-like histology

### Differential diagnosis

- Bullous pemphigoid
- Bullous insect bite reactions

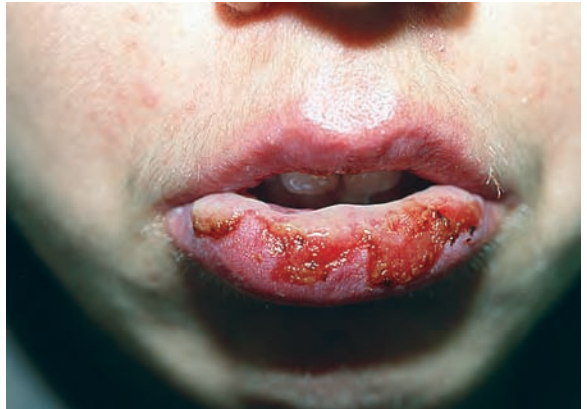- Chronic bullous disease of childhood
- Staphylococcal scalded skin syndrome
- Stevens–Johnson syndrome

### Treatment

- Prednisone 1–2 mg/kg per day until activity is suppressed. Once under control, steroids should be tapered to avoid side-effects
- Steroid-sparing agents can be used as an adjunct: cyclophosphamide, azathioprine, cyclosporine, methotrexate, or gold
- High-potency topical steroids might be helpful for localized disease
- Intravenous immunoglobulins (IVIG) may be a promising therapy

### Prognosis

- Pemphigus has significant morbidity and mortality
- Infection is often the cause of death in adults
- Prognosis without treatment is poor



**Figure 6.4** Paraneoplastic pemphigus – with extensive mouth involvement in an adult

### References

- Bystryn JC, Steinman NM. The adjuvant therapy of pemphigus. An update. *Arch Dermatol* 1996; 132: 203–12
- Harman KE, Albert S, Black MM. Guidelines for the management of pemphigus vulgaris. *Br J Dermatol* 2003; 149: 926–37
- Kanwar AJ, Dhar S, Kaur S. Further experience with pemphigus in children. *Pediatr Dermatol* 1994; 11: 107–11
- Lyde CB, Cox SE, Cruz PD. Pemphigus erythematosus in a five-year-old child. *J Am Acad Dermatol* 1994; 31: 906–9



**Table 6.1 Major immunobullous disorders**

<i>Disorder</i>	<i>Target antigen</i>	<i>Histology</i>	<i>DIF</i>
Pemphigus vulgaris	In desmosomes: Desmoglein 3 (130 kDa)	Suprabasilar acantholysis	IgG, C3 or both along keratinocyte surfaces
Neonatal pemphigus	Desmoglein 3 (130 kDa) Maternal IgG	Suprabasilar acantholysis	IgG, C3 or both along keratinocyte surfaces
Pemphigus foliaceus	Desmoglein 1 (160 kDa)	Granular cell layer acantholysis	IgG, C3 or both along keratinocyte surfaces
Fogo selvagem	Desmoglein 1 (160 kDa)	Granular cell layer acantholysis	IgG, C3 or both along keratinocyte surfaces
Pemphigus erythematosus	Desmoglein 1 (160 kDa)	Granular cell layer acantholysis	IgG, C3 or both along keratinocyte surfaces
Bullous pemphigoid	In hemidesmosomes: BPAG-1 (230 kDa) BPAG-2 (180 kDa)	Subepidermal blister with eosinophils	Linear IgG/ C3, IgA, IgM at BMZ
Pemphigoid gestationis	BPAG-2 (180 kDa)	Subepidermal blister (in lamina lucida)	IgG, C3 or both in linear pattern at BMZ
Dermatitis herpetiformis	Gliadin Tissue transglutaminase	Dermal papillary neutrophils; with subepidermal blister in lamina lucida	Granular IgA in dermal papillae
Chronic bullous disease of childhood	LABD, 97 kDa, others	Subepidermal bullae in lamina lucida with neutrophils	Linear IgA along BMZ
Paraneoplastic pemphigus	Desmoplakin 1 (250 kDa) Envoplakin (190 kDa) Periplakin (170 kDa) Desmoplakin 2 (210 kDa) BP antigen (230 kDa) Others	Suprabasilar acantholysis and lichenoid dermatitis	Linear granular IgG, C3 or both along keratinocyte surfaces and in BMZ
EB acquisita	Type 7 collagen (290 kDa and 145 kDa)	Subepidermal blister with neutrophils or cell poor infiltrate	IgG, C3 or others in linear pattern along BMZ

BMZ, basement membrane zone; DIF, direct immunofluorescence; IF, immunofluorescence; EB, epidermolysis bullosa

Prendiville JS, Israel DM, Wood WS, Dimmick JE. Oral pemphigus vulgaris associated with inflammatory bowel disease and herpetic gingivostomatitis in an 11-year-old girl. *Pediatr Dermatol* 1994; 11: 145–50

Rybojad M, Leblanc T, Flageul B, et al. Paraneoplastic pemphigus in a child with a T-cell lymphoblastic lymphoma. *Br J Dermatol* 1993; 128: 418–22

Stanley JR. Pemphigus. In Fitzpatrick's Dermatology in General Medicine, 6th edn. Freedberg IM Eisen AZ, Wolff K, Austen KF, eds. McGraw-Hill: New York, 2003: 558–67

Tope WD, Kamino H, Briggaman RA, et al. Neonatal pemphigus vulgaris in a child born to a woman in remission. *J Am Acad Dermatol* 1993; 29: 480–5

Walker DC, Kolar KA, Hebert AA, Jordan RE. Neonatal pemphigus foliaceus. *Arch Dermatol* 1995; 131: 1308–11

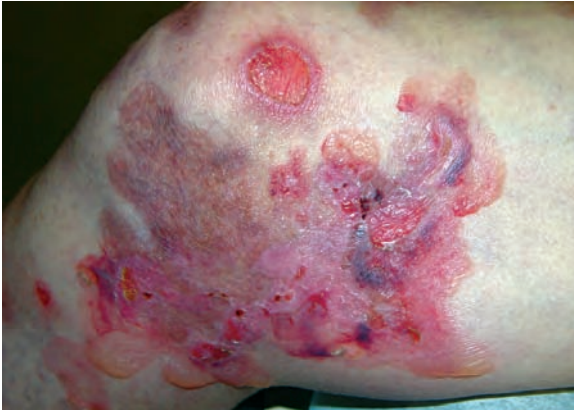Wanaukul S, Pongprasit P. Childhood pemphigus. *Int J Dermatol* 1999; 38: 29–35

Weston WL, Morelli JG, Huff JC. Misdiagnosis, treatments, and outcomes in the immunobullous diseases in children. *Pediatr Dermatol* 1997; 14: 264–72

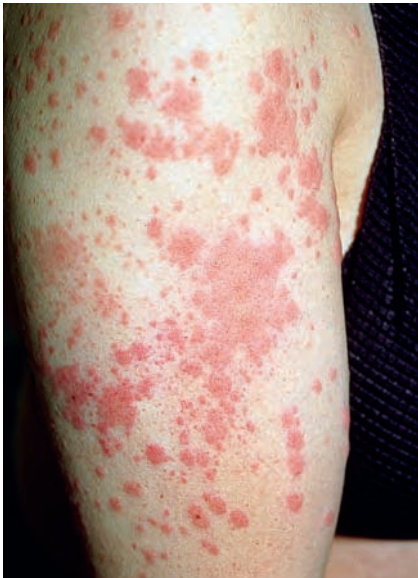## Bullous pemphigoid

### Major points

- Large, tense blisters arising on normal or erythematous skin
- Mucous membrane involvement in 10–35%
- Sites of predilection: lower abdomen, inner thighs, flexor forearms or generalized
- Bullae may have clear or hemorrhagic fluid (Figures 6.5 and 6.6)



**Figure 6.5** Bullous pemphigoid – large bullae on erythematous patches



**Figure 6.6** Pemphigoid gestationis – in a young pregnant woman. Her child was unaffected

- Erosions tend to re-epithelialize quickly
- Nikolsky sign is negative
- New vesicles may form at the edge of old blisters
- Blisters do not tend to scar but may be hyperpigmented
- Mild to moderate pruritus
- Early lesions tend to look urticarial
- Rare in childhood

### Pathogenesis

- Bullous pemphigoid (BP) antigens are proteins in the hemidesmosomes (HDs). Autoantibody binds both inside the cell to plaques of HDs and outside cells to the extracellular section of HDs
- BP antibodies are directed against both BPAg-1 (230 kDa) component and also BPAg-2 (180 kDa) (also called type XVII collagen)
- BP IgG can activate complement by the classical pathway causing leukocyte adherence to the basement membrane, degranulation of polymorphonuclear leukocytes and subsequent dermal–epidermal separation

### Diagnosis

- Histology: subepidermal blister without necrosis, and superficial dermal infiltrate with lymphocytes, histiocytes and eosinophils
- DIF: linear pattern of C3 and IgG at BMZ
- Indirect immunofluorescence: 70–80% of patients will have circulating IgG which binds to stratified squamous epithelium; titers do not correlate with disease extent or activity
- ~50% have elevated IgE, and sometimes eosinophilia, which correlates with pruritus

### Differential diagnosis

- Bullous insect bite reactions
- Bullous impetigo
- Bullous erythema multiforme
- Chronic bullous disease of childhood

### Treatment

- Prednisone 1–2 mg/kg per day until activity is suppressed. Once under control, steroids should be tapered to avoid side-effects
- Steroid-sparing agents can be used as an adjunct: cyclophosphamide, azathioprine, cyclosporine, methotrexate, or gold

- Localized BP can be treated with high-potency topical steroids
- Some patients respond to sulfones, tetracycline, or nicotinamide

### Prognosis

- BP may be self-limited and can last several months to many years
- Prognosis is good. In adults, half of treated patients go into remission in 2.5–6 years

### References

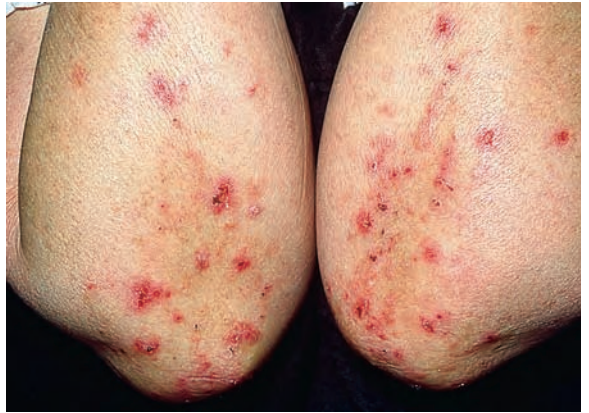- Chimanovitch I, Hamm H, Georgi M, et al. Bullous pemphigoid of childhood. *Arch Dermatol* 2000; 136: 527–32
- Kuenzli S, Grimaitre M, Krischer J, et al. Childhood bullous pemphigoid: report of a case with life-threatening course during homeopathy treatment. *Pediatr Dermatol* 2004; 21: 160–3
- Nagano T, Tani M, Adachi A, et al. Childhood bullous pemphigoid: immunohistochemical, immunoelectron microscopic, and Western blot analysis. *J Am Acad Dermatol* 1994; 30: 884–8
- Nemeth AJ, Klein AD, Gould EW, Schachner LA. Childhood bullous pemphigoid: clinical and immunologic features, treatment and prognosis. *Arch Dermatol* 1991; 127: 378–86
- Oranje AP, Vuzevski VD, van Joost T, et al. Bullous pemphigoid in children. *Int J Dermatol* 1991; 30: 339–42
- Petronius D, Bergman R. Bullous pemphigoid in two young infants. *Pediatr Dermatol* 2002; 19: 119–21
- Stanley JR. Bullous pemphigoid. In Fitzpatrick's *Dermatology in General Medicine*, 6th edn. Freedberg IM, Eisen AZ, Wolff K, Austen KF, eds. McGraw-Hill: New York, 2003: 574–81
- Trüeb RM, Didierjean L, Fellas A, et al. Childhood bullous pemphigoid: report of a case with characterization of the targeted antigens. *J Am Acad Dermatol* 1999; 40:338–44
- Vaillant L, Bernard P, Joly P, et al. Evaluation of clinical criteria for diagnosis of bullous pemphigoid. *Arch Dermatol* 1998; 134: 1075–80
- Weston WL, Morelli JG, Huff JC. Misdiagnosis, treatments, and outcomes in the immunobullous diseases in children. *Pediatr Dermatol* 1997; 14: 264–72

## Dermatitis herpetiformis

### Major points

- Most common immunobullous disease in children

- Characterized by intensely pruritic chronic small papules and vesicles located symmetrically over extensor surfaces (elbows, knees, upper spine), scalp hairline and posterior nuchal area (Figure 6.7)



**Figure 6.7** Dermatitis herpetiformis – typical excoriated lesions on extensor surfaces

- Primary lesions: erythematous papules, urticarial plaques or vesicles, but crusted lesions are frequently the only lesions seen. Large bullae infrequent
- Mucous membrane involvement is uncommon
- Onset is usually in adolescence or later
- Most have gastrointestinal (GI) abnormality similar to celiac disease (villous atrophy of the small intestine) but are asymptomatic
- About 80% of patients have HLA-B8 and DR3
- Lesions can be exacerbated by gluten or oral iodides
- Sometimes associated with GI lymphomas, or autoimmune disease (e.g. thyroid disease, diabetes, lupus erythematosus, Sjögren syndrome, or vitiligo)

### Pathogenesis

- Gluten plays a critical role
- IgA deposits may be complexes of immunoglobulins and GI-derived antigens which react with an unidentified skin antigen
- IgA is found in all skin sites, not just lesional skin
- IgA activates complement, probably via the alternative pathway, causing chemotaxis of neutrophils which release enzymes causing blistering. Cytokines or proteases that induce basal keratinocytes to produce collagenases or stromelysin-1 contribute to blister formation

### Diagnosis

- Histology: dermal papillary collections of neutrophils. Blood vessels are surrounded by lymphohistiocytic infiltrates with neutrophils and eosinophils
- Blister formation is within lamina lucida of the BMZ, and above lamina densa
- DIF shows granular IgA deposits (subclass IgA1) in dermal papillary tips in normal appearing skin; frequently, C3 is seen
- Antireticulin antibodies of IgA and IgG classes can be detected in the majority of patients
- Circulating IgA autoantibodies to endomysium (EMA), tissue transglutaminase (tTG) and gliadin are detected in both dermatitis herpetiformis and celiac disease

### Differential diagnosis

- Scabies
- Eczema
- Impetigo
- Pityriasis lichenoides
- Erythema multiforme
- Bullous drug reaction
- Factitial excoriations
- Bullous pemphigoid
- Bullous insect bite reactions
- Chronic bullous disease of childhood
- Pemphigus vulgaris

### Treatment

- Dapsone 2 mg/kg per day, adult dose 100–150 mg/day
- Sulfapyridine 1–4 g/day given four times a day for an adult
- Gluten-free diet may be effective; may take >5 months to 1 year to see an effect

### Prognosis

- Lifelong disorder, persisting indefinitely with varying severity

### References

Bardella MT, Fredella C, Trovato C, et al. Long-term remission in patients with dermatitis herpetiformis on a normal diet. *Br J Dermatol* 2003; 149: 968–71

Caproni M, Cardinali C, Renzi D, et al. Tissue transglutaminase antibody assessment in dermatitis herpetiformis [Letter]. *Br J Dermatol* 2001; 144: 196–7

Chorzelski TP, Rosinska D, Beutner EH, et al. Aggressive gluten challenge of dermatitis herpetiformis cases converts them from seronegative to seropositive for IgA-class endomysial antibodies. *J Am Acad Dermatol* 1988; 18: 672–8

Ermacora E, Prampolini L, Tribbia G, et al. Long-term follow-up of dermatitis herpetiformis in children. *J Am Acad Dermatol* 1986; 15: 24–30

Weston WL, Morelli JG, Huff JC. Misdiagnosis, treatments, and outcomes in the immunobullous diseases in children. *Pediatr Dermatol* 1997; 14: 264–72

Zone JJ, Meyer LJ, Petersen MJ. Deposition of granular IgA relative to clinical lesions in dermatitis herpetiformis. *Arch Dermatol* 1996; 132: 912–18

### Chronic bullous disease of childhood (linear IgA dermatosis)

#### Major points

- Presents as blisters which resemble bullous impetigo unresponsive to antibiotics
- Second most common immunobullous disease in childhood
- Typically presents in children <5 years of age with large tense bullae or vesicles on an erythematous base in the diaper area, face and other areas (Figures 6.8–6.10)
- Lesions are symmetrical and pruritic
- Numerous crusted vesicles or a ‘cluster of jewels’ appearance with new lesions appearing around the periphery of previous lesions
- Mucous membranes involved in up to 70% of cases, ranging from asymptomatic oral ulcerations to severe disease

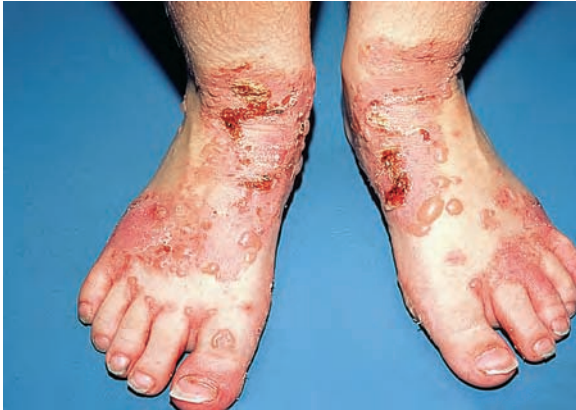#### Pathogenesis

- Caused by linear deposition of IgA to 97-kDa antigen among others in lamina lucida of BMZ, which incites inflammation and destruction of the epidermal–dermal barrier
- Associations:
  1. Drugs: vancomycin, lithium, diclofenac
  2. Lymphoid and nonlymphoid malignancies

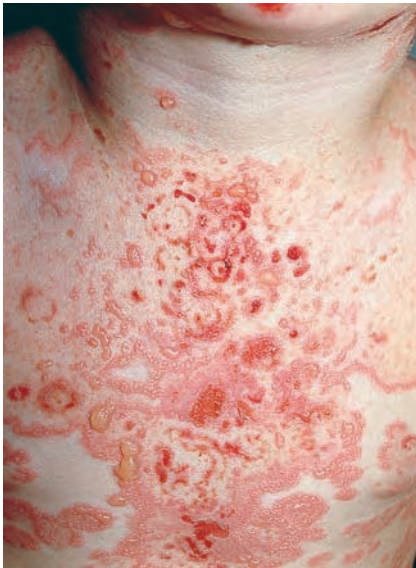#### Diagnosis

- Diagnosis is usually overlooked initially, because of the rarity of this disease and its confusion with bullous impetigo



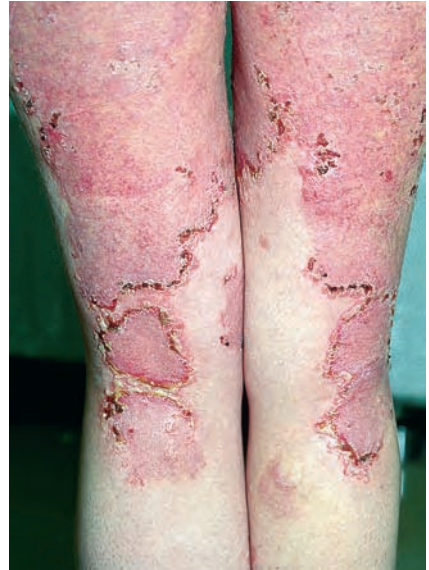

**Figure 6.8** Chronic bullous dermatosis of childhood – typical ringed blisters on the feet



**Figure 6.9** Chronic bullous dermatosis of childhood – extensive involvement of the trunk

- Histology:
  1. Biopsies should be taken in skin adjacent to a blister, not an old blister or crusted lesion
  2. Subepidermal bulla with neutrophils along the BMZ, often in papillary tips. Lymphocytic infiltrate may be present around superficial dermal blood vessels without vasculitis
- DIF: IgA in a homogeneous linear pattern along BMZ; occasional IgG and C3
  1. Three patterns of IgA deposition (found on electron microscopy): in lamina lucida (similar



**Figure 6.10** Linear IgA bullous dermatosis – typical blisters along the edge of healed blisters

to BP); at or below lamina densa (similar to epidermolysis bullosa acquisita); both above and below lamina densa

- Low titer IgA serum autoantibodies can sometimes be detected

#### *Differential diagnosis*

- Bullous impetigo
- Pemphigus
- Bullous pemphigoid
- Epidermolysis bullosa
- Erythema multiforme
- Bullous systemic lupus erythematosus

#### *Treatment*

- Dapsone 2 mg/kg per day
- Prednisone 1–2 mg/kg per day
- Most cases respond to combination of prednisone and dapsone
- Topical antibiotics and nonstick gauze covering if lesions are oozing or crusted
- Patients do not benefit from gluten-free diet
- Other drugs which may be beneficial: dicloxacillin, colchicine, sulfapyridine

#### *Prognosis*

- Usually lasts several years and then remits. Occasionally, persists into puberty but is less severe



- Oral medications can be tapered as child improves, and then discontinued when totally clear of lesions for 6 months

### References

- Legrain V, Taïeb A, Surlève-Bazeille J-E, et al. Linear IgA dermatosis of childhood: case report with an immunoelectron microscopic study. *Pediatr Dermatol* 1991; 8: 310–13
- Powell J, Kirtschig G, Allen J, et al. Mixed immunobullous disease of childhood: a good response to antimicrobials. *Br J Dermatol* 2001; 144: 769–74
- Rao CL, Hall RP. Linear IgA dermatosis and chronic bullous disease of childhood. In *Fitzpatrick's Dermatology in General Medicine*, 6th edn. Freedberg IM, Eisen AZ, Wolff K, Austen KF, eds. McGraw-Hill: New York, 2003: 587–92
- Siegfried EC, Sirawan S. Chronic bullous disease of childhood: successful treatment with dicloxacillin. *J Am Acad Dermatol* 1998; 39: 797–800
- Wojnarowska F. Chronic bullous disease of childhood. *Semin Dermatol* 1988; 7: 58–65
- Zone JJ, Taylor TB, Kadunce DP, et al. IgA antibodies in chronic bullous disease of childhood react with a 97 kDa basement membrane zone protein. *J Invest Dermatol* 1996; 106: 1277–80

## EPIDERMOLYSIS BULLOSA

### General

- Epidermolysis bullosa (EB) is a group of genetic diseases where mild trauma induces blister formation

- At least 18 distinct types, based on identification of mutations in various genes encoding proteins and clinical symptoms (Table 6.2)

### Major points

- In general, EB is divided into scarring (dystrophic) and nonscarring (simplex and junctional) types
- Nonscarring types demonstrate an intraepidermal separation (EB simplex) or a separation at the dermal–epidermal junction (junctional EB)
- Scarring types: subepidermal blisters are found in dystrophic EB
- Usually presents in newborn period with blisters and erosions. Extensive blistering may be potentially life-threatening to newborns

### Pathogenesis

- Defects associated with anchoring complexes along the basal cell layer and dermal–epidermal BMZ determine the type of EB
- Gene mutations (See Table 6.2)

### Diagnosis

- Diagnosis is established by clinical symptoms and skin biopsy. Electron microscopy is the gold standard. Gene mutation can be identified
- Biopsy of an infant may be difficult
  1. Induce a blister with gentle traction with a cotton-tipped applicator
  2. Shave biopsy, gentle punch biopsy or excisional biopsy should include both epidermis and dermis

**Table 6.2 Common types of epidermolysis bullosa**

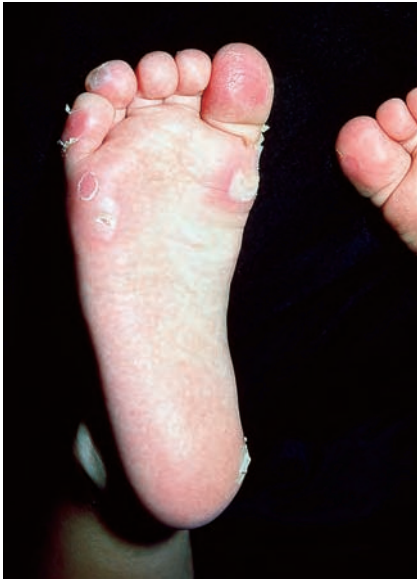Type gene	Mutations	Locations
<b>Simplex</b>		
Weber–Cockayne type	Keratins 5, 14	Hands, feet
Koebner type	Keratins 5, 14	Generalized
Dowling–Meara type	Keratins 5, 14	Generalized
<b>Junctional</b>		
Herlitz type	Laminin-5	Generalized, laryngeal
Generalized atrophic benign type	Type 17 collagen or Laminin A3, B3	Generalized
With pyloric atresia	$\alpha_6\beta_4$ integrin	Generalized, laryngeal, pylorus
<b>Dystrophic</b>		
Recessive type	Type 7 collagen	Generalized
Dominant types	Type 7 collagen	Generalized

3. Avoid old blisters because secondary changes occur with re-epithelization
4. Specimen should be sent for light and electron microscopic examination as well as immunofluorescence mapping

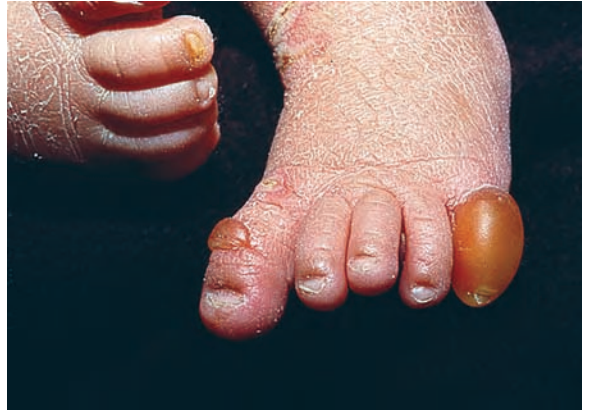## Epidermolysis bullosa simplex

### Major points

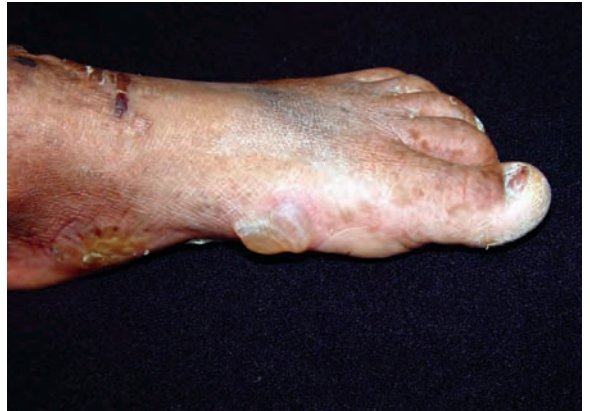- Weber–Cockayne type (localized EB simplex)
  1. Most common form of EB
  2. Localized to hands and feet (Figure 6.11)
  3. Aggravated by warm weather
  4. Begins in childhood or adolescence
  5. Hyperhidrosis common
- Generalized EB simplex (Koebner type)
  1. Presents with generalized blistering within first 12 months of life (Figures 6.12–6.14)
  2. Blisters tend to be more common on distal extremities, especially the feet, knees, elbows and hands
  3. Palmoplantar keratoses
- EB herpetiformis (Dowling–Meara type) (Figure 6.15)
  1. Generalized with pronounced oral mucosa involvement (Figure 6.11)



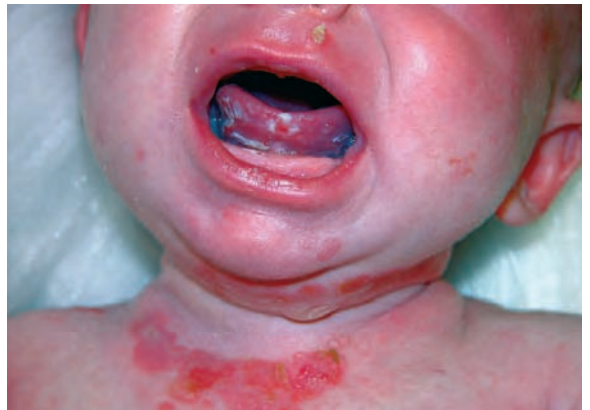**Figure 6.11** Epidermolysis bullosa simplex (Weber–Cockayne type) localized to hands and feet



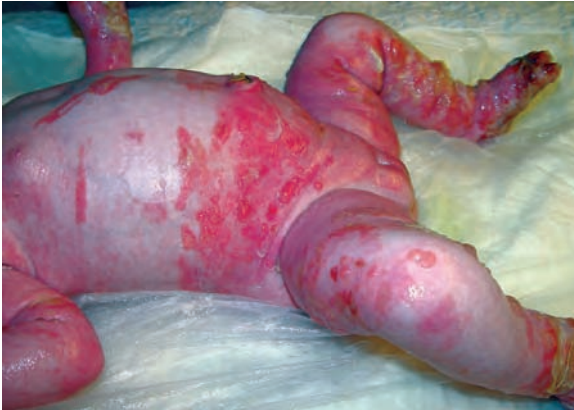**Figure 6.12** Epidermolysis bullosa simplex – typical tense blisters in a neonate



**Figure 6.13** Epidermolysis bullosa simplex – same child as in Figure 6.12, age 6 years



**Figure 6.14** Epidermolysis bullosa simplex – mouth involvement causing difficulty feeding



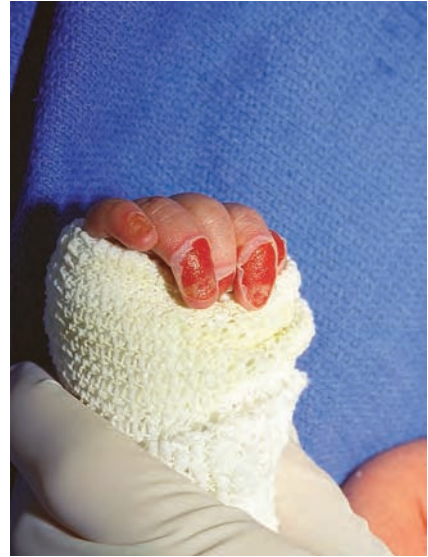**Figure 6.15** Epidermolysis bullosa simplex, Dowling-Meara type, severe generalized blistering in the neonatal period

2. Blisters are grouped
3. Nails may be shed and regrow
4. Hyperkeratosis of palms and soles

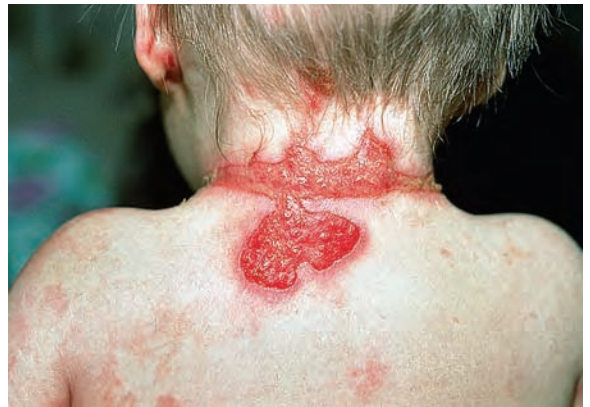## Junctional epidermolysis bullosa

### Major points

- Two major forms of junctional EB, although other subtypes exist
- Herlitz type
  1. Severe form usually fatal before the age of 5 years
  2. Blisters appear in the neonatal period
  3. Oral mucosa is usually affected, causing failure to thrive from poor nutrition
  4. Laryngeal involvement is common; may present with hoarse cry
  5. Nonhealing granulation tissue (mid-face, neck, spine, ears and nail beds) is characteristic (Figures 6.16 and 6.17)
  6. Enamel dysplasia
  7. Bacterial infection occurs frequently
  8. Nails usually lost
  9. Respiratory, GI and genitourinary systems can be involved
  10. Growth retardation
  11. Anemia
- Mitis junctional EB
  1. Mild but chronic ulcerations with poor healing, which may improve with age
  2. Hoarseness mild or absent



**Figure 6.16** Junctional type epidermolysis bullosa – typical granulation tissue on the fingertips



**Figure 6.17** Junctional epidermolysis bullosa – typical chronic nonhealing granulation tissue around the neck

3. Periorificial nonhealing erosions common
4. Enamel dysplasia
5. Scalp and nail lesions prominent
6. Atrophic scarring
- Generalized atrophic benign EB
  1. Generalized involvement
  2. Bullae on extremities and fewer on trunk, scalp and face
  3. Alopecia
  4. Mucous membrane involvement mild
  5. Enamel defects
  6. Normal lifespan

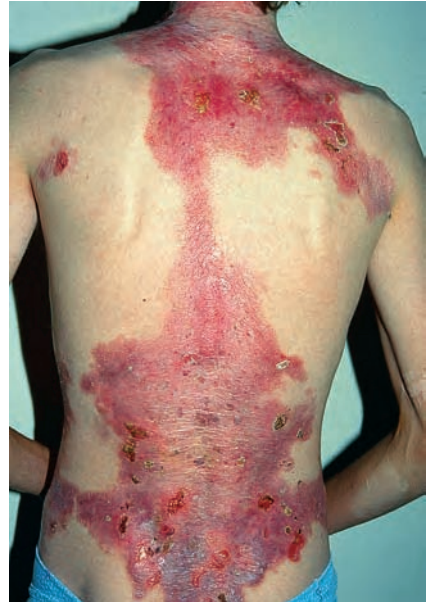

## Dystrophic epidermolysis bullosa

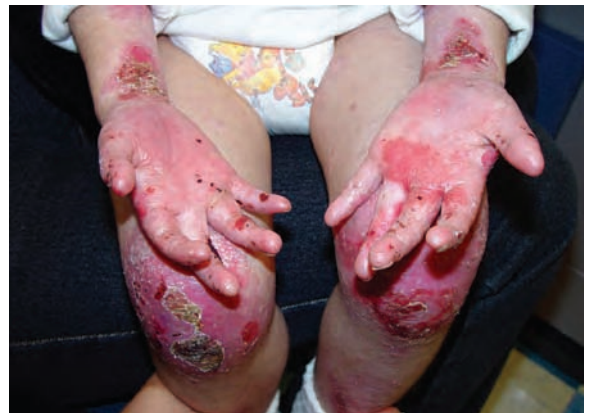- Recessive dystrophic EB of Hallopeau–Siemens
  1. Lesions heal with scar formation and milia (tiny white cysts within the scars)
  2. Scarring results in loss of nails; webbing of fingers and toes leads to mitten-like appearance; flexion contractures common (Figures 6.18–6.20)
  3. Scarring in scalp causing alopecia
  4. Eyelid involvement can lead to blindness
  5. Bullae of oral mucosa can cause pain and severe restriction in eating
  6. Blisters of esophagus can cause esophageal strictures resulting in dysphagia
  7. Vagina, urethra and anus can be involved with blistering and stricture
  8. Although teeth are usually normal, they often become carious because of difficulty with oral hygiene
  9. Mixed anemia from chronic blood loss and malnutrition occur in childhood
  10. Failure to thrive is common with growth retardation
  11. Secondary bacterial infection frequent
  12. Aggressive squamous cell carcinoma commonly arises in poorly healed atrophic areas in adolescence or early adulthood – usually fatal
- Dominant dystrophic EB of Cockayne–Touraine type
  1. Blisters are similar to recessive dystrophic EB but generally not as severe, usually acral
  2. Babies may be born with erosions secondary to intrauterine blister formation
  3. Atrophic scars with milia (Figures 6.21 and 6.22)
  4. Loss of nails may occur, but no webbing of fingers and toes
  5. Failure to thrive and chronic anemia rare
  6. Oral lesions uncommon
  7. Teeth normal
- Dominant dystrophic EB of Pasini
  1. Hypopigmented atrophic lesions (called albopapuloid lesions) in symmetrical pattern
  2. Dystrophic nails common
  3. Mucous membranes and teeth normal

### Pathogenesis

- Gene mutations of major structural proteins are known to cause the different types of EB (see Table 6.2)



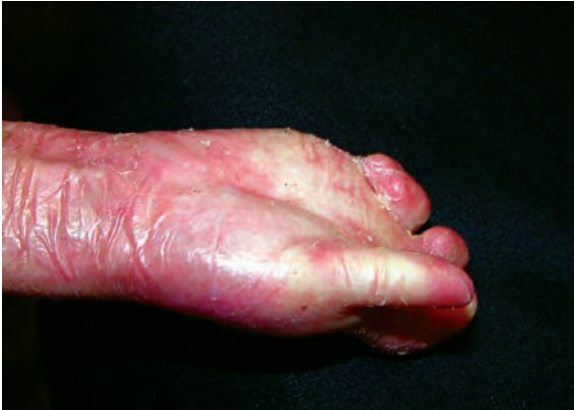**Figure 6.18** Recessive dystrophic type epidermolysis bullosa – scarring and chronic blistering in a teenager



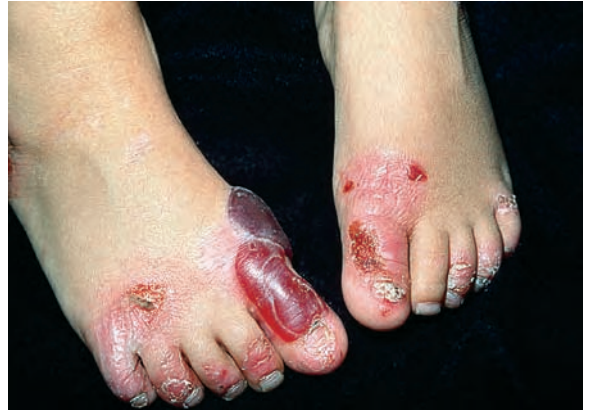**Figure 6.19** Recessive dystrophic epidermolysis bullosa with severe involvement on extremities

### Diagnosis

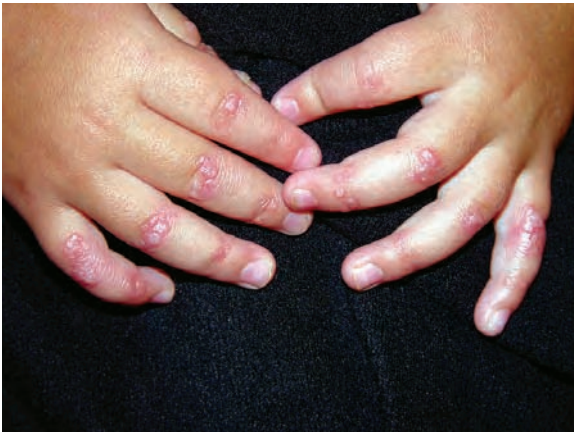- Skin biopsy (light microscopy, electron microscopy) as well as a molecular genetic analysis can differentiate the types of EB
- Electron microscopy: blister formation in EB simplex is found within epidermal cells above basal cell layer
- In junctional EB, blister formation occurs within the lamina lucida, just below the plasma



**Figure 6.20** Dystrophic epidermolysis bullosa – mitten deformity of the hand



**Figure 6.22** Dominant dystrophic type epidermolysis bullosa – blistering at the site of trauma



**Figure 6.21** Dominant dystrophic epidermolysis bullosa with residual milia and scarring on the hands

membrane of basal cells and above the lamina densa

- Dystrophic EB demonstrates a separation within anchoring fibrils below the basal lamina within the dermis
- Genetic analysis may be required if combination of clinical signs and electron microscopy is not conclusive

#### *Differential diagnosis*

- Bacterial infections (e.g. bullous impetigo, staphylococcal, streptococcal)
- Fungal infections (e.g. *Candida* infection)
- Viral infections (e.g. herpes simplex)
- Epidermolytic hyperkeratosis

- Erythema multiforme
- Immunobullous diseases (e.g. pemphigus)

#### *Treatment*

- Supportive with avoidance of trauma and wound management
- Physician with knowledge of EB is the best source for a comprehensive care program including skilled nursing
- Nutritional support: frequent feedings with soft nipples; may require G-tube placement
- Gentle handling: avoid clothing or devices which might injure skin
- Sheep-skin pad in crib and car seat softens friction
- Blisters should be opened with a sterile needle or scissors and roof allowed to remain intact by gently pressing out of blister fluid, leaving a 'biologic bandage'
- Topical antibiotics (e.g. bacitracin or mupirocin) can help prevent secondary bacterial infection
- Most patients, especially young children, benefit from gauze wrapping
- Care should be given to wrap the fingers individually in recessive dystrophic EB in order to prevent webbing of fingers
- Physical therapy can help prevent contractures
- Cool ambient temperature may help decrease blistering
- Wound dressings such as hydrophilic dressings, occlusive dressings and hydrogel dressings (e.g. Exudry®, Omniderm®, Vigilon®, DuoDerm®, Mepitel®) may aid in healing and reduce pain. Be careful not to pull dressings off forcefully



- Protein and caloric requirements may be twice normal. Extra calories should be encouraged with nutritional supplements or even gastric buttons
- Anemia: vitamin supplements and iron
- Constipation: high-fiber foods, stool softeners or mineral oil may help prevent rectal blistering
- Genetic counseling: chorionic villus sampling sent for prenatal diagnosis if gene defect is known
- Surgical release of fused digits followed by grafting and splinting
- Support group: D.E.B.R.A. of America, Inc.  
Internet address: [www.DEBRA.org](http://www.DEBRA.org)

### Prognosis

- Lifelong, chronic, blistering disorder
- EB simplex tends to improve with age, perhaps because older children and adults learn how to avoid blisters
- Recessive dystrophic EB tends to be slowly progressive, with further destruction of skin, including fingernails, web spaces and, in most severe cases, causing mitten deformities of hands

### References

- Eady RA, McGrath JA, McMillan JR. Ultrastructural clues to genetic disorders of skin: the dermal-epidermal junction. *J Invest Dermatol* 1994; 103: 13S–18S
- Fine JD. Skin bioequivalents and their role in the treatment of inherited epidermolysis bullosa. *Arch Dermatol* 2000; 136: 1259–60
- Livingston RJ, Sybert VP, Smith LT, et al. Expression of a truncated keratin 5 may contribute to severe palmar–plantar hyperkeratosis in epidermolysis bullosa simplex patients. *J Invest Dermatol* 2001; 116: 970–4
- Marinkovich MP. The molecular genetics of basement membrane diseases. *Arch Dermatol* 1993; 129: 1557–65
- Marinkovich MP, Khavari PA, Herron GS, Bauer EA. Inherited epidermolysis bullosa. In Fitzpatrick's Dermatology in General Medicine, 6th edn. Freedberg IM, Eisen AZ, Wolff K, Austen KF, eds. McGraw-Hill: New York, 2003: 596–609
- Nakano A, Pulkkinen L, Murrell D, et al. Epidermolysis bullosa with congenital pyloric atresia: novel mutations in the beta-4 integrin gene (ITGB4) and genotype/phenotype correlations. *Pediatr Res* 2001; 49: 618–26
- Parisi MA, Sybert VP. Molecular genetics in pediatric dermatology. *Curr Opin Pediatr* 2000; 12: 347–53
- Pearson RW. Clinicopathologic types of epidermolysis bullosa and their nondermatological complications. *Arch Dermatol* 1988; 124: 718–25
- Pfender E, Uitto J, Fine JD. Epidermolysis bullosa carrier frequencies in the US population [Letter]. *J Invest Dermatol* 2001; 116: 483–4
- Uitto J, Christiano AM. Molecular genetics of the cutaneous basement membrane zone. *J Clin Invest* 1992; 90: 687–92
- Uitto J, Pulkkinen L. Molecular genetics of heritable blistering disorders. *Arch Dermatol* 2001; 137: 1458–61

# BACTERIAL AND SPIROCHETAL DISEASES

---

## Impetigo

### Major points

- Most common bacterial skin infection in children
- Occurs superficially with no scarring
- More common in hot, humid climates or in crowded environments
- Associated with regional lymphadenopathy
- Nonbullous impetigo (impetigo contagiosa)
  1. Presents with fragile vesicles and pustules that are easily ruptured forming characteristic 'honey-colored' crusts (Figure 7.1)
  2. Most common on face and around nose, but can also occur on the extremities
  3. Can be a primary infection or can be secondary with an underlying dermatosis, called 'impetiginization'
- Bullous impetigo
  1. Most common in infancy
  2. Typically affects the diaper area
  3. Presents with flaccid, transparent bullae with little surrounding erythema; leads to erosions with a rim of scale (Figure 7.2)
  4. Can present with constitutional symptoms

### Pathogenesis

- Nonbullous impetigo
  1. *Staphylococcus aureus* causes in up to 85% of cases
  2. Group A streptococcus causes in up to 30% of cases with groups B, C, G and F rarely present
  3. Epidemics are caused by *Streptococcus pyogenes* M-serotypes (i.e. 2, 49, 53, 55–57, 60)

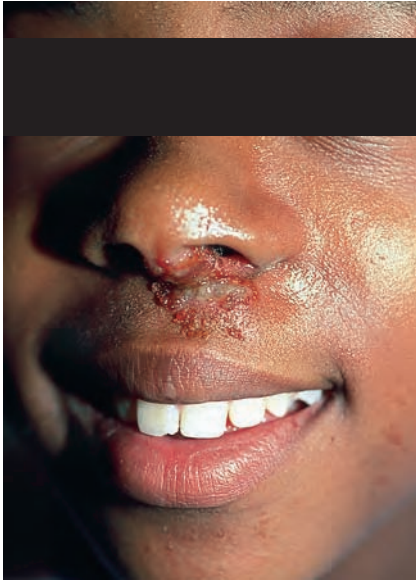
- Bullous impetigo
  1. *Staphylococcus aureus* is the causative organism with 80% from phage group 2
  2. *S. aureus* produces epidermolytic toxins A or B (exfoliatin) which interacts with desmoglein-1 to form bullae
- Causative organisms enter through breaks in the skin such as abrasions or insect bites
- Carriage of the organism in the nares can be a source of infection

### Diagnosis

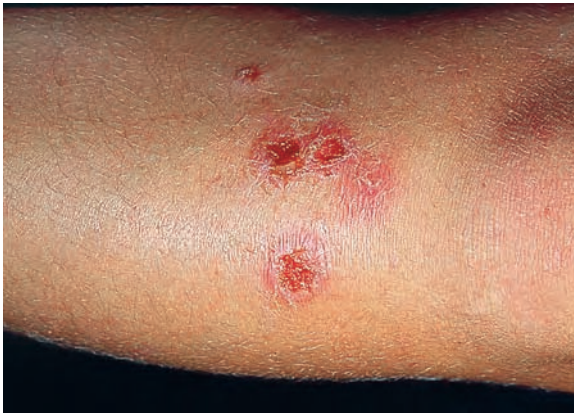- Clinical findings
- Gram stain reveals Gram-positive cocci in clusters or chains
- Staphylococci or streptococci may be isolated from lesions
- KOH prep and Tzanck prep are both negative
- Histology
  1. Nonbullous lesions reveal an intraepidermal vesicopustule within the subcorneal or granular layer with numerous neutrophils
  2. Bullous lesions reveal a bulla with cleavage in the uppermost epidermis and limited inflammation

### Differential diagnosis

- Nonbullous impetigo
  1. Nummular eczema
  2. Tinea corporis
  3. Herpes simplex
  4. Pemphigus foliaceus
- Bullous impetigo
  1. Arthropod reaction



**Figure 7.1** Impetigo contagiosa – typical crusted lesions on the face



**Figure 7.2** Bullous impetigo – with annular, crusted plaques

2. Fixed drug eruption
3. Erythema multiforme
4. Staphylococcal scalded skin syndrome
5. Chronic bullous disease of childhood

### Treatment

- Topical mupirocin
- Topical mupirocin to the nares may be effective at reducing carriage in recurrent cases
- If widespread or associated with constitutional symptoms: oral antibiotics with Gram-positive

coverage (e.g. dicloxacillin, cephalexin or erythromycin)

- Can resolve spontaneously over 2 weeks if left untreated in some cases

### Prognosis

- Typically resolves without scarring
- Can be recurrent with nasal carriage of staphylococci
- 2–5% of cases of impetigo are associated with the development of acute glomerulonephritis; most commonly associated with *Streptococcus pyogenes* M-serotypes 2, 49, 55, 57 and 60; treatment does not reduce risk of development
- Development of cellulitis is uncommon
- Hematogenous spread is rare

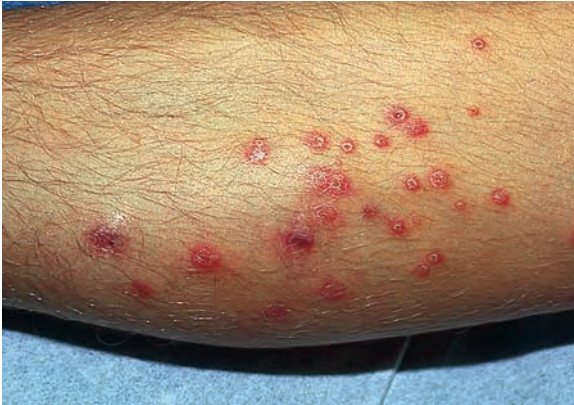### References

- George A, Rubin G. A systematic review and meta-analysis of treatments for impetigo. *Br J Gen Pract* 2003; 53: 480–7
- Hedrick J. Acute bacterial skin infections in pediatric medicine: current issues in presentation and treatment. *Paediatr Drugs* 2003; 5 (Suppl 1): 35–46
- Hirschmann JV. Impetigo: etiology and therapy. *Curr Clin Top Infect Dis* 2002; 22: 42–51
- Mancini AJ. Bacterial skin infections in children: the common and the not so common. *Pediatr Ann* 2000; 29: 26–35

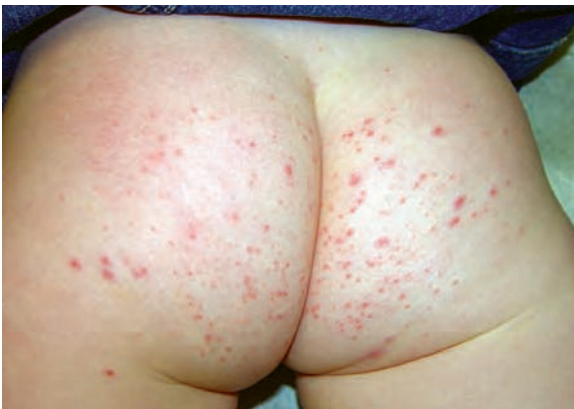## Folliculitis

### Major points

- Infection of the hair follicle
- Variable clinical presentation depending on the infectious organism, depth of penetration and location
- Staphylococcal folliculitis
  1. Most common type
  2. Often related to maceration, occlusion or poor hygiene
  3. Presents with diffuse, discrete, erythematous-based, perifollicular papules and pustules on the scalp, face, buttocks and extremities (Figures 7.3 and 7.4)
  4. Can present concurrently with impetigo
  5. Patient or household members may be nasal carriers of *S. aureus*



**Figure 7.3** Folliculitis – caused by *Staphylococcus aureus*



**Figure 7.4** Folliculitis – common location on the buttocks

2. Presents with pinpoint perifollicular papules and pustules on the back, chest and upper arms
  3. Can be pruritic
  4. May be associated with tinea versicolor or seborrheic dermatitis
  5. KOH reveals characteristic hyphae and spores
  6. Responds to topical or systemic antifungal therapies
  7. Typically chronic and recurrent
  - Gram-negative folliculitis
    1. Infection of the hair follicles by *Escherichia coli* and species of *Enterobacter*, *Klebsiella* or *Proteus*
    2. Occurs in patients with acne who have been on long-term oral antibiotic therapy
    3. Presents as suddenly worsening acne with facial papules, pustules or nodules
    4. Responds well to isotretinoin as well as amoxicillin–clavulanic acid or trimethoprim–sulfamethoxazole
  - Pseudomonas folliculitis (hot tub folliculitis)
    1. Caused by follicular infection with *Pseudomonas aeruginosa*
    2. Acquired in hot tubs, whirlpools, swimming pools and water slides or using body sponges that have not dried completely
    3. Presents with follicular papules and pustules accentuated in the bathing suit distribution (Figure 7.5)
    4. Can be associated with otitis externa, conjunctivitis, mild constitutional symptoms and rarely pneumonia and urinary tract infections
    5. Cutaneous disease resolves without treatment but can be recurrent
- 
6. Rarely related to immunodeficiency, HIV, or diabetes mellitus
  - Furunculosis
    1. Caused by *S. aureus*, especially phage type 80/81
    2. Develops from preceding superficial folliculitis with extension into the dermis and subcutaneous tissue
    3. Presents with tender, erythematous, perifollicular nodules with eventual central necrosis and rupture
    4. Often resolves with scarring
    5. Most common on the face, neck, axillae, or buttocks
  6. Carbuncle: two or more confluent furuncles
  - Pityrosporum folliculitis
    1. Superficial infection of the hair follicle with *Malassezia furfur*

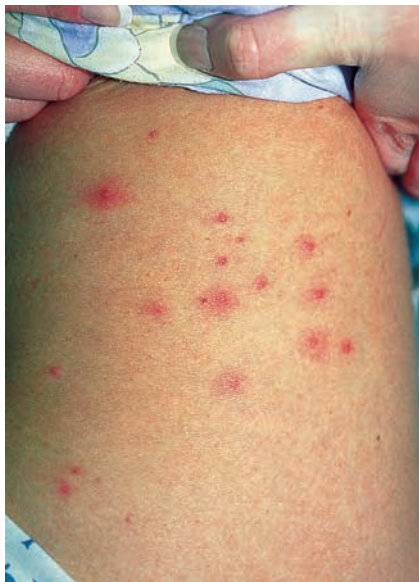### Pathogenesis

- Bacterial organism invades the follicular wall, leading to occlusion of the follicular orifice and causing inflammation
- Can be precipitated by occlusion with emollients, dressings or tar in hair-bearing areas

### Diagnosis

- Clinical presentation
- Gram stain reveals organism
- Bacterial culture
- Histology rarely needed; reveals subcorneal pustules with surrounding neutrophilic infiltrate





**Figure 7.5** Hot tub folliculitis caused by *Pseudomonas*

### Differential diagnosis

- Eosinophilic pustular folliculitis
- Candidiasis

### Treatment

- Can improve with antibacterial cleansers and drying
- Topical antibiotics (e.g. mupirocin, clindamycin)
- Penicillinase-resistant systemic antibiotic may be needed if extensive
- Consider topical mupirocin ointment to the nares and perianal area of patient and household members if there are recurrent episodes

### Prognosis

- Good, typically responds to therapy
- Can be recurrent if poor hygiene or nasal carriage of *S. aureus*
- Unresponsiveness, severe or systemic involvement warrants evaluation for an underlying immunodeficiency

### References

Duarte AM, Kramer J, Yusk JW, et al. Eosinophilic pustular folliculitis in infancy and childhood. *Am J Dis Child* 1993; 147: 197–200

Fleischer AB Jr, Ling M, Eichenfield L, et al. Tacrolimus Ointment Study Group. Tacrolimus ointment for the

treatment of atopic dermatitis is not associated with an increase in cutaneous infections. *J Am Acad Dermatol* 2002; 47: 562–70

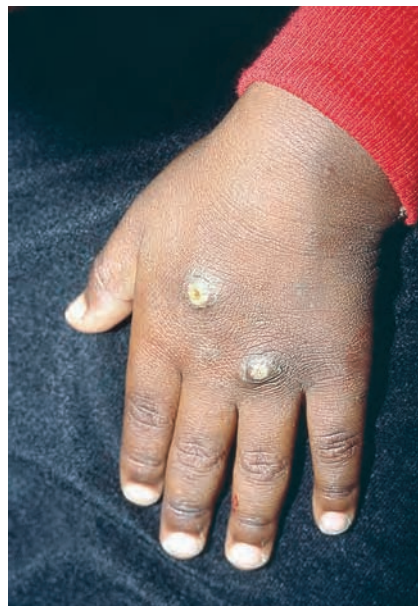Neubert U, Jansen T, Plewig G. Bacteriologic and immunologic aspects of gram-negative folliculitis: a study of 46 patients. *Int J Dermatol* 1999; 38: 270–4

Stahelin-Massik J, Gnehm HE, Itin PH. *Pseudomonas* folliculitis in a young child. *Pediatr Infect Dis J* 2000; 19: 362–3

## Ecthyma

### Major points

- Deep, punched out, ulcerative, painful, cutaneous infection (Figure 7.6)
- Typically develops on legs and buttocks at sites of minor trauma, insect bites or excoriations
- Often occurs in the setting of malnutrition or poor hygiene
- Develops as an erythematous-based vesiculopustule with progression to a crusted ulcer with overlying adherent crust and elevated peripheral rim
- Slow healing with resultant scarring
- Can be associated with fever and lymphadenopathy



**Figure 7.6** Ecthyma – typical punched out crusted papules and ulcers



### Pathogenesis

- Caused by *Streptococcus pyogenes* most commonly, or *Staphylococcus aureus*

### Diagnosis

- Clinical appearance
- Can be confirmed with Gram stain and bacterial culture

### Differential diagnosis

- Anthrax
- Cutaneous diphtheria
- Ecthyma gangrenosum caused by *Pseudomonas aeruginosa*
- Second-degree burn
- Cigarette burns from child abuse

### Treatment

- Warm compresses
- Local wound care with gentle cleansing and debridement
- Topical and systemic antibiotics

### Prognosis

- Heals with scarring
- Can rarely progress to cellulitis
- Infection can rarely be associated with post-streptococcal glomerulonephritis

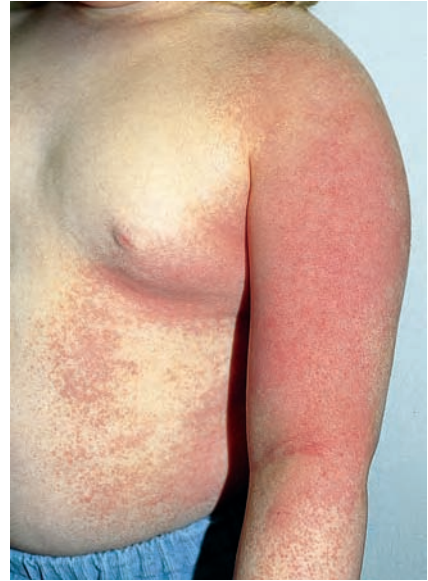### References

- Gudcuer H, Ergun T, Demircay Z. Ecthyma gangrenosum. *Int J Dermatol* 1999; 38: 299–302
- Mancini AJ. Bacterial skin infections in children: the common and the not so common. *Pediatr Ann* 2001; 29: 26–35
- Stulberg DL, Penrod MA, Blatny RA. Common bacterial skin infections. *Am Fam Physician* 2002; 66: 119–24
- Travers JB, Norris DA, Leung DY. The keratinocyte as a target for staphylococcal bacterial toxins. Symposium Proceedings. *J Invest Dermatol* 2001; 6: 225–30

## Cellulitis

### Major points

- Acute infection and inflammation of the deep dermis and subcutaneous fat
- Presents with warm, red, tender, edematous plaques with ill-defined borders (Figure 7.7)

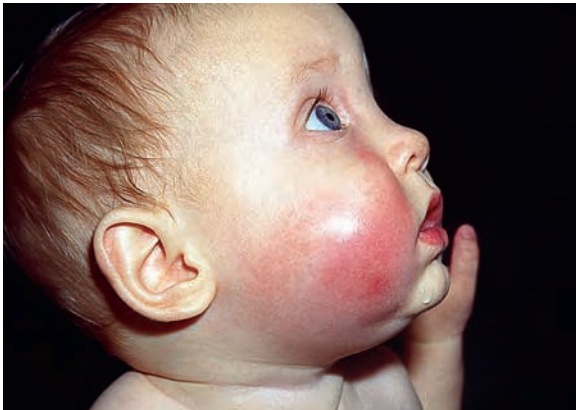

**Figure 7.7** Cellulitis – caused by streptococcus with marked erythema

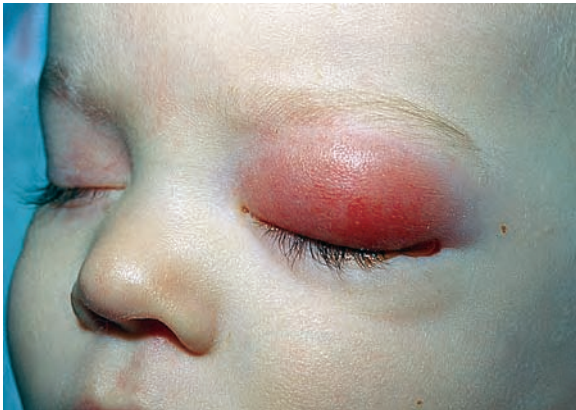- Typically blue to purple dusky erythema if caused by *Haemophilus influenzae* (usually on the face)
- Most commonly seen on the face, neck or extremities (Figures 7.8 and 7.9)
- Predisposing factors: immunosuppression and diabetes mellitus
- Typically accompanied by regional lymphadenopathy, fever and constitutional symptoms

### Pathogenesis

- Initiated by a break in the skin (e.g trauma or primary dermatosis) that serves as a portal of entry for the organism or preceded by upper respiratory infection, otitis media, sinusitis or tooth abscess
- Most common etiologic organisms: *Streptococcus pyogenes* or *Staphylococcus aureus*
- Preseptal or periorbital cellulitis (infection anterior to the orbital septum) is typically caused by *S. pyogenes* or *S. aureus*, but can also be caused by *Streptococcus pneumoniae*, especially in patients <5 years old
- Orbital cellulitis (infection behind the orbital septum) is most commonly caused by *S. aureus*, but can also be caused by *S. pyogenes*, *S. pneumoniae*, or *H. influenzae*



**Figure 7.8** Facial cellulitis – caused by *Haemophilus influenzae* with a violaceous hue



**Figure 7.9** Orbital cellulitis with meningitis caused by *Haemophilus influenzae*

- Additional causative agents in neonates include group B streptococci and rarely *E. coli*
- Inoculation through animal bites: *Pasteurella multocida* from cats and dogs, *Eikenella corrodens* from humans

### Diagnosis

- Clinical findings
- Typically accompanied by leukocytosis
- Gram stain and bacterial culture from lesional aspirate is positive in 25% of cases
- Histology reveals edema and intense neutrophilic inflammation in the dermis and fat; tissue Gram stain or bacterial culture is positive in the minority of cases

- Blood cultures may be positive if there is associated bacteremia
- Computed tomography may be indicated if there is ocular involvement
- Lumbar puncture is indicated if the patient is <1 year old or if there are signs of toxicity or sepsis

### Differential diagnosis

- Allergic contact dermatitis
- Urticaria
- Drug eruption
- Cold panniculitis
- Insect bite
- Wells syndrome

### Treatment

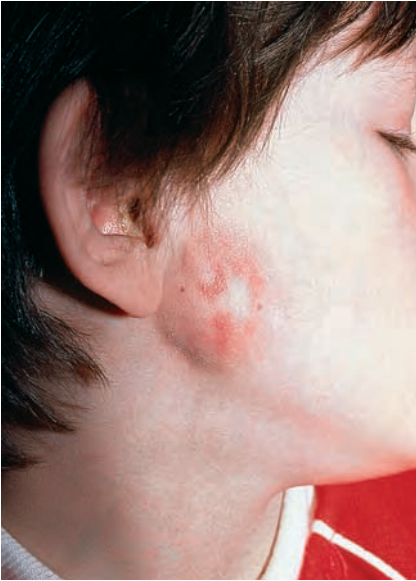- Therapy is based on the age of the patient, location of the infection, and the immune status of the patient
- Systemic antibiotics are required
- Localized infection on the extremity can be treated with oral penicillinase-resistant antibiotic with outpatient follow-up in 24 hours to re-assess status of patient
- Patients <5 years old should also be covered for *S. pneumoniae*
- Intravenous antibiotics and hospitalization are warranted if refractory to oral antibiotics, or with facial involvement
- Orbital cellulitis is an emergency and requires hospitalization, intravenous antibiotic therapy and evaluation by an ophthalmologist and otolaryngologist

### Prognosis

- Good prognosis if diagnosed and appropriately treated early
- Delay in diagnosis or treatment is associated with increased complications
- Complications: subcutaneous abscess (Figure 7.10), necrotizing fasciitis, lymphangitis, thrombophlebitis, bacteremia, osteomyelitis, septic arthritis and systemic involvement of the heart valves, eyes or central nervous system (CNS); post-streptococcal glomerulonephritis can also occur

### References

Capdevila O, Grau I, Vadillo M, et al. Bacteremic pneumococcal cellulitis compared with bacteremic cellulitis caused by *Staphylococcus aureus* and *Streptococcus pyogenes*. *Eur J Clin Microbiol Infect Dis* 2003; 22: 337–41



**Figure 7.10** Abscess – caused by *Staphylococcus aureus*

Cohen PR, Kurzrock R. Community-acquired methicillin-resistant *Staphylococcus aureus* skin infection: an emerging clinical problem. *J Am Acad Dermatol* 2004; 50: 277–80

Darmstadt GL. Bacterial skin infections in adolescents. *Adolesc Med* 2001; 12: 243–68

Eady EA, Cove JH. Staphylococcal resistance revisited: community-acquired methicillin resistant *Staphylococcus aureus*—an emerging problem for the management of skin and soft tissue infections. *Curr Opin Infect Dis* 2003; 16: 103–24

Fisher RG, Benjamin DK. Facial cellulitis in childhood: a changing spectrum. *South Med J* 2002; 95: 672–4

Givner LB. Periorbital versus orbital cellulitis. *Pediatr Infect Dis J* 2002; 21: 1157–8

## Erysipelas

### Major points

- Acute, superficial cellulitis with infection and inflammation in the dermis and upper subcutaneous tissue involving the superficial dermal lymphatics
- Infection follows inoculation through breaks in the skin (e.g. trauma, fissures, primary dermatosis such as intertrigo, tinea pedis or ulceration)
- Predisposing factors include lymphatic/venous obstruction, diabetes mellitus and nephrotic syndrome

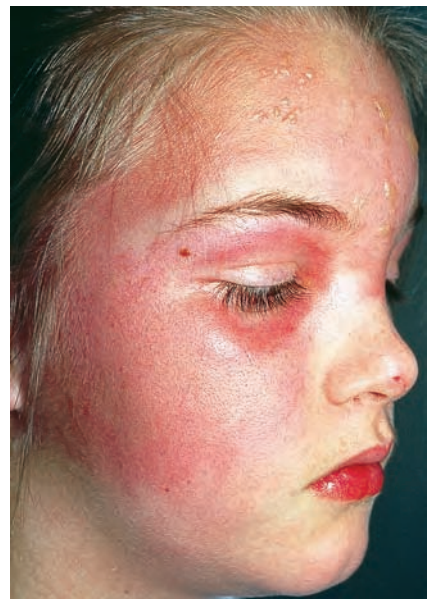- Typically involves the face, scalp or leg; the lower extremity has replaced the face as the most common location of involvement
- Presents as a red, shiny, warm, indurated plaque with well-demarcated, advancing border (Figure 7.11)
- Can also be vesicular, bullous or petechial
- Fever and constitutional symptoms can precede the cutaneous eruption

### Pathogenesis

- Bacteria enter the skin through some disruption of skin integrity leading to bacterial proliferation causing intense lymphatic inflammation
- Most commonly caused by infection with *Streptococcus pyogenes*
- Can also be due to infection with *S. aureus*, *S. pneumoniae* and group G, B, C, D streptococci

### Diagnosis

- Clinical findings
- ASO and anti-DNAase B titers may be elevated
- Gram stain and bacterial culture of the portal of entry may identify the organism
- Histology reveals marked dermal and lymphatic edema with surrounding neutrophilic infiltrate



**Figure 7.11** Erysipelas – quickly-spreading erythema with pain caused by streptococcus

- Latex particle agglutination for streptococcal antigens in skin biopsy specimens may be positive

### Differential diagnosis

- Systemic lupus erythematosus
- Dermatomyositis
- Relapsing polychondritis
- Acute tuberculoid leprosy
- Contact dermatitis
- Urticaria

### Treatment

- Systemic penicillin or cephalexin for at least 10 days; can use erythromycin or clarithromycin if penicillin allergic

### Prognosis

- May resolve with postinflammatory hyperpigmentation
- Can rarely progress to bacteremia, thrombophlebitis, abscess formation, necrotizing fasciitis, gangrene or bony changes
- Post-streptococcal renal and cardiac involvement can occur
- Recurrence occurs in up to 20% of cases

### References

- Bisno AL, Stevens DL. Streptococcal infections of skin and soft tissues. *N Engl J Med* 1996; 334: 240–5
- Bonnetblanc JM, Bedane C. Erysipelas: recognition and management. *Am J Clin Dermatol* 2003; 4: 157–63
- Dahl PR, Perniciaro C, Holmkvist KA, et al. Fulminant group A streptococcal necrotizing fasciitis: clinical and pathologic findings in 7 patients. *J Am Acad Dermatol* 2002; 47: 489–92
- Eriksson B, Jorup-Ronstrom C, Karkkonen K, et al. Erysipelas: clinical and bacteriologic spectrum and serological aspects. *Clin Infect Dis* 1996; 23: 1091–8
- Hedrick J. Acute bacterial skin infections in pediatric medicine: current issues in presentation and treatment. *Paediatr Drugs* 2003; 5 (Suppl 1): 35–46

## Perianal streptococcal dermatitis

### Major points

- Superficial infection of the perianal skin
- Associated with concurrent pharyngeal infection in >50% of cases

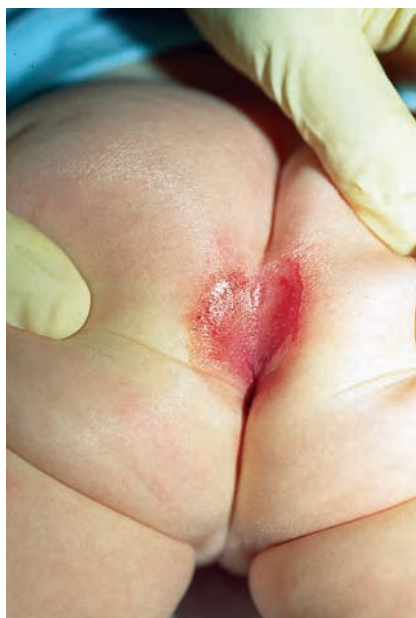- May be preceded by impetigo with secondary infection of the perianal skin
- Typically presents between 6 months and 10 years of age
- More common in males
- Presents acutely with well-demarcated, bright red, tender erythema surrounding the anus (Figure 7.12)
- Chronic infection leads to perianal fissures, crusting and psoriasiform plaques
- Associated with perianal itching and pain leading to painful defecation and fecal retention
- Rarely associated with constitutional symptoms
- Can precipitate guttate psoriasis in children

### Pathogenesis

- Local infection in the dermis caused by *Streptococcus pyogenes*

### Diagnosis

- Perianal swab with positive bacterial culture for *S. pyogenes* or latex agglutination are confirmatory
- Histology is not well-described and is rarely required



**Figure 7.12** Perianal streptococcus with typical bright shiny erythema



### Differential diagnosis

- Psoriasis
- Intertrigo
- Candidiasis
- Seborrheic dermatitis
- Pinworm infestation
- Inflammatory bowel disease
- Sexual abuse

### Treatment

- Oral penicillin or cephalexin for 10 days
- Alternatives: oral erythromycin or clarithromycin in penicillin-allergic patients
- Oral clindamycin has been successful in recurrent cases
- Mupirocin ointment topically along with systemic antibiotics have also been utilized to treat recurrences

### Prognosis

- Typically heals without sequelae
- Frequently recurrent
- Can lead to behavioral defecating difficulties if untreated

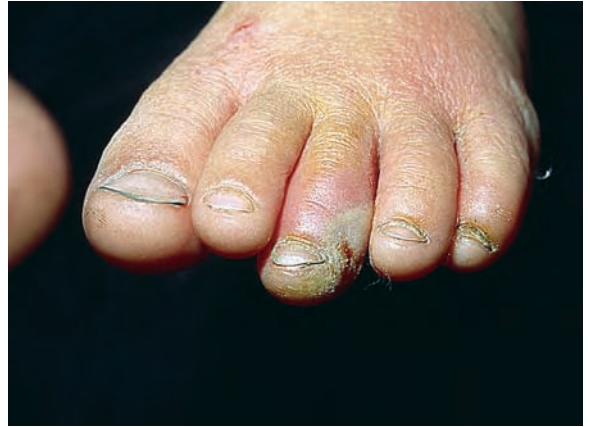### References

- Anonymous. Kindergarten-based outbreak of perianal group A streptococcal infection. *Arch Dis Child* 2003; 88: 811
- Barzilai A, Choen HA. Isolation of group A streptococci from children with perianal cellulitis and from their siblings. *Pediatr Infect Dis J* 1998; 17: 358–60
- Mogielnicki NP, Schwartzman JD, Elliott JA. Perineal group A streptococcal disease in a pediatric practice. *Pediatrics* 2000; 106: 276–81
- Petersen JP, Kaltoft MS, Misfeldt JC, et al. Community outbreak of perianal group A streptococcal infection in Denmark. *Pediatr Infect Dis J* 2003; 22: 105–9
- Velez A, Moreno JC. Febrile perianal streptococcal dermatitis. *Pediatr Dermatol* 1999; 16: 23–4

## Blistering distal dactylitis

### Major points

- Superficial blistering infection of the skin
- Typically affects school-aged children
- Presents with tense, tender, dusky, erythematous-based vesicles over the anterior fat pad of the fingers and toes (Figure 7.13)



**Figure 7.13** Blistering dactylitis caused by *Staphylococcus aureus*

- Can involve multiple digits
- May be associated with fever and constitutional symptoms
- Resolves with desquamation
- Can be associated with asymptomatic infection of the nasopharynx or conjunctiva

### Pathogenesis

- Caused by a localized infection with group A streptococcus
- Can rarely be due to infection with group B streptococcus or *S. aureus*

### Diagnosis

- Positive Gram stain and bacterial culture from blister fluid

### Differential diagnosis

- Herpetic whitlow
- Friction blisters

### Treatment

- Incision and drainage
- Systemic penicillinase-resistant antibiotics

### Prognosis

- Resolves without sequelae
- Can be recurrent

### References

- Barnett BO, Frieden IJ. Streptococcal skin diseases in children. *Semin Dermatol* 1992; 11: 3–10



Ney AC, English JC, Greer KE. Coexistent infections on a child's distal phalanx: blistering dactylitis and herpetic whitlow. *Cutis* 2002; 69: 46–8

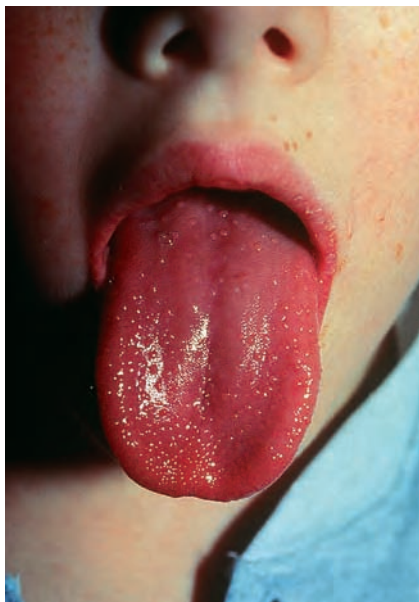Woroszyński A, Duran C, Tamayo L, et al. Staphylococcal blistering dactylitis: report of two patients. *Pediatr Dermatol* 1996; 13: 292–3

## Scarlet fever

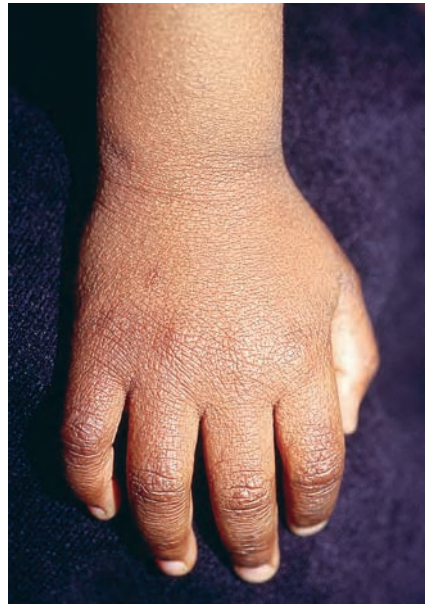Synonym: scarlatina

### Major points

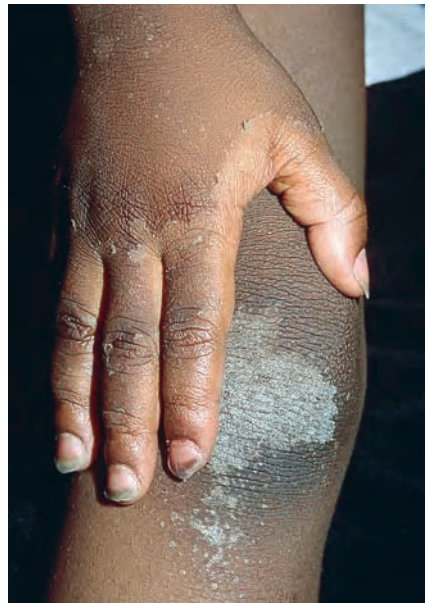- Most common in children aged 2 to 10 years
- Uncommon in children <2 years old because of maternal anti-exotoxin antibodies
- Typically begins with fever and sore throat
- Exanthem follows after 1–2 days; typically starts on upper trunk and then generalizes with typical sandpaper texture and sparing of the palms and soles (Figures 7.14–7.16)
- Resolves with fine brawny desquamation
- Erythema is accentuated in the skin folds which can develop petechiae (Pastia's lines)
- Facial flushing with circumoral pallor is common
- Enanthem with petechiae of the palate and uvula (Forschheimer spots), or bright red mucous



**Figure 7.14** Scarlet fever – strawberry tongue with loss of papillae



**Figure 7.15** Scarlet fever – typical sandpaper rash on the hand



**Figure 7.16** Scarlet fever – desquamation 1 week later, typically concentrated on hands, feet and knees

membranes and a white-coated tongue with dilated papillae (white strawberry tongue) that sloughs producing a glistening red tongue with dilated papillae (red strawberry tongue)

- May have associated lymphadenopathy, fever and constitutional symptoms

### Pathogenesis

- Initiated by infection of the pharynx, skin, soft tissue or surgical sites with *S. pyogenes* or group C or G streptococci
- Clinical manifestations are caused by streptococcal pyrogenic exotoxins A, B or C produced by the infectious organism

### Diagnosis

- Clinical presentation
- Leukocytosis with increased number of bands and eosinophilia
- Rising antistreptolysin-O titer during the acute phase and declining titer with convalescence
- Rapid antigen detection may be positive, but can be falsely negative early in the disease course
- Positive Gram stain and bacterial culture of the throat or wound is confirmatory
- Histology: dilated dermal blood and lymphatic vessels especially around hair follicles along with perivascular mononuclear cell infiltration

### Differential diagnosis

- Viral exanthem
- Exanthematous drug eruption
- Kawasaki disease
- Toxic shock syndrome
- Staphylococcal scalded skin syndrome
- Measles
- Rubella
- Mononucleosis

### Treatment

- Penicillin is the treatment of choice
- Alternatives: erythromycin, clarithromycin, or azithromycin

### Prognosis

- Typically good with early treatment
- Early complications can include otitis media, mastoiditis, pneumonia, bacteremia and osteomyelitis
- Rheumatic fever is a rare sequela; risk is reduced with early treatment
- Acute glomerulonephritis is a rare sequela and treatment of skin infection does not reduce its risk of development

- 80% of children develop lifelong antibodies to the exotoxins, eliminating the chance of recurrence

### References

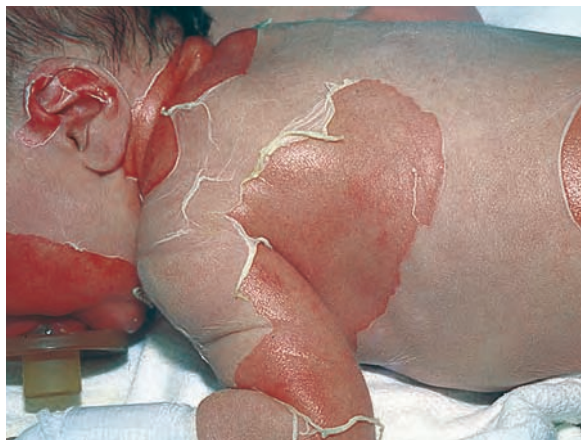- Bialecki C, Feder HM Jr, Grant-Kels JM. The six classic childhood exanthems: a review and update. *J Am Acad Dermatol* 1989; 21: 891–903
- Espinosa de los Monteros LE, Bustos IM, Flores LV, Avila-Figueroa C. Outbreak of scarlet fever caused by an erythromycin-resistant *Streptococcus pyogenes* emm22 genotype strain in a day-care center. *Pediatr Infect Dis J* 2001; 20: 807–9
- Shiseki M, Miwa K, Nemoto Y, et al. Comparison of pathogenic factors expressed by group A *Streptococci* isolated from patients with streptococcal toxic shock syndrome and scarlet fever. *Microb Pathol* 1999; 27: 243–52

## Staphylococcal scalded skin syndrome

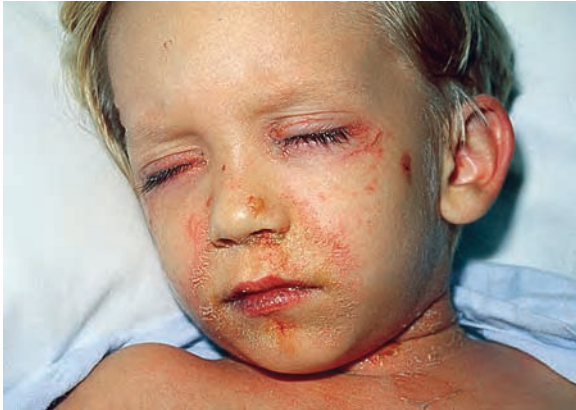Synonym: Ritter disease

### Major points

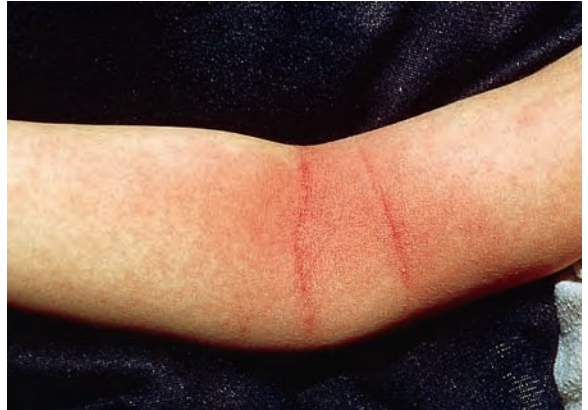- Typically presents in children <5 years old
- Initially begins with fever, malaise, irritability, skin tenderness and erythema
- Rapidly progresses to diffuse erythroderma that is accentuated in the flexural areas with characteristic perioral erythema (Figures 7.17–7.21)



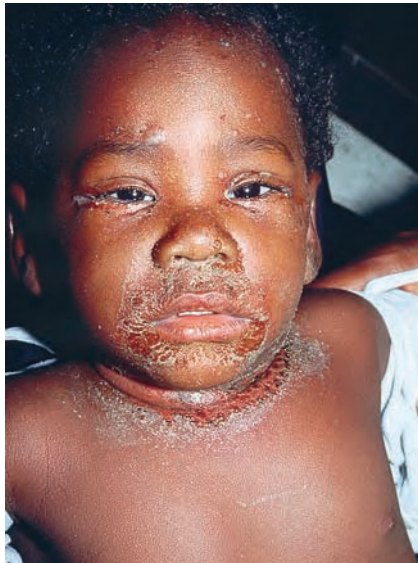
**Figure 7.17** Staphylococcal scalded skin syndrome – in a neonate; mother had a positive vaginal culture for *Staphylococcus aureus*



**Figure 7.18** Staphylococcal scalded skin syndrome – typical painful erythema and crusting around the face



**Figure 7.20** Staphylococcal scalded skin syndrome – painful erythema caused by exfoliative toxin

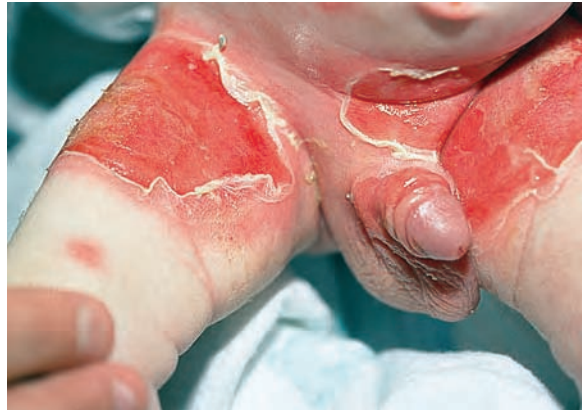

**Figure 7.19** Staphylococcal scalded skin syndrome – typical crusting and scaling on the face

- Followed by diffuse exfoliation or bullous desquamation with perioral, perinasal and periocular crusting and radial fissuring and underlying shiny erythema

#### Pathogenesis

- Primary colonization or infection with *S. aureus* phage group II (types 3A, 3B, 3C, 55, 71) of the nasopharynx, conjunctivae, cutaneous wounds, umbilical cord stump or urinary tract



**Figure 7.21** Staphylococcal scalded skin syndrome – localized to the diaper area

- Causative organisms produce epidermolytic toxins A and B that are hematogenously spread
- Exotoxins have serine protease activity causing cleavage of desmosomal desmoglein 1 leading to a granular layer split and generalized sloughing of the superficial epidermis

#### Diagnosis

- Culture of the primary source (e.g. nasopharynx, conjunctivae or umbilical cord)
- Gram stain and culture of the exfoliated skin is negative for organisms unless secondarily infected
- Tzanck smear may reveal acantholytic cells
- Histologic evaluation of the exfoliated skin in frozen sections reveals only stratum corneum



- Histology of skin reveals a subcorneal vesicle with the cleavage plane within the granular layer, a few acantholytic cells and limited inflammation

### Differential diagnosis

- Scarlet fever
- Kawasaki disease
- Toxic shock syndrome
- Bullous impetigo
- Bullous mastocytosis
- Drug-induced toxic epidermal necrolysis

### Treatment

- Gentle cleansing with antibacterial cleansers may prevent secondary infection
- Emollients, mupirocin, or topical silver sulfadiazine to denuded areas
- Oral penicillinase-resistant antibiotics in cases with limited cutaneous involvement
- Parenteral antibiotics are required if there is extensive cutaneous involvement or signs of systemic involvement

### Prognosis

- Typically heals without scarring in 14 days
- May be scarring if secondarily infected
- Extensive desquamation can lead to fluid and electrolyte imbalance
- Can develop pneumonia, endocarditis, cellulitis or bacteremia
- Mortality is less than 4% from sepsis

### References

- Faden H. Neonatal staphylococcal skin infections. *Pediatr Infect Dis J* 2003; 22: 389
- Ladhani S, Joannou CL. Difficulties in diagnosis and management of the staphylococcal scalded skin syndrome. *Pediatr Infect Dis J* 2000; 19: 819–21
- Ladhani S, Joannou CL, Lochrie DP, et al. Clinical, microbial, and biochemical aspects of the exfoliative toxins causing staphylococcal scalded skin syndrome. *Clin Microbiol Rev* 1999; 12: 224–42
- Patel GK, Finlay AY. Staphylococcal scalded skin syndrome: diagnosis and management. *Am J Clin Dermatol* 2003; 4: 165–75
- Sarkar R, Sharma RC, Koranne RV, Sardana K. Erythroderma in children: a clinico-etiological study. *J Dermatol* 1999; 26: 507–11

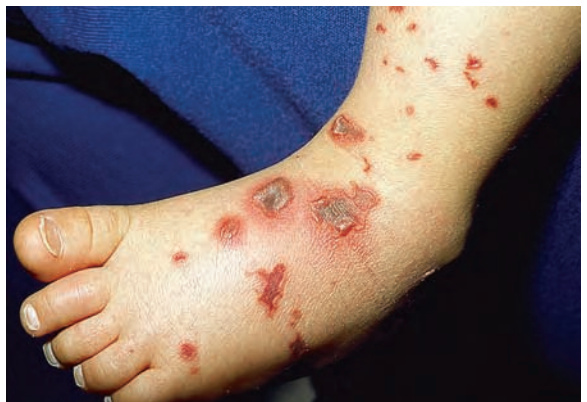## Meningococchemia

### Major points

- Severe, acute bacterial septicemia
- Most common in infants of 6–12 months of age; 50% of all cases are <5 years of age
- Increased susceptibility with asplenia or complement deficiency
- Begins with prodrome of fever, headache and upper respiratory symptoms, followed by meningeal irritation and neurologic symptoms
- Progression is variable but typically rapid
- Cutaneous findings: acrocyanosis of the ears, nose, lips, legs and genitalia (often the first cutaneous finding), petechiae, purpura, confluent ecchymoses with central necrosis that can progress to gangrene (Figure 7.22)
- Chronic meningococchemia is rare in children; has been associated with complement deficiencies or prior meningococcal disease

### Pathogenesis

- Infection with *Neisseria meningitidis*; typically from nasopharyngeal carriage or inhalation of infected secretions with bacterial seeding of the blood and widespread dissemination
- Endotoxin-mediated procoagulation and thrombosis leads to infarction and necrosis in multiple organ systems with consumption of protein C, protein S and antithrombin III
- Serogroups A and C are associated with epidemics; serotype B is associated with sporadic cases and is most common in childhood cases



**Figure 7.22** Meningococchemia – angulated irregular necrotic lesions

### Diagnosis

- Clinical findings of an acutely ill child with fever, typical skin lesions and signs of sepsis
- Cultures of blood and cerebrospinal fluid (CSF) which reveal Gram-negative diplococci
- Latex agglutination of the CSF is the most rapid diagnostic test
- Gram stain of aspiration fluid or scraping from a petechial lesion occasionally reveals organisms
- Histology reveals thrombi in the dermal vessels with acute vasculitis and perivascular hemorrhagic necrosis; Gram-negative diplococci may be identified within or around vessels
- Cultures of skin are positive in up to 85% of cases; requires chocolate agar or Thayer–Martin medium with specific growth requirements

### Differential diagnosis

- Gonococemia
- Bacteremia with *Haemophilus influenzae* or *Streptococcus pneumoniae*
- Henoch–Schönlein purpura
- Leukocytoclastic vasculitis
- Endocarditis
- Rickettsial infections
- Rheumatic fever

### Treatment

- Broad antibacterial coverage: ampicillin and cefotaxime or ceftriaxone with or without doxycycline until culture and sensitivity are available
- Supportive and intensive care
- Management of sepsis and other complications
- Polyvalent polysaccharide vaccines for serogroups A, C, Y and W-135 are available and recommended in those who are asplenic, those with complement deficiencies and those in closed communities (e.g. dormitories and the military); vaccination is 90% effective

### Prognosis

- Fatal if not diagnosed and/or treated appropriately
- Morbidity and mortality increase with increasing purpuric lesions
- Fulminant, rapidly progressive disease is associated with >50% mortality
- 90% recovery rate if treated in the early stages of disease

- Complications occur in 11–19% of cases and include gangrene with skin necrosis, septic arthritis, myocarditis, pneumonia, renal failure, adrenal involvement (Waterhouse–Friderichsen syndrome), neurologic involvement and seizures

### References

- Darmstadt GL. Acute infectious purpura fulminans: pathogenesis and medical management. *Pediatr Dermatol* 1998; 15: 169–83
- Domingo P, Muniz-Diaz E, Baraldes MA, et al. Associations between Fc gamma receptor IIA polymorphisms and the risk and prognosis of meningococcal disease. *Am J Med* 2002; 112: 19–25
- Malley R, Huskins WC, Kuppermann N. Multivariable predictive models for adverse outcome of invasive meningococcal disease in children. *J Pediatr* 1996; 129: 702–10
- Ploysangam T, Sheth AP. Chronic meningococemia in childhood: case report and review of the literature. *Pediatr Dermatol* 1996; 13: 483–7
- Powars D, Larsen R, Johnson J, et al. Epidemic meningococemia and purpura fulminans with induced protein C deficiency. *Clin Infect Dis* 1993; 17: 254–61

## Pitted keratolysis

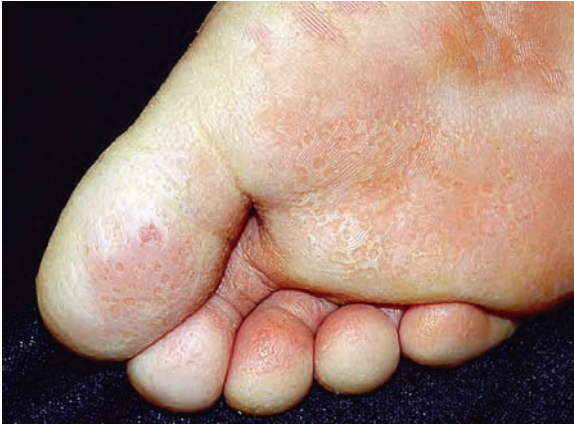### Major points

- Bacterial infection of the stratum corneum of the weight-bearing plantar surfaces
- Rarely affects palmar surfaces
- Malodorous; occasionally painful but typically asymptomatic
- Presents with shallow, discrete pits or erythematous plaques with shallow ulcerations (Figure 7.23)
- Associated with humid climates, hyperhidrosis, extended immersion in water or walking barefoot in wet environments

### Pathogenesis

- Multiple causative organisms have been identified and may exist synergistically: *Corynebacterium*, *Micrococcus*, *Dermatophilus*, *Actinomyces* or *Kytococcus*
- Extracellular enzymes classified as serine proteases are produced in cultures and have been shown to degrade human keratin





**Figure 7.23** Pitted keratolysis with typical multiple shallow craters on the feet

### Diagnosis

- Clinical appearance

### Differential diagnosis

- Tinea pedis
- Plantar warts
- Dyshidrotic eczema

### Treatment

- Topical antibiotics including erythromycin, clindamycin or mupirocin
- Castellani's paint
- Aluminum chloride
- Topical benzoyl peroxide
- Dakin solution (diluted bleach water 0.25%)

### Prognosis

- Can be recurrent but responds rapidly to treatment

### References

- Longshaw CM, Wright JD, Farrell AM, Holland KT. *Kytococcus sedentarius*, the organism associated with pitted keratolysis, produces two keratin-degrading enzymes. *J Appl Microbiol* 2002; 93: 810–16
- Shah AS, Kamino H, Prose NS. Painful, plaque-like pitted keratolysis occurring in childhood. *Pediatr Dermatol* 1992; 9: 251
- Takama H, Tamada Y, Yano K, et al. Pitted keratolysis: clinical manifestations in 53 cases. *Br J Dermatol* 1997; 137: 282–5

## Cat scratch disease

Synonym: cat scratch fever, benign lymphoreticulosis

### Major points

- Benign, self-limited infection
- > 90% of patients have a history of exposure to a kitten
- Inoculation site characterized by a maculopapule, vesiculopapule or pustule, develops 3–10 days after exposure; most common on the upper extremity, head or neck
- Primary inoculation occurs in the eye in 7% of cases leading to conjunctivitis or ocular granuloma
- Regional lymphadenopathy is the hallmark of the disease and develops 3–50 days following the primary inoculation
- Other rare associated cutaneous findings: morbilliform eruption, petechiae, urticaria, erythema multiforme and erythema nodosum
- May be accompanied by constitutional symptoms: fever, malaise, headache, anorexia, sore throat and nausea
- Systemic involvement in 4% of patients, typically those who are immunocompromised: thrombocytopenic purpura, pneumonitis, hypercalcemia, endocarditis, CNS involvement, hepatitis and hepatosplenic abscesses

### Pathogenesis

- Caused by the pleomorphic, Gram-negative bacillus *Bartonella henselae*
- Domestic cats, especially kittens <6 months of age, are the reservoir; fleas are implicated in the transmission between animals; rarely, dogs have been associated with infection
- Transmission to humans by cutaneous inoculation through a scratch, bite or lick of an infected animal

### Diagnosis

- Clinical history and examination
- Serologic tests for *B. henselae*, but may be falsely positive
- Biopsy of the skin or lymph node reveals areas of necrobiosis in the dermis characterized by a central acellular zone surrounded by palisading histiocytes and a few giant cells with a surrounding zone of lymphoid cells
- Small bacilli seen with Warthin–Starry silver stain from the skin or lymph node

- Culture of skin or blood is difficult without specific growth requirements

### Differential diagnosis

- Bacterial lymphadenitis
- Viral lymphadenopathy (e.g. HIV, Epstein–Barr virus, cytomegalovirus)
- Toxoplasmosis
- Histoplasmosis
- Atypical mycobacteria
- Sporotrichosis
- Sarcoidosis
- Lymphoreticular malignancy

### Treatment

- Not required as skin lesions resolve spontaneously over 2–4 weeks and lymphadenopathy typically resolves in 4 months
- Multiple antibiotics have been used and are reportedly effective in speeding recovery if used early in the disease course: azithromycin, rifampin, gentamicin or trimethoprim/sulfamethoxazole
- Warm compresses
- Needle aspiration or incision and drainage of lymph nodes may relieve symptoms, but can lead to a chronic draining fistula
- Lymph node excision may be undertaken for persistent lymphadenopathy or to aid in diagnosis
- Disease in the reservoir animal is also self-limited and does not require specific treatment or disposal

### Prognosis

- Patients with normal immune function have an excellent prognosis; disease resolves spontaneously over 1–3 months
- Associated with rare neurological sequelae
- Immunocompromised patients have a higher rate of systemic involvement and a more aggressive course (bacillary angiomatosis) which can lead to disseminated intravascular coagulation, shock and death

### References

Chian CA, Arrese JE, Pierard GE. Skin manifestations of Bartonella infections. *Int J Dermatol* 2002; 41: 461–6

Metzker-Cotter E, Kletter Y, Avidor B, et al. Long-term serological analysis and clinical follow-up of patients with cat scratch disease. *Clin Infect Dis* 2003; 37: 1149–54

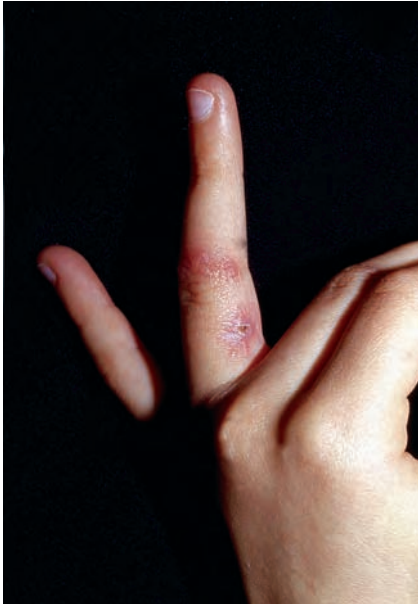Murakami K, Tsukahara M, Tsuneoka H, et al. Cat scratch disease: analysis of 130 seropositive cases. *J Infect Chemother* 2002; 8: 349–52

Somech R, Spierer Z. Uncommon presentation of some common pediatric diseases. *Adv Pediatr* 2003; 50: 269–304

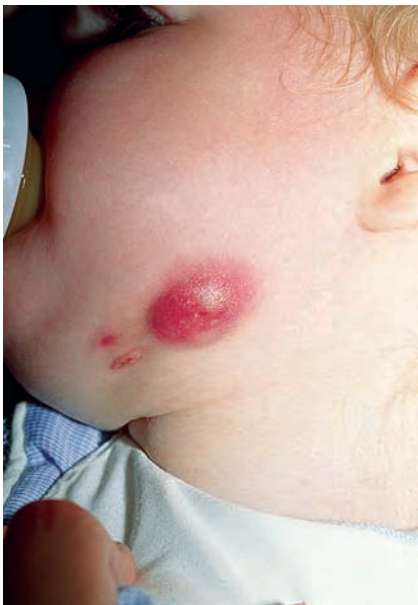## Atypical mycobacterial diseases

### Major points

- Nontuberculous acid-fast organisms that encompass a group of ~ 30 pathogens found in soil, animals, food, milk and water
- Genus *Mycobacterium* classified into four groups by Runyon:
  1. Group I
    - a. Photochromogens
    - b. Produces yellow pigment on Lowenstein–Jensen medium at 37°C with light exposure
    - c. Includes *M. kansasii*, *M. marinum*, *M. simiae*
  2. Group II
    - a. Scotochromogens
    - b. Produces yellow-orange pigment with dark exposure
    - c. Includes *M. scrofulaceum*, *M. szulgai*, *M. gordonae*, *M. xenopi*
  3. Group III
    - a. Nonphotochromogens
    - b. Does not produce pigment
    - c. Includes *M. avium-intracellulare*, *M. haemophilum*, *M. ulcerans*, *M. mageritense*
  4. Group IV
    - a. Rapid growers; growth within 3–5 days in culture
    - b. Does not produce pigment
    - c. Includes *M. fortuitum* and *M. chelonae*
- Low pathogenicity unless traumatic exposure or underlying immunocompromised state
- Most common cutaneous atypical mycobacterial infection is caused by *M. marinum* (formerly known as *M. balnei*) acquired from a swimming pool, aquarium or fish tank
- Cutaneous lesions: pink, red, purple or brown papules and nodules that can spread to adjacent surrounding skin and develop ulceration or crusting (Figures 7.24 and 7.25)



**Figure 7.24** Atypical mycobacterial infection – fish tank granuloma caused by *Mycobacterium marinum*



**Figure 7.25** Atypical mycobacterial infection – abscess caused by *Mycobacterium intracellulare*

- Lesions are most commonly found on the extremities, especially the fingers, knees, elbows and feet, and appear ~3 weeks after exposure

### Pathogenesis

- *M. marinum* is an aerobic acid-fast bacterium that inhabits warm water (open seas, natural pools, swimming pools or aquariums) and can affect fish, especially tropical fish, aquatic animals and humans
- Causative organism is inoculated into the skin either traumatically or through abrasions while working or playing in an affected environment

### Diagnosis

- Consistent history and physical examination
- Intradermal testing with purified protein derivative (PPD) may be positive and can be supportive
- Tissue culture for *M. marinum* can be positive in up to 70% of cases with proper growth requirements
- Histologic features depend on the stage of development:
  1. <2–3 months: nonspecific mixed inflammation
  2. ~4 months: small epithelioid granulomas with a few multinucleated giant cells
  3. >6 months: typical tuberculoid granulomas which may have central necrosis with or without epidermal hyperkeratosis and papillomatosis
- Acid-fast organisms may be identified by Fite stain of skin biopsy specimens from early lesions

### Differential diagnosis

- Bacterial abscess (e.g. *S. aureus*)
- Verruca vulgaris
- Cutaneous tuberculosis
- Sarcoidosis
- Foreign-body granuloma
- Sporotrichosis
- Blastomycosis
- Leishmaniasis

### Treatment

- Multiple systemic antibiotics: tetracycline, minocycline, doxycycline, trimethoprim–sulfamethoxazole, clarithromycin and rifampin effective if given for at least 8 weeks
- Surgical excision can be used if unresponsive to antibiotics
- Proper cleaning of the reservoir (e.g. fish tank) should be undertaken if feasible

### Prognosis

- Resolves with scarring

- Can resolve without treatment in 1–2 years but may persist for over a decade without treatment
- Can produce secondary draining sinuses, synovitis, bursitis, arthritis or osteomyelitis
- Rare cases of fatal disseminated disease

## References

- Ang P, Rattana-Apiromyakit N, Goh CL. Retrospective study of *Mycobacterium marinum* skin infections. *Int J Dermatol* 2000; 9: 343–7
- Aubry A, Chosidow O, Caumes E, et al. Sixty-three cases of *Mycobacterium marinum* infection: clinical features, treatment, and antibiotic susceptibility of causative isolates. *Arch Intern Med* 2002; 162: 1746–52
- Bartralot R, Pujol RM, Garcia-Patos V, et al. Cutaneous infections due to nontuberculous mycobacteria: histopathological review of 28 cases. Comparative study between lesions observed in immunosuppressed patients and normal hosts. *J Cutan Pathol* 2000; 27: 124–9
- Pumberger W, Hallwirth U, Pawlowsky J, Pomberger G. Cervicofacial lymphadenitis due to atypical mycobacteria: a surgical disease. *Pediatr Dermatol* 2004; 21: 24–9
- Speight EL, Williams HC. Fish tank granuloma in a 14-month-old girl. *Pediatr Dermatol* 1997; 14: 209–12

## Tuberculosis

### Major points

- Classification of cutaneous lesions is based on route of transmission and immunologic response
- Exogenous source
  1. Previously uninfected: primary inoculation tuberculosis or primary tuberculosis complex
    - a. Typically occurs in a wound: abrasion, insect bite, ear piercing, circumcision site
    - b. Lesion develops 2–4 weeks after inoculation
    - c. Presents as a red-brown papule with ‘apple jelly’ translucence on diascopy that may ulcerate or crust
    - d. Associated with regional lymphadenopathy or lymphangitis
  2. Previously infected: reinfection tuberculosis or tuberculosis verrucosa cutis
    - a. Very rare in children
    - b. Presents with large verrucous papule or plaque at the site of re-inoculation
    - c. Due to strong immunity and hypersensitivity against *M. tuberculosis*
- 3. *Bacillus Calmette–Guérin* (BCG) vaccination
  - a. Site of injection develops an enlarging papule which ulcerates and then heals spontaneously over 2–4 weeks
  - b. May have associated lymphadenopathy
  - c. Rarely develops a local abscess, scrofuloderma, generalized eruption or lupus vulgaris
- 4. Scrofuloderma
  - a. Caused by direct extension of the organism to the skin overlying an infected lymph node or bone
  - b. Lesions are most common over the cervical lymph nodes
  - c. May ulcerate or form draining sinuses
  - d. Heals with characteristic cord-like scar
- 5. Tuberculosis cutis orificialis
  - a. Autoinoculation of the mucous membranes
  - b. Occurs at the mouth, nose, anus, urinary meatus or genitalia from infected secretions or visceral involvement
  - c. Presents as painful punched-out ulcers with undermined edges
  - d. Indicates failing resistance to disease
- Hematogenous spread
  1. Lupus vulgaris
    - a. Chronic, slowly progressive cutaneous form
    - b. Associated with strong immunity to *M. tuberculosis*
    - c. Presents with atrophic red-brown plaques on the head and neck in ~90% of cases
    - d. Lesions can ulcerate and cause ectropion or eclabium
  2. Miliary or disseminated tuberculosis
    - a. Presents with generalized macules, papules, pustules, nodules or purpura associated with fulminant pulmonary or meningeal involvement
    - b. Systemically ill with poor prognosis
  3. Metastatic tuberculosis
    - a. Occurs in patients with decreased immunity or malnutrition
    - b. Presents with ulcerated nodules and sinuses
  4. Congenital tuberculosis
    - a. Intrauterine infection through placental circulation
    - b. Presents at 4–8 weeks of age with discrete crusted papules on the face, trunk and extremities

- Tuberculids – cutaneous reaction related to an immunologic response to the organism; associated with an underlying focus of distant infection with hematogenous spread
  1. Papulonecrotic tuberculid
    - a. Most commonly seen in children
    - b. Presents with successive crops of dusky-red papules with or without central necrosis on the extensor extremities which heal spontaneously with varioliform scars
    - c. Typically have infected lymph nodes
  2. Lichen scrofulosorum
    - a. Occurs in children and young adults
    - b. Presents with clusters of lichenoid papules and discolored plaques on the trunk
    - c. Resolves spontaneously and can recur
    - d. Associated with infection of the bone or lymph nodes
  3. Erythema induratum (Bazin disease)
    - a. Typically seen in girls and young women
    - b. Presents with ulcerated nodules on the posterior calves with underlying panniculitis and vasculitis

### Pathogenesis

- Caused by infection with *Mycobacterium tuberculosis*
- Can be spread by exogenous or endogenous routes

### Diagnosis

- Positive tuberculin test with PPD
- Histology: variety of inflammatory reaction patterns including nonspecific acute inflammation, epithelial hyperplasia, non-necrotic granulomas and necrotic granulomas
- Fite stain of skin biopsy specimen may reveal acid-fast bacilli
- Culture of tissue
- Polymerase chain reaction for *M. tuberculosis* DNA in tissue

### Differential diagnosis

- Cat scratch disease
- Atypical mycobacterial infection
- Syphilis
- Leprosy
- Sporotrichosis
- Tularemia
- Sarcoidosis
- Cutaneous lymphoma

### Treatment

- Isoniazid (10–15 mg/kg per day) and rifampin (10–20 mg/kg per day) for 9 months
- Pyrazinamide, ethambutol or streptomycin is added for the initial 2 months of therapy if drug resistance is a consideration (Hispanic or Asian population), or if the duration of therapy is limited to 6 months

### Prognosis

- Variable course and prognosis depending on classification and systemic involvement
- Cutaneous tuberculosis typically heals with scarring

### References

- Antaya RJ, Gardner ES, Bettencourt MS, et al. Cutaneous complications of BCG vaccination in infants with immune disorders: two cases and a review of the literature. *Pediatr Dermatol* 2001; 18: 205–9
- Caksen H, Arslan S, Oner AF, et al. Multiple metastatic tuberculous abscesses in a severely malnourished infant. *Pediatr Dermatol* 2002; 19: 90–1
- Jacinto SS, Lopez de Leon P, Mendoza C. Cutaneous tuberculosis and other skin diseases in hospitalized, treated pulmonary tuberculosis patients in the Philippines. *Cutis* 2003; 72: 373–6
- Kivanc-Altunay I, Baysal Z, Ekmekci TR, Koslu A. Incidence of cutaneous tuberculosis in patients with organ tuberculosis. *Int J Dermatol* 2003; 42: 197–200
- Tan H, Karakuzu A, Arik A. Scrofuloderma after BCG vaccination. *Pediatr Dermatol* 2002; 19: 323–5
- Thami GP, Kaur S, Kanwar AJ, Mohan H. Lichen scrofulosorum: a rare manifestation of a common disease. *Pediatr Dermatol* 2002; 19: 122–6

## Leprosy

Synonym: Hansen disease

### Major points

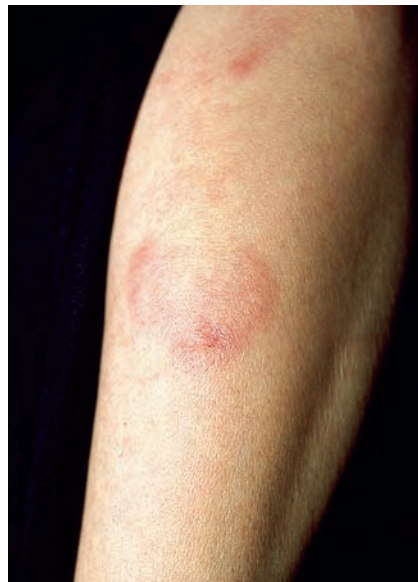- Chronic infection of the skin, nasal mucosa, nerves and eyes
- Clinical manifestations and disease course is dependent on the immune response of the host to *Mycobacterium leprae*
- Endemic in India, Southeast Asia, China, Central and East Africa, Central and South America, Louisiana, Hawaii and California



- Incubation period ~5 years
- Disease classification
  1. Tuberculoid leprosy
    - a. <3 skin lesions which are anesthetic and anhidrotic
    - b. Highest immune resistance and reactivity
    - c. Organisms are not identified in tissues (paucibacillary)
    - d. Nerve involvement
    - e. Strong positive reaction to the lepromin skin test
  2. Borderline tuberculoid leprosy
    - a. Few (3–10) skin lesions
    - b. May have enlarged nerves with mild motor impairment
  3. Borderline borderline leprosy
    - a. Indeterminate type
    - b. Multiple asymmetric annular plaques
    - c. Host resistance is unstable
    - d. Organisms may be identified
  4. Borderline lepromatous leprosy
    - a. Skin lesions are symmetrical and numerous
    - b. Nerve involvement is not prominent
  5. Lepromatous leprosy
    - a. Diffuse skin infiltration with characteristic leonine facies and loss of the eyebrows
    - b. No host resistance or reactivity
    - c. Organisms are numerous (multibacillary)
    - d. No reaction to lepromin skin test
- Childhood disease typically presents within the tuberculoid or indeterminate spectrum with hypopigmented macules (Figure 7.26)
- Children can also present with nerve involvement alone causing thickened peripheral nerves with sensory loss (e.g. temperature is lost first, followed by light touch and pinprick)

### Pathogenesis

- Infection caused by acid-fast bacillus *Mycobacterium leprae*
- Low infectivity
- Transmission is not fully known although droplet infection via an upper respiratory route is suspected
- Genetic predisposition may play a role in disease development
- Animal reservoirs: armadillos, monkeys and chimpanzees



**Figure 7.26** Leprosy – anesthetic plaque in a patient from Vietnam

### Diagnosis

- Slit skin smears stained with Ziehl–Neelsen reveals organisms
- Organisms cannot be cultured *in vitro*
- Histology varies depending on disease state
  1. Tuberculoid leprosy: noncaseating granulomas of epithelioid cells, Langhans giant cells and lymphocytes throughout the dermis; granulomas may extend along nerves; acid-fast bacilli are identified by Fite stain in <50% of cases
  2. Lepromatous leprosy: collections and sheets of histiocytes with a few lymphocytes; foamy macrophages (Virchow cells); Grenz zone; organisms are numerous within macrophages

### Differential diagnosis

- Pityriasis alba
- Tinea corporis
- Tinea versicolor
- Nummular eczema
- Granuloma annulare
- Vitiligo
- Sarcoidosis
- Syphilis
- Tuberculosis
- Lupus erythematosus

### Treatment

- Dapsone (1 mg/kg per day) for 1 year in all types
- Rifampin (10 mg/kg per day) should be added for 6 months in cases of tuberculoid, borderline tuberculoid or indeterminate disease
- Clofazimine (1 mg/kg per day) should be added for 2 years in cases of borderline, borderline lepromatous and lepromatous disease
- Type I reaction (downgrading or reversal reaction that represents an enhanced cell-mediated response to *M. leprae*) and type II reactions (erythema nodosum leprosum due to circulating immune complexes with potential multisystem involvement) are treated with systemic corticosteroids

### Prognosis

- Chronic disease with unpredictable course unless treated
- Reactional phenomenon can occur and leads to tissue damage, especially nerve injury with persistent neurologic sequelae
- 50% of patients will experience a reaction after starting antibiotic therapy

### References

- Boggild AK, Keystone JS, Kain KC. Leprosy: a primer for Canadian physicians. *Can Med Assoc J* 2004; 170: 71–8
- Cosma CL, Sherman DR, Ramakrishnan L. The secret lives of the pathogenic mycobacteria. *Ann Rev Microbiol* 2003; 57: 641–76
- Fakhouri R, Sotto MN, Manini MI, Margarido LC. Nodular leprosy of childhood and tuberculoid leprosy: a comparative, morphologic, immunopathologic and quantitative study of skin tissue reaction. *Int J Lepr Other Mycobact Dis* 2003; 71: 218–26
- Jayalakshmi P, Tong M, Sing S, Ganesapillai T. Leprosy in children. *Int J Lepr Other Mycobact Dis* 1997; 65: 95–7
- Ramos-e-Silva M, Rebello PF. Leprosy. Recognition and treatment. *Am J Clin Dermatol* 2001; 2: 203–11
- Rook GA, Martinelli R, Brunet LR. Innate immune responses to mycobacteria and the downregulation of atopic responses. *Curr Opin Allergy Clin Immunol* 2003; 3: 337–42

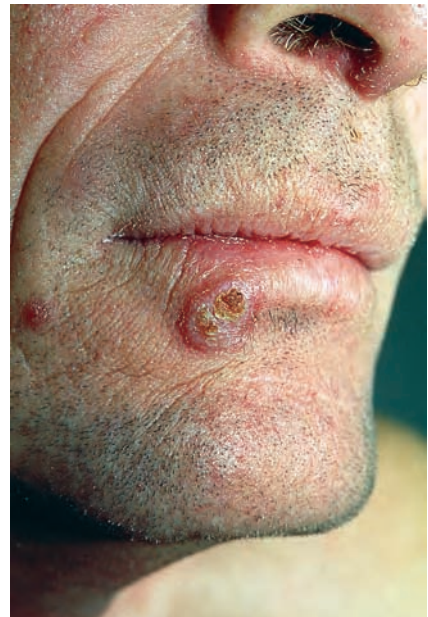### Syphilis

Synonym: lues

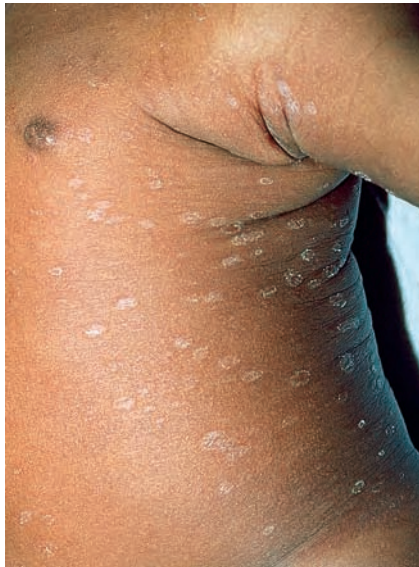### Major points

- Incubation period: 9–90 days after initial exposure

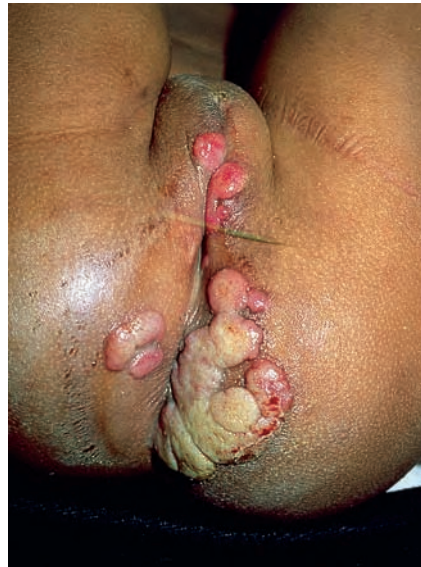- Often associated with other sexually transmitted diseases including HIV
- Congenital syphilis (See Chapter 2)
- Primary stage
  1. Initial lesion at the site of inoculation (chancre)
  2. Presents as a painless ulcer that heals over 1–6 weeks
  3. Typically found on the genitalia, but can also be seen on the lips, tongue, areola or hands (Figure 7.27)
- Secondary stage
  1. Begins 2–10 weeks after healing of the primary chancre
  2. Results from hematogenous spread
  3. Constitutional signs: generalized lymphadenopathy, hepatosplenomegaly
  4. Classic findings: diffuse papulosquamous eruption, specifically involving the palms and soles (Figures 7.28 and 7.29)
  5. Other skin findings: condyloma lata, (Figure 7.30) split papules, moth-eaten alopecia and mucous patches
- Subclinical, latent phase
  1. No signs or symptoms except for reactive serology
  2. May last 1–40 years



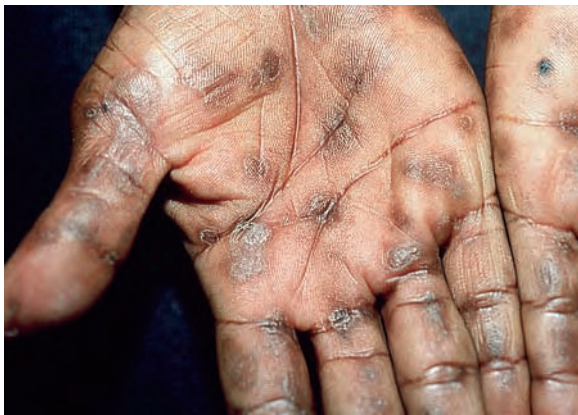**Figure 7.27** Syphilitic chancre in an adult



**Figure 7.28** Secondary syphilis – age 6 weeks acquired congenitally



**Figure 7.30** Secondary syphilis – condylomata lata (previously published in *Pediatric Dermatology* 1989; 6: 51–2, with permission)



**Figure 7.29** Secondary syphilis – typical copper-colored palmar lesions

- Tertiary or late stage
  1. Develops in one-third of untreated cases; rare in children
  2. Typically presents 3–5 years after the initial infection
  3. Presents with nodular lesion or gummas
  4. Can involve the bones, CNS and cardiovascular systems

#### Pathogenesis

- Caused by the spirochete *Treponema pallidum*

- Sexually transmitted disease with penetration of the organism through mucous membranes or abrasions in the stratum corneum
- Nonsexual transmission from an infected parent to a child is rare; sexual abuse should be assumed until proven otherwise

#### Diagnosis

- Nontreponemal antigen tests include the rapid plasma reagent (RPR) and Venereal Disease Research Laboratory (VDRL) test; typically positive within 5–6 weeks of infection; negative with therapy and in late syphilis
- Treponemal antigen tests are more sensitive and specific and include the microhemagglutination assay for *T. pallidum* (MHA-TP) or fluorescent treponemal antibody absorption (FTA-ABS) test; typically positive at 2–3 weeks after infection and remains positive for life
- Dark field examination and direct fluorescent antibody tests on lesional exudate or tissue
- Histology varies with stage of disease
  1. Primary syphilis: acanthosis, ulcer infiltrated by lymphocytes and plasma cells; Warthin–Starry silver stain may reveal the spirochete at the dermal–epidermal junction or around vessels

2. Secondary syphilis: epidermal psoriasiform hyperplasia, spongiosis, vacuolar alteration, papillary dermal edema, and a lymphohistiocytic perivascular and periadnexal infiltrate with variable number of plasma cells; spirochetes can be seen in one-third of cases with silver staining
3. Tertiary syphilis: granulomatous inflammation with central necrosis and peripheral infiltrate of lymphocytes, macrophages and plasma cells; spirochetes are typically not present

### *Differential diagnosis*

- Primary: herpes simplex, chancroid, granuloma inguinale
- Secondary: pityriasis rosea, psoriasis, drug eruptions, lichen planus, sarcoidosis
- Tertiary: leprosy, tuberculosis, sarcoidosis

### *Treatment*

- Parenteral penicillin G is the treatment of choice in all stages of syphilis, and is the only antibiotic with documented efficacy in pregnancy and in neurosyphilis
  1. Primary and secondary: benzathine penicillin G 50 000 units/kg intramuscularly up to 2.4 million units, in a single dose
  2. Latent: benzathine penicillin G 50 000 units/kg IM up to 2.4 million units with three doses at 1-week intervals
  3. Neurosyphilis: aqueous crystalline penicillin G 200 000–300 000 units/kg per day intravenously for 10 days
- Penicillin-allergic patients can be treated with:

1. Doxycycline 100 mg twice a day for 2–4 weeks depending on the duration of infection; associated with discoloration of teeth if <8 years old
2. Tetracycline 500 mg four times a day for 2–4 weeks depending on the duration of infection; associated with discoloration of teeth if <8 years old
3. Erythromycin 500 mg four times a day for 2 weeks

### *Prognosis*

- Variable depending on the stage of disease
- Untreated, the disease is slowly progressive and fatal with CNS and cardiac involvement

### *References*

- Burstein GR, Workowski KA. Sexually transmitted diseases treatment guidelines. *Curr Opin Pediatr* 2003; 15: 391–7
- Golden MR, Marra CM, Holmes KK. Update on syphilis: resurgence of an old problem. *J Am Med Assoc* 2003; 290: 1510–14
- Hollier LM, Cox SM. Syphilis. *Semin Perinatol* 1998; 22: 323–31
- Ozturk F, Gurses N, Sancak R, et al. Acquired secondary syphilis in a 6-year-old girl with no history of sexual abuse. *Cutis* 1998; 62: 150–1
- Pandhi D, Kumar S, Reddy BS. Sexually transmitted diseases in children. *J Dermatol* 2003; 30: 314–20
- Rubins S, Janniger CK, Schwartz RA. Congenital and acquired early childhood syphilis. *Cutis* 1995; 56: 132–6
- Vural M, Ilikkan B, Polat E, et al. A premature newborn with vesiculobullous skin lesions. *Eur J Pediatr* 2003; 162: 197–9





# VIRAL AND RICKETTSIAL DISEASES

---

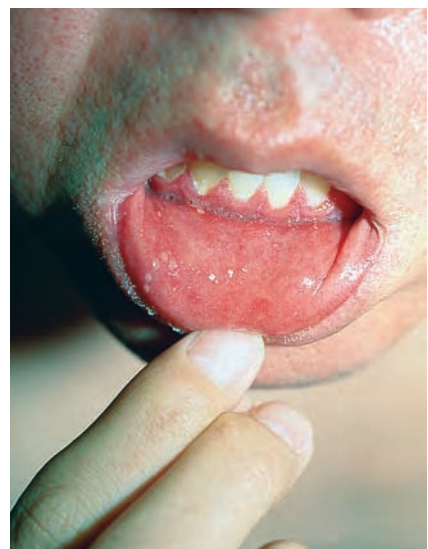## GENERAL

- Exanthems
  1. Morbilliform (measles-like)
  2. Petechial
  3. Scarletiform (scarlet-fever like)
  4. Vesiculobullous
  5. Papulonodular
  6. Asymmetric periflexural exanthem
- Enanthems (oral lesions)
  1. Nonspecific
  2. Specific
- Epidermal growths
  1. Verrucous
  2. Papular
- erythematous macules and papules which can become petechial (Figure 8.2)
- Complications (more common in young children, or those malnourished or chronically ill):
  1. Bacterial otitis media
  2. Bacterial pneumonia
  3. Encephalitis
  4. Myocarditis/pericarditis
  5. Thrombocytopenia
  6. Hepatitis
  7. Acute glomerulonephritis
- Atypical measles
  1. Usually in patients who have had killed measles vaccine, or failed vaccination

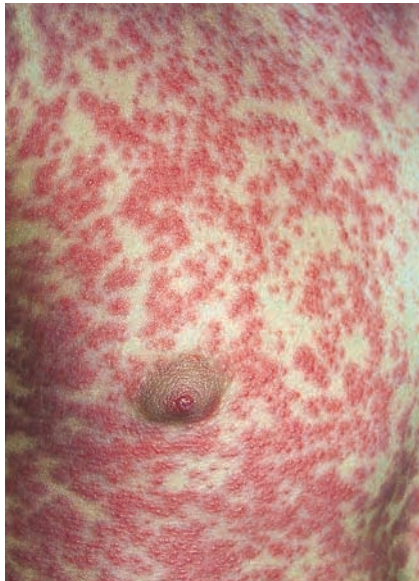## Measles (Rubeola)

### Major points

- Classic measles: prodrome of fever, malaise and upper respiratory symptoms followed by high fever, cough, coryza (rhinitis), conjunctivitis
- Incubation period 9–14 days
- Cough ‘barking’, sounds like croup
- Coryza (runny nose)
- Conjunctivitis with photophobia
- Lymphadenopathy, especially cervical
- Koplik spots (enanthem): 1-mm white spots (‘grains of sand’) on intensely erythematous background, usually on buccal mucosa (Figure 8.1)
- Characteristic rash begins on face as blotchy erythema, progresses downward to involve trunk and extremities with multiple discrete very



**Figure 8.1** Rubeola – Koplik spots: tiny white papules on oral mucosa



**Figure 8.2** Rubeola – intense morbilliform eruption

2. Symptoms: high fever, abdominal pain, pneumonitis, acral petechiae, vesicles, vesiculopustular eruption, vasculitis

### *Pathogenesis*

- Measles virus replicates in nasopharynx before disseminating
- Lymphoid hyperplasia occurs with wide distribution of virus-infected cells
- Rash is result of viremia with lodging of antigen and virus in the capillaries, followed by cell-mediated response
- Koplik spots contain viral nucleocapsids
- Lifelong immunity follows natural measles infection

### *Diagnosis*

- Characteristic rash and symptoms
- Positive serologic test for measles IgM antibody
- Viral isolation from nasopharyngeal secretions, blood or urine
- Rise in measles IgG antibody, acute and convalescent sera at first encounter and after 2–4 weeks
- Viral antigen detected by immunofluorescence in cell smears from nasal aspirates early in illness

### *Differential diagnosis*

- Rocky Mountain spotted fever

- Drug eruptions
- Vasculitis

### *Treatment*

- Isolation of patient; highly contagious
- Symptomatic treatment
- Antibiotics for secondary infection
- Immune globulin 0.25 ml/kg of body weight, intramuscularly; immunocompromised children 0.5 ml/kg (maximum 15 ml) given within 6 days attenuates the infection in exposed persons
- Immunization with live attenuated vaccine reduces the incidence of measles in contacts
- Vitamin A supplementation 200 000 IU orally for age >1 year; 100 000 IU for 6 months to 1 year. Repeat next day and 4 weeks later if there is ophthalmologic evidence of vitamin deficiency

### *Prognosis*

- Lifelong immunity follows natural measles infection or immunization
- High morbidity and mortality rate in malnourished or immunosuppressed patients

### *References*

- Bialecki C, Feder HM, Grant-Kels JM. The six classic childhood exanthems: a review and update. *J Am Acad Dermatol* 1989; 21: 891–903
- Butler JC, Havens PL, Sowell AL, et al. Measles severity and serum retinal (vitamin A) concentration among children in the United States. *Pediatrics* 1993; 91: 1176–81
- Frieden IJ, Resnick SD. Childhood exanthems. Old and new. *Pediatr Clin North Am* 1991; 38: 859–87
- Rall GE. Measles virus 1998–2002: progress and controversy. *Annu Rev Microbiol* 2003; 57: 343–67
- Report of the Committee on Infectious Diseases. Red Book, 26th edn. American Academy of Pediatrics: Elk Grove Village, IL, 2003: 419–29
- Somech R, Spierer Z. Uncommon presentation of some common pediatric diseases. *Adv Pediatr* 2003; 50: 269–304
- Venczel L, Rota J, Dietz V, et al. The Measles Laboratory Network in the region of the Americas. *J Infect Dis* 2003; 187 (Suppl 1): S140–5

## **Rubella**

### *Major points*

- Incubation period ~18 days (14–21 days)

- Prodrome may be mild or negligible, lasts 1–5 days, with fever up to 39°C, headache, malaise, sore throat, conjunctivitis
- 50% of infections are asymptomatic
- Rash may be absent in 40% of cases
- Enanthem (Forschheimer sign) present in 20%; consists of red macules or petechiae on soft palate
- Lymph node enlargement begins in prodrome in suboccipital, postauricular and cervical glands
- Rash appears on face and spreads downwards to trunk and limbs, made up of pink macules, which become confluent; clears quickly in 3–4 days
- Complications few in childhood
- Complications in adults and older children: monoarticular arthritis, which lasts ~1 month; rarely, purpura or encephalitis
- Rubella in pregnancy
  1. Fetal damage in 90% of cases in first 11 weeks of pregnancy (rubella embryopathy)
  2. Between 12 and 16 weeks' gestation, risk of deafness is 25%
  3. Major defects: deafness, mental retardation, heart damage, eye damage (cataracts, glaucoma), microcephaly, growth retardation
- Neonatal period
  1. Thrombocytopenic purpura which clears spontaneously in several weeks
  2. Jaundice (rubella hepatitis)
  3. Bone lesions
  4. Recurrent exanthem which may recur during first 5 years
  5. 'Blueberry muffin' appearance with blue/purple macules, papules in a generalized pattern due to extramedullary hematopoiesis
- Infectivity
  1. Patients infective for 2 days before rash and 7 days after rash begins
  2. In congenital rubella, virus can be shed up to 5–6 years
- Epidemics occur in spring, mainly in older children and adults

### Pathogenesis

- Rubella virus member of Rubivirus genus, RNA virus, Togaviridae
- Virus spreads through direct or droplet contact from nasopharyngeal secretions
- Rash may be result of viral dissemination to skin
- Mechanism of embryopathy unknown

### Diagnosis

- Morphology of rash with enlarged lymph nodes suggestive of diagnosis
- Serology with four-fold increase in antibody titers in acute and convalescent serum
- Specific IgM antibody in previous infection
- Viral isolation from peripheral blood leukocytes, stool or urine for months to years after birth in patients with rubella embryopathy or from nasal mucosa in acute disease

### Differential diagnosis

- Acute viral disease in children or adults (Table 8.1) or drug eruptions
- Congenital infections (toxoplasmosis, syphilis, cytomegalovirus (CMV), herpes simplex), neonatal lupus erythematosus, Wiskott–Aldrich syndrome, hereditary platelet disorders

### Treatment

- Symptomatic treatment for acute disease
- Nonsteroidal anti-inflammatory agents for arthritis
- Prophylaxis
  1. Active immunization with live attenuated rubella virus. Administration in pregnancy is contraindicated. Arthralgia is common

**Table 8.1 Viral morbilliform eruptions**

#### *Characteristic disease pattern*

Measles  
 Rubella  
 Roseola  
 Erythema infectiosum  
 Infectious mononucleosis  
 Pityriasis rosea  
 Hand, foot and mouth disease

#### *Nonspecific morbilliform eruptions*

Hepatitis A, B, C, D, E  
 Mumps  
 Echovirus  
 Coxsackievirus  
 Respiratory syncytial virus  
 Cytomegalovirus  
 Adenoviruses  
 Dengue fever  
 Ehrlichiosis  
 Colorado tick fever  
 HIV

- Immune serum globulin given 0.5 ml/kg intramuscularly

### Prognosis

- Good in acute disease
- Poor in rubella embryopathy. Multidisciplinary approach and birth defects clinic is advisable

### References

- Bale JF Jr. Congenital infections. *Neurol Clin* 2002; 20: 1039–60, vii
- Bialecki C, Feder HM, Grant-Kels JM. The six classic childhood exanthems: a review and update. *J Am Acad Dermatol* 1989; 21: 891–903
- Hartley AH, Rasmussen JE. Infectious exanthems. *Pediatr Rev* 1988; 9: 321–9
- Report of the Committee on Infectious Diseases. Red Book, 26th edn. American Academy of Pediatrics: Elk Grove Village, IL, 2003: 536–41
- Spika JS, Wassilak S, Pebody R, et al. Measles and rubella in the World Health Organization European region: diversity creates challenges. *J Inf Dis* 2003; 187 (Suppl 1): S191–7
- Vander Straten MR, Tying SK. Rubella. *Dermatol Clin* 2002; 20: 225–31

## Roseola (exanthem subitum, sixth disease)

### Major points

- Incubation period ~9 days
- Occurs mainly in infants under 2 years of age
- Abrupt high fever (39.5–40°C) for 2–5 days, with child looking otherwise well
- When the temperature falls, rash breaks out
- Rash consists of pink, morbilliform maculopapules and fades within 1–2 days
- Rash starts on neck and trunk, and later spreads to extremities and face
- Occasionally febrile seizures occur. Encephalitis rare
- Subclinical infection common
- Other features:
  - Mild edema of eyelids
  - Cervical lymphadenopathy
  - Cough
  - Otitis media
  - Hematuria

### Pathogenesis

- Caused by human herpesvirus-6 (HHV-6), member of the family Herpesviridae; a large, double-stranded DNA virus
- HHV-6 preferentially attacks circulating lymphocytes
- After initial infection, virus persists and can be detected in saliva

### Diagnosis

- Clinical picture usually specific with lack of symptoms during febrile stage, and eruption begins as fever subsides
- HHV-6 can be identified by culture of peripheral blood lymphocytes
- Serodiagnosis with rise in antibody production
- Skin lesions can demonstrate virus

### Differential diagnosis

See Table 8.1: drug eruptions

### Treatment

- Symptomatic treatment of fever with antipyretics and tepid sponge baths
- Follow-up at 2 days is recommended to confirm the diagnosis or rule out other causes of morbilliform rash and fever
- Isolation of the hospitalized patient is not necessary

### Prognosis

- Benign in infants
- Most older children and adults are immune, but may have a mild mononucleosis-like illness with fever, rash, cervical lymphadenopathy and possibly hepatitis for up to 3 months
- HHV-6 has been isolated from peripheral B cells in HIV patients, and may become reactivated in immunosuppressed patients with fever, hepatitis, bone marrow suppression and pneumonia
- By age 4 years, almost all individuals are seropositive

### References

- Bialecki C, Feder HM, Grant-Kels JM. The six classic childhood exanthems: a review and update. *J Am Acad Dermatol* 1989; 21: 891–903
- Blauvelt A. Skin diseases associated with human herpesvirus 6, 7, and 8 infection. *Symposium Proceedings. J Invest Dermatol* 2001; 6: 197–202

De Araujo T, Berman B, Weinstein A. Human herpesviruses 6 and 7. *Dermatol Clin* 2002; 20: 301–6

Dockrell DH. Human herpesvirus 6: molecular biology and clinical features. *J Med Microbiol* 2003; 52: 5–18

Report of the Committee on Infectious Diseases. Red Book, 26th edn. American Academy of Pediatrics: Elk Grove Village, IL, 2003: 357–9

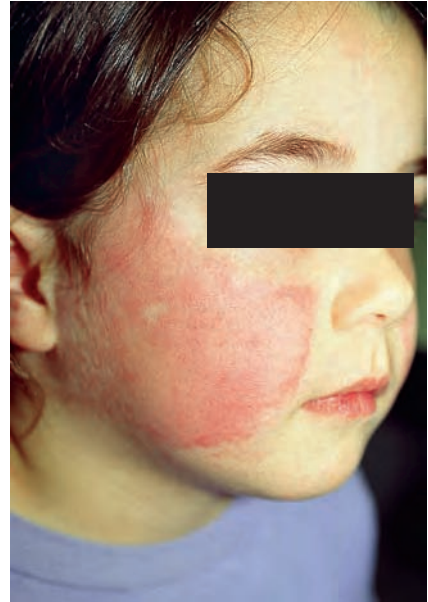## Erythema infectiosum (fifth disease)

### Major points

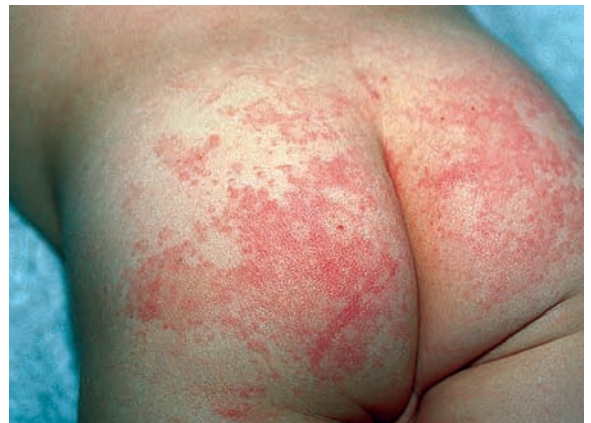- Common in school-aged children
- Classical presentation: intense confluent redness of both cheeks ('slapped cheeks') with circumoral pallor (Figure 8.3)
- Later symmetric, lacy, reticulated, macular, erythematous eruption on arms, legs, chest, abdomen or buttocks (Figure 8.4)
- Eruption lasts 3–5 days, but can have exacerbations up to 4 months, especially after exercise, fever, or sun-exposure
- Mild systemic symptoms and fever seen in 15–30%
- Occasionally, other eruptions may occur: morbilliform, vesicular, purpuric (particularly in a 'gloves and socks' distribution)
- Symmetric arthritis of hands, wrists and knees may occur which resolves in 1–2 months; more common in adults
- Red cell aplasia and transient aplastic crisis may occur in patients with chronic hemolytic anemias (e.g. sickle cell disease) lasting 7–10 days; may be persistent
- Chronic infection may result in systemic necrotizing vasculitis
- In pregnant women, fetal death may occur, caused by aplastic crisis in the fetus with resultant hydrops fetalis
- Risk of fetal death is <10% in first half of pregnancy, and nonsignificant in second half
- Conjunctivitis may occur
- Probably not contagious once skin eruption occurs except in patients with aplastic crisis who can be contagious for at least 1 week after onset of rash

### Pathogenesis

- Caused by parvovirus B19, a small DNA virus, which can be identified in skin lesions by electron microscopy



**Figure 8.3** Erythema infectiosum (fifth disease) – 'slapped cheeks'



**Figure 8.4** Erythema infectiosum – typical reticulated erythema

- Virus replicates in erythroid bone marrow cells causing transient aplastic crises in children with chronic hemolytic anemias
- Spread by respiratory secretions and blood
- Patients with aplastic crises are highly contagious before onset of clinical symptoms until a week or longer afterwards
- Incubation period usually 4–14 days but can be up to 20 days



### Diagnosis

- Cutaneous pattern characteristic
- Serum specific parvovirus B19-IgM antibody within 30 days of onset of illness is diagnostic. Serum IgG antibody indicates previous infection and immunity
- Best method for detecting chronic infection is demonstrating virus by nucleic acid hybridization assay or polymerase chain reaction (PCR) assay
- Viral B19 antigens can be detected by radioimmunoassay or enzyme assay

### Differential diagnosis

- Sunburn
- Drug eruptions (morbilliform)
- Collagen vascular diseases (reticulated pattern)
- See Table 8.1

### Treatment

- Supportive care
- Isolation from patients at risk for complications (pregnant women, chronic hemolytic anemia patients)
- Contact isolation for hospitalized children with aplastic crises or immunosuppressed patients
- Intravenous immunoglobulin may be effective in immunosuppressed children
- Good hand washing techniques

### Prognosis

- Excellent in normal children
- Children with arthritis, pregnant women, immunosuppressed patients and those with chronic hemolytic anemias should be followed until complications have subsided

### References

- Frieden IJ, Resnick SD. Childhood exanthems. Old and new. *Pediatr Clin North Am* 1991; 38: 859–87
- Heegaard ED, Brown KE. Human parvovirus B19. *Clin Microbiol Rev* 2002; 15: 485–505
- Katta R. Parvovirus B19: a review. *Dermatol Clin* 2002; 20: 333–42
- Qari M, Qadri SMH. Parvovirus B19 infection. *Postgrad Med* 1996; 100: 239–52
- Report of the Committee on Infectious Diseases. Red Book, 26th edn. American Academy of Pediatrics: Elk Grove Village, IL, 2003: 459–61

Silver MM, Hellmann J, Zielenska M, et al. Anemia, blueberry muffin rash and hepatomegaly in a newborn infant. *J Pediatr* 1996; 12: 579–86

Young NS, Brown KE. Parvovirus B19. *N Engl J Med* 2004; 350: 586–97

### Gianotti–Crosti syndrome

Synonym: papular acrodermatitis of childhood, papulovesicular acrolated syndrome

### Major points

- Characterized by numerous skin-colored or pink flat topped lichenoid symmetrical papules, 5–10 mm in size (Figures 8.5 and 8.6)
- Lesions begin individually and then often coalesce
- Distribution mainly on the arms, legs and face, and sparing trunk
- Associated findings:
  1. Low-grade fever and mild upper respiratory symptoms
  2. Lymphadenopathy
  3. Diarrhea
  4. Cough
  5. Hepatosplenomegaly
  6. Enanthem
- Age usually 8 months to 4 years
- Duration of rash 2–8 weeks

### Pathogenesis

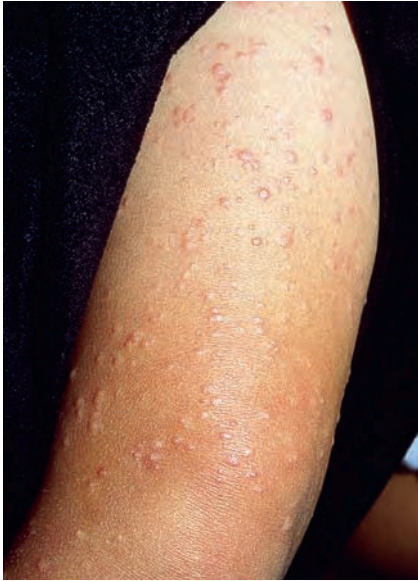- Various viral causes: Epstein–Barr virus (EBV), echovirus, coxsackie B virus, hepatitis A, B, or C, CMV, respiratory syncytial virus, parainfluenza virus, parvovirus B19, rubella virus, poliovirus, adenovirus, rotavirus, HHV-6, and immunizations with diphtheria, pertussis or influenza vaccines

### Diagnosis

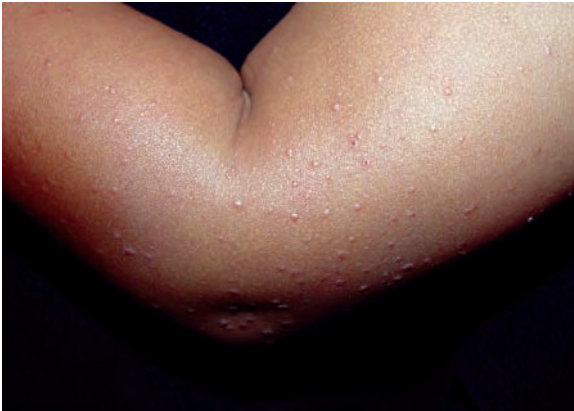- Characteristic clinical picture
- Biopsy usually not necessary
- Histology: spongiosis, exocytosis of lymphocytes, edema of the papillary dermis and a perivascular lymphocytic infiltrate

### Differential diagnosis

- Molluscum contagiosum
- Viral exanthem (nonspecific)
- Scarlet fever
- Kawasaki syndrome



**Figure 8.5** Gianotti–Crosti syndrome – lichenoid monomorphic papules on extremities



**Figure 8.6** Gianotti–Crosti syndrome – individual lichenoid papules

- Measles
- Rubella

#### *Treatment*

- Usually no treatment is needed
- If rash is symptomatic, topical corticosteroids may be helpful

#### *Prognosis*

- Rash resolves within 2–8 weeks

#### *References*

- Caputo R, Gelmetti C, Ermacora E, et al. Gianotti–Crosti syndrome: a retrospective analysis of 308 cases. *J Am Acad Dermatol* 1992; 26: 207–10
- Chuh AA. Diagnostic criteria for Gianotti–Crosti syndrome: a prospective case–control study for validity assessment. *Cutis* 2001; 68: 207–13
- Hoffmann B, Schuppe H-C, Adams O, et al. Gianotti–Crosti syndrome associated with Epstein–Barr virus infection. *Pediatr Dermatol* 1997; 14: 273–7
- Nelson JS, Stone MS. Update on selected viral exanthems. *Curr Opin Pediatr* 2000; 12: 359–64
- Report of the Committee on Infectious Diseases. *Red Book*, 26th edn. American Academy of Pediatrics: Elk Grove Village, IL, 2003: 419–29

#### **Unilateral laterothoracic exanthem**

Synonym: Asymmetric periflexural exanthem

#### *Major points*

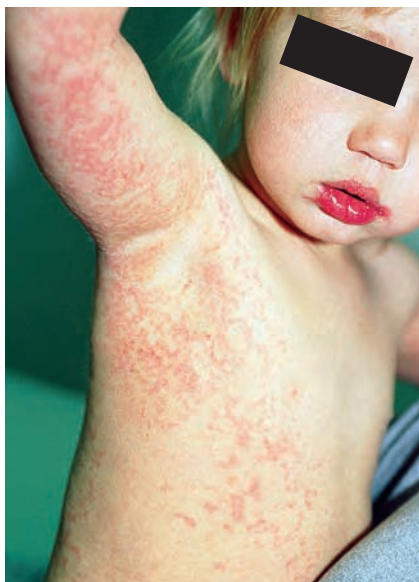- Female/male ratio >1
- Average age ~2 years, and most cases under 4 years
- More common in White children
- More common in spring
- Morbilliform, erythematous eczematous papules (occasionally with a pallid halo) on unilateral trunk (Figure 8.7)
- Begins as a discrete patch with small lichenoid papules, then extends into axilla over 3 weeks, becoming inflamed
- Lesions become confluent, then gradually clear, leaving some postinflammatory hyperpigmentation
- Similar lesions may appear on other side and involve extremities
- Pruritus uncommon
- Lesions last up to 6 weeks, with rare recurrences
- Usually no systemic symptoms

#### *Pathogenesis*

- Viral cause suggested by clinical symptoms, but no clear agent has been identified

#### *Diagnosis*

- Clinical appearance
- Histology: superficial perivascular dermatitis with some foci of lichenoid dermatitis



**Figure 8.7** Unilateral laterothoracic exanthem – beginning on the lateral trunk

### *Differential diagnosis*

- Atopic dermatitis
- Molluscum contagiosum
- Contact dermatitis
- Drug eruption

### *Treatment*

- Topical steroids and antihistamines may be helpful if pruritus is present

### *Prognosis*

- Self-limited
- May leave postinflammatory hyperpigmentation

### *References*

- Gutzmer R, Herbst RA, Kiehl P, et al. Unilateral laterothoracic exanthem (asymmetrical periflexural exanthem of childhood): report of an adult patient. *J Am Acad Dermatol* 1997; 37: 484–5
- McCuaig CC, Russo P, Powell J, et al. Unilateral laterothoracic exanthem. *J Am Acad Dermatol* 1996; 34: 979–84
- Resnick SD. New aspects of exanthematous diseases of childhood. *Dermatol Clin* 1997; 15: 257–66
- Taieb A, Megraud F, Legrain V, et al. Asymmetric periflexural exanthem of childhood. *J Am Acad Dermatol* 1993; 29: 391–3

## **Echovirus**

### *Major points*

- Morbilliform eruption, occasionally with petechiae
- Found worldwide and ubiquitous
- Incubation period 3–5 days
- Spread by fecal–oral route
- Despite enteric replication, gastrointestinal symptoms uncommon
- Severe symptoms can occur rarely: encephalitis, polio-like paralysis, neonatal hepatic necrosis
- Attack rates highest in infants and toddlers
- Occurs usually in summer in epidemics, particularly in crowded living conditions
- Echovirus 16 ('Boston exanthem') seen in epidemic form and may mimic roseola with morbilliform rash and sometimes vesicles appearing after 2–3 days of fever
  1. Adenopathy common
  2. Aseptic meningitis occasional
- Echovirus 9 usually shows a morbilliform eruption with acral petechiae which lasts 2–7 days
  1. Can be epidemic, usually in summer and fall in temperate climates. No seasonal pattern in tropics
  2. Primarily in preschool children
  3. Fever, sore throat, abdominal pain and vomiting
- Echoviruses 2, 4, 6, 11, 25, 30 show similar signs and symptoms
  1. Aseptic meningitis common

### *Pathogenesis*

- Echoviruses (33 types), small RNA viruses in picornavirus group

### *Diagnosis*

- Culture of echovirus from stool and throat washings, cerebrospinal fluid, or blood; biopsy if indicated
- Serum for acute and convalescent titers of antibodies (at 4 weeks) can be drawn and tested if tissue culture results are positive (enteroviruses can persist in the lower gastrointestinal tract for 8–12 weeks and may not be causative)

### *Differential diagnosis*

- Coxsackie viruses
- Roseola (human herpesvirus-6)

- Atypical measles
- Rocky Mountain spotted fever
- Meningococemia
- Streptococcal infection
- Epstein–Barr virus (EBV) infection
- Hepatitis
- Rubella
- Dengue fever
- Typhus

### *Treatment*

- Symptomatic treatment
- Very contagious
- Follow-up visits usually not necessary
- Intravenous immunoglobulin with a high antibody titer to the infecting virus may be beneficial in immunocompromised patients or life-threatening neonatal infection

### *Prognosis*

- Excellent unless complications cause permanent damage

### *References*

Frieden IJ, Resnick SD. Childhood exanthems. Old and new. *Pediatr Clin North Am* 1991; 38: 859–87

Kim KS, Hufnagel G, Chapman NM, Tracy S. The group B coxsackieviruses and myocarditis. *Rev Med Virol* 2001; 11: 355–68

Report of the Committee on Infectious Diseases. Red Book, 26th edn. American Academy of Pediatrics: Elk Grove Village, IL, 2003: 269–70

## **Infectious mononucleosis**

### *Major points*

- Can occur in all ages, with peak found in adolescents and young adults
- Onset is usually insidious
- Spectrum of disease is extremely variable, ranging from asymptomatic to fatal
- Presenting symptoms
  1. Fatigue
  2. Fever
  3. Generalized lymphadenopathy
  4. Sore throat with exudative pharyngitis
  5. Headache
  6. Splenomegaly

7. Jaundice
  8. Hepatomegaly
  9. Arthritis
  10. Rash (~15%): pink, fleeting morbilliform eruption lasting 1–5 days
- Treatment with ampicillin or penicillin for sore throat results in morbilliform rash in up to 80%: bright red papules or urticarial plaques; may persist for 7–10 days
  - Palmar erythema may be prominent
  - Neurologic symptoms: spatial and visual distortion, encephalitis, meningitis, neuritis, or Guillain–Barré syndrome
  - Acute phase lasts 2–3 weeks; begins with fever and sore throat
  - Extreme fatigue may persist for 3 months
  - Rare complications: splenic rupture, thrombocytopenia, agranulocytosis, hemolytic anemia, orchitis and myocarditis
  - Incubation period is 4–8 weeks in adolescents, shorter in prepubertal children
  - Transmission by close personal contact (oral, fecal) or blood transfusion
  - Asymptomatic carriage is common

### *Pathogenesis*

- Caused by several different viruses:
  1. Epstein–Barr virus (herpesvirus-4)
    - a. More common in adolescents and is the cause in 85%
    - b. EBV replicates in B-lymphocytes, which in normal patients are inhibited by natural killer and T-cell responses
    - c. In patients with cellular immune deficiencies, fatal dissemination or B-cell lymphoma can occur
  2. More common in infants and young children:
    - a. Cytomegalovirus (herpesvirus-5)
    - b. Human herpesvirus 6, 7
    - c. Rubella
    - d. Human parvovirus B19

### *Diagnosis*

- EBV antibody tests
  1. Nonspecific serologic tests for heterophile antibody, Paul–Bunnell test and slide agglutination
  2. Viral capsid antigen (VCA)-IgG antibody found in high titers early in infection

3. IgM anti-VCA antibody and early antigen (EA) antibody; useful in identifying recent infections
  4. Serum antibodies against EBV nuclear antigen (EBNA) demonstrate past or recent infection
  5. PCR or culture of saliva or peripheral blood mononuclear cells for EBV
- Patients who are negative for EBV should be tested for CMV and other causes

### *Differential diagnosis*

- Streptococcal pharyngitis
- Parvovirus B19 infection
- Idiopathic thrombocytopenic purpura
- Systemic lupus erythematosus
- Malignancies

### *Treatment*

- In mild cases, no treatment is necessary
- In severe cases with complications, prednisone 2–3 mg/kg per day for 3 days
- Ampicillin or penicillin should be avoided
- Avoid contact sports where abdominal injury may cause splenic rupture
- Weekly visits to assess the course of disease and complications
- In severe disease, hospitalization may be necessary
- Isolation not necessary

### *Prognosis*

- Excellent unless there are complications

### *References*

Ikediodi NI, Tying SK. Cutaneous manifestations of Epstein–Barr virus infection. *Dermatol Clin* 2002; 20: 283–9

Ohga S, Nomura A, Takada H, Hara T. Immunological aspects of Epstein–Barr virus infection. *Crit Rev Oncol Hematol* 2002; 44: 203–15

Report of the Committee on Infectious Diseases. Red Book, 26th edn. American Academy of Pediatrics: Elk Grove Village, IL, 2003: 271–3

Yachie A, Kanegane H, Kasahara Y. Epstein–Barr virus-associated T-/natural killer cell lymphoproliferative diseases. *Semin Hematol* 2003; 40: 124–32

## **Hepatitis**

### *Major points*

- Although viral hepatitis is not usually associated with an exanthem, it can cause a

morbilliform, urticarial, lichenoid or scarlatiniform eruption

- Hepatitis A and hepatitis E
  1. Incubation period is 15–50 days, average 25–30 days
  2. Symptoms: abrupt fever, jaundice, anorexia, nausea, malaise and occasionally upper respiratory symptoms
  3. Subclinical cases are more common, especially in younger children
  4. Sometimes have a preceding morbilliform eruption with following jaundice and development of icterus and hepatic tenderness
  5. Pruritus may occur
- Hepatitis B, hepatitis C, hepatitis D
  1. Spectrum of symptoms from asymptomatic seroconversion to clinical hepatitis with jaundice
  2. Anicteric infection is most common in young children
  3. Chronic infection can lead to cirrhosis, chronic active hepatitis or hepatocellular carcinoma
  4. Symptoms:
    - a. Morbilliform, urticarial and serum-sickness-like eruptions are the most common skin manifestations
    - b. Joint swelling
    - c. Fixed urticaria, lichen planus
    - d. Lasts 7–10 days, and resolves with the onset of hepatic symptoms
    - e. Leukocytoclastic vasculitis or periarteritis nodosa
- Papular acrodermatitis of childhood (See Gianotti–Crosti syndrome)

### *Pathogenesis*

- Hepatitis A virus (HAV), single-stranded RNA viruses replicate in liver
  1. Viral shedding into bowel during infectious stage, usually 1–3 weeks
  2. Viremia may occur and produce rash
  3. Hepatitis A and E are primarily waterborne, transmitted by human fecal contamination of food, causing local outbreaks
- Hepatitis B virus (HBV), double-stranded DNA virus, replicates by reverse transcription
  1. Reproduces as complete virus particles and capsids which circulate in the blood



2. Incubation period is 45–160 days, average 120 days
  3. Transmitted by blood or body fluids such as wound exudates, semen, saliva
  4. Chronic carrier is primary reservoir
  5. HBV can survive 1 week on dry objects
  6. Groups at high risk: intravenous drug users, multiple heterosexual partners, homosexual men, hemodialysis patients
- Hepatitis C virus, single-stranded RNA virus in a separate genus in Flaviviridae family
  - Hepatitis delta virus, unique single-stranded RNA virus which needs a co-infection with hepatitis B in order to enter hepatocytes and can result in fulminant or chronic hepatitis
  - Hepatitis E, single-stranded RNA virus, similar to calicivirus, acquired by fecal–oral route; incubation period ~40 days

### Diagnosis

- Serum aminotransferase elevated
- Serologic tests for IgM antihepatitis antibodies by enzyme-linked immunosorbent assay (ELISA) or radioimmunoassay diagnostic
- Hepatitis A
  1. Presence of IgM anti-HAV antibodies usually indicates recent infection, disappearing within 6 months
  2. IgG anti-HAV antibodies develop after IgM anti-HAV antibodies, and indicate past infection
- Hepatitis B
  1. Acute active infection
    - a. Hepatitis B surface antigen positive (HBsAg+)
    - b. Hepatitis B core antigen positive (HBcAg+)
    - c. Hepatitis B e antigen positive (HBeAg+)
    - d. IgM anti-hepatitis B core antibody positive (Anti-HBcAb+)
  2. Chronic infection
    - a. HBsAg+
    - b. IgG anti-hepatitis B surface antibody negative (Anti-HBsAb–)
    - c. IgG anti-hepatitis B core antibody positive (Anti-HBcAb+)
  3. Immunized: IgG anti-hepatitis B surface antibody positive (Anti-HBsAb+)
  4. Prior infection: Anti-HBsAb+, HBsAg–
- Hepatitis C: Anti-HCV+

### Differential diagnosis

- Viral exanthems, particularly rubella, parvovirus B19
- Urticaria
- Leukocytoclastic vasculitis of other etiologies
- Contact dermatitis
- Atopic dermatitis
- Lichen planus

### Treatment

- Bed rest, supportive measures
- Exposed individuals should receive human immune serum globulin 0.02 ml/kg, as soon as possible after exposure
- In HBV, hepatitis B immunoglobulin (HBIG), 0.06 ml/kg within 24 hours of exposure, and hepatitis B vaccine within 7 days of exposure. Repeat vaccination should be given 1 and 6 months later
- For perinatal exposure to HBV, 0.5 ml of HBIG within 12 hours of birth, and initial dose of vaccine at 7 days, 1 month and 6 months
- Education and good hygiene measures, as HAV may survive on objects in the environment for weeks
- Report to local public health officials
- Hepatitis B immunoprophylaxis is recommended
- Hepatitis C (chronic): interferon- $\alpha$

### Prognosis

- Course is usually benign, but can progress to liver failure

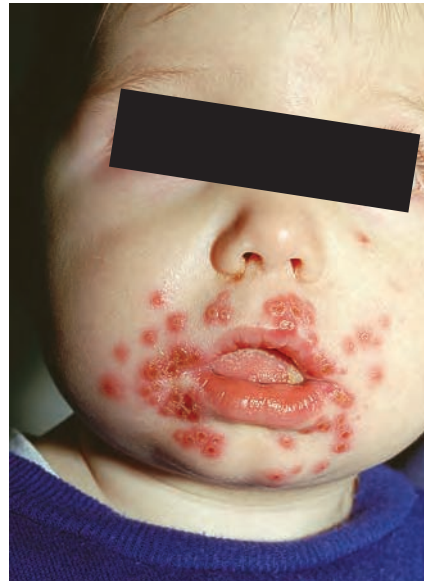### References

- Fontana RJ, Everson GT, Tuteja S, et al. Controversies in the management of hepatitis C patients with advanced fibrosis and cirrhosis. *Clin Gastroenterol Hepatol* 2004; 2: 183–97
- Ganem D, Prince AM. Hepatitis B virus infection – natural history and clinical consequences. *N Engl J Med* 2004; 350: 1118–29
- Report of the Committee on Infectious Diseases. Red Book, 26th edn. American Academy of Pediatrics: Elk Grove Village, IL, 2003: 309–43
- Roberts EA. Neonatal hepatitis syndrome. *Semin Neonatol* 2003; 8: 357–74
- Shearer CM, Jackson JM, Callen JP. Symmetric polyarthrititis with livedo reticularis: a newly recognized manifestation of hepatitis C virus infection. *J Am Acad Dermatol* 1997; 37: 659–61

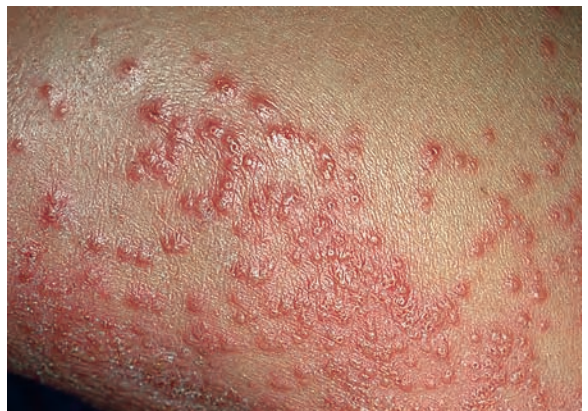## Herpes simplex

### Major points

- Lesions are typically grouped vesicles on erythematous base
  1. Although characteristically around the mouth or genital region, can be found anywhere
  2. On mucous membranes, blister roof easily becomes eroded
  3. Regional lymphadenopathy often prominent
  4. Generally heals within 8 days
  5. Herpes simplex virus (HSV) is ubiquitous and transmitted from direct contact with infected oral secretions or lesions
  6. Incubation period: 2 days to 2 weeks
- Manifestations in children and infants >1 month of age (Figure 8.8)
  1. Gingivostomatitis is commonly first manifestation of primary HSV infection, with fever, irritability, foul breath and inability to take liquids orally
    - a. Usually asymptomatic or diagnosed as a nonspecific 'viral' enanthem
    - b. Lasts 7–14 days
    - c. May need hospitalization if oral intake is poor
  2. Eczema herpeticum (Kaposi varicelliform eruption): diffuse infection concentrated in areas of dermatitis or other skin disorders (e.g. burns, Darier disease) with characteristic grouped vesicles on erythematous bases and punched out erosions (Figure 8.19)
    - a. High fever, lassitude, hundreds of vesicles
    - b. May be primary infection with HSV
    - c. Can be recurrent
  3. Immunocompromised patients: severe local lesions may occur with central necrosis; visceral involvement may occur
- Neonatal herpes infection (<4 weeks of age)
  1. 75–80% caused by HSV-2; the rest by HSV-1
  2. Characteristics of different presentations:
    - a. Generalized systemic infection with multiorgan involvement and encephalitis
    - b. Localized CNS disease
    - c. Disease localized to skin, eyes, or mucous membranes (Figure 8.10)
    - d. Intrauterine infection, usually in first trimester, which causes malformations and small-for-gestational-age infants
  3. Presents at birth to 6 weeks of age, with disseminated disease occurring in first 2 weeks of life
  4. Typical skin lesions present in 80%
  5. Asymptomatic cases probably do not occur
  6. Often severe with high mortality and morbidity, even with antiviral therapy
  7. Recurrent skin lesions common in surviving infants
  8. Incidence: 1 in 3000–20 000 live births
  9. Infants frequently born prematurely

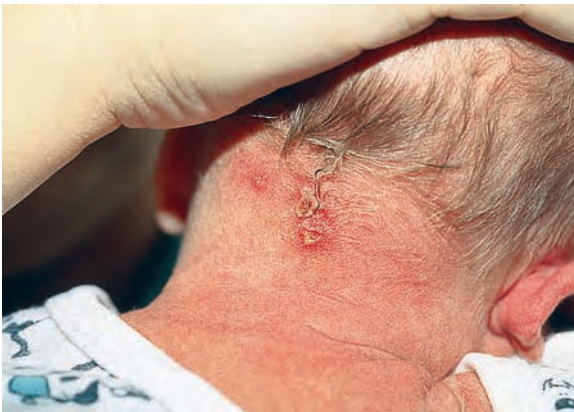

**Figure 8.8** Herpes simplex – primary infection



**Figure 8.9** Eczema herpeticum – generalized herpes simplex infection in a teenager with atopic dermatitis

10. Transmitted during birth through an infected birth canal, or by ascending infection. (In USA, 0.01–0.39% of women shed HSV at birth)
11. Postnatal transmission from infected parent can occur if lesions on mouth, hands, or nipples
12. Transmission from nursery workers rarely occurs
13. Risk of HSV infection in infant born vaginally to mother with first herpetic infection is 33–50%; with recurrent HSV is 3–5%



**Figure 8.10** Herpes simplex – in an 8-day-old neonate

- Genital herpes infection
  1. Usually caused by HSV-2; occasionally HSV-1
  2. Vesicles or shallow ulcerations, usually painful, in perineal area or on genitalia
  3. Transmitted from direct contact with infected secretions through sexual activity
  4. Genital herpes in prepubertal children should be investigated for sexual abuse
- Eye infections
  1. May be primary or recurrent
  2. Cause superficial conjunctivitis
  3. May involve deeper layers of cornea or chorioretinitis
  4. Potentially leading to scarring and loss of vision
- Herpetic whitlow
  1. Typically involves fingertips
  2. More common in thumbsuckers with inoculation from oral lesions (Figure 8.11)

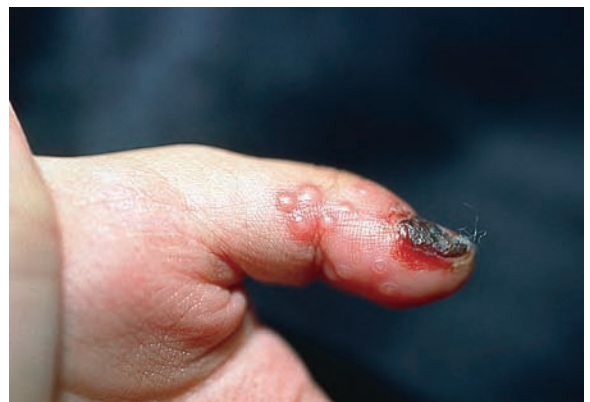- Herpes gladiatorum
  1. Occurs in wrestlers from direct skin-to-skin inoculation
- Recurrent erythema multiforme minor can occur with reactivation of herpes virus
- Herpes encephalitis: associated with fever, convulsions, irritability, alterations of consciousness, or focal neurological changes

### *Pathogenesis*

- Herpes simplex: large, enveloped DNA virus with two major types which have genomic and antigenic differences
  1. Type 1 (HSV-1) causes lesions above waist, but can be found anywhere
  2. Type 2 (HSV-2) usually involves genitalia
- Epidermotropic; produces infection within keratinocytes
- Persists in nerve ganglia in latent form and can become reactivated following various factors: fever, ultraviolet light, trauma, menses
- Transmitted during primary and recurrent infections, either symptomatic or asymptomatic
- With recurrent lesions, first 24 hours has highest concentration of virus with development of vesicles
- Active infection occurs despite high titers of specific antibody; antibody cannot interact with active virus, which is transferred from cell to cell

### *Diagnosis*

- Cell culture with special transport media will grow virus readily
  1. Open and swab skin vesicles



**Figure 8.11** Herpes simplex – herpetic whitlow in a thumb sucker

2. In neonates, take cultures from skin, nasopharynx, eyes, urine, blood, stool and CSF and maternal lesions, cervix or vulva
- Direct fluorescent antibody staining or immunoassay detection of vesicle scraping
- Polymerase chain reaction (PCR)
- Tzanck preparation: multinucleated keratinocytes and eosinophilic intranuclear inclusions; smear material from base of blister on slide and stain with Wright stain

### *Differential diagnosis*

- Cutaneous lesions
  1. Cellulitis
  2. Pyoderma
  3. Impetigo
- Gingivostomatitis
  1. Aphthous stomatitis
  2. Erythema multiforme
  3. Herpangina caused by enteroviruses, particularly coxsackie A virus
- Herpes keratitis
  1. Adenovirus (usually bilateral)
- Genital herpes simplex
  1. Gonorrhea
  2. Syphilis
- Neonatal herpes simplex
  1. TORCH complex (toxoplasmosis, other (syphilis, viruses), rubella, CMV, herpes simplex)
  2. Staphylococcal infection
  3. Candida infection

### *Treatment*

- Acyclovir indicated for primary infections, and occasionally for recurrences (see Chapter 21)
- Topical agents (as adjunct): acyclovir 5% ointment, docosanol 10% cream (Denavir) in conjunction with parenteral antiviral therapy) 1–2% trifluridine, 1% iododeoxyuridine, 3% vidarabine
- Topical steroids are contraindicated unless used in conjunction with antiviral therapy
- Refer to an ophthalmologist if eye involvement
- Isolation of patients in hospital
- HSV in wrestlers or rugby players
  1. Inspection of skin of players during athletic competition

2. Exclusion from competition until lesions are healed or deemed noninfectious by viral cultures
3. Wash mats with freshly prepared 1/64 household bleach solution (one-quarter of a cup diluted to 1 gallon of water) between matches

### *Prognosis*

- Generally heals in ~8 days
- Neonates and those who are immunocompromised have guarded prognosis
- All lesions are potentially recurrent

### *References*

- Amir J, Harel L, Smetana Z, Varsano I. The natural history of primary herpes simplex type 1 gingivostomatitis in children. *Pediatr Dermatol* 1999; 16: 259–63
- Arvin AM, Prober CG. Herpes simplex virus type 2 – a persistent problem. *N Engl J Med* 1997; 337: 1158–9
- Donovan B. Sexually transmissible infections other than HIV. *Lancet* 2004; 363: 545–56
- Drago F, Rebora A. The new herpesviruses. *Arch Dermatol* 1999; 135: 71–5
- Kimberlin DW. Neonatal herpes simplex infection. *Clin Microbiol Rev* 2004; 17: 1–13
- Kimberlin DW, Lin C-Y, Jacobs RF, et al. Natural history of neonatal herpes simplex virus infections in the acyclovir era. *Pediatrics* 2001; 108: 223–9
- Report of the Committee on Infectious Diseases. Red Book, 26th edn. American Academy of Pediatrics: Elk Grove Village, IL, 2003: 344–53
- Waggoner-Fountain LA, Grossman LB. Herpes simplex virus. *Pediatr Rev* 2004; 25: 86–93
- Wollenberg A, Zoch C, Wetzel S, et al. Predisposing factors and clinical features of eczema herpeticum: a retrospective analysis of 100 cases. *J Am Acad Dermatol* 2003; 49: 198–205

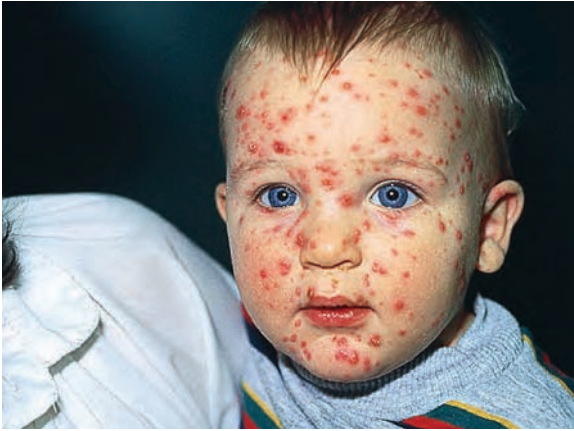## **Varicella**

Synonym: chickenpox

### *Major points*

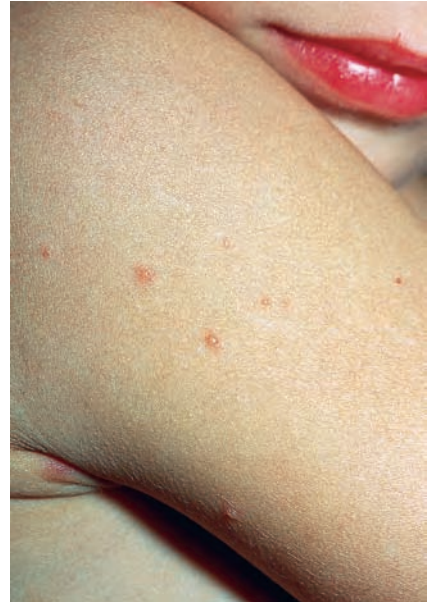- Clinical characteristics
  1. Abrupt onset of generalized pruritic, scattered vesicular rash with mild fever and mild systemic symptoms (Figures 8.12–8.14)



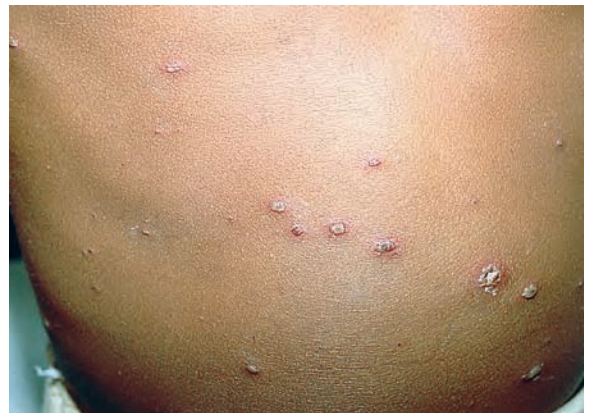

**Figure 8.12** Varicella – typical multiple lesions in different stages of development

2. Initial lesions resemble 'dew drops on a rose petal'
3. Crops of lesions in different stages of development; break out for 2–5 days
4. Individual lesions go from papules to vesicles to crusts within 24–48 hours
5. When shed, crusts leave shallow erosions
6. Lesions may be concentrated in areas of skin injury or sun exposure
7. Oral cavity lesions frequent, as are other mucous membrane lesions
8. Total duration 7–10 days
- Epidemiology
  1. Incubation period 10–21 days (average 14–16 days)
  2. Highly contagious
  3. Most contagious for 1–2 days before and shortly after onset of rash, but lasts until vesicles have crusted
  4. Person-to-person transmission by direct contact with infected patients (varicella or zoster) or air-borne spread from respiratory secretions
  5. Children who acquire their infection at home (secondary family cases) may have more severe disease than index case
  6. Late winter and early spring more common
  7. Most common in children <10 years
  8. Immunity is usually life-long
- Complications
  1. Bacterial superinfection with *Staphylococcus aureus* or *Streptococcus*
  2. Thrombocytopenia



**Figure 8.13** Varicella – classic initial lesion described as a 'dew drop on a rose petal'



**Figure 8.14** Varicella – typical multiple lesions on the trunk

3. Pneumonia
4. Arthritis
5. Hepatitis
6. Encephalitis or meningitis
7. Glomerulonephritis
8. More severe in adolescents and adults
9. Reye syndrome
10. Acute cerebellar ataxia
11. Immunocompromised children can have progressive varicella with continued eruption of



- lesions and high fever from 2 weeks to several months
- 12. Children receiving corticosteroids or chronic salicylate therapy may have more severe disease or complications
- 13. Fetal infection (first or early second trimester) can result in varicella embryopathy (congenital varicella syndrome) with limb atrophy and scarring; attack rate 1.2% (higher between 13 and 20 weeks' gestation)
- 14. Fetuses exposed to varicella-zoster virus can develop unapparent varicella and then zoster early in life
- 15. Severe neonatal varicella results when infant's mother develops varicella from 5 days before to 2 days after delivery; mortality rate 30%

### Pathogenesis

- Caused by varicella-zoster virus (human herpes virus-3)
- Herpes viruses are epidermotropic and produce infection within the keratinocytes with epidermal cell death

### Diagnosis

- Clinical diagnosis
- Viral culture is usually positive in the first 3–4 days of eruption
- Immunofluorescent staining with monoclonal antibodies of vesicular scrapings; PCR
- Tzanck smear demonstrates multinucleated epithelial cells containing intranuclear inclusions
- Acute and convalescent-phase sera for anti-varicella-zoster virus antibody
- Serologic tests: enzyme immunoassay (EIA), latex agglutination (LA), indirect fluorescent antibody (IFA) and fluorescent antibody-to-membrane antigen (FAMA) assays
- Histology: balloon degeneration within keratinocytes, multinucleated giant epithelial cell and nuclear inclusions

### Differential diagnosis

- Insect bite reactions
- Molluscum contagiosum
- Pityriasis lichenoides et varioliformis acuta
- Rickettsialpox
- Dermatitis herpetiformis
- Herpes simplex (disseminated)
- Orf

- Coxsackie infections
- Echoviruses 4, 9, 11, 17, 25
- Variola
- Vaccinia (cowpox)

### Treatment

- Healthy children usually do not require treatment
- Symptomatic treatment: wet dressings, soothing baths, oral antipruritics
- Acyclovir (see Chapter 21)
- Varicella-zoster immune globulin (VZIG) within 72 hours of exposure can modify the course, but is not helpful once the disease is established. (Consult Red Book)
- Hospitalized patients should be isolated
- Contact with elderly, neonates and immunocompromised children should be avoided
- School children with uncomplicated cases may return to school on the 6th day after the onset of the rash or when there are no new lesions, and existing lesions have crusted over; children with zoster based on similar criteria may return to school when lesions have crusted
- Varicella vaccine is a cell-free live-attenuated preparation
  1. Single dose recommended for patients between 12 months and 12 years with a 97% seroconversion rate
  2. Persons >13 years should have second dose 4–8 weeks after initial vaccination
- Secondary bacterial infection should be treated with antibiotics

### Prognosis

- Excellent in a healthy child
- Immunosuppressed children have higher rate of complications
- Virus persists in latent form after initial infection
- Reactivation causes herpes zoster ('shingles')

### References

- Arvin AM. Varicella vaccine – the first six years. *N Engl J Med* 2001; 344: 1007–9
- English R. Varicella. *Pediatr Rev* 2003; 24: 372–9
- Hall S, Maupin T, Seward J, et al. Second varicella infections: are they more common than previously thought? *Pediatrics* 2002; 109: 1068–73
- LaRussa P. The success of varicella vaccine. *Pediatr Ann* 2002; 31: 710–15

LaRussa P, Steinberg SP, Shapiro E, et al. Viral strain identification in varicella vaccines with disseminated rashes. *Pediatr Infect Dis* 2000; 19: 1037–9

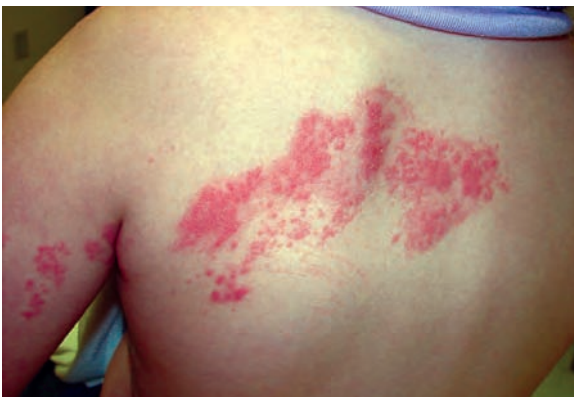MMWR. Varicella-related deaths among adults – United States, 1997. *Morbid Mortal Weekly Rep* 1997; 46: 409  
Report of the Committee on Infectious Diseases. Red Book, 26th edn. American Academy of Pediatrics: Elk Grove Village, IL, 2003: 672–86

Vazquez M, LaRussa PS, Gerson AA, et al. The effectiveness of the varicella vaccine in clinical practice. *N Engl J Med* 2001; 344: 955–60

## Herpes zoster

### Major points

- Patients have previously had varicella infection or vaccine
- Clinical characteristics:
  1. Lesions begin as erythematous macules, then become grouped vesicles on erythematous base in dermatomal distribution (may be one to three sensory dermatomes) (Figure 8.15)
  2. Most common dermatomes involved are on the trunk and buttocks
  3. Mild febrile illness lasts 7–10 days
  4. Pruritus may be severe
  5. Pain can occur and is localized to the area involved
  6. Generalized lesions may be seen in immunocompromised patients, with lesions appearing outside the dermatomes, with visceral complications



**Figure 8.15** Herpes zoster – typical dermatomal distribution of vesicles

- Complications
  1. Scarring (Figure 8.16)
  2. Motor paralysis
  3. Keratitis
  4. Ramsay-Hunt syndrome: involvement of geniculate ganglion with pain in the ear, vesicles on pinnae and facial palsy
  5. Postherpetic neuralgia (rare in children)

### Pathogenesis

- Caused by a recrudescence of a latent infection with varicella zoster virus (human herpes virus-3)

### Diagnosis

- Clinical diagnosis
- See Varicella above, for testing

### Differential diagnosis

- Herpes simplex infection
- Impetigo
- Pain can mimic internal disease: encephalitis, appendicitis

### Treatment

- Acyclovir either oral or intravenously (see Chapter 21)
- Topical antibiotic ointments (e.g. mupirocin, bacitracin)
- Oral antipruritics: hydroxyzine 10–25 mg every 6 hours, diphenhydramine 10–25 mg every 6 hours
- Prednisone 1–2 mg/kg per day to prevent postherpetic neuralgia and to decrease inflammation

### Prognosis

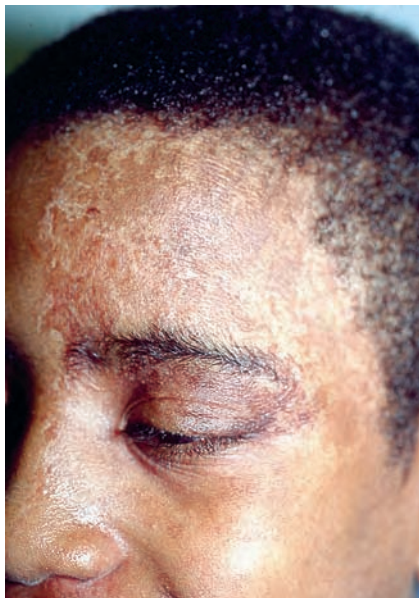- Excellent in immunocompetent host
- May be prolonged in immunocompromised host
- May cause scarring

### References

Brown TJ, McCrary M, Tyring SK. Antiviral agents: nonantiviral drugs. *J Am Acad Dermatol* 2002; 47: 581–99

English R. Varicella. *Pediatr Rev* 2003; 24: 372–9

Johnson RW. Herpes zoster in the immunocompetent patient: management of post-herpetic neuralgia. *Herpes* 2003; 10: 38–45



**Figure 8.16** Post-herpes zoster scarring

Kakourou T, Theodoridou M, Mostrous G, et al. Herpes zoster in children. *J Am Acad Dermatol* 1998; 39: 207–10

Liang MG, Heidelberg KA, Jacobson RM, McEvoy MT. Herpes zoster after varicella immunization. *J Am Acad Dermatol* 1998; 38: 761–3

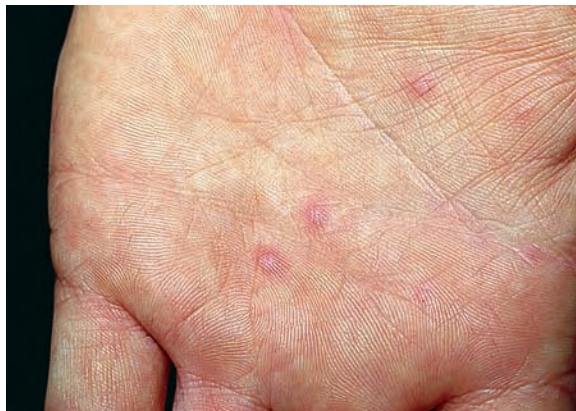McCrary ML, Severson J, Tyring SK. Varicella zoster virus. *J Am Acad Dermatol* 1999; 41: 1–14

Thomas SL, Hall AJ. What does epidemiology tell us about risk factors for herpes zoster? *Lancet Infect Dis* 2004; 4: 26–33

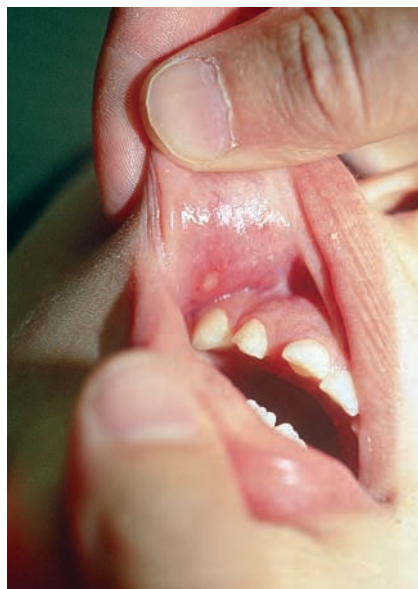## Hand, foot and mouth disease

### Major points

- Abrupt onset of scattered papules/vesicles, oval or linear in shape, in an acral distribution
- Individual (not grouped) lesions are seen on palms, fingertips, soles and mouth; occasionally, more numerous lesions may involve extremities (Figures 8.17 and 8.18)
- Lesions usually number <100
- Fever may be mild or nonexistent
- Oral lesions are discrete, shallow, oval erosions
- There is diarrhea, particularly in young children
- Epidemics occur in summer and early fall in temperate climates
- Incubation period: 3–5 days



**Figure 8.17** Hand, foot and mouth disease caused by coxsackie virus



**Figure 8.18** Hand, foot and mouth disease – oral lesion with erythematous halo

- Fecal–oral acquisition; virus may be excreted in feces for up to 12 weeks
- Contagious from 2 days before onset of rash to 2 days after
- Enteroviruses may survive on fomites
- Clinical attack rates highest in young children

### Pathogenesis

- Caused by several coxsackie virus groups: A16, A2, A5, A10 and A71

## Diagnosis

- Virus isolation from throat, stool and rectal swabs, and occasionally blood
- Antibodies from sera (onset of illness and 4 weeks after) showing rise in titer

## Differential diagnosis

See Table 8.1

- Acropustulosis of infancy
- Insect bites
- Urticaria

## Treatment

- None usually necessary
- Treat dehydration if it occurs in infants
- IVIG containing high antibody titer may be helpful for immunocompromised patients
- Good handwashing, personal hygiene, especially after diaper changes

## Prognosis

- Excellent

## References

Chang LY, King CC, Hsu KH, et al. Risk factors of enterovirus 71 infection and associated hand, foot, and mouth disease/herpangina in children during an epidemic in Taiwan. *Pediatrics* 2002; 109: 88

Chang LY, Lin TY, Huang YC, et al. Comparison of enterovirus-71 and coxsackievirus A16 clinical illnesses during the Taiwan enterovirus epidemic, 1998. *Pediatr Infect Dis J* 1999; 18: 1092–6

Frieden IJ, Resnick SD. Childhood exanthems. Old and new. *Pediatr Clin North Am* 1991; 38: 859–87

Messner J, Miller JJ, James WD, Honig PJ. Accentuated viral exanthems in areas of inflammation. *J Am Acad Dermatol* 1999; 40: 345–6

Report of the Committee on Infectious Diseases. Red Book, 26th edn. American Academy of Pediatrics: Elk Grove Village, IL, 2003: 269–70

Thomas I, Janniger CK. Hand, foot and mouth disease. *Cutis* 1993; 52: 265–6

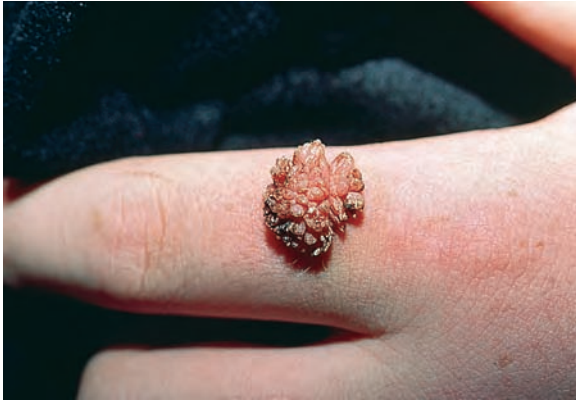## Verrucae

### Major points

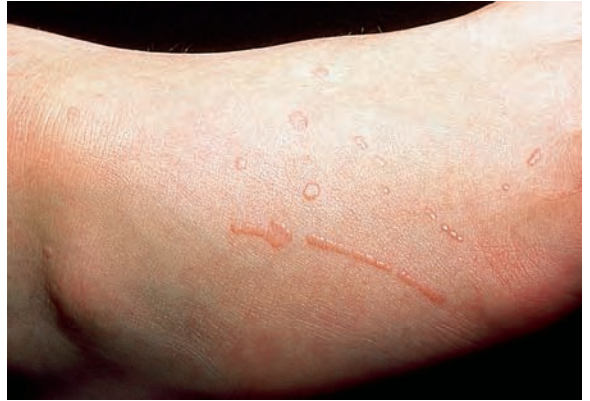- Human papillomaviruses (HPV) cause benign epithelial tumors (warts) of skin and mucous membranes

- Cutaneous warts are common in school-aged children
- Transmitted from person to person by direct contact. Enters areas of minor trauma to skin
- Severe or widespread infections occur in patients with compromised cellular immunity (e.g. transplantation, HIV infection) or atopic patients
- Anogenital warts are primarily transmitted by sexual contact, but may be acquired at delivery from an infected mother
- Evidence of genital HPV infection has been detected in up to 38% of sexually active adolescent females
- Incubation period: unknown; estimated 3 months to several years
- Common warts (caused by HPV 2, 4): dome-shaped papules with finger-like projections giving a rough appearance or texture of cauliflower (Figures 8.19 and 8.20)
  1. Usually asymptomatic and multiple
  2. Commonly occur on hands and around nails but can be anywhere, including lips and mouth
  3. Thrombosed capillaries give appearance of tiny dark dots
- Flat warts (caused by HPV 3, 10) common on face and extremities; usually small, multiple, flat topped papules (Figure 8.21)
- Plantar warts (caused by HPV 1, 4 and others) on weight-bearing areas; can be painful, hyperkeratotic; multiple lesions grouped together ('mosaic' appearance) (Figure 8.22)
- Anogenital or venereal warts (caused by HPV 6, 11, 16, 18) can range from asymptomatic papules to condylomata acuminata (cauliflower-like growths ranging from a few millimeters to several centimeters) (Figure 8.23)
  1. In males, found on shaft of the penis, meatus, scrotum and perineal areas
  2. In females, located on labia, vagina, cervix or perianal areas
  3. Perianal warts can cause itching, burning, local pain or bleeding
- Laryngeal papillomas found in children <3 years of age
  1. Manifest as hoarse crying or respiratory obstruction
  2. Acquired via aspiration of infected secretions from mother during passage through infected birth canal

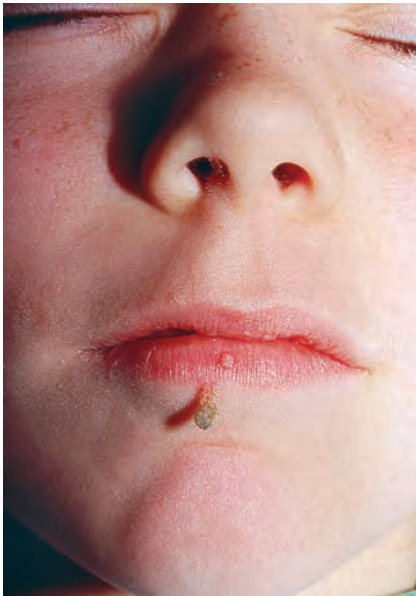



**Figure 8.19** Verruca vulgaris



**Figure 8.21** Plantar verrucae demonstrating the Koebner phenomenon

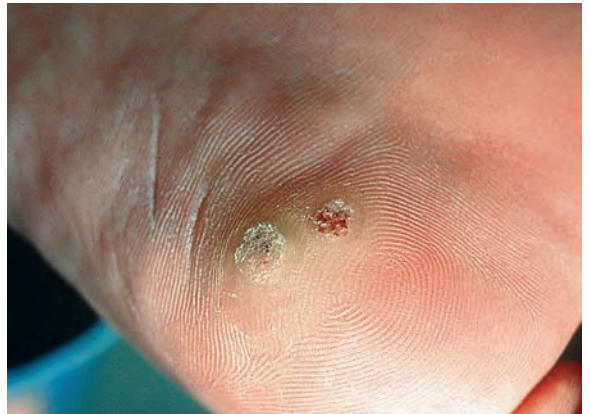


**Figure 8.20** Filiform verrucae often occur on the face

- Epidermodysplasia verruciformis: inherited deficiency of cell-mediated immunity to particular HPV types
  1. Presents in childhood as flat warts
  2. Malignant transformation occurs in adults in one-third of cases, particularly in sun-exposed areas

#### *Pathogenesis*

- Caused by papillomavirus, Papovaviridae family, DNA viruses



**Figure 8.22** Plantar warts showing the thrombosed capillaries

- >80 types have been identified, but most warts are caused by a few types
- Papillomaviruses are common in mammals and are species-specific
- HPV is located in epidermal cell nucleus and induces keratinocyte proliferation with relatively normal differentiation

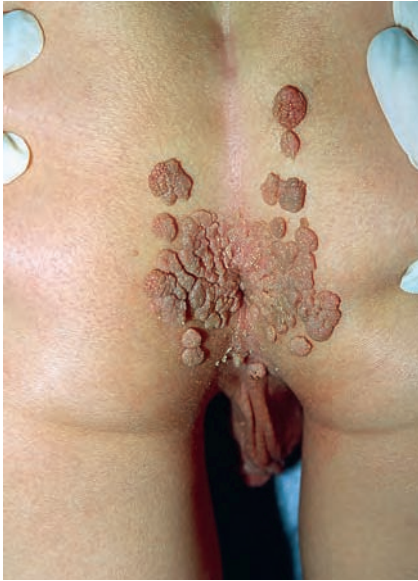
#### *Diagnosis*

- Clinical diagnosis
- Histology: vacuolated epidermal cells with hypergranulosis and eosinophilic inclusions
- PCR detection of certain viral types

#### *Differential diagnosis*

- Common warts: molluscum contagiosum, cysts
- Plantar warts: calluses





**Figure 8.23** Condyloma acuminata in a sexually abused child caused by human papillomavirus

- Anogenital warts: syphilis (condyloma lata); molluscum contagiosum
- Flat warts: lichen planus, lichen nitidus, seborrheic keratosis, epidermal nevus

### Treatment

- Nongenital warts often resolve spontaneously in <2 years
  1. Destruction: liquid nitrogen ( $-195^{\circ}\text{C}$ ), salicylic acid paints (17%),  $\text{CO}_2$  laser, pulsed dye laser, electrodesiccation, tape occlusion
  2. Tretinoin (0.025% or 0.05% cream) (off label) may be helpful for flat warts
- Anogenital warts
  1. Podophyllum resin 25%
  2. Podofilox
  3. Destructive methods such as liquid nitrogen, trichloroacetic acid,  $\text{CO}_2$  laser, or surgical excision
  4. Imiquimod 5% approved for >12 years
  5. Recurrences common
  6. Cervical HPV infections can be associated with epithelial dysplasia, and in certain types of HPV (16, 18, 31) may predispose the patient to cervical cancer
  7. In children who are not sexually active, suspicion of child abuse should be raised and

reported to appropriate authorities; inspect genitalia for signs of abuse

8. If history of unusual behavior, withdrawal, sleep disturbances, phobias, enuresis or encopresis, consider child abuse

### Prognosis

- Although most warts spontaneously regress, some persist for years
- Multiple treatments are often needed

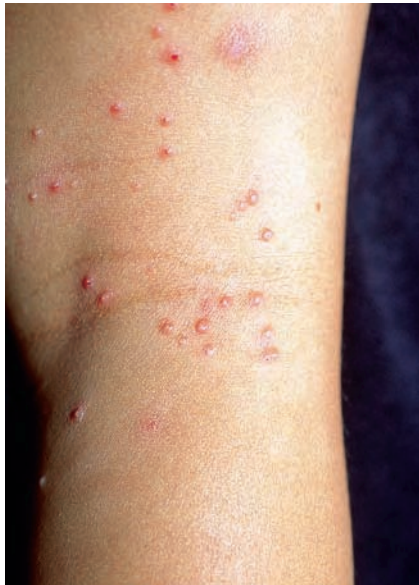### References

- Brown TJ, McCrary M, Tyring SK. Antiviral agents: nonantiviral drugs. *J Am Acad Dermatol* 2002; 47: 581–99
- Focht DR, Spicer C, Fairchok MP. The efficacy of duct tape vs. cryotherapy in the treatment of verruca vulgaris (the common wart). *Arch Pediatr Adolesc Med* 2002; 156: 971–4
- Grussendorf-Conen E-I, Jacobs S. Efficacy of imiquimod 5% cream in the treatment of recalcitrant warts in children. *Pediatr Dermatol* 2002; 19: 263–6
- Handley J, Hands E, Armstrong K, et al. Common association of HPV 2 with anogenital warts in prepubertal children. *Pediatr Dermatol* 1997; 14: 339–43
- Hengge UR, Cusini M. Topical immunomodulators for the treatment of external genital warts, cutaneous warts and molluscum contagiosum. *Br J Dermatol* 2003; 149: 15–19
- Kopera D. Verrucae vulgaris: flashlamp-pumped pulsed dye laser treatment in 134 patients. *Int J Dermatol* 2003; 42: 905–8
- Majewski S, Pniewski T, Malejczyk M, Jablonska S. Imiquimod is highly effective for extensive, hyperproliferative condyloma in children. *Pediatr Dermatol* 2003; 20: 440–2
- Torrelo A. What's new in the treatment of viral warts in children? *Pediatr Dermatol* 2002; 19: 191–9

## Molluscum contagiosum

### Major points

- Several (usually 2–20) skin-colored or pearly 1–6 mm discrete papules with central umbilication (Figures 8.24 and 8.25)
- Eczematous dermatitis often surrounds larger lesions
- Common locations: face, axilla and groin; can be anywhere
- May be sexually transmitted, mainly in teens and adults. In children, groin lesions common and



**Figure 8.24** Molluscum contagiosum – skin-colored papules, some with central umbilication

should not be considered a sexually transmitted disease unless there are other stigmata of sexual abuse

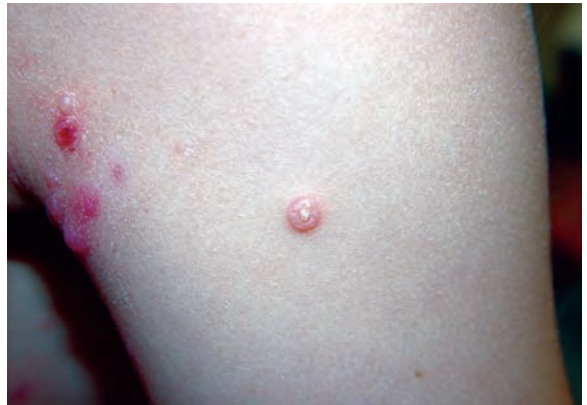- Patients with atopic dermatitis often have hundreds of lesions
- Infection occurs after contact with infected person, contaminated object, or swimming pool
- Incubation period 2–7 weeks but may be longer, up to 6 months
- Infectious as long as lesions are present
- Lesions may spontaneously suppurate, crust and resolve, being mistaken for secondary infection
- Conjunctivitis or keratitis may complicate lesions on eyelids
- Patients with HIV may have larger and more numerous lesions, suggesting that cell-mediated immunity helps eliminate the virus

#### *Pathogenesis*

- Caused by a poxvirus (Poxviridae) which induces epidermal cell proliferation

#### *Diagnosis*

- Clinical diagnosis
- Extrusion of keratinous material from a papule and inspecting it microscopically with Wright stain or



**Figure 8.25** Molluscum contagiosum – large lesion with several smaller ones nearby

potassium hydroxide will show characteristic pear-shaped ‘molluscum bodies’

- Histology: pear-shaped eosinophilic ‘molluscum bodies’ in the keratinocytes; bodies contain cytoplasmic masses of virus material
- Virus can be seen with electron microscopy

#### *Differential diagnosis*

- Warts
- Closed comedones
- Epidermal cysts
- Milia
- Folliculitis
- Pyogenic granuloma
- Keratoacanthoma

#### *Treatment*

- Lesions self-limiting and benign
- Can leave small pox-like scars, and can become very inflamed before resolving
- Mechanical removal of each papule can be performed with a dermal curette with prior application of anesthetic cream
- Other treatments:
  1. Liquid nitrogen
  2. Opening the lesions and squeezing out the contents
  3. Cantharidin
  4. Tretinoin or salicylic acid preparations may cause irritation and are somewhat unpredictable for treatment
  5. Imiquimod 5% cream (off label)

6. Cidofovir (off label)
- Recurrences common
- Treat every 2–4 weeks until cleared
- Molluscum is contagious; therefore, bathing or swimming together and sharing towels should be avoided

### Prognosis

- Most cases are self-limited within 6–9 months; however, some persist for years

### References

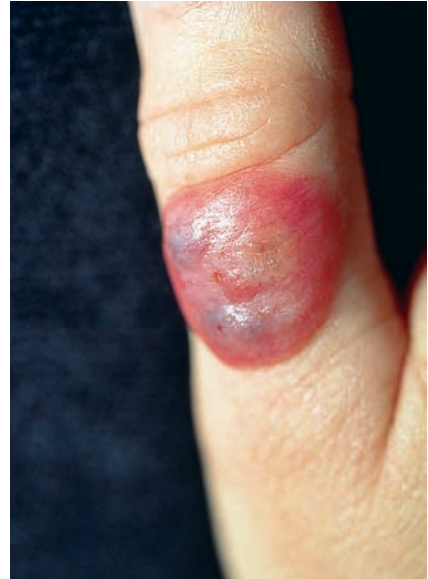- Bayerl C, Feller G, Goerdts S. Experience in treating molluscum contagiosum in children with imiquimod 5% cream. *Br J Dermatol* 2003; 149 (Suppl 66): 25–8
- Hengge UR, Cusini M. Topical immunomodulators for the treatment of external genital warts, cutaneous warts and molluscum contagiosum. *Br J Dermatol* 2003; 149 (Suppl 66): 15–19
- Hengge UR, Esser S, Schultewolter T, et al. Self-administered topical 5% imiquimod for the treatment of common warts and molluscum contagiosum. *Br J Dermatol* 2000; 143: 1026–31
- Majewski L, Jablonska S. Human papillomavirus-associated tumors of the skin and mucosa. *J Am Acad Dermatol* 1997; 36: 659–85
- Meadows KP, Tyring SK, Pavia AT, Rallis TM. Resolution of recalcitrant molluscum contagiosum virus lesions in human immunodeficiency virus-infected patients treated with cidofovir. *Arch Dermatol* 1997; 133: 987–90
- Mykowski PL. Molluscum contagiosum. New insights, new directions. *Arch Dermatol* 1997; 133: 1039–60
- Silverberg N. Pediatric molluscum contagiosum: optimal treatment strategies. *Paediatr Drugs* 2003; 5: 505–12

## Orf

Synonym: ecthyma contagiosum

### Major points

- Widespread in sheep and goats, affecting mainly young lambs that contract it from one another or persistent virus in pastures
- Incubation period: 5–6 days
- Begins as small, firm, red tender papule, enlarging to form a hemorrhagic pustule or bulla, which becomes crusted or umbilicated in the center (Figure 8.26)
- Usually 2–5 cm, solitary or few in number
- Common on fingers and hands



**Figure 8.26** Orf – bullous, erythematous nodule on finger

### Pathogenesis

- Caused by poxviridae inoculated from sheep or goats

### Diagnosis

- Clinical diagnosis with appropriate history
- Histology: inter- and intracellular edema, vacuolization and ballooning degeneration of the epidermis

### Differential diagnosis

- Pyoderma
- Brown recluse spider bite

### Treatment

- Secondary infection should be treated
- Removal of the bulk of lesion by biopsy may hasten healing

### Prognosis

- Spontaneous recovery in 6 weeks

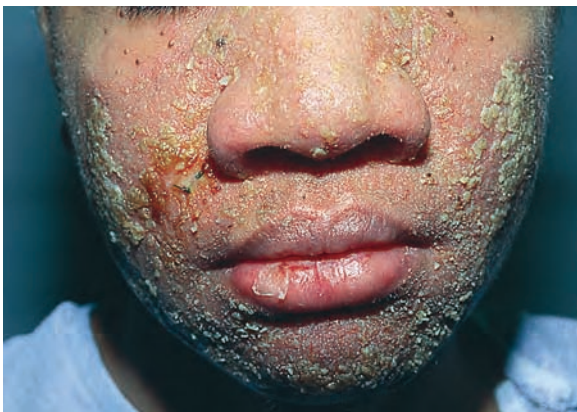### References

- Haig DM, McInnes C, Deane D, et al. The immune and inflammatory response to orf virus. *Comp Immunol Microbiol Infect Dis* 1997; 20: 197–204
- Weedon D. *Skin Pathology*. Churchill Livingstone: Edinburgh, 1997: 586–7

## Human immunodeficiency virus

### Major points

- Acquired immunodeficiency syndrome (AIDS): severe end of the clinical spectrum of HIV infections
- AIDS in children accounts for 2% of reported cases in the USA; most acquired from mothers
- Clinical manifestations (See Table 8.2)
  1. Generalized lymphadenopathy
  2. Hepatomegaly
  3. Splenomegaly
  4. Failure to thrive
  5. Candidiasis (oral or esophageal)
  6. Recurrent diarrhea
  7. Parotitis
  8. Cardiomyopathy
  9. Hepatitis
  10. Nephropathy
  11. CNS disease
  12. Developmental delay
  13. Seborrheic dermatitis (persistent)
  14. Pneumonia with *Pneumocystis carinii* (PCP); lymphoid interstitial pneumonia
  15. Recurrent bacterial infections with *Staphylococcus aureus* (Figure 8.27)
  16. Dermatophyte infections, widespread
  17. Scabies; severe, crusted
  18. Eosinophilic folliculitis
  19. Drug eruptions (especially with trimethoprim–sulfamethoxazole)
  20. Opportunistic infections (see Table 8.2)



**Figure 8.27** Human immunodeficiency virus infection with secondary *Staphylococcus aureus*

**Table 8.2 Revised case definition of AIDS-defining conditions for adults and adolescents ≥13 years of age**

Candidiasis of bronchi, trachea, or lungs  
 Candidiasis, esophageal  
 Cervical cancer, invasive  
 Coccidioidomycosis, disseminated or extrapulmonary  
 Cryptococcosis, extrapulmonary  
 Cryptosporidiosis, chronic intestinal  
 Cytomegalovirus disease (other than liver, spleen or lymph nodes)  
 Cytomegalovirus retinitis  
 Encephalopathy, HIV related  
 Herpes simplex: chronic ulcer >1 month's duration, or bronchitis, pneumonitis, or esophagitis  
 Histoplasmosis, disseminated or extrapulmonary  
 Isosporiasis, chronic intestinal  
 Kaposi sarcoma  
 Lymphoma, Burkitt  
 Lymphoma, immunoblastic  
 Lymphoma, primary of brain  
*Mycobacterium avium* complex or *M. kansasii*, disseminated or extrapulmonary  
*Mycobacterium tuberculosis*  
*Mycobacterium*, other species disseminated  
*Pneumocystis carinii* pneumonia  
 Pneumonia, recurrent  
 Progressive multifocal leukoencephalopathy  
 Salmonella septicemia, recurrent  
 Toxoplasmosis of brain  
 Wasting syndrome due to HIV  
 CD4+ T-lymphocyte count <200 cells/μl or CD4+ percentage <15%

Modified from Centers for Disease Control and Prevention. 1993 revised classification system for HIV infection and expanded case surveillance definition for AIDS among adolescents and adults. MMWR 1992; 41 (No. RR-17):1–19 and Red Book 2003: 360–82

21. Malignancies (uncommon in pediatric HIV) (see Table 8.2)
- Epidemiology
    1. Humans are reservoir
    2. HIV has been isolated from blood, CSF, pleural fluid, human milk, semen, cervical secretions, saliva, urine and tears
    3. Transmission:
      - a. Sexual contact
      - b. Percutaneous or mucous membrane exposure to contaminated blood or body fluids



- c. Mother-to-infant before or around the time of birth
- d. Breastfeeding
- e. Transfusion of blood or blood products
- Incubation period:
  1. HIV-infected neonates are usually asymptomatic in the first months of life
  2. Median onset of symptoms is 3 years of age if acquired perinatally (may be >5 years)

### *Pathogenesis*

- Caused by human immunodeficiency virus type 1 (HIV-1), a RNA cytopathic human retrovirus; HIV-2 is more common in West Africa
- HIV is tropic for T-helper lymphocytes (CD4+) and other cells such as monocytes, macrophages and CNS cells
- Retroviruses integrate into cell genome and replicate
- Virus persists for life in infected individuals
- Increasing loss of cell-mediated immunity with lymphopenia, decrease in T-helper lymphocytes (CD4+), and decrease in normal CD4+/CD8+ cell ratio
- Response of T lymphocytes to mitogens is lost; patients become anergic
- Loss of humoral immune function with elevated IgG and IgA
- Panhypogammaglobulinemia
- Viral load of circulating virus may be high (300 000 RNA copies/ml) or low (40 000 RNA copies/ml)

### *Diagnosis*

- For patients >18 months, serum antibody tests using enzyme immunoassays (EIA) are used for screening. Repeat testing should be performed, and confirmed with Western blot immunofluorescent antibody test
- Some patients with hypogammaglobulinemia or advanced disease may not have HIV antibodies
- Polymerase chain reaction (PCR) and HIV cultures are performed in reference laboratories
- Modified p24 antigen assay is less sensitive than PCR or culture but may be present early in infection
- For infants born to HIV-seropositive women, diagnosis may be difficult, as neonates are usually seropositive at birth, whether infected or not

1. HIV culture or PCR are preferred
2. May need to be repeated at 4–6 months of age

### *Differential diagnosis*

- Immunodeficiency states (e.g. severe combined immunodeficiency)
- Malnutrition
- Child abuse
- Infections, viral and bacterial
- Nutritional deficiencies

### *Treatment*

- Physicians should consult an HIV specialist if possible
- Treatment with antiretroviral agents for HIV-infected mothers during pregnancy can reduce the risk of vertical transmission
- Antiretroviral therapy
- Antibiotics or antifungal agents as appropriate for infections
- Newly diagnosed patients with HIV infection must be reported to public health department

### *Prognosis*

- Opportunistic infections, progressive neurological disease and severe wasting are associated with poor prognosis
- Viral load and CD4+ count are good predictors of prognosis

### *References*

- Fauci AS. The AIDS epidemic. *N Engl J Med* 1999; 341: 1046–50
- Hachem ME, Bernardi S, Pianosi G, et al. Mucocutaneous manifestations in children with HIV infection and AIDS. *Pediatr Dermatol* 1998; 15: 429–34
- Harris PS, Saag MS. Dermatologic manifestations of human immunodeficiency virus infection. *Curr Prob Dermatol* 1997; 9: 209–62
- Mocroft A, Youle M, Phillips AN, et al. The incidence of AIDS-defining illnesses in 4883 patients with human immunodeficiency virus infection. *Arch Intern Med* 1998; 158: 491–7
- Report of the Committee on Infectious Diseases. Red Book, 26th edn. American Academy of Pediatrics: Elk Grove Village, IL, 2003: 360–82
- Rico JM, Myers SA, Sanchez MR. Guidelines of care for dermatologic conditions in patients infected with HIV. *J Am Acad Dermatol* 1997; 37: 450–72



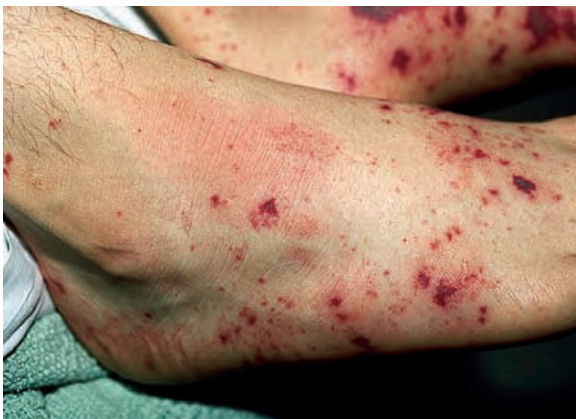Wananukul S, Deekajorndech T, Panchareon C, Thisyakorn U. Mucocutaneous findings in pediatric AIDS related to degree of immunosuppression. *Pediatr Dermatol* 2003; 20: 289–94

Ward HA, Russo GG, Shrum J. Cutaneous manifestations of antiretroviral therapy. *J Am Acad Dermatol* 2002; 46: 284–93

## Rocky mountain spotted fever

### Major points

- Clinical characteristics:
  1. Fever, headache, myalgias, nausea, vomiting, anorexia
  2. Rash begins on wrists and ankles as an erythematous macular eruption which later becomes petechial and spreads to the trunk (Figure 8.28)
    - a. Palms and soles are often involved
    - b. Rarely, no rash is present; more common in infants
  2. Thrombocytopenia
  3. Anemia
  4. Leukocytopenia
  5. Duration of illness ~3 weeks
  6. Involvement of various organ systems: CNS, cardiac, pulmonary, gastrointestinal tract, renal and other organs
  7. Disseminated intravascular coagulation in severe cases
  8. Shock leading to death



**Figure 8.28** Rocky Mountain spotted fever with vasculitis and purpura

- Epidemiology
  1. Incubation period: 2–14 days (usually 1 week)
  2. Transmitted to humans by the bite of ticks, which are reservoirs and vectors of *Rickettsia rickettsii*
  3. Ticks: *Dermacentor variabilis* (dog tick), *Dermacentor andersoni* (wood tick) in upper Rocky Mountain states, and *Amblyomma americanum* (Lone Star tick) in south central USA
  4. Organism is transmitted transovarially and between stages in ticks
  5. Increased risk: persons exposed to ticks frequently (e.g. pet owners, outdoorsmen)
  6. More common in children <15 years of age
  7. Most common in April through October
  8. Widespread in USA, with most cases reported in southeastern and south central states; also reported in Canada, Mexico, Central and South America

### Pathogenesis

- Caused by *Rickettsia rickettsii*, an obligate intracellular pathogen and member of the spotted fever group of rickettsiae

### Diagnosis

- Culture of organism not recommended because of danger of transmission
- Skin biopsy of rash with immunofluorescent staining for *R. rickettsii* is specific but not readily available
- Four-fold increase in one of multiple rickettsial group-specific tests; or decrease in antibody titer between acute and convalescent sera by indirect immunofluorescence antibody (IFA), complement fixation (CF), latex agglutination (LA), indirect hemagglutination (IHA), or microagglutination tests
  1. Antibodies can be detected by IFA 7–10 days after illness starts
  2. IFA and IHA are the most sensitive and specific tests
  3. CF and microagglutination are highly specific but lack sensitivity
  4. Weil–Felix serologic test (Proteus Ox-19 and Ox-2 agglutinins) is nonspecific and not sensitive
  5. PCR test from blood and skin specimens is available in reference laboratories but positivity depends upon number of organisms

### Differential diagnosis

- Drug eruptions
- Petechiae
- Vasculitis
- Ehrlichiosis
- Toxic shock syndrome
- Disseminated intravascular coagulation
- Measles
- Parvovirus B19 ('gloves and socks' syndrome)

### Treatment

- Doxycycline 2–4 mg/kg per day in one to two doses given orally or intravenously (adult dose 1–2 g/day) is drug of choice for all ages. Tetracycline staining of teeth is dose related and doxycycline is less likely to stain developing teeth than other tetracyclines. Since ehrlichiosis and Rocky Mountain Spotted Fever overlap clinically, tetracyclines are effective against both infections, whereas chloramphenicol is not
- Chloramphenicol 50–100 mg/kg per day given intravenously or orally in four doses (adult dose 2–4 g/day)
- Treatment is given until the patient has been afebrile for 2–3 days (usually 7–10 days)
- Preventative measures: protective clothing, tick/insect repellents to skin and clothes
- Thorough inspection of the skin after being outdoors and removal of ticks

### Prognosis

- Early treatment is needed for a good outcome
- Mortality highest in males, in persons >30 years, in non-Whites, and in persons with no known tick-bite history
- Delay in disease recognition increases risk of death or neurological sequelae

### References

- Case Records of the Massachusetts General Hospital (Case 32-1997). *N Engl J Med* 1997; 337: 1149–56
- Jacobs RE. Human monocytic ehrlichiosis: similar to Rocky Mountain spotted fever but different. *Pediatr Ann* 2002; 31: 180–4
- Masters EJ, Olson GS, Weiner SJ, Paddock CD. Rocky Mountain spotted fever: a clinician's dilemma. *Arch Int Med* 2003; 163: 769–74
- McGinley-Smith DE, Tsao SS. Dermatoses from ticks. *J Am Acad Dermatol* 2003; 49: 363–92

Report of the Committee on Infectious Diseases. *Red Book*, 26th edn. American Academy of Pediatrics: Elk Grove Village, IL, 2003: 532–4

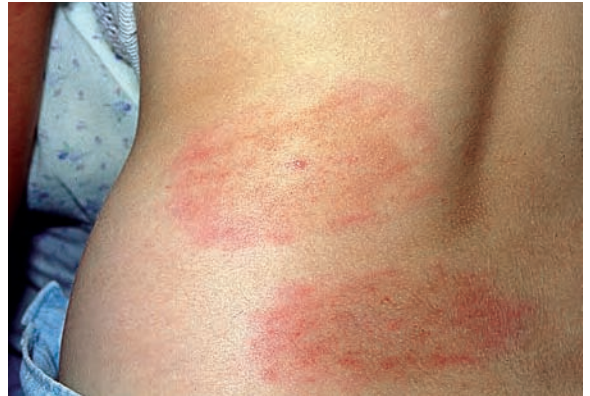Sexton DJ, Kaye KS. Rocky mountain spotted fever. *Med Clin North Am* 2002; 86: 351–60, vii–viii

### Lyme disease

Synonym: erythema chronicum migrans

### Major points

- Clinical manifestation divided into three stages:
  1. Early localized
    - a. Erythema migrans at site of tick bite (Figure 8.29)



**Figure 8.29** Lyme disease – typical annular patches of erythema chronicum migrans

- a. Begins as a red macule or papule, expanding during days to weeks to form a large annular erythematous lesion >5 cm (average 15 cm) with central clearing
  - c. Rash can vary greatly and may be vesicular or necrotic in the center
  - d. Fever, malaise, headache, mild neck stiffness and arthralgia
2. Early disseminated
  - a. Multiple lesions of erythema migrans which are similar to but usually smaller than the primary lesion
  - b. Lesions usually occur 3–5 weeks after the tick bite
  - c. Common manifestations: palsies of cranial nerves (especially 7th cranial nerve),

- meningitis, conjunctivitis, arthralgias, myalgias, headache and fatigue
- d. Rare manifestation: carditis
- 3. Late disease
  - a. Occurs several months to several years after the tick bite
  - b. Recurrent arthritis (pauciarticular, affecting large joints, particularly knees)
  - c. Chronic arthritis is uncommon in children treated in early stages with antibiotics
  - d. CNS: encephalopathy, neuropathy
- Epidemiology
  1. Usually occurs April through October
  2. Incubation period 3–31 days (average 7–14 days)
  3. Occurs in three distinct geographic regions in the USA (although it has been reported in 48 states): northeast (Massachusetts to Maryland), upper midwest (Minnesota, Wisconsin), west coast (northern California)
  4. Reported in Canada, Europe, former Soviet Union, China, Japan
  5. Tick vectors
    - a. *Ixodes scapularis* (previously called *Ixodes dammini*) in east and midwest
    - b. *Ixodes pacificus* in west

### Pathogenesis

- Caused by spirochete *Borrelia burgdorferi*, acquired by tick bite

### Diagnosis

- Clinical diagnosis
- *Borrelia* cultures require special media and are not readily available
- Serological testing:
  1. IgM specific antibody titers peak 3–6 weeks after onset of disease
  2. IgG antibody titers rise slowly and peak weeks to months later
  3. Titers persist for years and should not be used to assess treatment
  4. Localized erythema migrans, because it occurs 1–2 weeks after tick bite, usually does not show rising titers. Some patients treated early never develop elevated titers
- Enzyme immunoassay (EIA): may give false-positive results; should be confirmed with immunoblot

- Immunofluorescence assay (IFA): may give false-positive results; should be confirmed with immunoblot
- Western immunoblot test: should be used to corroborate positive or equivocal EIA or IFA results
  1. Both IgM and IgG should be assessed if early in disease
  2. IgM not recommended if illness >1 month's duration
  3. Comparing acute- and convalescent-phase sera may be needed in some cases
- PCR is specific but limited in availability
- Widespread practice of ordering serologic tests for nonspecific symptoms should be discouraged, as positive tests are frequently false-positives

### Differential diagnosis

- Granuloma annulare
- Gyrate erythema
- Tinea corporis
- Urticaria
- Drug eruption

### Treatment

- Early treatment usually prevents development of later stages
- Clinical response is slow, and symptoms may persist for weeks
- Jarisch–Herxheimer reaction with fever, chills and malaise can occur transiently when therapy is started; nonsteroidal anti-inflammatory agents may be helpful
- Early localized disease:
  1. Doxycycline 100 mg twice a day, orally for 14–21 days for children >8 years and nonpregnant women
  2. Amoxicillin 25–50 mg/kg per day, divided into three doses (maximum 2 g per day) for 14–21 days
- Multiple erythema migrans:
  1. Same oral regimen as early disease for 21 days
- Isolated facial palsy:
  1. Same oral regimen as early disease but for 21–28 days
  2. Treatment has no effect on palsy, but prevents further complications
- Arthritis:
  1. Same oral regimen as for early disease but for 28 days

- Persistent or recurrent arthritis:
  1. Ceftriaxone 75–100 mg/kg, intravenously or intramuscularly, once a day (maximum 2 g/day) for 14–21 days; or
  2. Penicillin 300 000 U/kg per day intravenously, given in divided doses every 4 hours (maximum, 20 million U/day) for 14–21 days
- Carditis/meningitis or encephalitis:
  1. Ceftriaxone 75–100 mg/kg intravenously or intramuscularly, once a day (maximum 2 g/day) for 14–21 days; or
  2. Penicillin 300 000 U/kg per day, intravenously, given in divided doses every 4 hours (maximum, 20 million U/day) for 14–21 days
- Control measures:
  1. Avoid tick-infested areas
  2. Cover skin with clothing as much as possible
  3. Permethrin can be sprayed on clothing to prevent tick attachment
  4. Repellents containing diethyltoluamide (DEET) can be applied sparingly to skin; can be neurotoxic in high doses
  5. Bathe with soap and water after outdoor exposure
  6. Inspect the skin and remove ticks daily
  7. Prophylactic antimicrobial treatment after tick bite is not usually recommended routinely, especially if the tick attachment is <24–48 hours

8. Analysis of ticks to determine infectivity is not recommended

### Prognosis

- Excellent for early disease
- Guarded for disseminated or late disease

### References

- American Academy of Pediatrics. Committee on Infectious Diseases. Prevention of Lyme disease. *Pediatrics* 2000; 105: 142–7
- Bachman DT, Srivastava G. Emergency department presentations of Lyme disease in children. *Pediatr Emerg Care* 1998; 14: 356–61
- Eppes SC. Diagnosis, treatment, and prevention of Lyme disease in children. *Paediatr Drugs* 2003; 5: 363–72
- Hengge UR, Tannapfel A, Tying SK, et al. Lyme borreliosis. *Lancet Infect Dis* 2003; 3: 489–500
- Huppertz HI. Lyme disease in children. *Curr Opin Rheumatol* 2001; 13: 434–40
- McGinley-Smith DE, Tsao SS. Dermatoses from ticks. *J Am Acad Dermatol* 2003; 49: 363–92
- Report of the Committee on Infectious Diseases. Red Book, 26th edn. American Academy of Pediatrics: Elk Grove Village, IL, 2003: 407–11
- Singh-Behl D, La Rosa SP, Tomecki KJ. Tick-borne infections. *Dermatol Clin* 2003; 21: 237–44
- Stanek G, Strle F. Lyme borreliosis. *Lancet* 2003; 362: 1639–47





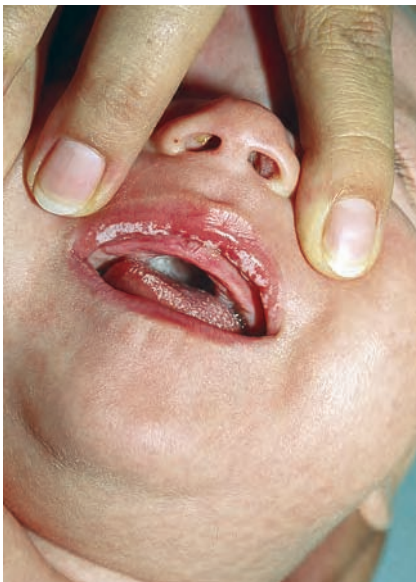# FUNGAL DISEASES

## SUPERFICIAL FUNGAL INFECTIONS

### *Candida*

#### Major points

- Oral candidiasis (thrush)
  1. Affects ~5% of healthy infants
  2. Clinical presentation: white, raised patches on buccal mucosa, tongue and palate; may be described as having a 'cheesy' appearance or as 'pseudomembranous' patches; scraping reveals a raw, red base (Figure 9.1)
  3. May be acquired from passage through the birth canal in a healthy newborn



**Figure 9.1** Candida – thrush on the lips and tongue

4. Infants or older children with persistent oral thrush should be evaluated for predisposing factors (e.g. immunodeficiency, HIV)
- Diaper candidiasis
    1. Clinical presentation: brightly erythematous ('beefy red') confluent patches with a sharply demarcated serpiginous border and satellite pustules; small rings of scale, edema, oozing
  - Candidal paronychia
    1. Seen in children who suck their fingers, in people who are exposed to excessive moisture, or in diabetics
    2. Clinical presentation: chronic inflammation of the skin surrounding the nails; periungual erythema, edema and separation of the nail fold from the nail plate
  - Congenital candidiasis/neonatal candidiasis (see Chapter 2)
  - Chronic mucocutaneous candidiasis (CMC)
    1. Recurrent or severe infections of the skin, mucous membranes and nails with *Candida*, most frequently *C. albicans*
    2. Persistent infection, sometimes granulomatous, and resistant to therapy
    3. Rare disorder
    4. Majority of cases begin in the first 3 years of life
    5. Male/female ratio = 1
    6. Absence of visceral or disseminated sepsis
    7. Often associated with genetic, immunologic or endocrine dysfunction
    8. Most common immune defect is a specific inability to respond to antigens of *C. albicans*
  - Systemic candidiasis
    1. Candidal infection in the blood, urine or cerebrospinal fluid (CSF)

2. Affects 2–4% of very-low-birth-weight infants
3. Associated with long-term hospitalization, invasive instrumentation, immunosuppression
4. Cutaneous findings: erythematous macules, papules and plaques
- Other manifestations of candida infection: folliculitis, candidal intertrigo, vaginitis and vulvovaginitis, esophagitis and laryngitis, intravenous line sepsis, candiduria
- Risk factors for invasive infection:
  1. High risk: HIV, extreme prematurity, neutropenia, diabetes, chemotherapy, corticosteroid therapy
  2. Increased risk: neutrophil defects (chronic granulomatous disease or myeloperoxidase deficiency), intravenous hyperalimentation, broad-spectrum antimicrobial therapy

### Pathogenesis

- Causative pathogen is a yeast-like fungus of the genus *Candida*
- Most common is *Candida albicans* (50–60%), which is part of the normal flora of the gastrointestinal tract and mucocutaneous areas of humans; it is not part of the normal skin flora
- The yeast phase is the dominant form; the pseudohyphal (mycelial) phase is the invasive form; the chlamydospore is the resting state
- Mechanism of invasion is unclear
- Host defense factors against invasion include: intact stratum corneum, humoral immunity
- Person-to-person transmission rarely occurs
- Patients with immunodeficiency (e.g. HIV/AIDS, prematurity, organ transplantation, chemotherapy) are at risk for invasive/recurrent disease
- Other risk factors: endocrine dysfunction, malnutrition, prematurity, use of antibiotics

### Diagnosis

- Characteristic clinical findings
- KOH preparation shows pseudohyphae and budding yeast
- Culture is helpful but may be misleading; *Candida* can be cultured from non-infected skin
- Diagnosis of invasive candidiasis requires isolation of the organism from typically sterile body fluid or tissue (e.g. blood, CSF, bone marrow, biopsy)
- For early-onset, recurrent or recalcitrant candidal infections, suspect CMC and evaluate

for underlying endocrine and autoimmune disorders

### Differential diagnosis

- Oral candidiasis
  1. Lichen planus
  2. Food in the mouth
  3. Leukoplakia
  4. Squamous cell carcinoma
- Diaper candidiasis
  1. Irritant contact dermatitis
  2. Psoriasis
  3. Allergic contact dermatitis
- Candidal paronychia
  1. Bacterial infection
  2. Herpetic whitlow

### Treatment

- Oral candidiasis
  1. Oral nystatin suspension 100 000 U/ml four times a day PO, 'swish and swallow'
  2. Clotrimazole troches
  3. Elimination of predisposing factors (e.g. antibiotics)
  4. In the immunocompromised: oral fluconazole or itraconazole
- Skin infections
  1. Topical nystatin is effective and inexpensive
  2. Other topical antifungals: miconazole, clotrimazole, naftifine, ketoconazole, econazole, ciclopirox
- Vulvovaginal candidiasis
  1. Topical azoles are more effective than nystatin
  2. Clotrimazole, miconazole, ketoconazole, others
- Diaper candidiasis
  1. Topical nystatin or antifungal creams
  2. Oral nystatin may be of benefit, especially if there is thrush
  3. Protective barrier (e.g. zinc oxide-containing ointments) after dermatitis has resolved
  4. Elimination of predisposing factors, frequent diaper change, use of superabsorbent disposable diapers
- Chronic mucocutaneous candidiasis
  1. Usually refractory to traditional topical antifungal therapies and imidazole preparations
  2. Systemic antifungal agents: oral fluconazole, oral itraconazole and low-dose IV amphotericin B (0.3 mg/kg per day, maximum 1.5 mg/kg per day) have been used successfully

- 3. Immune enhancers
- 4. Maintenance on antifungal therapy may be necessary
- Systemic candidiasis
  1. Early treatment is critical, based on clinical suspicion, as culture may take days
  2. IV amphotericin B: drug of choice for disseminated disease
  3. Alternative treatment: fluconazole IV or PO
  4. Duration based on clinical response, presence or absence of neutropenia
  5. Flucytosine may be used as adjuvant in cases with CNS involvement; can act synergistically with amphotericin B

### Prognosis

- Based on the severity of disease and underlying predisposing factors
- Disseminated or invasive candidiasis can be rapidly fatal
- Chronic mucocutaneous candidiasis has a high frequency of relapse; severe infections with other organisms may occur and result in serious morbidity or death

### References

- Friedlander SF, Rueda M, Chen BK, Caceres-Rios HW. Fungal, protozoan, and helminthic infections. In: Pediatric Dermatology, 3rd edn. Schachner LA, RC Hansen, eds. CV Mosby: St Louis, 2003: 1093–129
- Garcia Hidalgo L. Dermatological complications of obesity. *Am J Clin Dermatol* 2002; 3: 497–506
- Kaufman D. Strategies for prevention of neonatal invasive candidiasis. *Semin Perinatol* 2003; 27: 414–24
- Mengesha YM, Bennett ML. Pustular skin disorders: diagnosis and treatment. *Am J Clin Dermatol* 2002; 3: 389–400
- Report of the Committee on Infectious Diseases. Red Book, 26th edn. American Academy of Pediatrics: Elk Grove Village, IL, 2003: 229–32
- Rowen JL. Mucocutaneous candidiasis. *Semin Perinatol* 2003; 27: 406–13

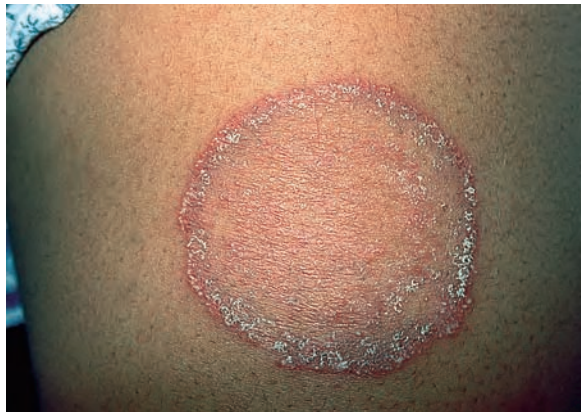## Tinea corporis

Synonym: ringworm

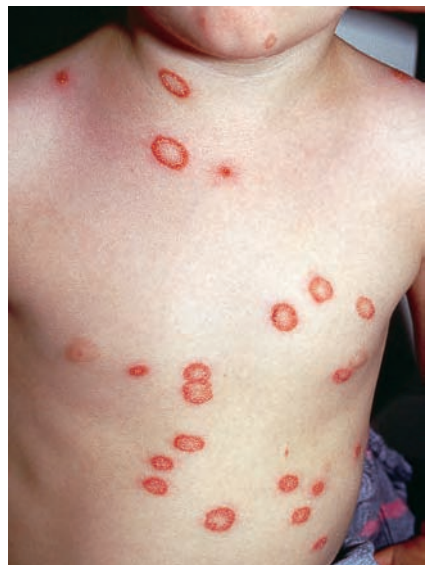### Major points

- Dermatophyte infection of body surfaces, not otherwise designated to a specific body site

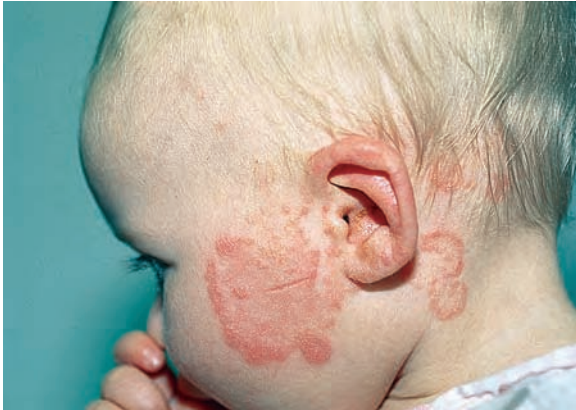- More prevalent in warm or moist climates
- Clinical presentation: red, scaly papules coalescing into annular plaques; may see erythema, vesicles, pustules, bulla, crusting; often unilateral; may be pruritic (Figures 9.2–9.4)
- Tinea incognito – alteration in appearance when topical corticosteroid is applied (source of diagnostic confusion)
- Tinea gladiatorum – tinea corporis affecting wrestlers; lesions usually on neck and upper arms where there is physical contact



**Figure 9.2** Tinea corporis – annular erythematous scaly plaque, acquired from a cat



**Figure 9.3** Tinea corporis – multiple inflammatory, annular lesions



**Figure 9.4** Tinea corporis – acquired from a kitten

- Tinea profunda – unusual clinical presentation of a boggy mass resembling a kerion
- Majocchi granuloma – perifollicular or follicular granulomatous inflammatory response to dermatophyte, often associated with topical steroid usage (Figure 9.5)
- Hypersensitivity eruption (dermatophytic or id reaction) – pruritic, fine papulovesicular eruption on trunk, hands, or face caused by a hypersensitivity reaction to fungal infection

#### Pathogenesis

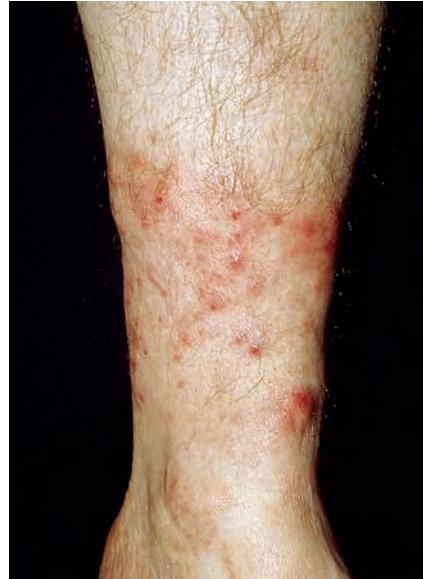- Most common causes: *Trichophyton tonsurans*, *T. rubrum* and *T. mentagrophytes*, *Microsporum canis* and *Epidermophyton floccosum*
- Transmission by direct contact with infected humans, animals, or fomites

#### Diagnosis

- KOH preparation – scraping should be performed from scale with demonstration of hyphae in epidermal cells
- Culture on dermatophyte test medium (DTM) or Sabouraud dextrose agar

#### Differential diagnosis

- Nummular eczema
- Granuloma annulare
- Candidiasis
- Erythema annulare centrifugum
- Psoriasis
- Pityriasis rosea
- Subacute cutaneous or discoid lupus erythematosus



**Figure 9.5** Majocchi granuloma from tinea pedis treated with topical steroids

#### Treatment

- Topical treatment usually sufficient in limited disease:
  1. Miconazole, clotrimazole, terbinafine, tolnaftate, naftifine, or ciclopirox, ketoconazole, econazole, oxiconazole, butenafine, or sulconazole until 1–2 weeks after clearance
  2. Minimum duration of therapy recommended is 4 weeks
  3. Treat until there is no scaling
- Oral antifungals for poor response or in extensive disease
  1. Griseofulvin 20 mg/kg per day PO for 4 weeks given 1–2 times a day
  2. Oral itraconazole, fluconazole and terbinafine (off label)
- Use of combination antifungal/corticosteroid (e.g. Lotrisone) can be associated with persistent/recurrent infection

#### Prognosis

- Cases resolve with treatment

#### References

Adams BB. Tinea corporis gladiatorum: a cross-sectional study. *J Am Acad Dermatol* 2000; 43: 1039–41



Alston SJ, Cohen BA, Braun M. Persistent and recurrent tinea corporis in children treated with combination antifungal/corticosteroid agents. *Pediatrics* 2003; 111: 201–3

Greenberg HL, Shwayder TA, Bieszk N, Fivenson DP. Clotrimazole/betamethasone dipropionate: a review of costs and complications in the treatment of common cutaneous fungal infections. *Pediatr Dermatol* 2002; 19: 78–81

Gupta AK, Chaudhry M, Elewski B. Tinea corporis, tinea cruris, tinea nigra, and piedra. *Dermatol Clin* 2003; 21: 395–400

Report of the Committee on Infectious Diseases. Red Book, 26th edn. American Academy of Pediatrics: Elk Grove Village, IL, 2003: 619–20

## Tinea pedis

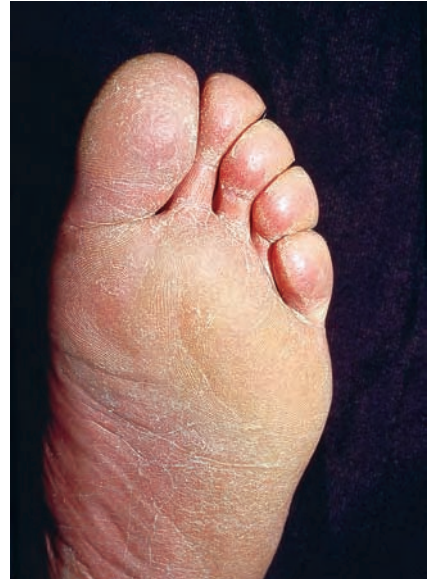Synonym: athlete's foot fungus

### Major points

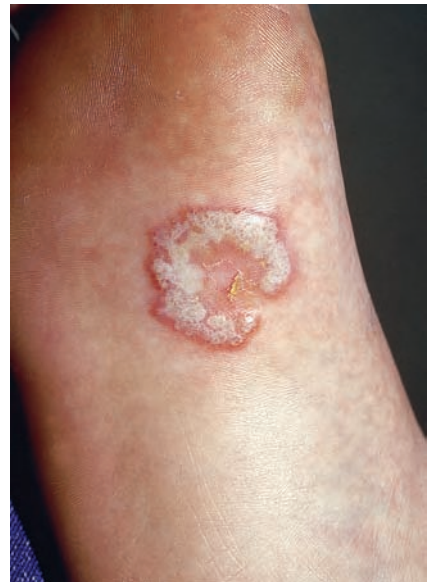- Prevalence in industrialized countries approaches 10%; men have a 20% risk of developing tinea pedis; increases in incidence with age (probably due to increased exposure)
- Uncommon in young children; common in adolescents and adults
- Clinical presentation: scaly, pruritic, erythematous eruption on the plantar and dorsal surfaces of the feet with maceration, peeling, and fissuring in the lateral toe web spaces (especially in the 3rd and 4th interdigital spaces); may see vesicles (Figures 9.6 and 9.7)
- Toenails can be affected and dystrophic
- Commonly occurs in association with tinea cruris
- Often a family history is positive (usually an affected parent)
- Hypersensitivity reaction to the fungus (dermatophytid or id reaction) may be present on the hands and feet with pruritic vesicles and papules

### Pathogenesis

- Causative organisms: *Trichophyton rubrum* (60%), *Trichophyton mentagrophytes* (25%), *Epidermophyton floccosum* (10%) and mixed (5%)
- Transmission is by person-to-person contact; often source of exposure in children is a parent
- Fungi also found in damp areas – swimming pools, locker rooms



**Figure 9.6** Tinea pedis – typical scaling on bottom of foot



**Figure 9.7** Tinea pedis – bullous, annular lesion with a positive KOH preparation

### Diagnosis

- Characteristic clinical manifestations
- KOH preparation – scraping reveals branching hyphae
- Fungal culture to confirm on DTM or Sabouraud media



### Differential diagnosis

- Dyshidrotic eczema
- Contact dermatitis
- Atopic dermatitis
- Juvenile plantar dermatosis ('sweaty-sock syndrome')
- Psoriasis
- Pitted keratolysis

### Treatment

- Topical antifungal therapy
  1. Miconazole, haloprogin, clotrimazole, ciclopirox, terbinafine, butenafine, tolnaftate, ketoconazole, econazole, naftifine, oxiconazole, or sulconazole
  2. Duration of treatment ~2–3 weeks
- Oral antifungals for severe, chronic, or recalcitrant tinea pedis
  1. Oral griseofulvin for 6–8 weeks
  2. Oral itraconazole or terbinafine (not US Food and Drug Administration (FDA)-approved for this indication)
- Superimposed bacterial infections treated with antibacterial agents (topical or systemic); soak feet in dilute bleach water (Dakin solution 0.25%) once daily for 15 minutes
- Prevention of recurrences:
  1. Foot hygiene: keep feet cool and dry; drying between toes; absorbent socks; air shoes between wearings
  2. Topical antifungal powder (e.g. ZeaSORB AF®)

### Prognosis

- Rarely, may be complicated by bacterial superinfection including lymphangitis, lymphadenitis and cellulitis

### References

- Gupta AK, Chow M, Daniel CR, Aly R. Treatments of tinea pedis. *Dermatol Clin* 2003; 21: 431–62
- McBride A, Cohen BA. Tinea pedis in children. *Am J Dis Child* 1992; 146: 844–7
- Report of the Committee on Infectious Diseases. Red Book, 26th edn. American Academy of Pediatrics: Elk Grove Village, IL, 2003: 621–3
- Sweeney SM, Wiss K, Mallory SB. Inflammatory tinea pedis/manum masquerading as bacterial cellulitis. *Arch Pediatr Adolesc Med* 2002; 156: 1149–52

Weinstein A, Berman B. Topical treatment of common superficial tinea infections. *Am Fam Physician* 2002; 65: 2095–102

Zaias N, Rebell G. Clinical and mycological status of the *Trichophyton mentagrophytes* (interdigitale) syndrome of chronic dermatophytosis of the skin and nails. *Int J Dermatol* 2003; 42: 779–88

### Tinea capitis

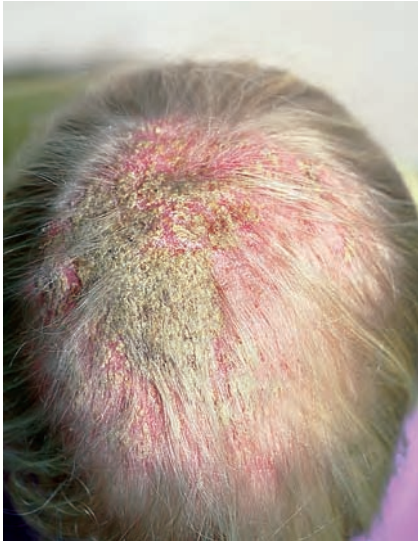Syndrome: Scalp ringworm

#### Major points

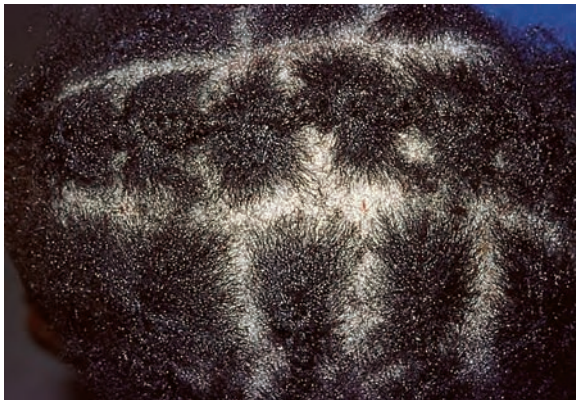- Most common in preschool or school-age children (ages 3–9 years)
- Incidence is highest in Black children
- Most common cause is *Trichophyton tonsurans* in North America (>90%)
- Clinical presentation is an incomplete alopecia especially prominent on the crown and occipital regions, with scaling
- Other clinical presentations:
  1. Asymptomatic scaling
  2. Widespread scaling with minimal hair loss (seborrheic dermatitis-like pattern) (Figures 9.8–9.10)
  3. Black-dot tinea – discrete areas of hair loss with stubs of broken hairs resembling dots
  4. Kerion – painful, inflamed, crusted mass with purulent discharge; often with associated fever and regional lymphadenopathy (Figure 9.11)
  5. Favus – inflammation and scarring characterized by yellow cup-shaped crusts (scutula), around a hair; rare in the USA
- Classified as ectothrix (spores on the surface of the hairs) which fluoresces with Wood's lamp or endothrix (spores inside the hair shaft) which does not fluoresce
- Hypersensitivity reaction (dermatophytic or id reaction); pruritic, fine, papulovesicular eruption on trunk, hands, or face may occur (Figure 9.12)

#### Pathogenesis

- Caused by dermatophytic fungi; common etiologic agents are *T. tonsurans* (anthropophilic) and *Microsporum canis* (zoophilic)
- Transmission is person-to-person or fomites such as combs, clothing, bedding, toys and furniture



**Figure 9.8** Tinea capitis – scaly patch of hair loss with *Microsporum canis*

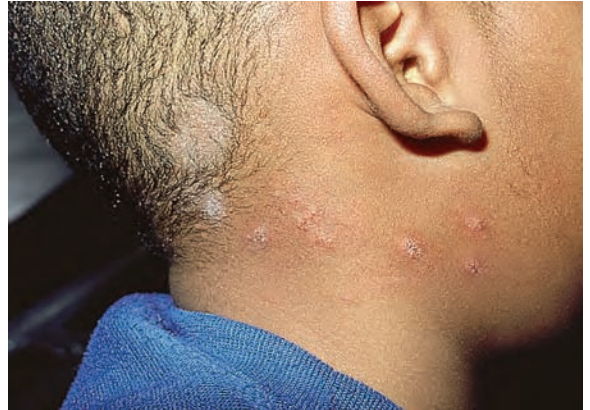

**Figure 9.9** Tinea capitis – typical diffuse scaling mistaken for dandruff

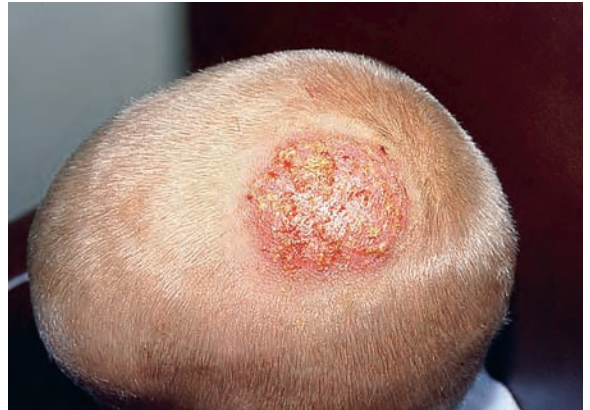- Asymptomatic individuals, especially family members, act as reservoirs for infection (~25% of family members affected)

#### Diagnosis

- Clinical examination
- KOH preparation: observe spores within broken-off hairs, rarely hyphae
- Culture – collect specimen by rubbing a sterile cotton swab over the scalp and inoculating in fungal media or DTM
- Skin biopsy may be necessary to confirm diagnosis in unusual cases, especially Majocchi granuloma



**Figure 9.10** Tinea capitis – scaling typical of *Trichophyton tonsurans* with additional tinea corporis



**Figure 9.11** Kerion – marked inflammation and crusting in the scalp

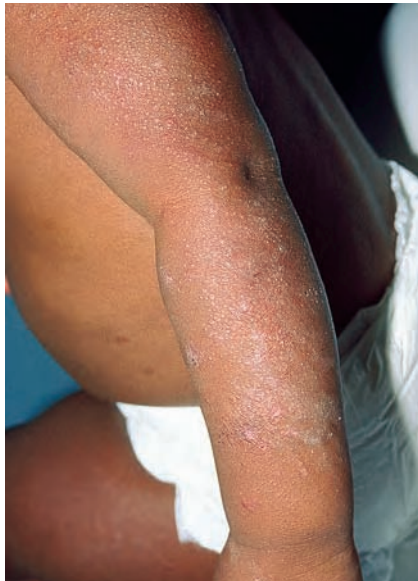- Histology: neutrophils in the upper stratum corneum; stain for fungi with periodic acid-Schiff (PAS) or methenamine silver stain

#### Differential diagnosis

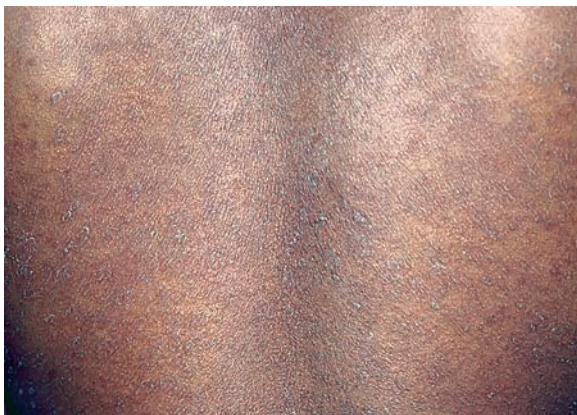
- Alopecia areata
- Trichotillomania
- Staphylococcal infection
- Traction alopecia
- Seborrheic dermatitis
- Psoriasis

#### Treatment

- Topical antifungals not fully effective
- Oral griseofulvin:



**Figure 9.12** Hypersensitivity reaction to tinea capitis



**Figure 9.13** Tinea versicolor with hyperpigmented scaly plaques

1. Microsize griseofulvin 20 mg/kg per day (maximum 1 g/24 hours)
2. Ultramicrosize griseofulvin 10 mg/kg per day (maximum 750 mg/24 hours)
3. Take BID with fatty foods to increase absorption
4. Minimal duration of treatment is 4–6 weeks; continue for 2 weeks past clinical resolution
- Adjuvant treatment to decrease fungal shedding and curb spread of infection:
  1. Selenium sulfide 2.5% shampoo 2–3 times a week
  2. Ketoconazole 1–2% shampoo 2–3 times a week
- Newer oral antifungal therapies shown to be safe and effective: (see doses in Chapter 21)
  - terbinafine, itraconazole, fluconazole
- Obtain follow-up cultures until negative result is obtained
- Evaluate household contacts and treat if necessary
- For severe inflammatory kerion: prednisone 1 mg/kg per day in addition to antifungal therapy, can hasten reduction of scaling and pruritus
- Secondary bacterial infection in a kerion should be treated with appropriate antibiotic therapy for *Staphylococcus* coverage

### Prognosis

- Usually resolves without permanent alopecia
- With severe inflammatory disease, scarring and permanent hair loss may occur, but tends to be rare and spotty

### References

- Abdel-Hamid IA, Agha SA, Moustafa YM, El-Labban AM. Pityriasis amiantacea: a clinical and etiopathologic study of 85 patients. *Int J Dermatol* 2003; 42: 260–4
- Chen BK, Friedlander SF. Tinea capitis update: a continuing conflict with an old adversary. *Curr Opin Pediatr* 2001; 13: 331–5
- Gupta AK, Adam P, Dlova N, et al. Therapeutic options for the treatment of tinea capitis caused by *Trichophyton* species: griseofulvin versus the new oral antifungal agents, terbinafine, itraconazole, and fluconazole. *Pediatr Dermatol* 2001; 18: 533–8
- Gupta AK, Cooper EA, Ginter G. Efficacy and safety of itraconazole use in children. *Dermatol Clin* 2003; 21: 521–35
- Gupta AK, Cooper EA, Lynde CW. The efficacy and safety of terbinafine in children. *Dermatol Clin* 2003; 21: 511–20
- Report of the Committee on Infectious Diseases. *Red Book*, 26th edn. American Academy of Pediatrics: Elk Grove Village, IL, 2003: 617–18

### Onychomycosis

Synonym: tinea unguium

### Major points

- Less common in children than adults; rare in children <6 years old



- Prevalence of onychomycosis in children is 0.3–0.44%
- Mycotic nail infection accounts for roughly 30% of nail diseases seen in childhood
- Most commonly affects the toenails
- Most common type in children is distal and lateral subungual onychomycosis
- Higher prevalence in children with Down syndrome or HIV infection
- Usually associated with tinea pedis

### Pathogenesis

- Most common causative agent is *Trichophyton rubrum*, followed by *Candida* sp. and *T. interdigitale*
- Transmission usually from a family member

### Diagnosis

- KOH preparation – scrape underneath the nail plate or take fine clippings or filings through the entire thickness of the nail with visualization of hyphae
- Histology of nail clipping with PAS staining can demonstrate fungal elements
- For severe disease, must exclude immunodeficiency, HIV, endocrinopathies

### Differential diagnosis

- Psoriasis
- Lichen planus
- Alopecia areata
- Twenty-nail dystrophy

### Treatment

- Mild cases may respond to topical therapy:
  1. Terbinafine or ketoconazole creams
  2. Ciclopirox 8% lacquer (Penlac)
- Oral antifungals needed for moderate to severe disease: griseofulvin, itraconazole, terbinafine, fluconazole
- Adjuvant surgical debridement or excision of affected nail may be of benefit for severely affected nails
- Foot hygiene to reduce recurrence: keep feet cool, clean and dry; absorbent socks; antifungal foot powders; well-fitting shoes; avoid barefoot contact with areas with a high density of fungal spores, such as bathroom floors, gymnasiums and locker rooms

### Prognosis

- May be recurrent

### References

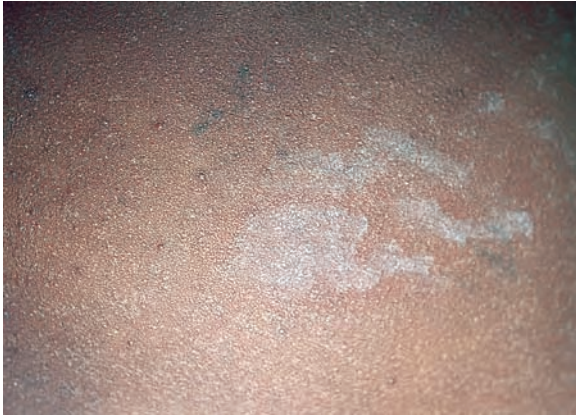- Arrese JE, Pierard GE. Treatment failures and relapses in onychomycosis: a stubborn clinical problem. *Dermatology* 2003; 207: 255–60
- Faergemann J, Baran R. Epidemiology, clinical presentation and diagnosis of onychomycosis. *Br J Dermatol* 2003; 149 (Suppl 65): 1–4
- Ghannoum MA, Hajjeh RA, Scher R, et al. A large-scale North American study of fungal isolates from nails: the frequency of onychomycosis, fungal distribution and antifungal susceptibility patterns. *J Am Acad Dermatol* 2000; 43: 641–8
- Gupta AK, Chang P, Del Rosso JQ, et al. Onychomycosis in children: prevalence and management. *Pediatr Dermatol* 1998; 15: 464–71
- Gupta AK, Skinner AR. Onychomycosis in children: a brief overview with treatment strategies. *Pediatr Dermatol* 2004; 21: 74–9
- Gupta AD, Skinner AR. Onychomycosis in children: a brief overview with treatment strategies. *Pediatr Dermatol* 2004; 21: 74–9
- Scher RK, Baran R. Onychomycosis in clinical practice: factors contributing to recurrence. *Br J Dermatol* 2003; 149 (Suppl 65): 5–9

### Tinea versicolor

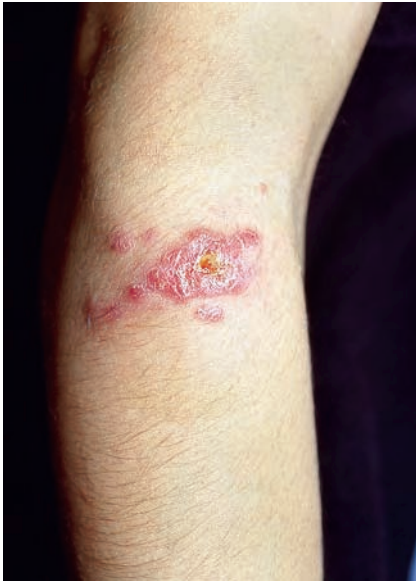Synonyms: pityriasis versicolor

### Major points

- Worldwide distribution
- Superficial chronic fungal infection
- Common in temperate regions: prevalence of ~1% during warmer parts of the year
- More common in tropical and subtropical regions: incidence of up to 40% in tropics
- Majority of cases occur during adolescence
- 5–7% of cases occur in children <13 years
- Male/female ratio = 1
- Family history is often positive
- Clinical presentation:
  1. Discrete or confluent hypopigmented or hyperpigmented (fawn-colored or brown) oval macules and patches with slight, fine scale (Figures 9.13 and 9.14)



**Figure 9.14** Tinea versicolor with typical furfuraceous scale



**Figure 9.15** Sporotrichosis – grouped erythematous papules and nodules

2. Distribution over back, upper chest and shoulders, neck and proximal extremities
3. The face is commonly affected in children (rarely in adults)
4. Lesions fail to tan normally and are more prominent in summer months
- Other related conditions:
  1. *Pityrosporum* folliculitis
  2. Obstructive dacryocystitis – from colonization of the lacrimal sac
  3. Confluent and reticulate papillomatosis – may represent a host response to *P. orbiculare*
  4. Systemic infection in patients receiving intralipid therapy: neonates with cardiovascular disease, or immunosuppressed

### Pathogenesis

- Causative agent is *Pityrosporum orbiculare* (*Malassezia furfur*)
- Lipophilic yeast, part of the normal flora of the skin
- Not contagious
- *P. orbiculare* changes from the round, budding blastospore form to the hyphal form under predisposing conditions:
  1. Exogenous factors: heat, humidity or moisture, or occlusive clothing
  2. Endogenous factors: adrenalectomy, diabetes, pregnancy, malnutrition, systemic corticosteroids, immunosuppression, hyperhidrosis, seborrheic dermatitis

### Diagnosis

- Characteristic skin findings
- Wood's lamp may aid in diagnosis of subclinical patches
- KOH preparation – 'spaghetti and meatballs' appearance of budding yeast cells and hyphae
- Culture/biopsy usually unnecessary

### Differential diagnosis

- Vitiligo
- Pityriasis alba
- Postinflammatory hypopigmentation
- Psoriasis
- Seborrheic dermatitis
- Erythrasma
- Dermatophytosis

### Treatment

- Topical therapy
  1. Selenium sulfide 2.5% applied once a day for 7 days for 10 minutes, and washed off; then on the first and third day of the month for 6 months
  2. Propylene glycol 50% in water applied once or twice a day
  3. Topical azoles: ketoconazole, miconazole, oxiconazole once or twice a day



4. Topical terbinafine 1% cream
- Systemic therapy: ketoconazole 400 mg in a single dose, repeated 1 week later; exercise to induce sweating increases skin concentration and increases effectiveness of systemic therapy

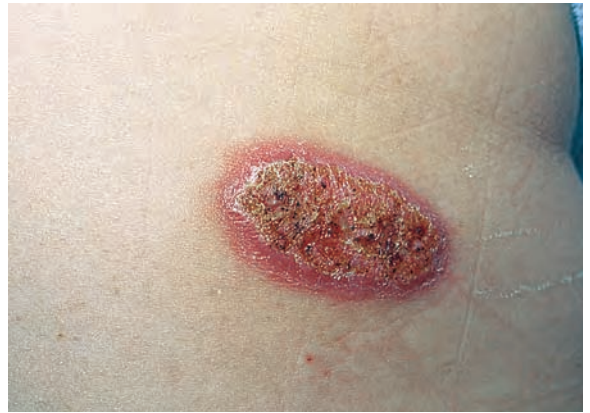### Prognosis

- Repigmentation may take months or years
- Recurrence rates high, 60–80%, with topical therapy

### References

- Gupta AK, Batra R, Bluhm R, Faergemann J. Pityriasis versicolor. *Dermatol Clin* 2003; 21: 413–29
- Report of the Committee on Infectious Diseases. Red Book, 26th edn. American Academy of Pediatrics: Elk Grove Village, IL, 2003: 623–4
- Terragni, L, Lassagni A, Oriani A, Gelmetti C. Pityriasis versicolor in the pediatric age. *Pediatr Dermatol* 1991; 8: 9–12
- Vander Straten MR, Hossain MA, Ghannoum MA. Cutaneous infections dermatophytosis, onychomycosis, and tinea versicolor. *Infect Dis Clin North Am* 2003; 17: 87–112

- Severe disease manifestations: disseminated visceral, osteoarticular meningel, and pulmonary sporotrichosis
- Usually affects normal hosts; disease more severe in immunosuppressed people



**Figure 9.16** Blastomycosis – isolated verrucous plaque on the leg

## DEEP FUNGAL INFECTIONS

### Sporotrichosis

#### Major points

- Worldwide distribution
- Clinical presentation: subacute or chronic cutaneous and subcutaneous infection
  1. Lymphocutaneous sporotrichosis – commonly on upper or lower extremities or face; incubation period 1–3 weeks; begins with small, firm, subcutaneous, violaceous nodules with regional lymphadenopathy; over the next 2 weeks, secondary nodules and streaking appear following the course of lymphatics; often ulcerates; facial localization common in children (Figure 9.15)
  2. Fixed cutaneous sporotrichosis – erythematous papules, nodules, or verrucous plaques (may ulcerate) with scale or crust surrounded by violaceous halo; does not extend past point of inoculation
  3. Children more commonly have solitary lesions

- Risk factors for severe disease: strong association with HIV infection, diabetes, chronic obstructive pulmonary disease (COPD)
- Pulmonary and disseminated sporotrichosis is rare in children

#### Pathogenesis

- Causative agent is *Sporothrix schenckii*, a dimorphic fungus which exists as a mold in nature and as yeast *in vivo* at a temperature of 37°C
- The organism grows in sphagnum moss, thorny plants (especially roses), decaying vegetation, soil and hay
- Infection occurs with exposure to environmental foci at the site of minor trauma; specific activities associated with disease include rose gardening, topiary production, Christmas tree farming, hay baling, masonry; inoculation may occur after motor vehicle or other accidents or animal (especially cat) bites/scratches
- Pulmonary sporotrichosis – transmitted by inhalation of spores
- T-cell-mediated immunity is important in host defense; disease more severe in patients with AIDS

### Diagnosis

- Culture scrapings or exudates from site of infection on Sabouraud dextrose agar at room temperature; read at 4–7 days; conversion to yeast form demonstrated on brain–heart infusion agar at 37°C
- Skin biopsy for culture/examination with special stains (e.g. PAS) demonstrates organisms
- No definitive serologic test available

### Differential diagnosis

- Bacterial infection
- Pyoderma
- Spider or insect bite
- Non-tuberculous mycobacteria infection
- Nocardiosis
- Deep fungal infections: blastomycosis, paracoccidiomycosis, chromoblastomycosis
- Tularemia
- Leishmaniasis

### Treatment

- Itraconazole 100 mg/day PO for 3–6 months
- Saturated solution of potassium iodide (SSKI)
  1. For a 50–70 kg person: 5 drops (50 mg/drop) three times daily, increasing 1 drop per dose per day to a maximum of 30–35 drops TID for 4–6 weeks after resolution of the lesion (do not increase if there is severe nausea)
  2. For infants and smaller children: 1 drop TID, increasing to a maximum of 10 drops TID for 4–6 weeks until resolution of lesions
- Local heat therapy applied ~1 hour/day for many months (baths at ~45°C, hot compress, hand-held heater); watch for burns
  1. Basis for treatment is that growth of some strains is inhibited by temperature of >35°C, killed at a temperature of 39°C
- Amphotericin B – for pulmonary, disseminated and meningeal disease, and in children with immunodeficiency

### Prognosis

- May lead to scarring or hyperpigmentation

### References

Burch JM, Morelli JG, Weston WL. Unsuspected sporotrichosis in childhood. *Pediatr Infect Dis J* 2001; 20: 442–5

De Araujo T, Marques AC, Kerdel F. Sporotrichosis. *Int J Dermatol* 2001; 40: 737–42

Koga T, Matsuda T, Matsumoto T, Furue M. Therapeutic approaches to subcutaneous mycoses. *Am J Clin Dermatol* 2003; 4: 537–43

Queiroz-Telles F, McGinnis MR, Salkin I, Graybill JR. Subcutaneous mycoses. *Infect Dis Clin North Am* 2003; 17: 59–85, viii

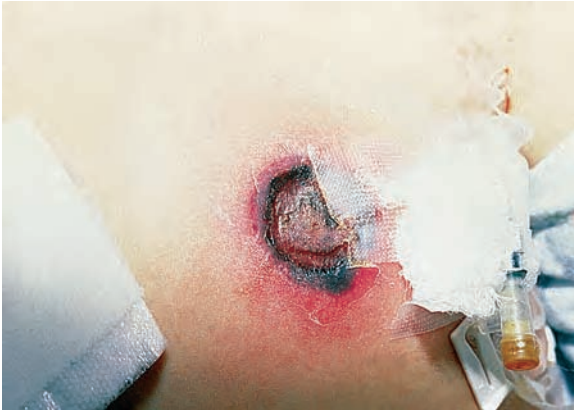Report of the Committee on Infectious Diseases. Red Book, 26th edn. American Academy of Pediatrics: Elk Grove Village, IL, 2003: 558–9

### Blastomycosis

Synonyms: North American blastomycosis, Gilchrist disease

#### Major points

- Endemic in midwest and south central USA, the Great Lakes region, upstate New York, Eastern Canada, Manitoba
- Cases have been reported in Africa, and rarely in Central and South America, Europe, India and the Middle East
- Rare in children
- Clinical findings: acute, primary pulmonary infection (often subclinical) occurs after a 30–45-day incubation period; this may resolve or progress to chronic pulmonary infection or dissemination with extrapulmonary manifestations, such as cutaneous findings (secondary cutaneous blastomycosis)
- Skin is involved in 40–80% of cases where there is extrapulmonary disease
- Cutaneous lesions are verrucous or ulcerative with heaped-up borders; usually slowly enlarging; erythema nodosum has been reported; may see subcutaneous nodules (Figure 9.16)
- Other organs involved include: bones and joints, genitourinary system, CNS (mass lesion or meningitis)
- Primary cutaneous blastomycosis – relatively rare, inoculation occurs after trauma (e.g. dog bite, open wounds); lymphangitis and regional lymphadenopathy often accompany the skin lesion; no evidence of systemic infection; the organism can be recovered from the skin lesion
- Immunosuppression is a risk factor for disease, and also for more aggressive disease with higher mortality
- Intrauterine or congenital infections occur rarely



**Figure 9.17** Mucormycosis – acquired from infected tape

### Pathogenesis

- Causative agent is *Blastomyces dermatitidis*, a dimorphic fungus, growing in a mycelial form at room temperature and in a yeast form at 37°C; reproduces with characteristic broad-based budding
- The organism is found in warm, damp soil
- Transmission to humans is most often via lungs; aerosolized conidia are inhaled and transform to the yeast form at body temperature
- Person-to-person transmission does not occur
- Cellular immunity and adequate neutrophil and humoral responses are among the factors necessary for host defense

### Diagnosis

- Clinical findings
- Histology: thick-walled, broad-based budding yeasts
- Specimen collection:
  1. Sputum: organisms can be seen on KOH preparation or by special stains
  2. Wet preparation or special stains of exudates from cutaneous lesions, synovial fluid, or soft tissue abscesses usually reveal organisms
  3. CSF is usually negative
- Culture needed for definitive diagnosis
- Serologic assays not sensitive or specific

### Differential diagnosis

- Pyoderma gangrenosum
- Squamous cell carcinoma

- Other cutaneous infections: sporotrichosis, nocardiosis, atypical mycobacteria, tularemia, leishmaniasis

### Treatment

- Amphotericin B IV has greatest proven treatment success (cure rates up to 97%)
- Itraconazole 4–10 mg/kg per day has been used to treat non-life-threatening blastomycosis in children; treatment course is many months

### Prognosis

- May result in chronic pulmonary disease
- In immunosuppressed patients, serious disease is frequent with complications of CNS disease, acute respiratory distress syndrome, fungemia and high mortality rates

### References

- Bradsher RW, Chapman SW, Pappas PG. Blastomycosis. *Infect Dis Clin North Am* 2003; 17: 21–40
- Lemos LB, Baliga M, Guo M. Blastomycosis: the great pretender can also be an opportunist. Initial clinical diagnosis and underlying diseases in 123 patients. *Ann Diagn Pathol* 2002; 6: 194–203
- Pappas PG, Dismukes WE. Blastomycosis, Gilchrist's disease revisited. *Curr Clin Top Infect Dis* 2002; 22: 61–77
- Report of the Committee on Infectious Diseases. Red Book, 26th edn. American Academy of Pediatrics: Elk Grove Village, IL, 2003: 219–20
- Zampogna JC, Hoy MJ, Ramos-Caro FA. Primary cutaneous North American blastomycosis in an immunosuppressed child. *Pediatr Dermatol* 2003; 20: 128–30

## Mucormycosis

### Major points

- Acute, rapidly progressive, fatal disease occurring in immunosuppressed patients caused by opportunistic fungi
- Cutaneous mucormycosis:
  1. Superficial: gradual onset with slow progression, associated with the use of contaminated adhesive tape; no vascular or deep tissue involvement (Figure 9.17)
  2. Gangrenous: progresses rapidly with painful ulcers and eschars; vascular invasion with

hematogenous spread common; poor prognosis; usually occurs in the setting of skin trauma (e.g. IM injection, open fracture, insect bites, motor vehicle accidents) in patients with an underlying predisposing condition

- a. Premature infants: associated with contaminated adhesive tape use or wooden tongue depressors for limb splinting; very grave prognosis in this setting
  - b. Older children with underlying myeloproliferative disease
- Other clinical presentations:
    1. Rhinocerebral: most common, affects diabetics with underlying ketoacidosis
    2. Pulmonary: more common in patients with hematologic malignancies
    3. Gastrointestinal: usually seen only with severe malnutrition; high (98%) mortality rate
    4. Disseminated: more common in patients with hematologic malignancies
  - Infection affects patients with neutropenia, diabetes, generalized immunosuppression (hematologic malignancy, bone marrow or solid organ transplantation, HIV/AIDS), deferoxamine therapy, trauma, burns
  - Rarely occurs in immunocompetent individuals

### Pathogenesis

- Caused by fungi in the family Mucoraceae; opportunistic 'bread molds'
- Most common pathogen is *Rhizopus oryzae*
- Organism is present in decaying fruits and vegetables, seeds, soil and animal excreta
- Infection occurs after skin/soft tissue trauma, ingestion of spores (gastrointestinal form), use of contaminated tape in a patient with underlying predisposing factors
- Angiotrophic nature of the fungus results in vascular invasion and destruction leading to skin necrosis and ulceration
- Infection occurs in patients with impaired neutrophil or mononuclear cell phagocytic function

### Diagnosis

- Early diagnosis is critical
- Tissue biopsy usually needed for diagnosis – direct microscopic examination with hematoxylin and

eosin (H&E), PAS staining or Gomori's methenamine silver

- Organism grows on routine bacterial and fungal culture media

### Differential diagnosis

- Aspergillosis
- Ecthyma gangrenosum (pseudomonas infection)

### Treatment

- Extensive surgical debridement of necrotic tissue required (due to poor penetration of antifungal agents)
- Amphotericin B, IV
- Correction of underlying disease

### Prognosis

- High mortality rates; especially with infection in infants
- Older children have somewhat better prognosis
- Prognosis is best for the cutaneous form of the disease
- Mortality rates:
  1. Cutaneous 16%
  2. Rhinocerebral 67%
  3. Pulmonary 83%
  4. Disseminated and gastrointestinal disease ~100%
- Early detection, extensive surgical debridement, and systemic amphotericin B necessary for survival

### References

- Boyd AS, Wiser B, Sams HH, King LE Jr. Gangrenous cutaneous mucormycosis in a child with a solid organ transplant: a case report and review of the literature. *Pediatr Dermatol* 2003; 20: 411–15
- Leitner C, Hoffmann J, Zerkowski M, Reinert S. Mucormycosis: necrotizing soft tissue lesion of the face. *J Oral Maxillofacial Surg* 2003; 61: 1354–8
- Prabhu RM, Patel R. Mucormycosis and entomophthoromycosis: a review of the clinical manifestations, diagnosis and treatment. *Clin Microbiol Infect* 2004; 10: 31–47

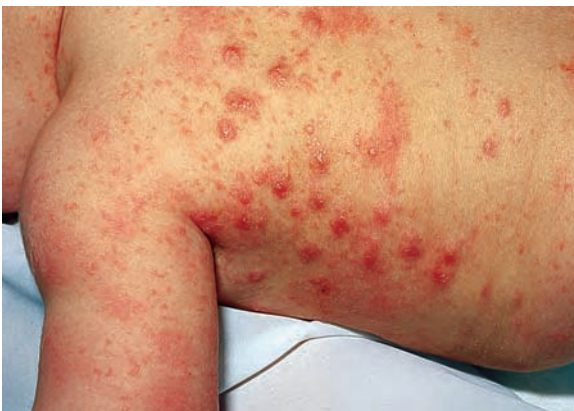# INFESTATIONS AND ENVIRONMENTAL HAZARDS

---

## Scabies

### Major points

- Papules on wrists, fingerwebs, periaxillary skin, genitalia and abdomen
- In infants, lesions more generalized: feet, scalp and face
- Multiple excoriations, erythematous papules, honey-colored crusts, some pustules and secondary impetigo
- Pruritus, often increased in evening/night
- Erythematous nodules (nodular scabies) more common on trunk and axillae, particularly in infants (Figure 10.1)
- Debilitated or immunosuppressed individuals who are unable to scratch may be severely affected
- Burrows (linear superficial lesions) are diagnostic; usually seen on wrists, interdigital webs, or feet of infants (Figures 10.2 and 10.3)

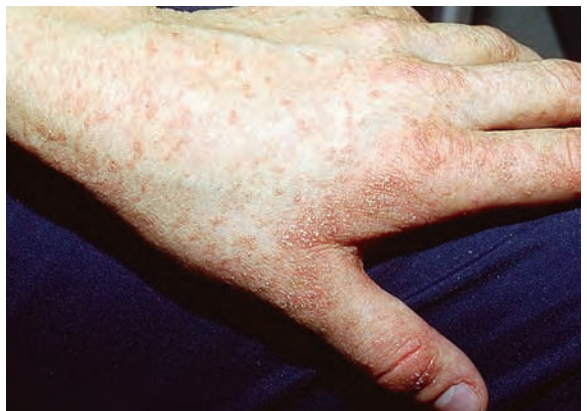

**Figure 10.1** Nodular scabies – usually more prominent in the axillary areas

- Symptoms may vary: asymptomatic carriers, or few scattered itchy papules, or hundreds of lesions, or thick crusts which have hundreds of mites (crusted scabies)
- High index of suspicion in pruritic patients
- Family members are often itchy, although degree of itching may vary

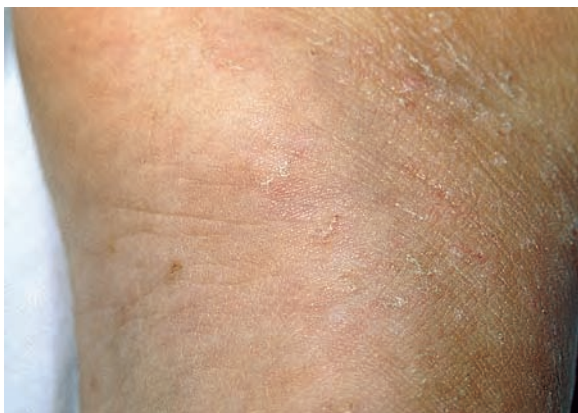### Pathogenesis

- Caused by eight-legged human mite, *Sarcoptes scabiei*, <0.4 mm in length
- Female mite remains within stratum corneum where she lays eggs and can move 0.5–5 mm/day; female mite lives 30–40 days; burrows up to 5 mm/day; lays 2–3 eggs/day; eggs take 10–14 days to mature
- Human contact or contagious clothing or bed sheets (fomites) necessary for transmission



**Figure 10.2** Scabies – typical pruritic papules on the hands and finger webs



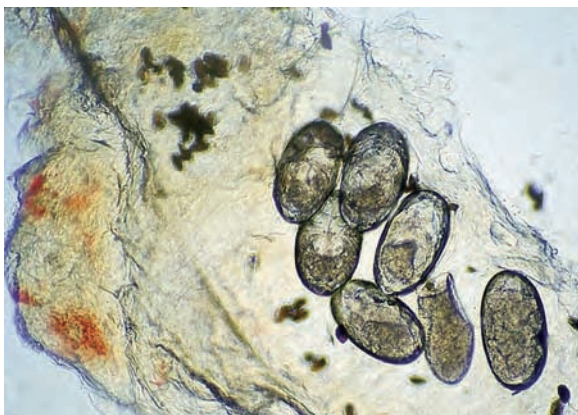

**Figure 10.3** Scabies – burrow showing linear tunnel with tiny, dark dot at end which is the mite

- Newly infested individuals may not itch for 3–6 weeks and may be a source of infestation

### Diagnosis

- Confirmed by scraping an unscratched burrow, demonstrating a mite, egg, feces (scybala) microscopically (Figure 10.4)



**Figure 10.4** Scabies – typical eggs and feces seen microscopically

- Technique of scraping:
  1. Scrape several lesions, preferably unscratched burrows with a no. 15 blade
  2. Place scales on glass slide, cover with immersion oil or KOH and coverslip
  3. Microscope objective on low power: 4× or 10×
- Adult female mite has a round body, eight legs, length ~0.3 mm; male is half that size

### Differential diagnosis

- Atopic dermatitis
- Lichen planus
- Dermatitis herpetiformis
- Papular urticaria (insect bites)
- Impetigo
- Folliculitis
- Contact dermatitis
- Histiocytosis

### Treatment

- Permethrin cream 5% (see Table 10.1)
  1. Dispense 60 g per patient; no refills
  2. Apply thin layer of cream from neck down to toes
  3. Be sure to include finger webs, armpits, groin
  4. Leave cream on for 8–12 hours (overnight)
  5. Take a hot shower or bath in the morning
  6. Wash clothes used in previous 3 days through the hot cycle of the washer
  7. Reapply cream (same technique) 1 week later
  8. Do not apply cream more than twice
- Gamma benzene hexachloride lotion or cream 1% (lindane, Kwell®, Gamene®)
  1. Dispense 60 g per patient; no refills
  2. A bath is not recommended before applying the lotion

**Table 10.1** Instruction sheet for scabies treatment

#### Permethrin cream 5%

A bath is not necessary before applying the cream. If you take a bath, wait half an hour before applying the cream. Apply a thin layer from the neck down to the toes. Be sure not to forget finger webs, fingernails, armpits and groin. Leave cream on for 8–12 hours (overnight). After this, take a hot shower or bath to remove the cream. At the time of the shower, wash clothing and bed linen used in the previous 3 days in the hot cycle of the washer. Reapplication is necessary 1 week later (left on 8–12 hours – same routine). Be sure to keep your return appointment with your doctor.

Do not apply this cream more than is recommended by your doctor

3. Apply a thin layer of cream or lotion from the neck down to the toes. Be sure to include finger webs, armpits and groin
4. Leave cream on for 8–12 hours (overnight)
5. In the morning, take a hot shower or bath
6. At time of shower, wash clothing and bed linen used in previous 3 days in hot cycle of washer
7. Reapply cream or lotion (same technique) 1 week later (left on for 8–12 hours) with same routine
8. Lindane should not be used by pregnant women, women who are breast feeding, or very young infants
9. Do not apply this lotion more than is recommended
- Precipitated sulfur ointment 6–10% (for infants, small children, and pregnant patients)
  1. Apply thin layer of ointment from neck down to toes
  2. Be sure to apply between fingers, toes, in armpits and groin
  3. For babies who have lesions on their heads, apply ointment directly to these areas
  4. Leave ointment on for 24 hours
  5. After this time, the patient may bathe
  6. Reapply ointment in the same manner. Leave on for 24 hours
  7. Again reapply ointment; three times each for 24 hours (total 72 hours)
  8. After 72 hours, wash clothing and bed linen used in previous 3 days in hot cycle of washer and dryer
  9. Sulfur ointment is messy and odiferous, and may stain clothing
- Ivermectin (oral) 150–400 µg/kg for teens and adults (off label)
  1. Single dose orally is 95% effective; repeat at 2 weeks if necessary
  2. Administered as 6-mg scored tablets (range 9–18 mg depending upon weight)
- Other points:
  1. Follow-up in 2–3 weeks to prevent patient from continually treating themselves for itching.
  2. Patients may need hydrocortisone 1–2.5% cream or ointment to calm residual itching
  3. Be sure to treat all family members and others with close personal contact
  4. People do not get human scabies from animals

## References

- Avila-Romay A, Alvarez-Franco M, Ruiz-Maldonado R. Therapeutic efficacy, secondary effects, and patient acceptability of 10% sulfur in either pork fat or cold cream for the treatment of scabies. *Pediatr Dermatol* 1991; 8: 64–6
- Hoke AW, Maibach HI. Scabies management: a current perspective. *Cutis* 1999; 64: 2–16
- Huynh TH, Norman RA. Scabies and pediculosis. *Dermatol Clin* 2004; 22: 7–11
- Kim K-J, Rosh K-H, Choi J-H, et al. Scabies incognito presenting as urticaria pigmentosa in an infant. *Pediatr Dermatol* 2002; 19: 409–11
- Meinking TL, Taplin D, Hermida JL, et al. The treatment of scabies with ivermectin. *N Engl J Med* 1995; 333: 26–30
- Paller AS. Scabies in infants and small children. *Semin Dermatol* 1993; 12: 3–8
- Pruksachatkunakorn C, Damrongsak M, Sinthupuan S. Sulfur for scabies outbreaks in orphanages. *Pediatr Dermatol* 2002; 19: 448–53
- Usha V, Gopalakrishnan Nair TV. A comparative study of oral ivermectin and topical permethrin cream in the treatment of scabies. *J Am Acad Dermatol* 2000; 42: 236–40

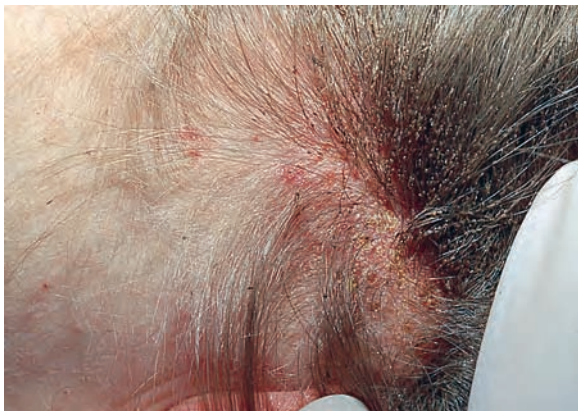## Pediculoses (louse infestations)

### Major points

- Body louse infestations present with excoriated papules and pustules on trunk and perineum
- *Pediculosis capitis* usually presents with pruritic papules at nape of neck (Figure 10.5)
- Nits and lice can be detected in scalp or clothing, especially seams of clothing
- Nits are white ovoid bodies, tightly adherent to hair shafts
- Head lice are infrequent in Black patients
- Pubic lice ('crabs') occasionally with blue-black crusted macules (maculae ceruleae)
- Pubic lice can also be seen in eyelashes or the scalp of young children

### Pathogenesis

- Caused by *Pediculus humanus* (human body louse) with subspecies *capitis* (head lice) or *humanus* (body lice) and *Phthirus pubis* (crab lice)
- Lice are six-legged insects, 1–4 mm long; they attach to skin or hair and ingest blood



**Figure 10.5** Pediculosis (lice) – pruritic papules and nits at the nape of the neck

- The female louse produces new offspring every 2 weeks, attaching to hair and depositing eggs along the hair shaft
- Crowded living conditions are ideal for spreading infestation through direct contact
- Fomites (e.g. hairbrushes, hats, scarves, coats, clothes)
- Body lice carry typhus in some endemic areas

### Diagnosis

- Observation of nits or lice by visual inspection or microscopically (Figure 10.6)

### Differential diagnosis

- Scabies
- Insect bites (mosquitoes, fleas)



**Figure 10.6** Pediculosis (lice) – louse with nits microscopically (courtesy of Dr Anne Lind)

- Dermatitis herpetiformis
- Factitial excoriations
- Pseudonits (retained external hair root sheath)

### Treatment

- *Pediculosis Capitis* (Head lice)
  1. Permethrin 1% (Nix®) one application of cream rinse, left on for 10 minutes after shampoo, then rinsed out
  2. Pyrethrins with piperonyl butoxide (RID®, A-200 Pyrinat Shampoo®) two applications (5–7 days apart) applied undiluted to the scalp, left on 10 minutes, then rinsed out
  3. Lindane 1% shampoo (by prescription) 10-minute application then rinsed out; repeat in 1 week
  4. Malathion 0.5% (Ovide®) excellent ovicidal, but odiferous. Apply to hair, let dry for 8–12 hours, then shampoo out. Repeat in 1 week. Caution: flammable
  5. Ivermectin 200–250 µg/kg in a single oral dose (off label)
  6. Other hints
    - a. Apply cream rinse and comb hair to remove nits
    - b. Chemicals used to ‘dissolve’ nits (of questionable value): vinegar, glacial acetic acid, Step 2® (formic acid); use with combing
    - c. Metal nit combs – helpful if hair is thick
    - d. Nit picking – if hair is thin (may want to cut individual hairs)
    - e. R & C Spray® – for use on clothing, furniture which cannot be washed or dry cleaned; do not use on people
    - f. Pseudonits – flakes of skin on hair shafts which may resemble nits; to differentiate, observe microscopically
- *Pediculosis corporis* (Body lice)
  1. Proper hygiene, clean clothes, clean housing conditions
  2. Lindane lotion 1% (left on 8 hours, then washed off)
- *Pediculosis pubis* (crab lice)
  1. Lindane 1% shampoo
    - a. 5-minute application, then wash out
    - b. Repeat in 1 week
    - c. Nits should be removed

2. Synergized pyrethrins (OTC)-(RID®, R & C Shampoo®, A-200®)
  - a. Apply undiluted, leave on 10 minutes, then wash off
  - b. Second application in 1 week
3. Treat sexual contacts or other appropriate contacts
4. Eyelash involvement
  - a. Use petrolatum 3–5 times a day for 8 days
  - b. Remove nits
  - c. Do not use lindane or pyrethrins on the eyelids

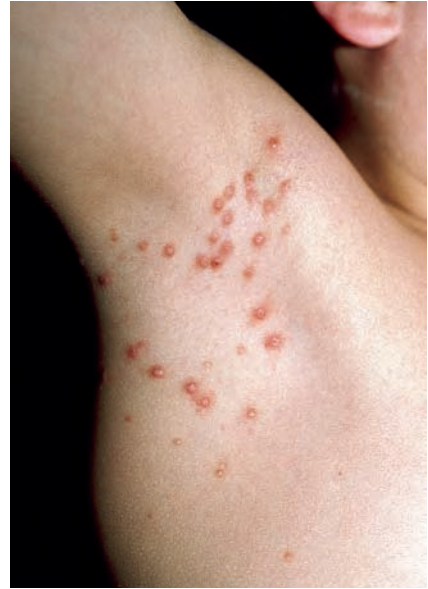### References

- Burgess IF. Human lice and their control. *Annu Rev Entomol* 2004; 49: 457–81
- Drugs for head lice. *Medical Letter* 1997; 39 (Issue 992): 6–7
- Frankowski B, Weiner LB. Head lice. *Pediatrics* 2002; 110: 638–43
- Huynh TH, Norman RA. Scabies and pediculosis. *Dermatol Clin* 2004; 22: 7–11
- Ko CJ, Elston DM. Pediculosis. *J Am Acad Dermatol* 2004; 50: 1–12
- Meinking TL, Serrano L, Hard B, et al. Comparative *in vitro* pediculicidal efficacy of treatments in a resistant head lice population in the United States. *Arch Dermatol* 2002; 138: 220–4
- Williams LK, Reichert A, MacKenzie WR, et al. Lice, nits and school policy. *Pediatrics* 2001; 107: 1011–15

### Papular urticaria (insect bite reactions)

#### Major points

- Clinical points
  1. Erythematous pruritic papules (Figure 10.7)
  2. May be grouped in clusters; where the insect bit several times, it looks like ‘breakfast, lunch and dinner’
  3. Occasional vesicles or bullae, especially in young children
  4. May be anywhere on the body, but typically on exposed skin
  5. Children aged 18 months to 10 years typically affected
  6. Recurrent crops common
  7. One child in the family may be the only person bitten



**Figure 10.7** Papular urticaria (insect bite reactions) – multiple, erythematous, pruritic papules

8. Common in spring or summer
9. Some immunosuppressed children or those with HIV infections can have severe exaggerated reactions
10. Harvest mites (chiggers)
  - a. *Trombiculidae splendens*
  - b. Bright red mites
  - c. Tends to occur in intertriginous areas and around waistband
  - d. Larval form takes blood meal then drops off

#### Pathogenesis

- Lesions caused by delayed hypersensitivity reaction to insect bite
- Fleas (dog or cat), mosquitoes, bedbugs, lice, scabies or mites (fowl, grain, grass) can be implicated in most cases

#### Diagnosis

- Clinical recognition
- May need biopsy confirmation in rare or unusual cases
- Histology: wedge-shaped perivascular lymphoid infiltrate with eosinophils, endothelial prominence and spongiosis or focal epidermal necrosis



### Differential diagnosis

- Viral exanthems (varicella and others)
- Scabies
- Atopic dermatitis
- Pityriasis lichenoides et varioliformis acuta

### Treatment

- Avoid offending insects
- Veterinarian should inspect household pets for fleas or mites
- Insecticides used in house can kill fleas in carpet or furniture
- Protective clothing with long sleeves and long trousers
- Insect repellents containing DEET 10% or less may be applied to clothing or skin (Caution: can be neurotoxic)
- Pruritic lesions can be individually treated with a topical steroid (low strength to medium) 2–3 times a day
- Oral antihistamines (diphenhydramine, hydroxyzine) may help reduce itching

### Prognosis

- Excellent, once offending agent is removed

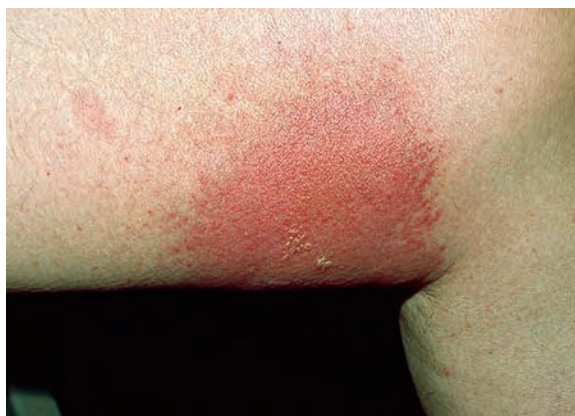### References

- Asada H, Miyagawa S, Sumikawa Y, et al. CD4+ T-lymphocyte-induced Epstein–Barr virus reactivation in a patient with severe hypersensitivity to mosquito bites and Epstein–Barr virus-infected NK cell lymphocytosis. *Arch Dermatol* 2003; 139: 1601–7
- Demain JG. Papular urticaria and things that bite in the night. *Curr Allergy Asthma Rep* 2003; 3: 291–303
- Diven DB, Newton RC, Ramsey KM. Heightened cutaneous reactions to mosquito bites in patients with acquired immunodeficiency syndrome receiving zidovudine. *Arch Intern Med* 1988; 148: 2296
- Goddard J. *Physician's Guide to Arthropods of Medical Importance*, Boca Raton, FL: 4th edn. CRC Press, 2003
- Moffitt JE. Allergic reactions to insect stings and bites. *South Med J* 2003; 96: 1073–9
- Tokura Y, Ishihara S, Tagawa S, et al. Hypersensitivity to mosquito bites as the primary clinical manifestation of a juvenile type of Epstein–Barr virus-associated natural killer cell leukemia/lymphoma. *J Am Acad Dermatol* 2001; 45: 569–78

## Hymenoptera stings

### Major points

- Bee, wasp, or hornet stings followed by local reaction:
  1. Immediate pain and burning followed by intense, local, erythematous reaction with swelling, pruritus and an urticarial plaque (Figure 10.9)
  2. Honeybee leaves stinger in skin which can be gently removed by scraping with a fingernail or blade to prevent further envenomation
  3. Other Hymenoptera (e.g. yellow jackets) may sting repeatedly
- Systemic reactions (1–3% of population):
  1. Angioedema or generalized urticaria within 10 minutes
  2. Laryngeal edema and/or bronchospasm
  3. Rare anaphylaxis, shock and death



**Figure 10.8** Hymenoptera sting – marked erythema and pruritus 2 days after a sting

- Fire ant bites (*Solenopsis*) – intense local inflammatory response followed by superficial pustules; bites/stings are usually multiple

### Pathogenesis

- Hymenoptera order of insects includes bees, wasps, hornets and ants
- Venom contains phospholipase A2 which liberates acute inflammatory mediators
- Other active agents: hyaluronidase, histamine, acid phosphatase, norepinephrine and others



### Diagnosis

- Clinical diagnosis and history

### Differential diagnosis

- Urticaria
- Snake bite
- Lacerations
- Animal bite

### Treatment

- Apply ice or cold compresses
- Systemic reactions may require subcutaneous epinephrine (adrenaline), steroids, antihistamines and treatment of shock if necessary
- In highly sensitive patients, consider desensitization
- Potent or ultrapotent topical steroid for persistent reactions
- Avoidance and pest control

### Prognosis

- Excellent for local reactions.
- Guarded in sensitive patients with severe systemic symptoms

### References

- Cohen PR. Imported fire ant stings: clinical manifestations and treatment. *Pediatr Dermatol* 1992; 9: 44–8
- Ditto AM. Hymenoptera sensitivity: diagnosis and treatment. *Allergy Asthma Proc* 2002; 23: 381–4
- Golden DB. Stinging insect allergy. *Am Fam Physician* 2003; 67: 2541–6

## Caterpillar dermatitis (lepidopterism)

### Major points

- Lepidoptera (order) consists of butterflies and moths
- Incidental contact with insect larvae, especially hairs or spines of caterpillars
- Presents with widespread red macules and urticarial wheals
- Chronic cutaneous lesions: lichen simplex chronicus, post-inflammatory hyperpigmentation
- Other symptoms: inflammation of skin, eyes, respiratory system with dermatitis, conjunctivitis, keratitis, rhinitis, wheezing

- Rare systemic findings: tachycardia, arrhythmia, chest pain, dyspnea, peripheral neuropathy, convulsions, shock
- Treatment of symptoms: antihistamines, antipruritic lotions, mid-potency topical corticosteroids
- Stripping skin with adhesive tape will help remove remaining hairs
- Symptoms last hours to 10 days

### References

- Gardner TL, Elston DM. Painful papulovesicles produced by the puss caterpillar. *Cutis* 1997; 60: 125–6
- Kuspis DA, Rawlins JE, Krenzelok EP. Human exposures to stinging caterpillar: *Lophocampa caryae* exposures. *Am J Emerg Med* 2001; 19: 396–8
- Maier H, Spiegel W, Kinaciyan T, et al. The oak processionary caterpillar as the cause of an epidemic airborne disease: survey and analysis. *Br J Dermatol* 2003; 149: 990–7
- Severs GA, Elston DM. What's eating you? Megalopyge opercularis. *Cutis* 2003; 71: 445–8

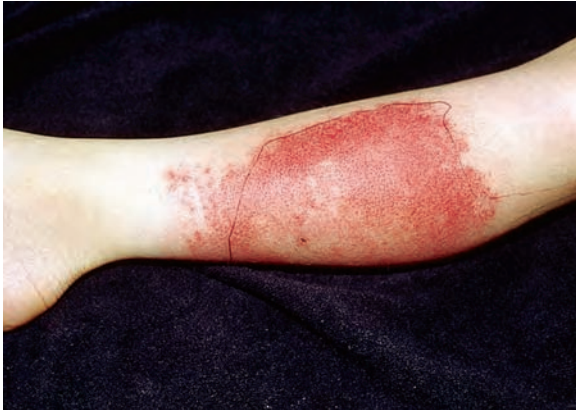## Spider bites

### Major points

- Two spiders in USA which cause most problems: black widow spider (*Lactrodectus mactans*) and brown recluse spider (*Loxosceles reclusa*)
- Initial bites may be either painful (black widow spider) or nonpainful until several hours later (brown recluse spider)
- Hemorrhagic painful blister or skin necrosis follows, which may extend for several days until size reaches its maximum (Figure 10.9)
- Common on exposed skin (e.g. ankles or hands)
- Systemic reactions: vomiting, headache, chills, malaise, thrombocytopenia, hemolysis and hemoglobinuria; probably related to amount of venom injected

### Pathogenesis

- Spiders with powerful jaws which penetrate skin, inject venom and produce a reaction
- *Loxosceles reclusa* found in midwestern USA (particularly Arkansas, Tennessee, Texas and Missouri); mainly in attics, cellars and abandoned buildings



**Figure 10.9** Spider bite – necrosis and pain from *Loxosceles reclusa*

- 1. Size 8–10 mm, brown, with thin legs, and has a distinct violin shape on its dorsal thorax
- *Lactrodactus mactans*
  - 1. Causes acute pain and edema at site of bite; systemic symptoms caused by neurotoxin  $\alpha$ -lactrotoxin
  - 2. Often found in old outhouses and bite exposed buttocks

### Diagnosis

- Identify spider if possible
- Central necrosis and pain may be prominent

### Differential diagnosis

- Vascular infarction
- Vasculitis
- Bacteremia
- Ecthyma gangrenosum
- Streptococcal gangrene
- Herpes zoster
- Cutaneous diphtheria
- Anthrax

### Treatment

- Ice packs directly to site will reduce spread of venom in tissues
- Elevation of area and bed rest advised until necrosis has stopped, usually several days
- Surgical excision not recommended and may spread toxin
- Dapsone may be helpful early
- 25% of bites become infected with *Staphylococcus aureus* – use antibiotics to cover

- Close follow-up until lesion stabilized
- Corticosteroids for systemic symptoms (e.g. hemolysis or thrombocytopenia); best given IV and patient observed for other symptoms for ~3 days
- Recognition of spider and its habitat is important in avoiding these bites. In endemic areas, shake out clothes before getting dressed and shake bed clothes before retiring
- Antivenin if available if reaction severe

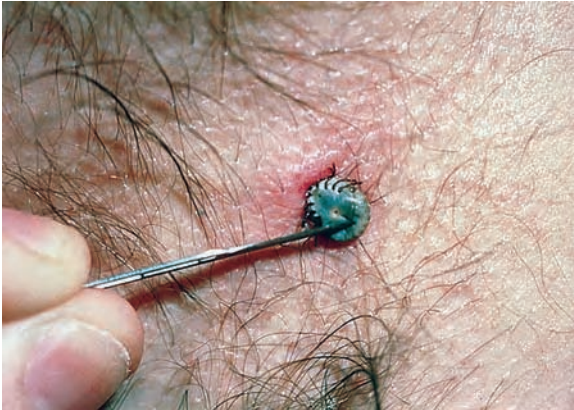### References

- Elston DM. What's eating you? *Loxosceles reclusa* (brown recluse spider). *Cutis* 2002; 69: 91–2, 94–5
- Isbister GK, Graudins A, White J, Warrell D. Antivenom treatment in arachnidism. *J Toxicol Clin Toxicol* 2003; 41: 291–300
- Orion E, Matz H, Ruocco V, Wolf R. Parasitic skin infestations II, scabies, pediculosis, spider bites: unapproved treatments. *Clin Dermatol* 2002; 20: 618–25
- Sams HH, Dunnick CA, Smith ML, King LE. Necrotic arachnidism. *J Am Acad Dermatol* 2001; 44: 561–73
- Sams HH, Hearth SB, Long LL, et al. Nineteen documented cases of *Loxosceles reclusa* envenomation. *J Am Acad Dermatol* 2001; 44: 603–8
- Wendell RP. Brown recluse spiders: a review to help guide physicians in nonendemic areas. *South Med J* 2003; 96: 486–90
- Williams ST, Khare VK, Johnston GA. Severe intravascular hemolysis associated with brown recluse spider envenomation. *Am J Clin Pathol* 1995; 104: 463–7

### Tick bites

#### Major points

- Usually painless, and often noticed when engorged tick is found (Figure 10.10)
- Local urticaria, pruritus, or erythema can occur several days after the bite (Figure 10.11)
- Common locations: scalp, axilla and groin
- Persistent pruritic papule may occur from retained tick mouthparts forming a granulomatous reaction
- *Borrelia burgdorferi*, which causes Lyme disease, can be carried by ticks. Observation of an expanding ring of erythema (erythema chronicum migrans) at the site of tick attachment is seen within 3 weeks after the bite (See Chapter 8)

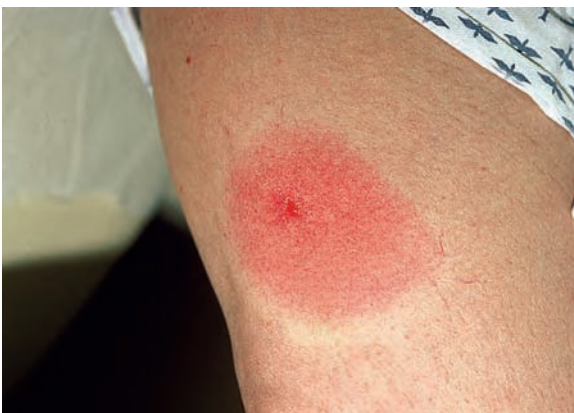

**Figure 10.10** Tick embedded in skin, thought to be a 'changing mole'

- Rare reaction: tick paralysis with fever, nausea, abdominal cramping, headache and ascending symmetric paralysis similar to Guillain-Barré syndrome

#### Pathogenesis

- Major species
  1. *Dermacentor variabilis* (American dog tick); carrier of Rocky Mountain spotted fever
  2. *Amblyomma americanum* (Lone Star tick) in Southern USA; carrier of Rocky Mountain spotted fever and Ehrlichia
  3. *Ixodes dammini* (deer tick) in Eastern USA; carrier of *Borrelia burgdorferi* (Lyme disease)
  4. *Ixodes ricinus* in Europe; carrier of *Borrelia* (erythema chronicum migrans)



**Figure 10.11** Tick bite with erythematous patch

- Ticks occur in wooded areas primarily in warmer months; also occur from handling dogs or clothing
- Larval and nymphal stages attach their heads into skin for blood meal, and become engorged
- Ticks cut skin surface with sharp chelicerae, introducing the proboscis, and secreting saliva into wound. Saliva contains an anticoagulant, an anesthetic and a cement substance, as well as possible *Borrelia*. As tick engorges, *Borrelia* proliferate in the tick gut and enters patient's blood after 24–48 hours

#### Diagnosis

- Careful clinical inspection and history
- Nymphal stages are small and may be overlooked (size 1–2 mm, 'seed ticks')

#### Differential diagnosis

- Nevocellular nevus
- Skin tag
- Pyogenic granuloma

#### Treatment

- Remove tick:
  1. Grasp the body of tick as close to the mouthparts as possible
  2. Apply slow, gentle, firm, outward pressure until the tick releases its mouthparts
  3. Not recommended: burning tick with a match, applying noxious substances to skin, squeezing, twisting or jerking the tick
- Cleanse skin with alcohol and apply topical antibiotic ointment
- Dispose of the tick by putting it in a jar of alcohol for a few minutes, then flush down the toilet
- Keep the tick for examination later; may be helpful in endemic Lyme disease areas
- Prevention is important
  1. Avoid tick-infested areas, especially tall grass and dense brush
  2. Wear long sleeves, and long trousers tucked into boots
  3. Wear insect repellents containing DEET
  4. Inspect children and dogs after exposure

#### References

Eppes SC. Diagnosis, treatment, and prevention of Lyme disease in children. *Paediatr Drugs* 2003; 5: 363–72

McGinley-Smith DE, Tsao SS. Dermatoses from ticks. *J Am Acad Dermatol* 2003; 49: 363–92

Meinking T, Taplin D. Infestations. In *Pediatric Dermatology*, 3rd edn. Schachner L, Hansen R. eds. Mosby: New York, 2003: 1141–80

Spach DH, Liles WC, Campbell GL, et al. Tick-borne diseases in the United States. *N Engl J Med* 1993; 329: 936–47

Stanek G, Strle F. Lyme borreliosis. *Lancet* 2003; 362: 1639–47

Wilson ME. Prevention of tick-borne diseases. *Med Clin North Am* 2002; 86 :219–38

## Cutaneous larva migrans

Synonym: creeping eruption

### Major points

- Within a few hours, there is pruritic dermatitis at the site of exposure
- Serpiginous, linear, erythematous, slightly raised, pruritic tracts 2–3 mm wide with bizarre patterns (Figure 10.12)
- Vesicles, pain or edema in area
- Feet most frequently affected
- Peripheral eosinophilia (can be up to 35% of cells)

### Pathogenesis

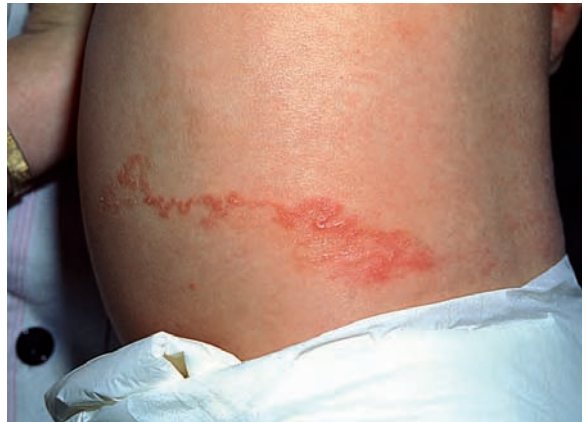- Caused by *Ancylostoma braziliensis* or *A. caninum*, the dog and cat hookworm (most common in southeastern North America)
  1. History of playing along southeastern or central shoreline of USA or in sandbox where cat or dog excreta may have been deposited
  2. Larvae hatch and penetrate bare skin where they migrate and die within 4–6 weeks
  3. Larvae can migrate 1–2 cm/day
- Other organisms less commonly causing larva migrans: *Bunostomum phlebotomum* (cattle hookworm), *A. duodenale*, and *Necator americanus*

### Diagnosis

- Characteristic history and inspection: linear, serpiginous, pruritic lesions

### Differential diagnosis

- Annular erythema
- Erythema chronicum migrans
- Tinea corporis



**Figure 10.12** Cutaneous larva migrans – typical erythematous, serpiginous, linear streak

- Tinea pedis
- Nummular eczema
- Visceral larva migrans

### Treatment

- For *A. braziliensis*, topical thiabendazole 15% cream applied 3–4 times/day for 5–7 days; apply cream beyond erythematous lesions
- Freeze advancing burrow with liquid nitrogen
- Return visit 4–5 days after starting treatment to determine therapeutic response
- Ivermectin 12 mg PO, single dose 0.2 mg/kg (off label)
- High potency topical steroids for itching

### Prognosis

- Lesions are self-limited because humans are ‘dead-end’ hosts
- Duration is variable, usually lasting 4–6 weeks

### References

- Albanese G, Venturi C, Galvati G. Treatment of larva migrans cutanea (creeping eruption): a comparison between albendazole and traditional therapy. *Int J Dermatol* 2001; 40: 67–71
- Brenner MA, Patel MB. Cutaneous larva migrans: the creeping eruption. *Cutis* 2003; 72: 111–15
- Caumes E, Datry A, Paris L, et al. Efficacy of ivermectin in the therapy of cutaneous larva migrans. *Arch Dermatol* 1992; 128: 994–5
- Caumes E. Treatment of cutaneous larva migrans. *Clin Infect Dis* 2000; 30: 811–14



Davies HD, Sakuls P, Keystone JS. Creeping eruption. *Arch Dermatol* 1993; 129: 588–91

Elgart ML. Creeping eruption. *Arch Dermatol* 1998; 134: 619–20

Van den Enden E, Stevens A, Van Gompel A. Treatment of cutaneous larva migrans. *N Engl J Med* 1998; 339: 1246–7

## Animal bites

### Major points

- Dog and cat bites (pets) are most common
- Victim usually a child who is teasing or playing with the animal
- Location usually the hand
- Human bites and monkey bites are often infected with aerobic or anaerobic mouth organisms
- Wild animals such as skunks, bats, foxes, coyotes, raccoons, other carnivores and some monkeys should be considered rabid until proven otherwise

### Pathogenesis

- Most common organism causing secondary infection is *Pasteurella multocida*

### Diagnosis

- History of a bite and clinical appearance

### Differential diagnosis

- Other bites or stings

### Treatment

- Culture wound for bacteria, then wash and leave open if possible (except face)
- Antibiotics should be given: amoxicillin–clavulanic acid, cefuroxime or clindamycin and a fluoroquinolone
- Tetanus immunization if needed
- Rabies immunization considered if needed

### Prognosis

- Excellent unless lesions are large or multiple
- Scarring is possible
- Secondary infection

### References

Gandhi RR, Liebman MA, Stafford BL, et al. Dog bite injuries in children: a preliminary survey. *Am Surg* 1999; 65: 863–4

Jones N, Khoosal M. Infected dog and cat bites. *N Engl J Med* 1999; 340: 1841–2

Overall KL, Love M. Dog bites to humans – demography, epidemiology, injury, and risk. *J Am Vet Med Assoc* 2001; 218: 1923–34

Presutti RJ. Prevention and treatment of dog bites. *Am Fam Physician*. 2001; 63: 1567–72

Weiss HB, Friedman DI, Coben JH. Incidence of dog bite injuries treated in emergency departments. *J Am Med Assoc* 1998; 279: 51–3

## Snake bites

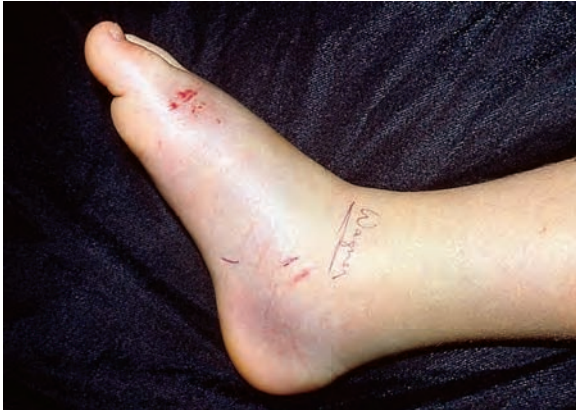### Major points

- Snakes
  1. Family Viperidae
    - a. Crotalinae (pit vipers). North America: rattlesnake, cottonmouth, copperhead
    - b. Viperinae (true vipers). Africa, Europe, other continents: vipers, adders
  2. Elapidae
    - a. Tropical and warm temperate zones: coral snakes, cobras, mambas
  3. Hydrophidae
    - a. Hydrophinae. Indopacific region: sea snakes
- 7000 bites recorded annually in USA, 2000 by venomous snakes
- Degree of toxicity depends upon potency of the venom, amount injected, size of person bitten, and size of snake
- Pain occurs immediately after bite followed by edema, numbness, ecchymosis and painful lymphadenopathy within 30 minutes
- Typical victims are males, aged 17–27 years
- Most bites are on extremities, between April and September
- Skin will have distinct fang punctures
- Immediate pain occurs, followed by edema, numbness, ecchymosis and painful lymphadenopathy within 30 minutes (Figure 10.13)
- Systemic symptoms (must be differentiated from terror): nausea, vomiting, sweating, fever, slurred speech, bleeding

### Pathogenesis

- Pit-viper venom increases permeability of capillary membranes, causing edema, hypotension, hemolysis and other symptoms





**Figure 10.13** Snake bite from copperhead showing marked swelling, necrosis and pain

- Venoms are mixtures of potent proteolytic enzymes and low molecular-weight peptides with toxic effects

### Diagnosis

- Clinical diagnosis with history

### Differential diagnosis

- Other venomous animal or insect bites

### Treatment

- Call regional Poison Control Center (National hotline: 800-222-1222)
  1. Identify species
  2. Aggressive supportive care, laboratory evaluation, and observation for at least 8–12 hours
  3. Antivenom if available and indicated
  4. Polyvalent pit viper antivenin should be used for severe snake bites (except the coral snake) as soon as possible
- Clean and cover the wound; baseline circumferential measurements of necrosis
- Limb should be immobilized in a functional position
- Tetanus toxoid
- Antibiotic coverage, if indicated
- Hospitalization with careful observation for dropping blood count and hemolysis
- Surgical debridement may need to be performed 3–10 days after the bite

### Prognosis

- Severity depends upon size and species of snake, amount and degree of toxicity of venom, location,

first-aid treatments provided, timing of definitive treatment and state of health of the victim

- Common necrosis of skin with scar formation
- Rarely fatal

### References

- Dart RC, McNally J. Efficacy, safety, and use of snake antivenoms in the United States. *Ann Emerg Med* 2001; 37: 181–8
- Gold BS, Dart RC, Barish RA. Bites of venomous snakes. *N Engl J Med* 2002; 347: 347–56
- Hall EL. Role of surgical intervention in the management of crotaline snake envenomation. *Ann Emerg Med* 2001; 37: 175–80
- Juckett G, Hancox JG. Venomous snakebites in the United States: management review and update. *Am Fam Physician* 2002; 65: 1367–74
- Lalloo DG, Theakston RD. Snake antivenoms. *J Toxicol Clin Toxicol* 2003; 41: 277–90; 317–27
- Rosen PB, Leiva JI, Ross CP. Delayed antivenom treatment for a patient after envenomation by *Crotalus atrox*. *Ann Emerg Med* 2000; 35: 86–8

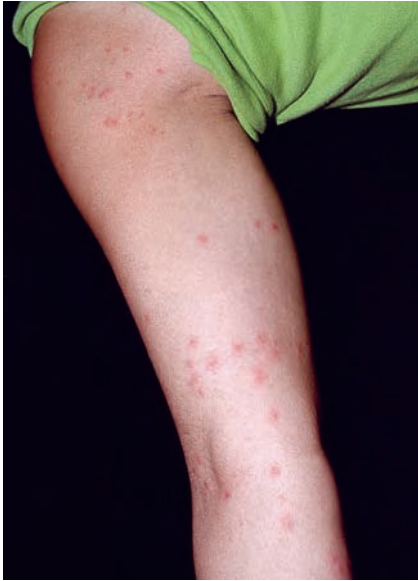## Cercarial dermatitis (swimmer's itch)

### Major points

- Clinical characteristics
  1. Begins with urticarial lesions (usually 10–30 but can be >200) and prickling sensation starting half an hour after exposure to infected water (Figure 10.14)
  2. Within 24 hours, pruritic erythematous papules occur in exposed areas not covered by a swimsuit
  3. Headache, fever and superinfection occasionally seen
- Occurs in freshwater lakes of upper Great Lakes region of North America and throughout the world

### Pathogenesis

- Caused by *Schistosoma cercariae* (larval form of schistosomes)
- Humans are accidental hosts in life cycle of schistosomes
- Primary hosts (waterfowl, birds, mice, deer, etc.) deposit eggs in excreta in water
- Eggs hatch forming miracidia which infect snails, where they transform into cercariae



**Figure 10.14** Cercarial dermatitis (swimmer's itch)

- In host, cercariae attach to skin and penetrate into dermis and blood vessels, passing to the gastrointestinal tract; eggs are discharged into feces, completing the life cycle
- In humans, cercariae do not penetrate the blood vessels, but die in the superficial papillary dermis
- Cercarial proteins stimulate delayed-type hypersensitivity response manifest as an erythematous rash and itching

#### Diagnosis

- Typical distribution after history of swimming in fresh water

#### Differential diagnosis

- Seabather's eruption
- Insect bites
- Impetigo
- Varicella
- Insect bites
- Contact dermatitis
- Scabies
- Jellyfish stings

#### Treatment

- Topical steroid creams (low or mid-strength), drying lotions, oatmeal baths and oral antihistamines may help pruritus

- Severe eruption can be treated with oral prednisone 1 mg/kg per day for 5 days
- Treat secondary infection if present
- Not contagious
- Prevention is difficult. Barrier clothing or application of petrolatum prior to swimming may be of some benefit

#### Prognosis

- Lesions are self-limited

#### References

- Folster-Holst R, Disko R, Rowert J, et al. Cercarial dermatitis contracted via contact with an aquarium: case report and review. *Br J Dermatol* 2001; 145: 638–40
- Gonzales E. Schistosomiasis, cercarial dermatitis, and marine dermatitis. *Dermatol Clin* 1989; 7: 291–300
- Sanguenza OP, Lu D, Sanguenza M, Pereira CP. Protozoa and worms. In *Dermatology*. Bologna JL, Jorizzo JL, Rapini R, eds. Mosby: London, 2003: 1295–320

### Seabather's eruption

Synonym: marine dermatitis

#### Major points

- Clinical characteristics
  1. Erythematous macules, papules or wheals that itch or burn
  2. May progress to vesiculopapules and heal with crusts in 7–10 days
  3. Occurs under covered areas (e.g. swimsuit, bathing cap, wet suit areas), beginning shortly after bathing in seawater
  4. Symptoms usually noticed after exiting water
  5. Systemic symptoms (e.g. fatigue, malaise, fever, lymphadenopathy)

#### Pathogenesis

- Caused by stinging larvae of sea anemones, Portuguese man-of-war, or thimble jellyfish; type determined by geographical location

#### Diagnosis

- Clinical lesions in typical bathing suit distribution after salt water swimming

#### Differential diagnosis

- Atopic dermatitis
- Jellyfish stings

- Swimmer's itch
- Insect bites
- Contact dermatitis
- Caterpillar dermatitis
- Varicella
- Viral eruptions
- Urticaria

### *Treatment*

- Wash and dry skin immediately after bathing
- Symptomatic relief with topical steroids, antipruritic lotions, or oral antihistamines
- Oral prednisone 1 mg/kg per day if symptoms are severe
- Avoid occluding clothes, such as T-shirts, wet suits

### *Prognosis*

- Self-limited eruption; resolves in 2 weeks

### *References*

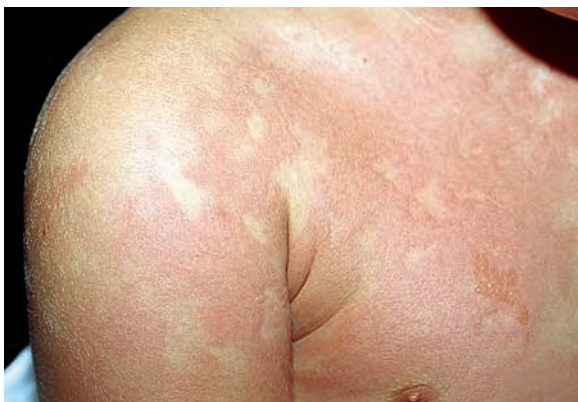- Adams BB. Dermatologic disorders of the athlete. *Sports Med* 2002; 32: 309–21
- Freudenthal AR, Joseph PR. Seabather's eruption. *N Engl J Med* 1993; 329: 542–4
- Segura Puertas L, Burnett JW, Heimer de la Coteria E. The medusa stage of the coronate scyphomedusa *Linuche unguiculata* ('thimble jellyfish') can cause seabather's eruption. *Dermatology* 1999; 198: 171–2
- Tomchik RS, Russell MT, Szmant AM, Black NA. Clinical perspectives on seabather's eruption, also known as 'sea lice'. *J Am Med Assoc* 1993; 269: 1669–72
- Wong DE, Meinking TL, Rosen LB, et al. Seabather's eruption. *J Am Acad Dermatol* 1994; 30: 399–406

## HYPERSENSITIVITY DISORDERS/ UNCLASSIFIED DISORDERS

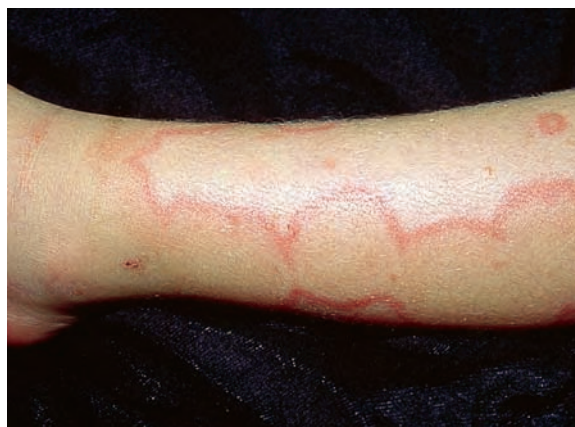### Urticaria

#### *Major points*

- 15–20% of children will have at least one episode by adolescence
- Classified as acute if it lasts for <6 weeks, chronic if >6 weeks
- Usually acute (not chronic) in children
- Etiologic factor can often be identified in children
- Frequent association with atopy
- Presents with circumscribed, slightly elevated, erythematous, edematous plaques that persist for minutes to hours; typical wheal and flare; usually pruritic; often presents at points of pressure (e.g. belt-line, palms, soles); individual lesions rarely last for more than 24–48 hours, but new lesions often arise as older ones clear (Figures 11.1 and 11.2)
- Food-related urticaria often has associated itching and swelling of the lips, mucous membranes,



**Figure 11.1** Urticaria – generalized pruritic wheals



**Figure 11.2** Urticaria – annular plaques which have become confluent. These lesions were gone the next day

palate and tongue with gastrointestinal (GI) symptoms (e.g. diarrhea)

- Papular urticaria occurs on the lower extremities of children as a result of insect bites
- Dermatographism – sharply demarcated wheal and erythematous flare occurring within seconds of stroking the skin
- Giant urticaria – large lesions of 6–10 cm in diameter
- Anaphylaxis – life-threatening medical emergency characterized by the sudden onset of urticaria, angioedema, dyspnea and hypotension
- Angioedema – deep edema of the subcutaneous tissue manifesting as diffuse swelling; often affects the hands, feet, eyelids and lips
  1. Mild angioedema accompanies ordinary urticaria in 10% of infants and children

2. Occurs more severely in:
  - a. Anaphylaxis
  - b. Serum sickness
  - c. Hereditary angioedema – autosomal dominant deficiency in C1 esterase inhibitor

### *Pathogenesis*

- Results from dilatation of capillaries, arterioles and venules with increased permeability
- Mediators: histamine released from circulating mast cells and basophils, anaphylotoxins, kinins, arachadonic acid metabolites, acetylcholine (cholinergic urticaria)
- Mechanism/etiologic factors:
  1. Immunologic factors: type I IgE-mediated hypersensitivity reaction; type II hypersensitivity reaction; type III hypersensitivity reaction (serum sickness); activation of alternate complement pathway
  2. Nonimmunologic factors: cholinergic effects, direct effect of physical agents, drugs
  3. Modulating factors: alcohol, heat, fever, exercise and emotional stress, endocrine factors
  4. Genetic factors: may play a role in chronic urticaria
  5. Infections: association with streptococcal pharyngitis, otitis media, sinusitis, upper respiratory infection, mononucleosis, hepatitis, coxsackie infections, mycoplasma infections, parasitic infections, fungal infections
  6. Drugs:
    - a. Allergic reaction: penicillins, others
    - b. Histamine liberators (even in normal individuals): codeine, morphine, cocaine, meperidine, quinine, thiamine, pilocarpine, polymyxin, dextran, D-tubocurarine
  7. Foods/additives: cow's milk allergy (infants), eggs, nuts, shellfish and other sea foods, chocolate, strawberries, grains
  8. Insect bites and stings: fleas, bed bugs, mites, bees, fire ants
  9. Acute contact urticaria: nettles, cat scratch, animal saliva, sea lice, moth or butterfly scales
  10. Physical agents or pressure
  11. Localized heat or cold
  12. Sun exposure (solar urticaria)
  13. Exposure to water (aquagenic urticaria)

### *Diagnosis*

- Complete history and physical examination looking for infection, drug history, travel, environmental history, pet exposure, food history
- Test for dermatographism
- Other tests as indicated: ice cube test (cold urticaria), exercise test or methacholine test (cholinergic urticaria), pressure test (pressure urticaria), tepid towel test (aquagenic urticaria)
- Laboratory studies as indicated: streptococcal throat culture, complete blood count (CBC), streptozyme, erythrocyte sedimentation rate (ESR), urinalysis, complement levels, transaminases (AST and ALT), mycoplasma titers, sinus films, chest X-ray, urine culture, stool for ova and parasites, C1 esterase inhibitor level (if angioedema is present)

### *Differential diagnosis*

- Erythema multiforme
- Systemic lupus erythematosus
- Dermatomyositis
- Porphyria
- Dermatitis herpetiformis
- Bullous pemphigoid
- Vasculitis
- Guttate psoriasis
- Pityriasis rosea

### *Treatment*

- H1-type oral antihistamines
  1. Over-the-counter oral medications such as chlorpheniramine and diphenhydramine (Benadryl) are often adequate
  2. Prescription medications: hydroxyzine (Atarax®) or azatadine
  3. Continue treatment for at least 1 week after resolution of hives
- Identification and removal of etiologic agent if possible (e.g. food, drug) or treat infection
- Reassurance
- For anaphylaxis: epinephrine and airway/cardiovascular support; wear Medical Alert bracelet

### *Prognosis*

- Acute urticaria – excellent prognosis in the absence of serious disease



- 20–30% of cases of acute urticaria will evolve into chronic or recurrent disease
- Chronic urticaria – prognosis for early resolution better than in adults
  1. Urticaria only: average duration 6 months
  2. Angioedema only: average duration 1 year
  3. Urticaria with angioedema: average duration 5 years
  4. Cholinergic urticaria: average duration 7 years
  5. Dermatographism: average duration 2 years

### References

- Beattie PE, Dawe RS, Ibbotson SH, Ferguson J. Characteristics and prognosis of idiopathic solar urticaria. *Arch Dermatol* 2003;139:1149–54
- Greaves MW. Chronic idiopathic urticaria. *Cur Opin Allergy Clin Immunol* 2003; 3: 363–8
- Kozel MMA, Bossuyt PMM, Mekkes JR, Bos JD. Laboratory tests and identified diagnoses in patients with physical and chronic urticaria and angioedema: a systematic review. *J Am Acad Dermatol* 2003; 48: 409–16
- Mortureux P, Leaute-Labreze C, Legrain-Lifermann V, et al. Acute urticaria in infancy and early childhood. *Arch Dermatol* 1998; 134: 319–23
- Muller BA. Urticaria and angioedema: a practical approach. *Am Fam Physician* 2004; 69: 1123–8
- Poon M, Reid C. Do steroids help children with acute urticaria? *Arch Dis Child* 2004; 89: 85–6
- Sackesen C, Sekerel BE, Orhan F, et al. The etiology of different forms of urticaria in childhood. *Pediatr Dermatol* 2004; 21: 102–108
- Zembowicz A, Mastalerz L, Setkowicz M, et al. Safety of cyclooxygenase 2 inhibitors and increased leukotriene synthesis in chronic idiopathic urticaria with sensitivity to nonsteroidal anti-inflammatory drugs. *Arch Dermatol* 2003; 139: 1577–82

## Erythema multiforme

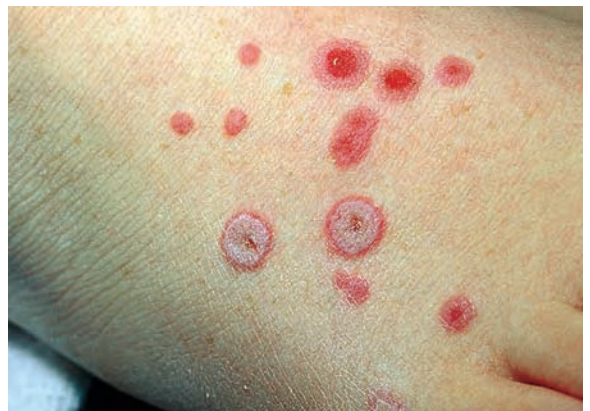Synonym: erythema multiforme minor

### Major points

- Acute, self-limited cutaneous disease
- Herpes simplex virus (HSV 1 or 2) is the major precipitating factor
- Most common in young adults, rare in younger children
- Clinical features:
  1. Rare prodrome, mild if present, with low-grade fever, cough, decreased appetite
  2. Fixed red papules which develop into target/iris lesions
  3. Target or iris lesions – regular circular macule or plaque that enlarges centrifugally, forming three zones of color change, and may coalesce with other lesions; central zone appears as dusky erythematous macule with bulla and/or crust (indicating epidermal damage) surrounded by lighter area and a purplish red external ring (Figure 11.3)
  4. Vesicles and bullae
  5. Symmetrically distributed in acral distribution on extensor surfaces of extremities and face
  6. Mucous membrane involvement can be mild or absent, or may have painful oral erosions
  7. Predilection for sun-exposed skin
  8. May exhibit Koebner phenomenon
  9. Frequently recurrent
  10. May or may not have a history of preceding HSV 1 or HSV 2 infection (~50%)
  11. Itching and/or burning sensation may occur

### Pathogenesis

- Presumed to be a delayed hypersensitivity reaction with cytotoxic attack on keratinocytes bearing foreign (e.g. viral) antigens
- HSV has been the most prevalent precipitating factor identified in erythema multiforme minor; can be detected by polymerase chain reaction (PCR) of skin



**Figure 11.3** Erythema multiforme – target lesions with bullous component

- Other etiologic factors: drugs, *Histoplasma* infection and orf
- Histology: interface dermatitis with exocytosis, apoptotic keratinocytes and a perivascular mononuclear cell infiltrate

### Diagnosis

- Characteristic clinical findings
- Skin biopsy if diagnosis is in doubt
- No laboratory studies usually necessary

### Differential diagnosis

- Giant urticaria
- Drug reaction
- Polymorphous light eruption
- Bullous pemphigoid
- Vasculitis
- Systemic lupus erythematosus

### Treatment

- Symptomatic treatment:
  1. Oral antihistamines for itching/burning
  2. Oral antacids for oral ulcers, for soothing effect
- Topical antibiotics to prevent secondary infection
- Preventative treatment: prophylactic oral acyclovir can prevent recurrences, use for 6–12 months
- Intermittent acyclovir ineffective unless used early during outbreak
- Systemic steroids if given early for recurrences

### Prognosis

- Lesions fade over 1–3 weeks without specific treatment
- Usually lesions heal without sequelae, but may have mild scarring or hypopigmentation
- HSV-associated erythema multiforme commonly recurs
- Patients on immunosuppressive drugs tend to have more frequent and longer recurrences

### References

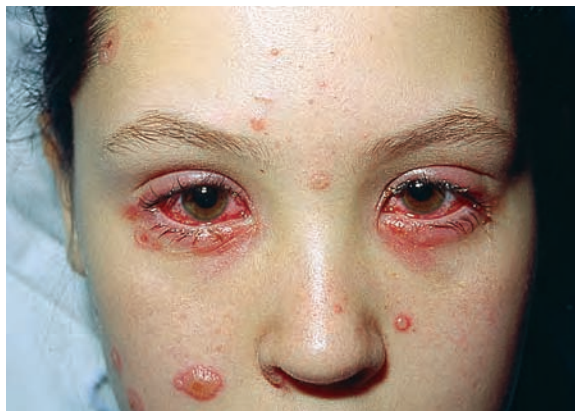- Ayangco L, Rogers RS. Oral manifestations of erythema multiforme. *Dermatol Clin* 2003; 21: 195–205
- Weston WL. Erythema multiforme and Stevens–Johnson syndrome. In *Dermatology*. Bologna JL, Jorizzo JL, Rapini RP, et al., eds. Mosby: London, 2003: 313–21
- Weston WL, Brice SL, Jester JD, et al. Herpes simplex virus in childhood erythema multiforme. *Pediatrics* 1992; 89: 32–4

Weston WL, Morelli JG. Herpes simplex virus-associated erythema multiforme in prepubertal children. *Arch Pediatr Adolesc Med* 1997; 151: 1014–16

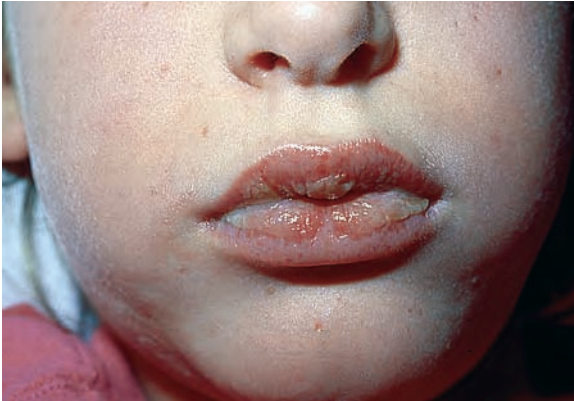## Stevens–Johnson syndrome/toxic epidermal necrolysis

### Major points

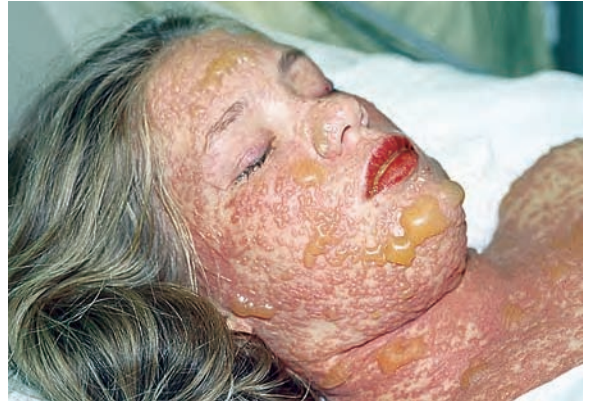- Stevens–Johnson syndrome (SJS) and toxic epidermal necrolysis (TEN) are on a spectrum and have considerable overlap (see Chapter 13)
- Severe cutaneous reaction in which the individual appears acutely ill
- Rare in infants and children compared to teens and adults
- Combined incidence of SJS and TEN is approximately 1.5–2 cases per million per year in the general population
- Stevens–Johnson syndrome (erythema multiforme major):
  1. Drugs are the major precipitating factor
  2. *Mycoplasma pneumoniae* infection associated in children and teens
  3. Clinical features:
    - a. 1–14 day prodrome of high fever, sore throat, malaise
    - b. Rapid onset of cutaneous blistering with epidermal detachment beginning with target lesions (Figures 11.4–11.6)



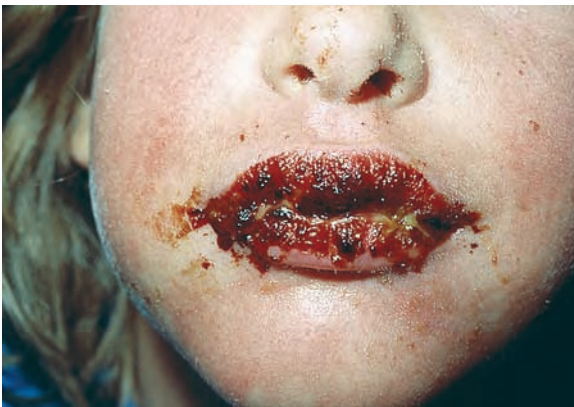**Figure 11.4** Stevens–Johnson syndrome – marked eye involvement



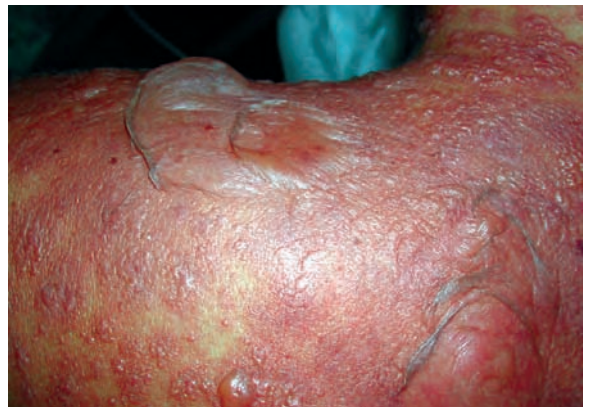**Figure 11.5** Stevens-Johnson syndrome – early erythema and tenderness of the lips



**Figure 11.7** Toxic epidermal necrolysis – diffuse blistering over 90% of the skin surface



**Figure 11.6** Stevens-Johnson syndrome – same patient as Figure 11.5 5 days later showing intense erythema and bleeding on the lips



**Figure 11.8** Toxic epidermal necrolysis – positive Nikolsky sign

- c. Involvement of two or more mucosal sites
- d. Fever, lymphadenopathy, toxic symptoms
- e. Total body surface area of epidermal detachment  $\leq 10\%$  classified as SJS; 10–30% classified as SJS–TEN overlap;  $>30\%$  as TEN
- Toxic epidermal necrolysis:
  1. Drugs are the cause in  $>95\%$  of cases
  2. Clinical features:
    - a. 1–3 day prodrome of fever, stinging eyes, cutaneous tenderness
    - b. Rapid onset of blistering with epidermal detachment (Figures 11.7 and 11.8)
    - c. Positive Nikolsky sign
    - d. Total body surface area of epidermal detachment  $>30\%$

### Pathogenesis

- Same factors precipitate SJS and TEN:
  1. Drugs:
    - a. Antibiotics: penicillin, doxycycline, tetracycline
    - b. Anticonvulsants: carbamazepine, phenytoin, phenobarbital, lamotrigine, valproic acid
    - c. Sulfonamides
    - d. Nonsteroidal anti-inflammatory drugs (NSAIDs): ibuprofen, naproxen
  2. Specific cause identified in only 50% of cases
- Immune-mediated: drug activates CD95 (fas) ligand which binds to an apoptotic receptor located on the keratinocyte cell surface
- Histology:



1. Extensive epidermal damage with keratinocyte necrosis, basal cell layer vacuolation and blister formation at the dermal–epidermal junction
2. Dermal edema
3. Perivascular infiltrates

### Diagnosis

- Characteristic clinical findings and course
- Skin biopsy

### Differential diagnosis

- Staphylococcal scalded skin syndrome
- Kawasaki disease
- Toxic shock syndrome
- Serum sickness-like drug eruption

### Treatment

- Severe cases best treated in an intensive care unit, preferably a burn unit
- Supportive measures:
  1. Removal of offending drug and any cross-reacting drug
  2. Fluid and electrolyte balance
  3. Nutritional support
  4. Prevention of complications (e.g. cultures and antibiotics for infection only when indicated)
  5. Physical therapy to prevent contractures
- Management of skin wounds:
  1. Topical antibiotic therapy e.g. 1% silver sulfadiazine (Silvadene®) twice daily (unless sensitive to sulfa)
  2. Debridement is indicated for extensive disease but may not be necessary for localized disease
  3. Hydrotherapy in a tank, bathtub, or shower to aid debridement
  4. Pre-medication with pain medicines
  5. Consider biological dressings
- Systemic treatments:
  1. Intravenous immunoglobulin (IVIG) 0.5–2 g/kg administered over 3 days
  2. Corticosteroids are controversial
    - a. If used, should be early and high dose short duration (<5 days)
    - b. Some evidence suggests IV pulsed methylprednisolone is preferable
    - c. May cause increased septic complications

### Prognosis

- High morbidity and mortality rates

- Mortality ~30% in SJS and 25–70% in TEN
- Poor prognostic factors in TEN: neutropenia, large percentage of body surface skin loss
- Disease has a protracted course lasting from 15 days to months
- Recovery is long and may require home physical therapy, tutoring and psychological support
- Sequelae: scarring, contractures, ocular sequelae (eyelid immobility, corneal scarring, blindness), esophageal and anal strictures, vaginal stenosis, urethral meatal stenosis, hair and nail loss
- Recurrences rare; most caused by re-exposure to same offending medication

### References

- Bachot N, Roujeau JC. Differential diagnosis of severe cutaneous drug eruptions. *Am J Clin Dermatol* 2003; 4: 561–72
- Bachot N, Roujeau JC. Intravenous immunoglobulins in the treatment of severe drug eruptions. *Curr Opin Allergy Clin Immunol* 2003; 3: 269–74
- Bannasch H, Kontny U, Kruger M, et al. A semisynthetic bilaminar skin substitute used to treat pediatric full-body toxic epidermal necrolysis. *Arch Dermatol* 2004; 140: 160–2
- Hebert AA, Bogle MA. Intravenous immunoglobulin prophylaxis for recurrent Stevens–Johnson syndrome. *J Am Acad Dermatol* 2004; 50: 286–8
- Martinez AE, Atherton DJ. High-dose systemic corticosteroids can arrest recurrences of severe mucocutaneous erythema multiforme. *Pediatr Dermatol* 2000; 17: 87–90
- Metry DW, Jung P, Levy ML. Use of intravenous immunoglobulin in children with Stevens–Johnson syndrome and toxic epidermal necrolysis: seven cases and review of the literature. *Pediatrics* 2003; 112: 1430–6
- Prendiville J. Stevens–Johnson syndrome and toxic epidermal necrolysis. *Adv Dermatol* 2002; 18: 151–73
- Ringheanu M, Laude TA. Toxic epidermal necrolysis in children—an update. *Clin Pediatr* 2000; 39: 687–94

## Erythema nodosum

### Major points

- Uncommon skin disorder
- Prevalence of 2.4 per 10 000 in adults; rarer in children
- Sex ratio in children before puberty is roughly equal (in contrast to the female predominance in adults)

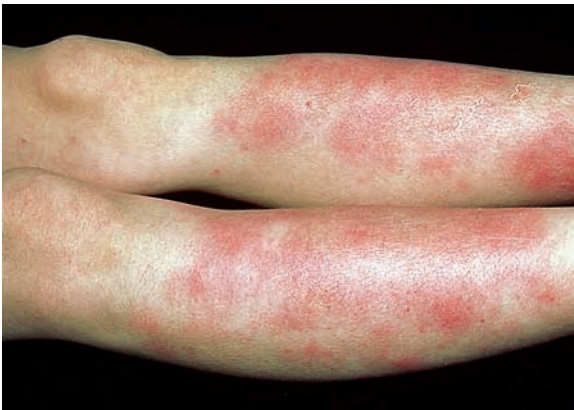- Often associated with infection:
  1. Beta-hemolytic streptococcus (especially pharyngitis)
  2. Other causes: *Yersinia*, *Mycoplasma pneumoniae*, tuberculosis
- Less commonly associated chronic diseases: inflammatory bowel disease, Hodgkin disease, sarcoidosis
- Clinical presentation:
  1. Tender, erythematous or bruise-like nodules or plaques with irregular and indistinct borders (Figure 11.9)
  2. No ulceration or suppuration
  3. Usually located bilaterally on the anterior and lateral legs
  4. Other body sites: upper limbs, trunk, face, plantar surfaces in children
  5. Upper respiratory symptoms/fever/arthritis related to etiologic agent (i.e. infection)
  6. Clinical course is <6 weeks
  7. Resolves without scarring

#### Pathogenesis

- Autoimmune or hypersensitivity disease
- Etiologic factors: infections, chronic diseases, idiopathic
- Histology: septal panniculitis

#### Diagnosis

- Characteristic clinical findings usually sufficient for diagnosis
- Skin biopsy in atypical, protracted cases



**Figure 11.9** Erythema nodosum – tender plaques on the anterior shins caused by streptococcal disease

- Laboratory studies: CBC, ESR, liver enzymes, throat swab, stool culture, CXR, anti-streptolysin titer, *Yersinia* serologic test

#### Differential diagnosis

- Nodular vasculitis (Bazin disease) from tuberculosis
- Henoch–Schönlein purpura
- Eosinophilic cellulitis
- Infectious cellulitis
- Other panniculitides
- Child abuse
- Trauma

#### Treatment

- Bed rest and restriction of physical activities for ~2 weeks
- Analgesic medications or nonsteroidal anti-inflammatory drugs (NSAIDs)
- Treatment of underlying condition

#### Prognosis

- Course is benign and self-limited
- Lesions last ~10–14 days and resolve without scarring
- Recurrences are rare

#### References

- Boh EE, al-Smadi RM. Cutaneous manifestations of gastrointestinal diseases. *Dermatol Clin* 2002; 20: 533–46
- Crawford GH, Kim S, James WD. Skin signs of systemic disease: an update. *Adv Dermatol* 2002; 18: 1–27
- Hern AE, Shwayder TA. Unilateral plantar erythema nodosum. *J Am Acad Dermatol* 1992; 26: 259–60
- Kakourou T, Drosatou P, Psychou F, et al. Erythema nodosum in children: a prospective study. *J Am Acad Dermatol* 2001; 44: 17–21
- Labbe L, Perel Y, Maleville J, Taieb A. Erythema nodosum in children: a study of 27 patients. *Pediatr Dermatol* 1996; 13: 447–50
- Ter Poorten MC, Thiers BH. Panniculitis. *Dermatol Clin* 2002; 20: 421–33, vi

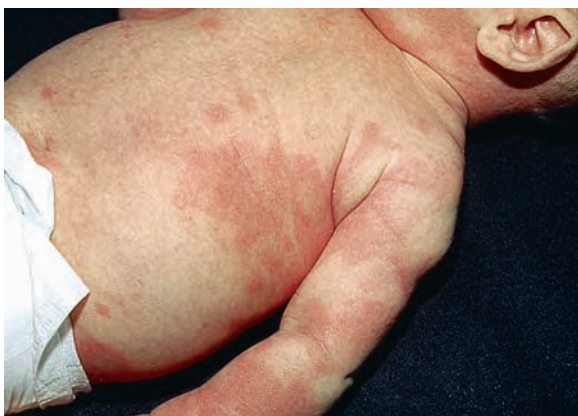### Annular erythemas

#### Major points

- Heterogeneous group of disorders characterized by annular erythematous eruption



- Transient:
  1. Erythema gyratum atrophicans transiens neonatale
    - a. Presents in newborns
    - b. Patchy, generalized erythema that resolves into atrophic hypopigmented patches
  2. Annular erythema of infancy
    - a. Onset in infancy, usually ages 3–11 months
    - b. Erythematous plaques that enlarge centrifugally to form rings and arcs; lesions appear and vanish over 36–48 hours (Figure 11.10)



**Figure 11.10** Annular erythema of infancy – this rash resolved in 2 weeks without treatment

3. Annular erythema in infants born to mothers with autoimmune disease (e.g. neonatal lupus erythematosus)
- Chronic:
    1. Erythema annulare centrifugum (EAC)
      - a. Rare in children but has been reported in neonates
      - b. Dusky red, erythematous papules and plaques that expand in a centrifugal pattern, usually on trunk and proximal extremities, fine scale at advancing edge
      - c. May accompany an underlying infection or neoplasm
    2. Familial annular erythema
      - a. Presents shortly after birth
      - b. Erythematous papules that enlarge centrifugally to form rings; may have vesiculated borders or inner collarette of scale
      - c. Family history of disorder

3. Erythema chronicum migrans (ECM)
  - a. Manifestation of Lyme disease caused by infection with *Borrelia burgdorferi* (see Chapter 8)
  - b. Enlarging erythematous ring develops at the site of a tick bite, up to a diameter of 20–30 cm

- Nonspecific annular erythemas

### Pathogenesis

- Inflammatory hypersensitivity disorder of unknown etiology

### Diagnosis

- Characteristic clinical findings
- Skin biopsy
- Histology consistent with diagnosis: superficial and deep lymphohistiocytic infiltrate in a perivascular distribution with presence of eosinophils and sometimes neutrophils

### Differential diagnosis

- Erythema multiforme
- Annular urticaria
- Tinea corporis
- Seborrheic dermatitis

### Treatment

- Tends to resolve without treatment in the absence of underlying disease
- Antihistamines, antibiotics, corticosteroids (systemic and local), antifungals (oral and topical) have been reported to have no effect on disease course
- ECM and accompanying Lyme disease should be treated with antibiotics (see Chapter 8); skin lesion resolves with treatment

### Prognosis

- Complete resolution without treatment has been reported to occur after a course of partial remissions and exacerbations over a period of months to years
- Course can be chronic

### References

- Anzai H, Kikuchi A, Kinoshita A, Nishikawa T. Recurrent annular erythema in juvenile chronic myelogenous leukaemia. *Br J Dermatol* 1998; 138: 1058–60
- Bottoni U, Innocenzi D, Bonaccorsi P, et al. Erythema annulare centrifugum: report of a case with neonatal onset. *J Eur Acad Dermatol Venereol* 2002; 16: 500–3

Cox NH, McQueen A, Evans TJ, Morley WN. An annular erythema of infancy. *Arch Dermatol* 1987; 123: 510–13

Stachowitz S, Abeck D, Schmidt T, Ring J. Persistent annular erythema of infancy associated with intestinal *Candida* colonization. *Clin Exp Dermatol* 2000; 25: 404–5

Toonstra J, de Wit FE. 'Persistent' annular erythema of infancy. *Arch Dermatol* 1984; 120: 1069–72

Watanabe T, Tsuchida T, Ito Y, et al. Annular erythema associated with lupus erythematosus/Sjogren's syndrome. *J Am Acad Dermatol* 1997; 36: 214–18

Weyers W, Diaz-Casajo C, Weyers I. Erythema annulare centrifugum: results of a clinicopathologic study of 73 patients. *Am J Dermatopathol* 2003; 25: 451–62

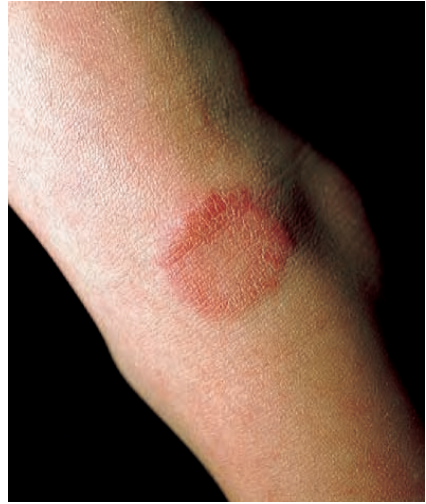## Granuloma annulare

### Major points

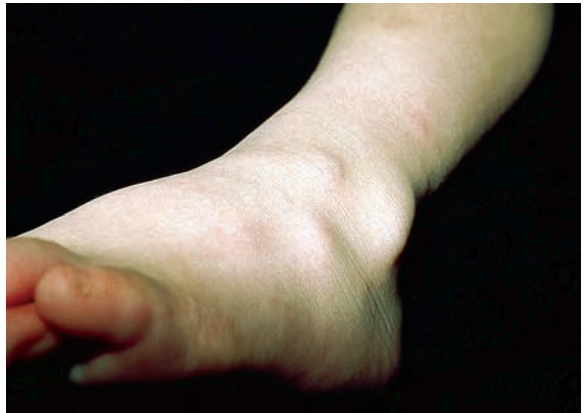- Benign, self-limited dermatosis
- Subcutaneous indurated dermal papules/plaques in an annular configuration
- Several different types:
  1. Localized form – most common, usually seen on the dorsa of the hands and feet and lower extremities, but may be seen anywhere (Figure 11.11)
  2. Subcutaneous form – deep dermal or subcutaneous nodules with no overlying epidermal change, commonly on the pretibial area of children aged 2–5 years (Figure 11.12)
  3. Perforating form (generalized perforating granuloma annulare) – rare, grouped papules, some of which have a central area where damaged collagen ulcerates through the epidermis
  4. Generalized form – hundreds of small papules forming ringed lesions that coalesce into reticulate patterns or linear bands
- Association with insulin-dependent diabetes mellitus in adults, not children

### Pathogenesis

- Etiology unknown
- Proposed to be an immune-mediated response to an unknown antigenic stimulus with degeneration of collagen in the dermis, reactive inflammation and fibrosis
- Histology: palisading granuloma with necrobiotic collagen, fibrin and mucin deposits; in perforating



**Figure 11.11** Granuloma annulare – typical ring of papules



**Figure 11.12** Granuloma annulare – deep subcutaneous nodules

granuloma annulare the granulomas perforate the epidermis, extruding necrobiotic material

### Diagnosis

- Characteristic clinical findings
- Skin biopsy if atypical
- No specific laboratory abnormalities associated

### Differential diagnosis

- Tinea corporis
- Sarcoidosis
- Rheumatoid nodules
- Necrobiosis lipoidica

### Treatment

- Reassurance of benign condition
- Mid-range topical corticosteroid with or without occlusion
- Intralesional steroids for persistent lesions

### Prognosis

- Lesions persist for several years then resolve spontaneously
- Mainly a cosmetic problem

### References

- Choi JC, Bae JY, Cho S, et al. Generalized perforating granuloma annulare in an infant. *Pediatr Dermatol* 2003; 20: 131–3
- Grogg KL, Nascimento AG. Subcutaneous granuloma annulare in childhood: clinicopathologic features in 34 cases. *Pediatrics* 2001; 107: 42
- Kuwahara, RT, Naylor MF, Skinner RB. Treatment of granuloma annulare with topical 5% imiquimod cream. *Pediatr Dermatol* 2003; 20: 90

## Rheumatoid nodules

### Major points

- Subcutaneous nodules similar to the ones seen in rheumatoid arthritis in adults with no other clinical signs or laboratory evidence of systemic disease
- Seen in otherwise healthy children most commonly at 2–10 years of age
- Clinical presentation:
  1. Subcutaneous nodules
  2. Often multiple
  3. Distribution usually on the limbs, over the occiput, prepatellar and malleolar regions, pretibial areas, heels, fingers, elbows and proximal ulnar regions
  4. Occasional reports of associated arthralgias
- Not thought to be a precursor for juvenile rheumatoid arthritis (JRA); however, there have been rare reported cases of development of JRA
- May be the same entity as subcutaneous granuloma annulare (pseudorheumatoid nodules)

### Pathogenesis

- Etiology unknown
- Thought to be an immunologic mechanism; IgG and IgM have been found in nodules

- Reported following trauma or acute tonsillitis
- Histology:
  1. Similar to that of subcutaneous granuloma annulare
  2. Central necrotic zone surrounded by palisading histiocytes and mononuclear inflammatory cells

### Diagnosis

- Clinical presentation
- Absence of clinical or laboratory evidence of JRA

### Differential diagnosis

- Granuloma annulare
- Rheumatoid nodules associated with JRA
- Calcinosis cutis
- Osteoma cutis

### Treatment

- No specific treatment usually needed
- Intralesional steroids

### Prognosis

- Nodules may regress and disappear over time
- Generally, does not progress to JRA

### References

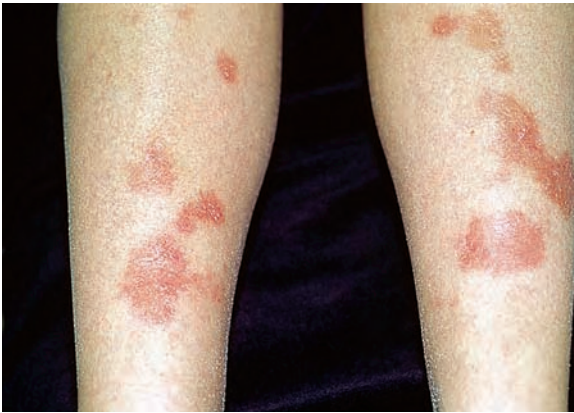- Cawkwell GD. Benign rheumatoid nodules. *Arch Pediatr Adolesc Med* 1994; 148: 1219–20
- Nalbant S, Corominas H, Hsu B, et al. Ultrasonography for assessment of subcutaneous nodules. *J Rheumatol* 2003; 30: 1191–5
- Yamamoto T, Matsunaga T, Nishioka K. Rheumatoid neutrophilic dermatitis, rheumatoid papules, and rheumatoid nodules in a patient with seronegative rheumatoid arthritis. *J Am Acad Dermatol* 2003; 48: 634–5
- Yavuz H, Ozel A, Yilmaz O, et al. Benign rheumatoid nodules. *Am J Dis Child* 1993; 147: 1011–12

## Necrobiosis lipoidica diabetorum

### Major points

- Skin lesions strongly associated with diabetes mellitus (DM) type I but has been reported with type II DM
- Prevalence of 0.06% in children with diabetes and may precede onset of DM
- Female/male ratio >1

- Average age of onset: 15 years
- Clinical presentation:
  1. Painless papules which enlarge to form a central, waxy, atrophic, depressed area with an elevated violaceous peripheral ring (Figure 11.13)
  2. Central color is reddish-brown to orange-yellow
  3. Telangiectasias may be seen within plaques
  4. Usually over the bilateral anterior tibias
  5. Often multiple plaques
  6. May rarely be seen on the upper extremities or trunk
  7. Tend to ulcerate



**Figure 11.13** Necrobiosis lipoidica diabetorum – erythematous, shiny plaques on shins with central atrophy

### Pathogenesis

- Etiology unknown
- Microangiopathy or other vascular etiology, lipid disorder, and immunologic mechanisms have been proposed
- Histology: diffuse palisading and interstitial granulomatous inflammation

### Diagnosis

- Characteristic clinical findings
- Skin biopsy
- Evaluation for diabetes

### Differential diagnosis

- Granuloma annulare
- Sarcoidosis

- Panniculitis
- Morphea

### Treatment

- Treat underlying diabetes to achieve good glycemic control
- Corticosteroids:
  1. Potent topical corticosteroids – for early lesions
  2. Intralesional corticosteroids – injected into the active border of established lesions
- Oral pentoxifylline (Trental®)

### Prognosis

- Ulcerated lesions heal slowly and may ulcerate again
- May indicate a greater risk for diabetic retinopathy and nephropathy

### References

- de Silva DM, Schofield OM, Walker JD. The prevalence of necrobiosis lipoidica diabetorum in children with type 1 diabetes. *Br J Dermatol* 1999; 141: 593–4
- Pestoni C, Ferreirós MM, de la Torre C, Toribio J. Two girls with necrobiosis lipoidica and type I diabetes mellitus with transfollicular elimination in one girl. *Pediatr Dermatol* 2003; 20: 211–14
- Retting KR. Necrobiosis lipoidica diabetorum. *Clin Pediatr* 2000; 39: 439–40
- Szabo RM, Harris GD, Burke WA. Necrobiosis lipoidica in a 9-year-old girl with new-onset type II diabetes mellitus. *Pediatr Dermatol* 2001; 18: 316–19

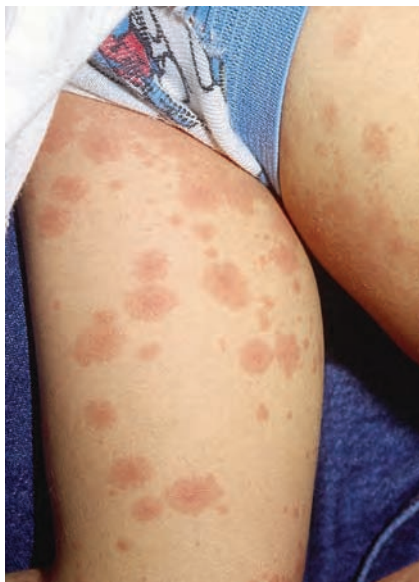## Kawasaki disease

### Major points

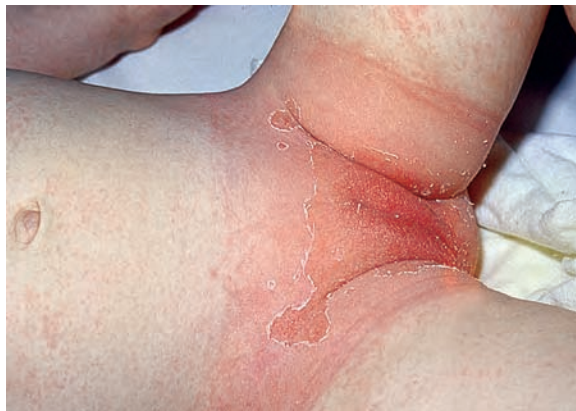- Characterized by high fever, lymphadenopathy and mucocutaneous lesions
- Most serious complications are coronary artery abnormalities:
  1. Aneurysms, diffuse ectasia, vasculitis
  2. Develop in 20–25% of cases of untreated Kawasaki disease
  3. Giant aneurysm carries the worst prognosis – risk of developing coronary thrombosis, stenosis or myocardial infarction
  4. Smaller aneurysms tend to resolve; giant aneurysms do not



- Most common cause of acquired heart disease among children in the USA
- Occurs predominantly in children <5 years age
- Hospitalization rate for US children aged <5 years is ~17 per 100 000 (approximates the disease incidence)
- Increased risk in younger children, males (ratio of 1.5 : 1), and individuals of Asian descent
- Increased rates in winter and spring months, with higher socioeconomic status, and in certain geographic regions of the USA (higher in the Northeast and West)
- Clinical course can be divided into three phases:
  1. Acute febrile phase (7–14 days):
    - a. Fever
    - b. Conjunctival injection
    - c. Mouth and lip changes – dryness, redness, fissuring, crust, ‘strawberry tongue’
    - d. Swelling and erythema of hands and feet
    - e. Rash – polymorphous exanthem on the body and/or extremities, especially in diaper area (Figures 11.14 and 11.15)
    - f. Cervical lymphadenopathy
  2. Subacute phase (from the end of fever for ~25 days)
    - a. Desquamation of fingers and toes (Figure 11.16)



**Figure 11.14** Kawasaki disease – targetoid, erythematous macules

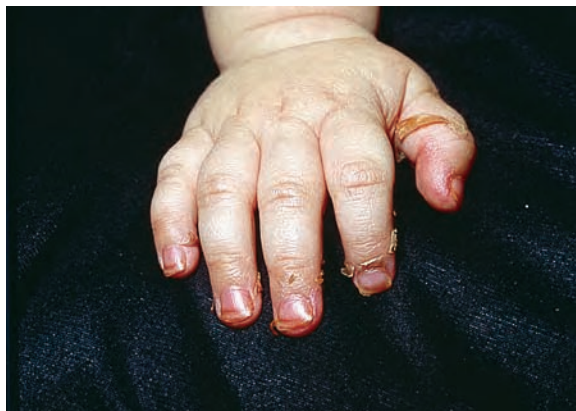

**Figure 11.15** Kawasaki disease – perineal rash with peeling

- b. Arthritis and arthralgias
  - c. Thrombocytosis
3. Convalescent phase (6–8 weeks)
    - a. Clinical symptoms resolve
    - b. Continues until ESR becomes normal

### Pathogenesis

- Etiology unknown
- Immunoregulatory abnormalities – response to a bacterial (or viral) protein toxin acting as a superantigen has been proposed
- Presumed etiology is infectious – viral (e.g. Epstein–Barr virus and retrovirus), *Streptococcus viridans*, staphylococci, *Propionibacterium* species and parvovirus



**Figure 11.16** Kawasaki disease – desquamation of the fingertips



### Diagnosis

- Based on history and physical examination
- Jones criteria:
  1. High fever for  $\geq 5$  days without other explanation
  2. Four of the following five criteria:
    - a. Conjunctival injection
    - b. Oropharyngeal changes: injected or fissured lips, hyperemia of pharynx, strawberry tongue
    - c. Extremity changes: erythema of palms or soles, hand or foot edema, periungual desquamation
    - d. Polymorphous rash (especially on trunk)
    - e. Acute nonsuppurative cervical lymphadenopathy
- Cases of 'atypical' or 'incomplete' Kawasaki disease:
  1. Fewer than four of the five criteria
  2. Coronary complications
  3. More common in infants <6 months age
- Electrocardiogram and echocardiogram – to look for cardiovascular manifestations
- Common laboratory abnormalities: leukocytosis, thrombocytosis, elevated ESR and C-reactive protein, sterile pyuria

### Differential diagnosis

- Viral exanthem
- Scarlet fever
- Staphylococcal scalded skin syndrome
- Stevens–Johnson syndrome
- Drug reactions
- Toxic shock syndrome

### Treatment

- Combined intravenous immunoglobulin (IVIG) and aspirin therapy
  1. IVIG – 2 g/kg as a single dose before day 10 of fever can reduce risk of coronary artery disease from ~20% to <5%
  2. Aspirin – 30–100 mg/kg per day in four divided doses until defervescence, and then reduced to 3–5 mg/kg per day as a single daily dose
- Ongoing fever or other signs of inflammation 24–72 hours or longer after treatment may warrant additional doses of IVIG

- Treatment of cardiac complications – thrombolytics, surgical revascularization, cardiac transplantation
- Use of corticosteroids is controversial

### Prognosis

- 85% of children treated in the first 10 days after onset will have prompt defervescence and resolution of signs of inflammation
- Prognosis is favorable for those children who do not develop coronary artery abnormalities
- In children with coronary artery aneurysms:
  1. 50% regress within 2 years
  2. For giant aneurysms (>8 mm), risk for stenosis, complete obstruction, or myocardial infarction
- Myocardial infarction is the major cause of mortality – most commonly occurs after years in patients with giant aneurysms

### References

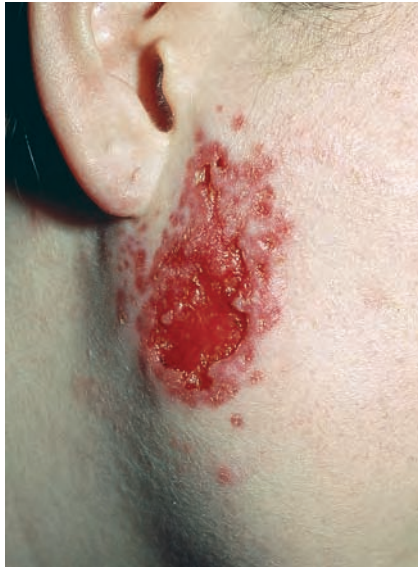- Genizi J, Miron D, Spiegel R, et al. Kawasaki disease in very young infants: high prevalence of atypical presentation and coronary arteritis. *Clin Pediatr* 2003; 42: 263–7
- Holman RC, Curns AT, Belay ED, et al. Kawasaki syndrome hospitalizations in the United States, 1997 and 2000. *Pediatrics* 2003; 112: 495–501
- Meissner HC, Leung DYM. Kawasaki syndrome: where are the answers? *Pediatrics* 2003; 112: 672–5
- Proft T, Fraser JD. Bacterial superantigens. *Clin Exp Immunol* 2003; 133: 299–306
- Taubert KA, Shulman ST. Kawasaki disease. *Am Fam Physician* 1999; 59: 3093–102, 3107–8

## Pyoderma gangrenosum

### Major points

- Clinical features:
  1. Begins as a small pustule, erythematous nodule, or bulla that spreads concentrically from the center to develop necrotic ulceration with a mucopurulent base, violaceous undermined border, and peripheral erythema (Figure 11.17)
  2. Clinical variants: ulcerative, pustular, bullous, or vegetative
  3. History given of preceding minor trauma or irritation is common

4. May progress to become atrophic paper-like skin or cribriform scars
5. Single or multiple lesions
6. Most frequent on anterior legs; may occur on face, trunk, or buttocks



**Figure 11.17** Pyoderma gangrenosum – deep scarring and painful erythema

7. Exquisitely painful
  8. Pathergy may be reported
- Often occurs in association with systemic disorders:
    1. Inflammatory bowel disease
    2. Arthritis
    3. Hematologic disease: leukemia, monoclonal gammopathy, polycythemia vera, lymphoma
    4. Immunodeficiency disorders: hypogammaglobulinemia, IgA deficiency, impaired leukocyte deficiency, HIV
    5. Most common in children: inflammatory bowel disease and arthritis
  - Idiopathic (no associated disease identified) in 20–30% of cases

#### *Pathogenesis*

- Cause is unknown
- Proposed to be an exaggerated inflammatory response caused by an underlying immunologic abnormality

1. Frequent association with systemic diseases with presumed autoimmune etiology or immunologic defects
  2. Associated immune abnormalities have been reported, including: immunoglobulin levels, cell-mediated immunity and neutrophil function
- Pathergy has been reported in ~20% of cases
  - Histology: necrosis and ulceration of the epidermis and dermis, acute inflammatory cell infiltrate and the margin of the lesion, chronic inflammatory cell infiltrate at the base

#### *Diagnosis*

- Skin biopsy – to exclude deep fungal infection and vasculitis
- Look for underlying conditions
- Common laboratory abnormalities: elevated ESR, mild anemia, various immune defects (e.g. abnormal immunoglobulins)

#### *Differential diagnosis*

- Deep fungal infection
- Vasculitis
- Sweet syndrome
- Spider bite

#### *Treatment*

- Treat underlying disorder
- Systemic treatment
  1. Oral or pulsed IV corticosteroids
  2. Dapsone (oral)
- Adjuvant topical antibiotic therapy
- Topical or intralesional corticosteroids at edge of active lesion
- Dressings – oxygen-permeable or semi-permeable
- Other options if above treatments fail: cyclophosphamide, azathioprine, methotrexate, mercaptopurine, melphalan, minocycline, tetracycline, clofazimine, cyclosporine A, thalidomide
- Surgical debridement can extend the lesion; not recommended

#### *Prognosis*

- Atrophy or scarring common
- Successful treatment of underlying disorder may result in clearing
- Chronic relapsing disease may occur and may be difficult to manage

## References

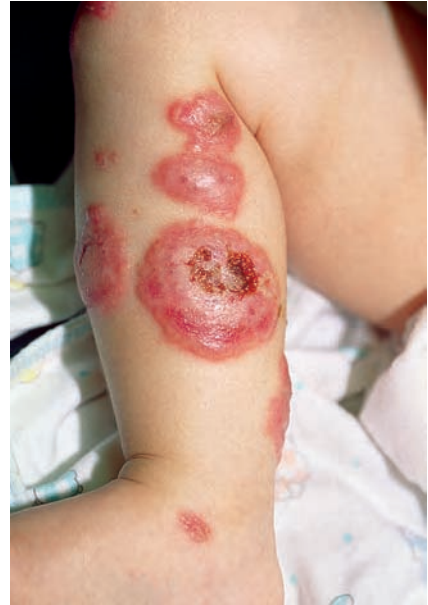- Crowson AN, Mihm MC Jr, Magro C. Pyoderma gangrenosum: a review. *J Cutan Pathol* 2003; 30: 97–107
- Dourmishev AL, Miteva I, Schwartz RA. Pyoderma gangrenosum in childhood. *Cutis* 1996; 58: 257–62
- Gettler S, Rothe M, Grin C, Grant-Kels J. Optimal treatment of pyoderma gangrenosum. *Am J Clin Dermatol* 2003; 4: 597–608
- Mekkes JR, Loots MA, Van Der Wal AC, Bos JD. Causes, investigation and treatment of leg ulceration. *Br J Dermatol* 2003; 148: 388–401

## Sweet syndrome

Synonym: acute febrile neutrophilic dermatosis

### Major points

- Cardinal features: fever, neutrophilic leukocytosis in the peripheral blood; tender, red plaques on limbs, face and neck; dense dermal infiltrate of neutrophils on histology
- Can occur at all ages
  1. Peak onset in middle age
  2. Pediatric cases account for 5% of all total reported cases
  3. Can occur in infants as young as 7 weeks
- Cutaneous manifestations:
  1. Abrupt onset of lesions that enlarge and coalesce over days to weeks
  2. Bright red to purple, painful, tender, sharply demarcated plaques (Figure 11.18)
  3. May have scaling, crusting, hemorrhagic bullae, or ulceration
  4. May be warm to touch
  5. Lesions range in size from 4 mm to >12 cm
  6. Lesions are usually multiple
  7. Solitary lesions usually have a predilection for the face
  8. Distribution is asymmetric; over the upper extremities, neck, face more than trunk, lower extremities
  9. Pathergy has been reported
- Extracutaneous manifestations:
  1. Fever
  2. Neutrophilic leukocytosis
  3. Serum sickness-like symptoms: myalgias, malaise, nausea, headache



**Figure 11.18** Sweet syndrome – large, indurated plaques

4. Meningeal symptoms
5. Gastrointestinal distress
6. Musculoskeletal symptoms: arthralgias, arthritis
7. Renal involvement (11–72%): proteinuria, hematuria, acute renal failure, glomerulonephritis
8. Ocular findings: iritis, episcleritis, conjunctivitis
9. Lung involvement
10. Hepatic involvement
- Associated with many conditions (Table 11.1):
  1. Antecedent infection (especially upper respiratory infection)
  2. Autoimmune/inflammatory diseases
  3. Malignancy (in 20% of cases) – primarily hematologic malignancies
  4. Drugs and vaccinations (especially granulocyte colony-stimulating factor; G-CSF)

### Pathogenesis

- Likely to be a reactive process resulting from immunologic hypersensitivity to a variety of agents (e.g. infection, neoplasm, drug, autoimmune processes)
- Interleukin-1 has been implicated as a mediator for both cutaneous and systemic inflammation
- Association with G-CSF treatment supports neutrophil activation as a mechanism

**Table 11.1 Conditions associated with Sweet syndrome****Inflammatory/autoimmune**

Ulcerative colitis  
 Crohn disease  
 Bowel bypass syndrome  
 Systemic lupus erythematosus  
 Rheumatoid arthritis  
 Sjögren syndrome  
 Behçet syndrome  
 Pyoderma gangrenosum  
 Subacute thyroiditis  
 Cirrhosis

**Infections**

*Staphylococcus*  
*Streptococcus*  
*Yersinia*  
*Salmonella*  
 Tuberculosis  
 Histoplasmosis  
 Meningitis  
 Hepatitis  
 HIV

**Malignancy**

Acute myelogenous leukemia  
 Chronic myelogenous leukemia  
 Acute lymphocytic leukemia  
 Chronic lymphocytic leukemia  
 Lymphoma  
 Myelodysplastic syndromes  
 Breast cancer  
 Prostate cancer  
 Ovarian cancer  
 Endometrial cancer  
 Vaginal cancer  
 Testicular cancer  
 Rectal cancer

**Other**

Drugs (most commonly granulocyte colony-stimulating factor)  
 Immunizations  
 Pregnancy  
 Photoinduction  
 Renal stones

Adapted from Fitzgerald RL, McBurney IE, Nesbitt LT. Sweet's syndrome. *Int J Dermatol* 1996; 35: 9–15

- Histology:
  1. Dense, dermal infiltrate of mature neutrophils
  2. Epidermis is usually normal, but may have reactive changes
  3. Classic definition of Sweet syndrome requires the absence of vasculitis; however, vasculitis (vessel damage) may be seen especially in lesions present for a long duration – thought to be a result of toxic metabolites released by activated neutrophils

**Diagnosis**

- Diagnostic criteria (two major and one minor criteria needed for diagnosis):
  1. Major criteria:
    - a. Abrupt onset of tender or painful erythematous plaques or nodules
    - b. Predominantly neutrophilic infiltration in the dermis
  2. Minor criteria:
    - a. Preceded by respiratory infection, GI infection, vaccination or associated with: inflammatory disease, hematoproliferative disorder, solid malignant tumor, or pregnancy
    - b. Malaise and fever ( $>38^{\circ}\text{C}$ )
    - c. Laboratory values at onset: ESR  $>20$  mm, C-reactive protein, segmented neutrophils  $>70\%$  in peripheral blood smear, leukocytosis (three out of four values necessary)
    - d. Excellent response to systemic corticosteroid or potassium iodide treatment
- Rule out infectious causes, including HIV
- Underlying condition (e.g. malignancy) should be investigated
- Laboratory findings are nonspecific: ESR, C-reactive protein, CBC, renal function tests
- Skin biopsy usually necessary

**Differential diagnosis**

- Drug reaction
- Cellulitis
- Herpes simplex infection
- Pyoderma gangrenosum
- Secondary syphilis
- Erythema multiforme
- Vasculitis
- Leukemia cutis



### Treatment

- Systemic glucocorticoids:
  1. Oral steroids 0.5–1.5 mg/kg per day for 10 days followed by a slow taper
  2. Lesions usually clear in several days with treatment
- Other drugs: potassium iodide, dapsone, cyclosporine, colchicine, clofazimine, indomethacin, methotrexate, isotretinoin, pulse steroids with chlorambucil

### Prognosis

- Most cases respond well to oral steroids with rapid clearing of lesions
- Healing may result in hyperpigmentation, milia, or scarring
- Untreated lesions usually resolve in 6–8 weeks, but may take months
- Recurrences are common
- Prognosis depends upon severity of underlying systemic condition

### References

- Callen JP. Neutrophilic dermatoses. *Dermatol Clin* 2002; 20: 409–19
- Crawford GH, Kim S, James WD. Skin signs of systemic disease: an update. *Adv Dermatol* 2002; 18: 1–27
- Fitzgerald RL, McBurney IE, Nesbitt LT. Sweet's syndrome. *Int J Dermatol* 1996; 35: 9–15
- Kourtip AP. Sweet syndrome in infants. *Clin Pediatr* 2002; 41: 175–7
- Malone JC, Slone SP, Wills-Frank LA, et al. Vascular inflammation (vasculitis) in Sweet syndrome. *Arch Dermatol* 2002; 138: 345–9
- Von den Driesch P. Sweet's syndrome (acute neutrophilic dermatosis). *J Am Acad Dermatol* 1994; 3: 535–56

## Sarcoidosis

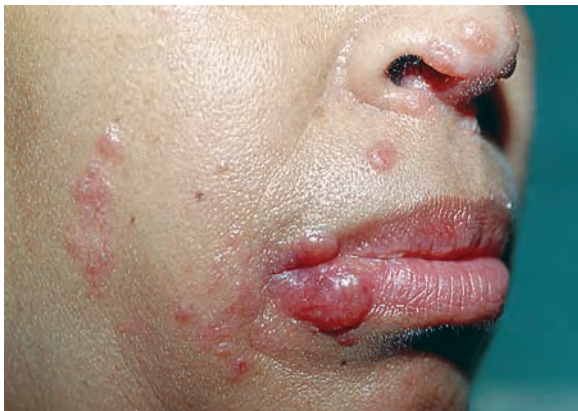### Major points

- Systemic granulomatous disorder characterized by the presence of noncaseating granulomas
- Rare in pediatric age group; more common in adolescents and young adults
- Male/female ratio = 1
- Two distinct forms of juvenile sarcoidosis:
  1. Early-onset:

- a. Presents in ages 1–5 years
  - b. Triad of arthritis/rash/uveitis with typical pulmonary disease often absent
  - c. Predominantly Whites
  - d. Often confused with JRA
  - e. Less favorable prognosis – progressive and debilitating course
2. Older children:
    - a. Presents in adolescence
    - b. Similar to adult disease with lung/lymph node/eye involvement
    - c. Predominantly Blacks
- Clinical manifestations are protean; multiple organ systems can be involved
  - Most common clinical features:
    1. Lung involvement:
      - a. Most common organ involved
      - b. Accounts for majority of morbidity and mortality
      - c. Dry cough and dyspnea
      - d. Bilateral hilar lymphadenopathy with or without parenchymal involvement
      - e. Abnormal chest X-ray and pulmonary function tests
    2. Cutaneous manifestations:
      - a. Red to yellowish-brown papules, plaques, or nodules; erythema nodosum; hypo- or hyperpigmentation (Figure 11.19)
      - b. Most frequent on the face, but may occur on trunk, extremities, buttocks
      - c. Lupus pernio (sarcoidosis of the nose) – rare in children
    3. Eye involvement:
      - a. Common, serious and progressive
      - b. Granulomatous uveitis
      - c. Conjunctival granulomatous nodules
      - d. Complications: optic neuritis, band keratopathy, cataracts, glaucoma, retinal vasculitis
    4. Lymphadenopathy
    5. Other organ systems involved: CNS, kidneys, liver, spleen, heart and blood vessels, musculoskeletal system

### Pathogenesis

- Etiology unknown
- Postulated to represent an altered immune response to unknown agent(s) resulting in granuloma formation



**Figure 11.19** Sarcoidosis – typical firm papules on the face in an adult

- Genetic predisposition
- Histology: discrete, compact, noncaseating, epithelioid cell granulomas

### Diagnosis

- Biopsy: demonstration of noncaseating granulomas in one or more organs
  - a. Fungal and other infections should be ruled out using special stains
  - b. Least invasive biopsy site should be chosen based on clinical presentation (e.g. skin, palpable lymph nodes)
- Characteristic clinical findings
- Radiographic imaging:
  1. Chest X-ray: bilateral hilar lymphadenopathy
  2. CT or MRI for involvement in the orbit, CNS, muscle/bone
- Ophthalmologic evaluation
- Laboratory studies are nonspecific: calcium levels and serum angiotensin converting enzyme may be elevated

### Differential diagnosis

- Systemic juvenile rheumatoid arthritis
- Lymphoma
- Tuberculosis
- Other diffuse interstitial pulmonary diseases
- Infections with granulomatous reactions

### Treatment

- Asymptomatic patients and mild disease; watchful waiting without treatment may be appropriate; may spontaneously resolve

- Patients with multisystem disease:
  1. Oral corticosteroid treatment for serious lung, ocular, neurological, cardiac disease
  2. Methotrexate if refractory to steroid treatment or as a steroid-sparing agent
  3. Other agents used: cyclosporine, azathioprine, cyclophosphamide

### Prognosis

- Majority of older children recover with minimal or no therapy with improved pulmonary status (similar to adults)
- Poor prognosis associated with severe involvement at presentation, multiorgan involvement, early-onset form of disease

### References

- Cimaz R, Ansell BM. Sarcoidosis in the pediatric age. *Clin Exp Rheumatol* 2002; 20: 231–7
- Fetil E, Ozkan S, Ilknur T, et al. Sarcoidosis in a preschooler with only skin and joint involvement. *Pediatr Dermatol* 2003; 20: 416–18
- Lindsley CB, Petty RE. Overview and report on international registry of sarcoid arthritis in childhood. *Curr Rheumatol Rep* 2000; 2: 343–8
- Mana J, Marcoval J, Graells J, et al. Cutaneous involvement in sarcoidosis: relationship to systemic disease. *Arch Dermatol* 1997; 133: 882–8
- Ramanan AV, Denning DW, Baildam EM. Cutaneous childhood sarcoidosis – a rare disease refractory to treatment. *Rheumatology* 2003; 42: 1570–1
- Shetty AK, Gedalia A. Sarcoidosis: a pediatric perspective. *Clin Pediatr* 1998; 37: 707–17
- Shetty AK, Gedalia A. Sarcoidosis in children. *Curr Probl Pediatr* 2000; 30: 153–76

## NUTRITIONAL DISORDERS

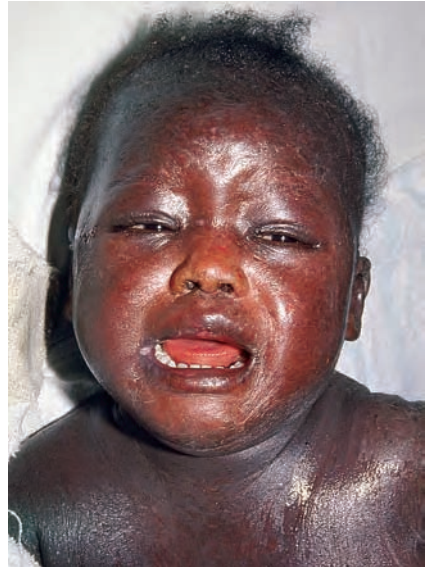### Anorexia and bulimia nervosa-associated skin disorders

- Xerosis
- Acral changes: coldness, cyanosis, periungual erythema
- Hypertrichosis
- Telogen effluvium
- Brittle hair and nails

- Carotenemia
- Oral changes: cheilitis and perleche, aphthae, gum erosions, dental caries
- Russell sign: calluses on the dorsum of hands from repetitive forced vomiting

## Kwashiorkor

- Protein intake deficiency with normal caloric intake
- Causes:
  1. All maize diet (e.g. in impoverished areas)
  2. Chronically ill children
  3. Restricted diet (e.g. food fads, food aversion)
- Cutaneous findings:
  1. Generalized hyperpigmentation
  2. Black patches of thickened epidermis over pressure point which desquamate ('peeling paint' appearance) (Figure 11.20)
  3. Dry, hypopigmented hair
  4. Desquamation around eyes, mouth
  5. Erosions in mouth, intertriginous areas with fissuring
- Extracutaneous findings: massive edema/anasarca, extreme irritability, apathy



**Figure 11.20** Kwashiorkor – protein malnutrition in a child who was thought to be allergic to milk, so milk was eliminated from her diet

## Marasmus

- Total calorie starvation
- Cutaneous findings:
  1. Thin, dry, lax skin
  2. Hair is thin, falls out readily
  3. Occasionally seen: fine scaling, desquamation, hyperpigmentation
- Extracutaneous findings:
  1. Loss of subcutaneous fat and muscle
  2. Individual remains alert

## Vitamin deficiencies

- Vitamin A (retinol) deficiency
  1. Cutaneous findings: scaliness, atrophy of sebaceous and sweat glands, follicular hyperkeratosis (phrynoderma), dull scalp hair
  2. Extracutaneous findings: poor night vision, conjunctival xerosis, Bitot spots in the eyes, impaired bone growth, cranial nerve lesions
  3. Causative drugs/factors: fat malabsorption, liver disease
- Vitamin B<sub>1</sub> (thiamine) deficiency – beriberi
  1. Wet (cardiac) beriberi: myocarditis with high-output congestive heart failure, edema
  2. Dry (neurologic) beriberi: peripheral neuropathy with wrist/foot drop, motor and digestive disturbances
  3. Wernicke–Korsakoff syndrome: encephalopathy with psychosis, ataxia, memory loss, confabulation, confusion
  4. Orogenital dermatitis
  5. Causative factors: rice-dependent diets, chronic alcoholism
- Vitamin B<sub>2</sub> (riboflavin) deficiency
  1. Cutaneous findings: oculo-orogenital syndrome, angular cheilitis, black tongue, glossitis, seborrheic dermatitis/dyssebacia, scrotal dermatitis
  2. Extracutaneous findings: anemia, mental retardation
  3. Causative drugs/factors: borate poison, neonatal phototherapy for hyperbilirubinemia, protein deficiency, hypothyroidism
- Vitamin B<sub>3</sub> (niacin) deficiency – pellagra
  1. Classic triad (3 Ds): diarrhea, dermatitis, dementia
  2. Cutaneous findings: dermatitis on sun-exposed skin, Casal necklace – photosensitive eruption

- around the neck, angular stomatitis, glossitis, oral and perirectal sores
- 3. Causative drugs/factors: gastrointestinal (malabsorptive) disease, drugs, plain corn diet, alcoholism
- Vitamin B<sub>6</sub> (pyridoxine) deficiency
  1. Cutaneous findings: periorificial dermatitis, pellagra-like rash, seborrhea, conjunctivitis, stomatitis, glossitis
  2. Extracutaneous findings: anorexia, GI symptoms, anemia, lymphopenia, confusion
  3. Causative factors: drugs, uremia, cirrhosis
- Vitamin B<sub>12</sub> (cobalamin) deficiency
  1. Cutaneous findings: hyperpigmentation of flexural areas, palms, soles, nails, oral cavity, glossitis, poliosis
  2. Extracutaneous findings: megaloblastic anemia, paresthesias, ataxia, hypotonia in infants, mental status changes
  3. Causative drugs/factors:
    - a. In infants – born to strict vegan mother or mothers with pernicious anemia, malnutrition due to low socioeconomic status
    - b. Others: decreased gastric synthesis of intrinsic factor (pernicious anemia), tropical sprue, strict vegetarianism, ileal destruction or bypass, chronic alcoholism
- Vitamin C (ascorbic acid) deficiency – scurvy
  1. Cutaneous findings: follicular hyperkeratosis, perifollicular petechiae, 'corkscrew' hairs, poor wound healing, koilonychias, gingival hemorrhage, sclerodermatous changes
  2. Extracutaneous findings: weakness, fatigue, depression
- Vitamin D deficiency – rickets
  1. No cutaneous alterations seen with deficiency
  2. Extracutaneous findings: rickets, muscle weakness
  3. Causative drugs/factors: excessive lack of sunlight, malabsorption, liver disease, vitamin D resistance, renal disease
- Biotin deficiency
  1. Cutaneous findings: acrodermatitis enteropathica, intertriginous and periorificial dermatitis, conjunctivitis, glossitis, cheilitis, xerosis, alopecia
  2. Extracutaneous findings: neuropsychiatric symptoms
  3. Causative drugs/factors: raw egg-white ingestion (avidin impedes absorption of biotin), anticonvulsant drugs, total parenteral nutrition, chronic GI disease, short bowel
- Vitamin K deficiency
  1. Deficiency results in impairment of the coagulation cascade; vitamin K is required for synthesis of factors II, VII, IX, X and proteins C and S
  2. Cutaneous findings: purpura, ecchymoses, hemorrhage
  3. Extracutaneous findings: GI, nasal, subgaleal, intracranial hemorrhage
  4. Causative drugs/factors: neonates (inadequate intake and decreased production), warfarin, antibiotics, liver disease, fat malabsorption
- Folic acid deficiency
  1. Similar to vitamin B<sub>12</sub> deficiency
  2. Cutaneous findings: hyperpigmentation of tongue and genitals, glossitis, angular cheilitis
  3. Extracutaneous findings: megaloblastic anemia
  4. Causative drugs/factors: phenytoin, barbiturates, methotrexate, celiac disease, goat's milk diet, pregnancy

## References

- Avci Z, Turul T, Aysun S, Unal I. Involuntary movements and magnetic resonance imaging findings in infantile cobalamin (Vit B 12) deficiency. *Pediatrics* 2003; 112: 684–6
- Barthelemy H, Chouvet B, Cambazard F. Skin and mucosal manifestations in vitamin deficiency. *J Am Acad Dermatol* 1986; 15: 1263–74
- Grob JJ, Collet-Villette AM, Aillaud MF, et al. Spontaneous adult scurvy in a developed country: new insight in an ancient disease. *Arch Dermatol* 1990; 126: 249–51
- Glorio R, Allevato M, De Pablo A, et al. Prevalence of cutaneous manifestations in 200 patients with eating disorders. *Int J Dermatol* 2000; 39: 348–53
- Hegy J, Schwartz RA, Hegyi V. Pellagra: dermatitis dementia, and diarrhea. *Int J Dermatol* 2004; 43: 1–5
- Lucky AW, Powell J. Cutaneous manifestations of endocrine, metabolic, and nutritional disorders. In *Pediatric Dermatology*, 3rd edn. Schachner LA, Hansen RC, eds. Mosby: New York, 2003: 937–8
- Lutter CK, Rivera JA. Nutritional status of infants and young children and characteristics of their diets. *J Nutr* 2003; 133: 2941S–9S
- Miller SJ. Nutritional deficiency and the skin. *J Am Acad Dermatol* 1989; 21: 1–30



Schulze UME, Pettke-Rank CV, Kreienkamp M, et al. Dermatologic findings in anorexia and bulimia nervosa of childhood and adolescence. *Pediatr Dermatol* 1999; 16: 90–4

Sigman GS. Eating disorders in children and adolescents. *Pediatr Clin North Am* 2003; 50: 1139–77

## Acrodermatitis enteropathica

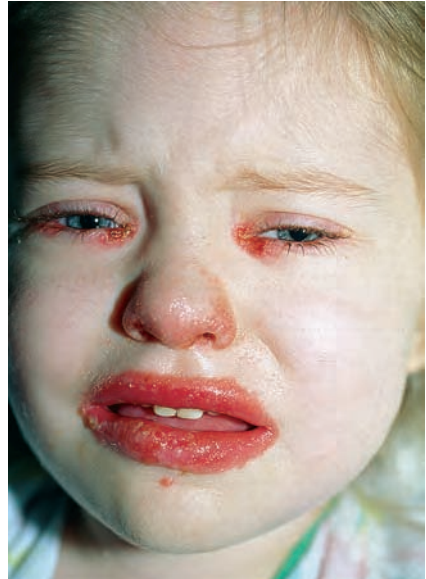
Synonym: zinc deficiency

### Major points

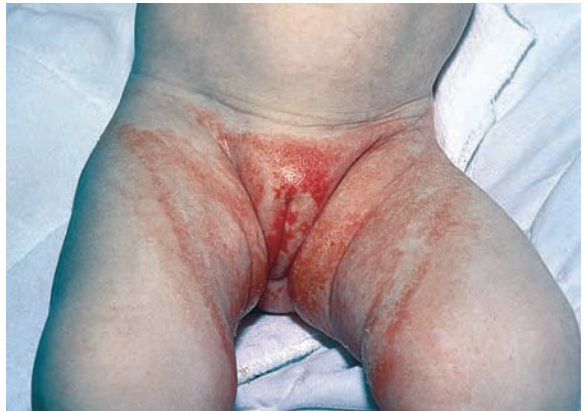- Classic presentation: dermatitis, diarrhea, alopecia, extreme irritability
- Types:
  1. Genetic (autosomal recessive)
  2. Nutritional, found sporadically in premature and full-term infants
  3. Endemically in the Middle East (growth failure and delayed pubertal maturation); caused by concurrent ingestion of high amounts of a zinc-binding ligand, phytate
  4. Iatrogenic zinc deficiency associated with total parenteral nutrition
- Genetic form: usually occurs 1–2 weeks after weaning from breast feeding, and rarely during breast feeding; in bottle-fed infants it occurs 4–10 weeks of age
- Dermatitis: periorificial (around mouth, eyes, genital area) and acral areas: erythematous, vesiculobullous or psoriasiform eruption with exudation and crusting (Figure 11.21)
- Secondary superinfection with *Candida* and staphylococci common
- Nail changes: pustular paronychia with subsequent nail dystrophy
- Hair fine and sparse, leading to total alopecia
- Photophobia, blepharitis, conjunctivitis, cheilitis
- Other: failure to thrive, apathy, ataxia, immune abnormalities, poor wound healing

### Pathogenesis

- Zinc is essential for normal function of all cells
- May be caused by defect in intestinal absorption of zinc or from deficient intake, malabsorption (as in cystic fibrosis) (Figures 11.22 and 11.23) and other chronic illnesses
- In the genetic form, caused by mutation in the intestinal zinc-specific transporter SLC39A4 on chromosome 8q24.3



**Figure 11.21** Acrodermatitis enteropathica – erythematous, eroded, periorificial plaques



**Figure 11.22** Cystic fibrosis presenting with edema and acrodermatitis enteropathica lesions

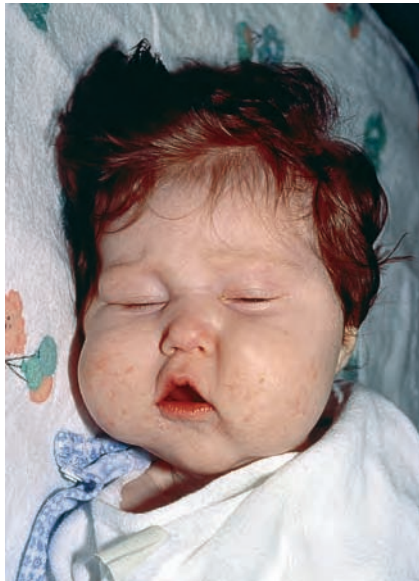### Diagnosis

- Low plasma zinc levels are pathognomonic (blood must be collected in special acid-washed or plastic tubes)
- Low serum alkaline phosphatase (a zinc-dependent metalloenzyme)

### Differential diagnosis

- Seborrheic dermatitis
- Psoriasis





**Figure 11.23** Cystic fibrosis – edema is obvious in the cheeks

- Candidal infection
- Fatty acid deficiency
- Biotin deficiency

#### *Treatment*

- Rapid and dramatic improvement with supplementation
- Zinc is in nuts, whole grains, green leafy vegetables, shellfish
- Daily requirement is 1–3 mg/kg per day, or 10–20 mg for adults

#### *Prognosis*

- Excellent response when treated
- Can be fatal without supplementation

#### *References*

- Brar BK, Pall A, Gupta RR. Acrodermatitis enteropathica-like rash in an exclusively breast fed infant with zinc deficiency. *J Dermatol* 2003; 30: 259–60
- Kim BE, Wang F, Dufner-Beattie J, et al. Zn<sup>2+</sup>-stimulated endocytosis of the mZIP4 zinc transporter regulates its location at the plasma membrane. *J Bio Chem* 2004; 279: 4523–30
- Michalczyk A, Varigos G, Catto-Smith A, et al. Analysis of zinc transporter, hZnT4 (Slc30A4), gene expression in a mammary gland disorder leading to reduced zinc secretion into milk. *Hum Genet* 2003; 113: 202–10
- Muniz AE, Bartle S, Foster R. Edema, anemia, hypoproteinemia, and acrodermatitis enteropathica: an uncommon initial presentation of cystic fibrosis. *Pediatr Emerg Care* 2004; 20: 112–4
- Nakano A, Nakano H, Nomura K, et al. Novel SLC39A4 mutations in acrodermatitis enteropathica. *J Invest Dermatol* 2003; 120: 963–6
- Perafan-Riveros C, Franca LF, Alves AC, Sanches JA Jr. Acrodermatitis enteropathica: case report and review of the literature. *Pediatr Dermatol* 2002; 19: 426–31
- Quirk CM, Seykora J, Wingate BJ, Cotsarelis G. Acrodermatitis enteropathica associated with anorexia nervosa. *J Am Med Assoc* 2002; 288: 2655–6
- Wang K, Zhou B, Kuo YM, et al. A novel member of a zinc transporter family is defective in acrodermatitis enteropathica. *Am J Hum Genet* 2002; 71: 66–73

# PHOTODERMATOSES AND PHYSICAL INJURY AND ABUSE

## PHOTODERMATOSES

### General

- Sun exposure in childhood is normal; excessive sun exposure may result in sunburn (toxic response) or, in some cases, abnormal reactions (e.g. lupus)
- Tanning is a sign of ultraviolet (UV) injury, and should not be considered 'healthy'
- Long-term consequences of chronic sun damage: skin cancer and photoaging

### Phototoxicity/sunburn

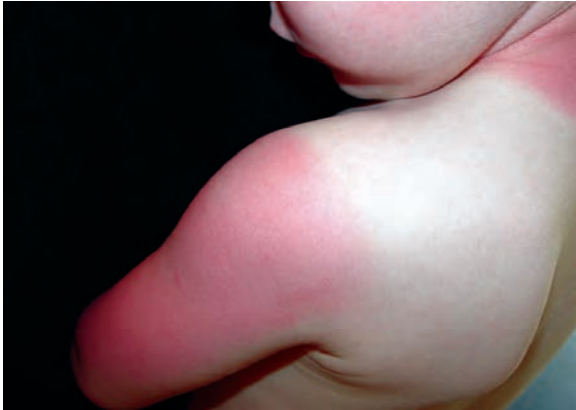#### Major points

- Sunburn depends upon a number of factors:
  1. Length of exposure

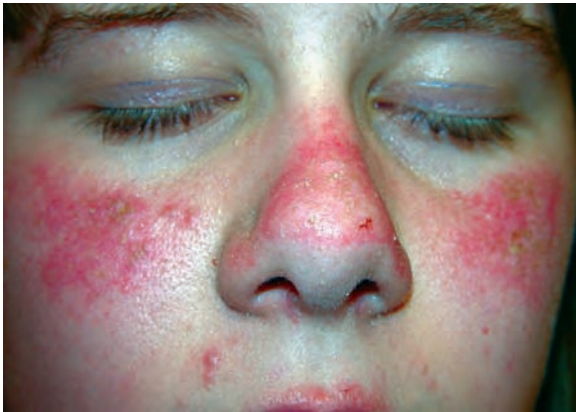2. Skin phototype (Table 12.1)
  3. Direction of sun's rays (summer > winter)
  4. Time of day (10.00 to 15.00 are strongest rays)
  5. Geographical location (nearer equator)
  6. Altitude (higher > lower)
  7. Age (infants > young children > adults)
- Erythema and tenderness begin 30 minutes to 4 hours after sun exposure; peaks at 24 hours; may last for 72 hours (Figures 12.1 and 12.2)
  - Most prominent on areas which receive direct light (e.g. nose, cheeks, shoulders) with less reaction in shielded areas (e.g. under nose and chin, and on upper eyelids)
  - With intense exposure: blistering, edema and later desquamation
    1. Sleep often disturbed
    2. Tenderness of skin
    3. Reduced sweating

**Table 12.1 Skin phototypes**

<i>Skin type</i>	<i>Reactivity to sun</i>	<i>Examples</i>
I	Always burns; never tans	Light skin, blond or red hair, blue or brown eyes, and freckles (e.g. Celts)
II	Always burns; tans minimally or lightly	Light skin; red, blond, or brown hair; blue, hazel or brown eyes (e.g. Northern Europeans)
III	Sometimes burns; tans gradually and uniformly	Brown hair, blue or brown eyes (e.g. Southern Europeans)
IV	Burns minimally or never; always tans	Dark brown hair, dark eyes, light brown skin (e.g. Latinos, Asians)
V	Moderately pigmented skin; never burns, always tans well	Medium brown skin, dark brown hair (e.g. Middle Easterners, Latinos)
VI	Deeply pigmented; never burns, always tans well	Dark skin, dark hair (e.g. Black Africans)



**Figure 12.1** Phototoxicity – from excessive sun exposure



**Figure 12.2** Phototoxicity from doxycycline

- 4. In severe burns, collapse from heat stroke, fever, headache and fatigue
- Ultraviolet light
  1. UV light consists of UVA, UVB, UVC
  2. UVB does not generate a perception of warmth unless skin is already burned (i.e. a person does not realize the damage until it is too late)
  3. On cloudy days, visible light and infrared rays (both cause a sensation of warmth) are filtered out; however, 80% of UVB can get through
  4. Much of lifetime sun exposure occurs before 18 years

#### *Pathogenesis*

- Acute ultraviolet injury is caused by radiation damage

1. First change is vasodilatation, probably caused by prostaglandins as mediators
  2. Metabolic changes occur within epidermal cells, which demonstrate clumping of tonofilaments and abnormalities of cytoplasm and nucleus which produce dyskeratotic 'sunburn cells', recognizable by light microscopy. These cells lose their epidermal cell attachments, and produce intraepidermal blisters
  3. By 48 hours, damage throughout epidermis
  4. By 72 hours, regeneration begins
  5. At 96 hours, great increase in number of melanocytes that have arborized their dendrites, beginning the tanning process
- Tanning response occurs in two distinct phases:
    1. Immediate response caused by photo-oxidation of melanin chromoproteins
    2. Delayed tanning develops with increased melanosome formation and increased transfer of melanosomes to keratinocytes; starts at 2 days and peaks at 19 days
    3. Melanin absorbs UVB and also acts as a 'sponge' by mopping up free radicals which damage the epidermis
  - UV radiation effects are cumulative
    1. Long-term effects: fine, deep wrinkling, actinic keratoses, skin cancer (especially basal cell carcinoma and squamous cell carcinoma), laxity, mottled pigmentation and telangiectasias
    2. Malignant melanoma: more common in patients with a history of several severe sunburns

#### *Diagnosis*

- Clinical symptoms and history
- Histology: epidermal spongiosis, 'sunburn cells' (dyskeratotic damaged epidermal cells), dermal vasodilatation, edema, neutrophils, monocytes, reduced number of Langerhans cells
- Photosensitizing agents can induce a reaction with short exposure (5–30 minutes) (Table 12.2)

#### *Differential diagnosis*

- Porphyria
- Lupus erythematosus
- Viral eruptions (e.g. fifth disease)
- Xeroderma pigmentosum

**Table 12.2 Exogenous photosensitizers**

	<i>Examples</i>
Drugs	Antibiotics (sulfonamides, tetracyclines, griseofulvin), phenothiazines, diuretics (furosemide, thiazides), quinine, isoniazid, tranquilizers, antidepressants, anti-inflammatory agents (naproxen), antiarrhythmics, antihypertensives
Plants	Furocoumarins
Dyes	Methylene blue, toluidine blue, xanthenes, fluorescein, eosin, erythrosine, acridine
Polycyclic hydrocarbons	Pitch, coal tars, anthracene, acridine, fluoranthrene
Perfumes/cosmetics	Bergamot oil, musk ambrette, 6-methylcoumarin, halogenated salicylanilides
Sunscreens	PABA, benzophenones, cinnamates
Tattoos	Cadmium sulfide

### Treatment

- Prevention
  1. Good sun protection habits should be stressed at an early age
  2. Infants <6 months should not have much direct sun exposure, but should be protected with clothing and umbrellas; more likely to develop heat stroke because of decreased ability to sweat
  3. Sun-protective clothing (e.g. Solumbra)
  4. Shade (e.g. umbrellas)
  5. Sunscreens (see Chapter 21) with the regular use of SPF 15 sunscreen during first 18 years of life, the lifetime incidence of nonmelanoma skin cancers can be reduced 78%
- Acute sunburn
  1. Cool wet compresses
  2. Aspirin, non-steroidal agents and indomethacin inhibit prostaglandin synthesis, and may modify sunburn if given within 24–48 hours of exposure, but will not repair damage already done to epidermal cells
  3. Steroids either topically or orally are not beneficial
  4. Topical anesthetics (e.g. benzocaine) can be sensitizing and only bring temporary relief. Not recommended
  5. Efficacies of topical aloe vera, jojoba oil and vitamin E have not been well studied

### Prognosis

- Self-limited
- Chronic sun exposure has long-term effects

### References

- Cokkinides VE, Weinstock MA, O'Connell MC, Thun MJ. Use of indoor tanning sunlamps by US youth, ages 11–18 years, and by their parent or guardian caregivers: prevalence and correlates. *Pediatrics* 2002; 109: 1124–30
- Drake LA, Dinehart SM, Farmer ER, et al. Guidelines of care for photoaging/photodamage. *J Am Acad Dermatol* 1996; 35: 462–4
- Driscoll MS, Wagner RF Jr. Clinical management of the acute sunburn reaction. *Cutis* 2000; 66: 53–8
- Garssen J, van Loveren H. Effects of ultraviolet exposure on the immune system. *Crit Rev Immunol* 2001; 21: 359–97
- Geller AC, Colditz G, Oliveria S, et al. Use of sunscreen, sunburning rates, and tanning bed use among more than 10 000 US children and adolescents. *Pediatrics* 2002; 109: 1009–14
- Kim HJ. Photoprotection in adolescents. *Adolesc Med State Art Rev* 2001; 12: 181–93

### Photoallergic dermatitis

#### Major points

- Chemicals can produce abnormal reactions when light energy is absorbed, causing either phototoxic or photoallergic reactions
- Photosensitizing agents may be either endogenous or exogenous
  1. Endogenous photosensitivity (e.g. porphyria); primary action spectrum is in the UVA range, 400–410 nm
  2. Exogenous photosensitizers produce phototoxic reactions which clinically resemble exaggerated sunburn (see Table 12.2)
  3. Topical photosensitizers (e.g. furocoumarins, lime oil, oil of cedar, vanilla oils, oil of lavender and sandalwood oil) cause photosensitivity reactions beginning 24 hours after exposure (see Phytophotodermatitis)

- Ranges from mild erythema or eczematous patches to severe blistering; may present with only postinflammatory hyperpigmentation
- Most photosensitization caused by UVA (320–400 nm)

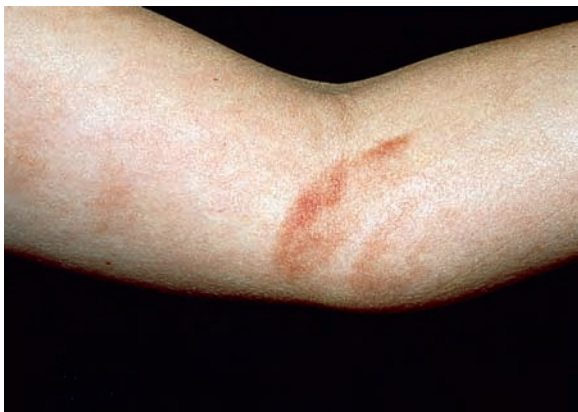### References

- Crouch RB, Foley PA, Baker CS. Analysis of patients with suspected photosensitivity referred for investigation to an Australian photodermatology clinic. *J Am Acad Dermatol* 2003; 48: 714–20
- Darvay A, White IR, Rycroft RJ, et al. Photoallergic contact dermatitis is uncommon. *Br J Dermatol* 2001; 145: 597–601
- Moore DE. Drug-induced cutaneous photosensitivity: incidence, mechanism, prevention and management. *Drug Safety* 2002; 25: 345–72
- Morison WL. Clinical practice. Photosensitivity. *N Engl J Med* 2004; 350: 1111–17

## Phytophotodermatitis

### Major points

- Caused by exposure to furocoumarins (psoralens) from plants
- Clinical picture:
  1. Redness, blisters and post-inflammatory hyperpigmentation, which often occur in bizarre shapes or linear streaks (Figure 12.3)
  2. Can present with hyperpigmented streaks without history of erythema or blistering



**Figure 12.3** Phytophotodermatitis caused by lime juice and sun exposure

3. Limes, certain perfumes, celery and certain grasses have higher content of furocoumarins
4. History of exposure is helpful

### Differential diagnosis

- Allergic contact dermatitis
- Postinflammatory hyperpigmentation
- Incontinentia pigmenti
- Lentiginous nevus

### Treatment

- Avoid photosensitizing chemicals
- Apply moderate potency topical corticosteroid 2–3 times daily for 2–3 weeks
- Over-the-counter bleaching creams with hydroquinone may be helpful for postinflammatory hyperpigmentation, although usually not needed

### Prognosis

- Excellent; lesions fade slowly

### References

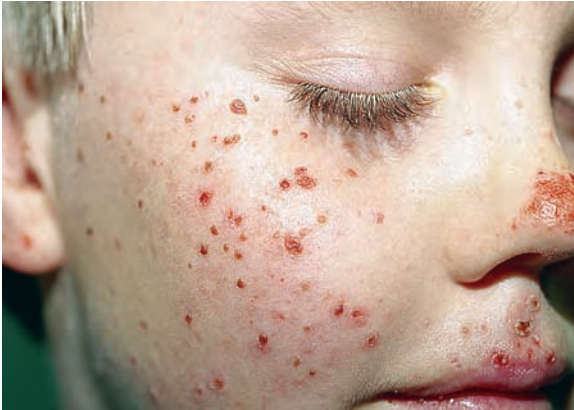- Bowers AG. Phytophotodermatitis. *Am J Contact Dermatitis* 1999; 10: 89–93
- Coffman K, Boyce WT, Hansen RC. Phytophotodermatitis simulating child abuse. *Am J Dis Child* 1985; 139: 239–40
- Goskowitz MO, Friedlander SE, Eichenfield LF. Endemic 'Lime' disease: phytophotodermatitis in San Diego County. *Pediatrics* 1994; 93: 828–30
- Solis RR, Dotson DA, Trizna Z. Phytophotodermatitis: a sometimes difficult diagnosis. *Arch Fam Med* 2000; 9: 1195–6

## Polymorphous light eruption

### Major points

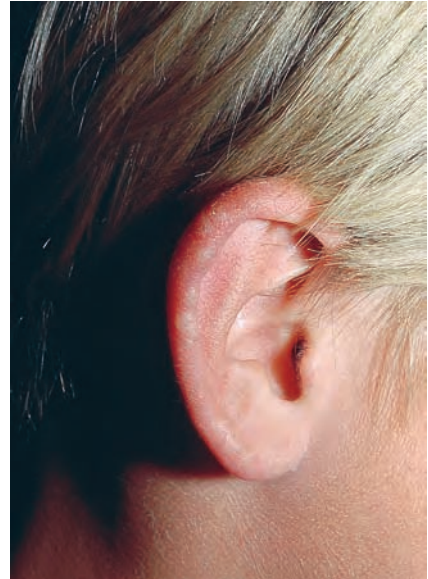- Broad term for a group of sun-sensitive disorders which have distinct clinical patterns
- Four major types:
  1. Papular polymorphous light eruption (PMLE)
    - a. Most common type, manifests as a papular, itchy dermatitis beginning in spring and tending to improve throughout summer (Figure 12.4)
    - b. Sudden onset of pruritic, discrete, erythematous papules and plaques





**Figure 12.4** Polymorphous light eruption – vesicles on the face

- c. Begins within hours to days of sun exposure
- d. Lasts 1–7 days
- e. Not scarring
- f. Not all areas of sun exposure affected
- g. Female/male ratio >1
- h. Some improvement or resolution with time
2. Actinic prurigo (Hutchinson summer prurigo)
  - a. Most commonly seen in school-aged children
  - b. More common in Native Americans
  - c. Dermatitis starts in the early spring with acute itchy facial and forearm dermatitis with edematous papules and vesicles
  - d. With time, crusting, thickening and lichenification
  - e. Eruption clears, only to recur the next spring; however, some children have the eruption all year
  - f. Chronic cheilitis, especially of the lower lip
  - g. Autosomal dominant in some families
3. Juvenile spring eruption (hydroa aestivale)
  - a. Primarily seen in northern European boys, aged 5–12 years
  - b. Discrete papules of 2–3 mm or vesicles on ears and cheeks lasting about a week (Figure 12.5)
  - c. Tends to recur each spring
  - d. Some patients develop more typical papular PMLE



**Figure 12.5** Juvenile spring eruption – limited to the ears

4. Hydroa vacciniforme
  - a. Discrete, deep-seated vesicles on ears, nose and face which lead to hemorrhage and scarring
  - b. Lesions last up to 4 weeks
  - c. Occasional keratitis and uveitis
  - d. Begins before age 10 years
  - e. Male/female ratio >1
  - f. Rare

#### *Pathogenesis*

- Considered to be caused by delayed-type hypersensitivity response to a UV radiation-induced antigen
- One-quarter of affected individuals sensitive to UVB alone, one-quarter to UVB and UVA together, and one-half to UVA only
- Probably genetic, with incomplete expression and penetrance

#### *Diagnosis*

- Suspect diagnosis on clinical basis. Biopsy or phototesting may be needed
- Histology shows:
  1. Superficial and deep lymphocytic infiltrate
  2. Papillary dermal edema and hemorrhage
  3. Variable epidermal changes

4. Spongiotic dermatitis resembling eczema
5. Late lesions demonstrate chronic infiltration of lymphocytes and spongiosis

### *Differential diagnosis*

- Atopic dermatitis
- Contact dermatitis
- Systemic lupus erythematosus
- Erythropoietic protoporphyria
- Sunburn/phototoxicity
- Photoallergic reactions
- Tinea corporis
- Drug-induced photosensitivity
- Solar urticaria

### *Treatment*

- Sun avoidance
- Restriction of daily activities outdoors between 10.00 and 16.00 (peak UV times)
- Clothing: wide-brimmed hat, long-sleeved shirt and sunscreens
- Topical corticosteroids in an ointment vehicle 2–3 times a day
- Wet dressings for acute weeping lesions
- Treatment of secondary bacterial infection if present
- $\beta$ -carotene (Solatene) 60–180 mg/day for an adult
- For severe cases, oral psoralen plus UVA (PUVA) under controlled conditions may help induce hardening
- Frequent follow-up visits if dermatitis is not under control; less frequent as child improves
- Hydroxychloroquine (Plaquenil®) 100–200 mg BID (adult dose) for severe cases

### *Prognosis*

- Variable; some patients may improve with time or with chronic sun exposure; however, many patients continue to have symptoms

### *References*

Boonstra HE, van Weelden H, Toonstra J, van Vloten WA. Polymorphous light eruption: a clinical, photobiologic, and follow-up study of 110 patients. *J Am Acad Dermatol* 2000; 42: 199–207

Fusaro RM, Johnson JA. Hereditary polymorphic light eruption of American Indians: occurrence in non-Indians with polymorphic light eruption. *J Am Acad Dermatol* 1996; 34: 612–17

Hann SK, Im S, Park Y-K, Lee S. Hydroa vacciniforme with unusually severe scar formation: diagnosis by repetitive UVA phototesting. *J Am Acad Dermatol* 1991; 25: 401–3

Hasan T, Ranki A, Jansen CT, Karvonen J. Disease associations in polymorphous light eruption. *Arch Dermatol* 1998; 134: 1081–5

Leenutaphong V. Hydroa vacciniforme: an unusual clinical manifestation. *J Am Acad Dermatol* 1991; 25: 892–5

Patel DC, Bellaney GJ, Seed PT, et al. Efficacy of short-course oral prednisolone in polymorphic light eruption: a randomized controlled trial. *Br J Dermatol* 2000; 143: 828–31

Rhodes LE. Polymorphic light eruption reassessed. *Arch Dermatol* 2004; 140: 351–2

van de Pas CB, Hawk JL, Young AR, Walker SL. An optimal method for experimental provocation of polymorphic light eruption. *Arch Dermatol* 2004; 140: 286–92

Van Praag MCG, Boom BW, Vermeer BJ. Diagnosis and treatment of polymorphous light eruption. *Int J Dermatol* 1994; 33: 233–8

## **Solar urticaria**

### *Major points*

- Pruritic wheals occur within minutes of sun exposure and last <24 hours
- Locations on sun-exposed areas
- Onset usually >10 years of age
- Tolerance (i.e. ‘hardening’) can occur after repeated exposure
- Onset usually between 10 and 50 years of age
- Slight female predominance

### *Pathogenesis*

- Allergic response to photo-induced allergen
- Mast cells play a major role
- Types of solar urticaria based on action spectra: usually visible light, but UVA and UVB or combinations may be responsible

### *Diagnosis*

- Clinical characteristics
- Histology: similar to urticaria with dermal edema, perivascular neutrophilic and eosinophilic infiltrates

### *Differential diagnosis*

- Urticaria
- Polymorphous light eruption

- Porphyria
- Drug reactions

### *Treatment*

- Sun avoidance with clothing and sunscreens
- Nonsedating antihistamines
- Systemic steroids (short course for 5–10 days) initially may be helpful
- PUVA may induce tolerance

### *Prognosis*

- May be chronic and intermittent

### *References*

Beattie PE, Dawe RS, Ibbotson SH, Ferguson J. Characteristics and prognosis of idiopathic solar urticaria: a cohort of 87 cases. *Arch Dermatol* 2003; 139: 1149–54

Grabbe J. Pathomechanisms in physical urticaria. Symposium Proceedings. *J Invest Dermatol* 2001; 6: 135–6

Roelandts R. Diagnosis and treatment of solar urticaria. *Dermatol Ther* 2003; 16: 52–6

## **GENODERMATOSES WITH SUN SENSITIVITY**

### **Porphyria**

#### *Major points*

- Group of disorders of porphyrin metabolism which can have sun sensitivity as a primary feature (Table 12.3)
- Erythropoietic protoporphyria (EPP)
  1. Most common type in children
  2. Usually presents in preschool child with burning, itching or stinging of skin after short exposure to sun, even through window glass
  3. Younger children may be irritable but may not have typical skin lesions
  4. Intense sun exposure may result in severe facial edema, urticaria, vesiculation and crusting
  5. Chronic changes: thickened skin-colored papules on the dorsal hands, and pitted scarring on nose and face (Figures 12.6 and 12.7)
  6. Perioral linear papules may result from previous vesicular damage

#### *Pathogenesis*

- Caused by enzyme defects in heme biosynthesis which lead to blockade of porphyrin

pathway and accumulation of porphyrins and precursors

- Porphyrin molecules absorb visible light and generate molecular level excited states leading to free radical formation with subsequent cell membrane damage and cell death

### *Diagnosis*

- Histology: thickening of superficial blood vessels and a perivascular deposit of periodic acid-Schiff (PAS)-positive material which, on direct immunofluorescence, contains IgG
- Blood, urine and stool porphyrin levels have characteristic patterns

### *Differential diagnosis*

- Phototoxicity
- Photoallergic reactions
- Polymorphous light eruption
- Solar urticaria
- Contact dermatitis

### *Treatment*

- Sun avoidance with clothing and sunscreens blocking UVA (physical sunscreens with titanium dioxide are best)
- $\beta$ -carotene (Solatene) 60–180 mg/day may be helpful
- Because of potential chronic liver changes, liver function tests should be followed every 6–12 months
- Genetic counseling advised. Family members should be screened and liver functions followed
- Low-dose hydroxychloroquine

### *Prognosis*

- Chronic, life-long sun sensitivity, skin damage and possible liver disease

### *References*

Ahmed I. Childhood porphyrias. *Mayo Clin Proc* 2002; 77: 825–36

Bruce AJ, Ahmed I. Childhood-onset porphyria cutanea tarda: successful therapy with low-dose hydroxychloroquine (Plaquenil). *J Am Acad Dermatol* 1998; 38: 810–14

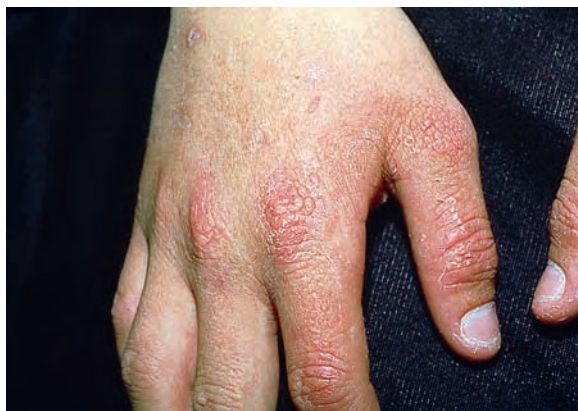Cummins R, Wagner-Weiner L, Paller A. Pseudoporphyria induced by celecoxib in a patient with juvenile rheumatoid arthritis. *J Rheumatol* 2000; 27: 2938–40

De Silva B, Banney L, Uttley W, et al. Pseudoporphyria and nonsteroidal antiinflammatory agents in children with juvenile idiopathic arthritis. *Pediatr Dermatol* 2000; 17: 480–3

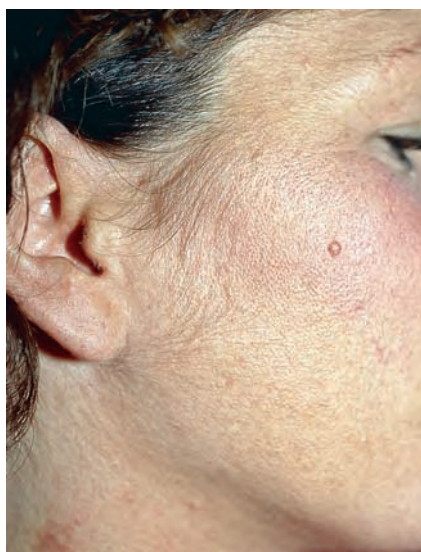**Table 12.3 Porphyrrias**

<i>Type</i>	<i>Characteristics</i>	<i>Gene</i>	<i>Laboratory investigations</i>
Erythropoietic porphyria (EP)	Begins in infancy Marked photosensitivity with pain Vesicles, bullae Hypertrichosis Mutilating scars Hemolytic anemia Splenomegaly Erythrodontia	Uroporphyrinogen III synthetase (UROS) Gene locus: 10q25.2-q26.3 Autosomal recessive	Urine: elevated URO I, COPRO I Urine: fluorescent Stool: elevated COPRO I Blood: fluorescent RBCs
Erythropoietic protoporphyria (EPP)	Onset in first decade Mild to severe photosensitivity Burning, stinging after sun exposure Edematous plaques with erythema, purpura Waxy or depressed scars on nose, dorsal hands Liver: cholelithiasis, hepatic failure	Ferrochelatase (FECH) Gene locus: 18q21.3 Autosomal dominant	Blood: elevated FEP Blood: elevated RBC & plasma PROTO Blood: fluorescent RBCs Urine: normal porphyrins Stool: elevated PROTO
Acute intermittent porphyria (AIP)	Onset 2nd to 4th decade No photosensitivity Recurrent attacks of abdominal pain, weakness, neuropathy, behavioral changes Attacks precipitated by drugs, events	PBG deaminase Gene locus: 11q23.3 Autosomal dominant	Urine: elevated ALA, PBG during attacks Stool: ALA, PBG during attacks Blood: plasma neg, RBC neg
Porphyria cutanea tarda (PCT)	Onset in 3rd to 4th decade Moderate photosensitivity Bullae, fragility, scars, milia, hyperpigmentation, facial hypertrichosis Precipitated by alcohol, estrogens, iron, hydrocarbons Liver iron overload	Uroporphyrinogen decarboxylase (UROD) Gene locus: 1p34 Autosomal dominant or sporadic	Urine: URO I>III, ISOCOPRO Stool: ISOCOPRO>PROTO Plasma + RBC neg
Variegate porphyria (VP)	Onset 2nd to 3rd decade Photosensitivity similar to PCT Acute attacks similar to AIP Common in South Africa	Protoporphyrinogen oxidase Gene locus: 1q22, 6p21.3 Autosomal dominant	Urine: ALA and PBG elevated during attacks Urine: elevated URO & COPRO between attacks Stool: PROTO>COPRO both elevated during and between attacks
Hereditary coproporphyria (HCP)	Onset any age Skin lesions resemble PCT but milder Attacks like AIP but milder	Coproporphyrinogen oxidase Gene locus: 3q12 Autosomal dominant	Stool: COPRO III elevated during and between attacks Urine: COPRO III elevated during and between attacks Elevated ALA, PBG only during attacks

ALA, delta-aminolevulinic acid; PBG, porphobilinogen; URO, uroporphyrin; COPRO, coproporphyrin; PROTO, protoporphyrin; ISOCOPRO, isocoproporphyrin; RBCs, red blood cells; FEP, free erythrocyte protoporphyria



**Figure 12.6** Erythropoietic protoporphyria – scars on hands



**Figure 12.7** Porphyria cutanea tarda – hypertrichosis on the face

Fritsch C, Bolsen K, Ruzicka T, Goerz G. Congenital erythropoietic porphyria. *J Am Acad Dermatol* 1997; 36: 594–610

Gross U, Hoffmann GF, Doss MO. Erythropoietic and hepatic porphyrias. *J Inherit Metab Dis* 2000; 23: 641–61

Huang J-L, Zaider E, Roth P, et al. Congenital erythropoietic porphyria: clinical, biochemical, and enzymatic profile of a severely affected infant. *J Am Acad Dermatol* 1996; 34: 924–7

LaDuca JR, Bouman PH, Gaspari AA. Nonsteroidal antiinflammatory drug-induced pseudoporphyria: a case series. *J Cutan Med Surg* 2002; 6: 320–6

Paller AS, Eramo LR, Farrell EE, et al. Purpuric phototherapy-induced eruption in transfused neonates: relation to transient porphyrinemia. *Pediatrics* 1997; 100: 360–4

Pandhi D, Suman M, Khurana N, Reddy BSN. Congenital erythropoietic porphyria complicated by squamous cell carcinoma. *Pediatr Dermatol* 2003; 20: 498–501

Poh-Fitzpatrick MB, Wang X, Anderson KE, et al. Erythropoietic protoporphyria: altered phenotype after bone marrow transplantation for myelogenous leukemia in a patient heteroallelic for ferrochelatase gene mutations. *J Am Acad Dermatol* 2002; 46: 861–6

## Xeroderma pigmentosum

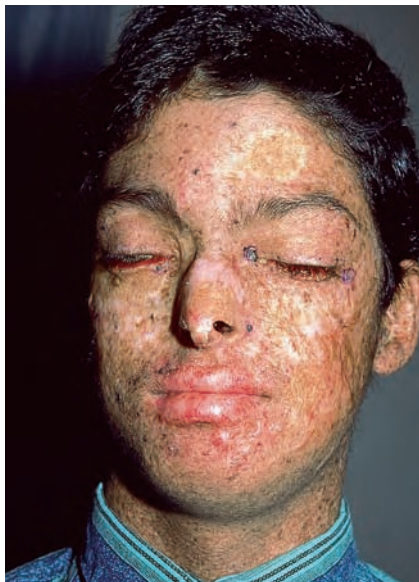### Major points

- Presents in infancy with extreme sun sensitivity
- By 18 months of age, early sunburn reactions and freckling are evident after minimal sun exposure (Figure 12.8)
- Sunburn reactions persist for weeks
- Telangiectasias and atrophy of skin
- Actinic keratoses develop as red, scaly persistent macules and papules on sun-exposed areas
- In darker skinned patients, findings may be more subtle
- By 6–8 years, multiple basal cell carcinomas, squamous cell carcinomas and malignant melanoma are common
- Ocular findings, particularly photophobia and decreased vision, occur in ~20%
- Mild to severe mental retardation, especially evident in De Sanctis–Cacchione syndrome

### Pathogenesis

- Defective repair of ultraviolet radiation damage to pyrimidine dimers in DNA in many cell types (e.g. epidermal cells, fibroblasts, lymphocytes, corneal cells, liver cells)
- Group A: most severe form; exhibits skin and central nervous system disorders (severe or mild) (DeSanctis–Cacchione syndrome); gene locus/gene: 9q22.3/ XPA
- Group B: gene locus/gene: 2q21/ ERCC3, XPB
- Group C: usually have only skin disorders; most common in USA, Europe, Egypt; gene locus/gene: 3p25/ XPC





**Figure 12.8** Xeroderma pigmentosum – multiple lentigines and scarring from previous skin cancer removal

- Group D: skin cancer, CNS disorders; may have Cockayne syndrome or trichothiodystrophy; gene locus/gene: 19q13.2-q13.3/ ERCC2, EM9
- Group E: few skin cancers, excision repair 40–50% of normal, gene locus: 11p12-p11
- Group F: mild skin symptoms, excision repair 10–20% of normal; gene locus: 16p13.3-p13.13; gene: ERCC4
- Group G: mental retardation, neurological abnormalities, photosensitivity, excision repair <5% of normal; gene locus: 13q33, gene: ERCC5

### Diagnosis

- Sub-typing can be done in certain laboratories by studying the DNA repair mechanisms after UV light exposure in the clinical setting of XP

### Differential diagnosis

- Multiple lentigines syndrome (LEOPARD syndrome)
- Erythropoietic protoporphyria
- Basal cell nevus syndrome

### Treatment

- Treatment is symptomatic, with removal of skin cancers
- Early biopsy of suspicious lesions

- Prevention with complete sun avoidance: sun protective clothing, sunscreens, and night time habits of outdoor activities
- Should ideally be followed at a center which is familiar with this condition and treatment of skin cancers
- Frequent visits are important to evaluate incipient tumors

### Prognosis

- Prognosis is poor. Morbidity from chronic skin cancers requiring surgery. Early death from metastatic skin cancer or melanoma. Some types have a better prognosis

### References

- Bootsma D, Hoeijmakers JHJ. The genetic basis of xeroderma pigmentosum. *Ann Genet* 1991; 34: 143–50
- Cleaver JE, Thompson LH, Richardson AS, States JC. A summary of mutations in the UV-sensitive disorders: xeroderma pigmentosum, Cockayne syndrome, and trichothiodystrophy. *Hum Mutat* 1999; 14: 9–22
- Kraemer KH, Lee MM, Scotto J. Xeroderma pigmentosum. Cutaneous, ocular, and neurologic abnormalities in 830 published cases. *Arch Dermatol* 1987; 123: 241–50
- Sary A, Sarasin A. The genetics of the hereditary xeroderma pigmentosum syndrome. *Biochimie* 2002; 84: 49–60
- Tsao H. Genetics of nonmelanoma skin cancer. *Arch Dermatol* 2001; 137: 1486–92

## Cockayne syndrome

### Major points

- Premature aging
- Microcephaly
- Photosensitivity – scaly erythema, begins at 1 year of age
- Short stature
- Mental retardation (progressive)
- Disproportionately large hands, feet, ears
- Atrophy of subcutaneous facial fat with sunken eyes
- Ocular defects
- Flexion contractures
- Short life span
- Autosomal recessive
- Gene locus/gene:
  1. Type 1: chromosome 5/ERCC8, CKN1
  2. Type 2: chromosome 10q11/ERCC6, CKN2

## References

- Berneburg M, Lehmann AR. Xeroderma pigmentosum and related disorders: defects in DNA repair and transcription. *Adv Genet* 2001; 43: 71–102
- Licht CL, Stevnsner T, Bohr VA. Cockayne syndrome group B cellular and biochemical functions. *Am J Hum Genet* 2003; 73: 1217–39

## Bloom syndrome

### Major points

- Short stature (prenatal onset)
- Telangiectatic facial erythema (butterfly distribution)
- Photosensitivity (not true poikiloderma)
- Hypogonadism
- High incidence of malignancy, especially leukemias, lymphomas, gastrointestinal tract cancer
- Increased susceptibility to infections
- Autosomal recessive
- Male/female ratio >1
- Gene locus: 15q26.1
- Gene: BLM, RECQ3 helicase; protein product is member of DNA helicase

### References

- Chisholm CA, Bray MJ, Karns LB. Successful pregnancy in a woman with Bloom syndrome. *Am J Med Genet* 2001; 102: 136–8
- Duker NJ. Chromosome breakage syndromes and cancer. *Am J Med Genet* 2002; 115: 125–9
- Duker NJ. Chromosome breakage syndromes and cancer. *Am J Med Genet* 2002; 115: 125–9
- Franchitto A, Pichierri P. Protecting genomic integrity during DNA replication: correlation between Werner's and Bloom's syndrome gene products and the MRE11 complex. *Hum Mol Genet* 2002; 11: 2447–53
- Siegel DH, Howard R. Molecular advances in genetic skin diseases. *Curr Opin Pediatr* 2002; 14: 419–25

## Rothmund–Thomson syndrome

Synonym: poikiloderma congenitale

### Major points

- Generalized poikiloderma, begins in infancy and progresses until age 3–5 years; lesions begin as red

edematous plaques sometimes accompanied by blistering

- Photosensitivity
- Ocular abnormalities
- Hyperkeratoses of palms, soles, hands, wrists, ankles and elsewhere (squamous cell carcinoma may develop)
- Scalp hair sparse and fine, may progress to partial or total alopecia
- Short stature (<4 feet) (<1.2 m)
- Autosomal recessive (female/male ratio >1)
- Gene locus: 8q24.3
- Gene: RECQL4 (DNA helicase)

### References

- Collins P, Barnes L, McCabe M. Poikiloderma congenitale: case report and review of the literature. *Pediatr Dermatol* 1991; 8: 58–60
- Duker NJ. Chromosome breakage syndromes and cancer. *Am J Med Genet* 2002; 115: 125–9
- Furuichi Y. Premature aging and predisposition to cancers caused by mutations in RecQ family helicases. *Ann NY Acad Sci* 2001; 928: 121–31
- Hickson ID. RecQ helicases: caretakers of the genome. *Nature Rev Cancer* 2003; 3: 169–78
- Kitao S, Shimamoto A, Goto M, et al. Mutations in RECQL4 cause a subset of cases of Rothmund–Thomson syndrome. *Nature Genet* 1999; 22: 82–4
- Vennos EM, Collins M, James WD. Rothmund–Thomson syndrome: review of the world literature. *J Am Acad Dermatol* 1992; 27: 750–62

## Pellagra – vitamin B<sub>3</sub> (niacin) deficiency

### Major points

- Four D's: Diarrhea, Dementia, Dermatitis (on sun-exposed areas, angular stomatitis, glossitis, oral and perirectal sores), Death
- Causative drugs/factors: isoniazid, sulfonamides, anticonvulsants, antidepressants, plain corn diet (niacin not bioavailable), gastrointestinal disease (malabsorption), carcinoid syndrome, Hartnup disease

### References

- Karthikeyan K, Thappa DM. Pellagra and skin. *Int J Dermatol* 2002; 41: 476–81

Tyler I, Wiseman MC, Crawford RI, Birmingham CL. Cutaneous manifestations of eating disorders. *J Cutan Med Surg* 2002; 6: 345–53

## COLD INJURIES

### Pernio

Synonym: chilblains

#### Major points

- Abnormal inflammatory response to cold, damp, nonfreezing conditions
- May be associated with cryoglobulins
- Clinical:
  1. Single or multiple erythematous to violaceous macules, papules or nodules; rare blistering (Figure 12.9)
  2. Distribution: symmetrical on distal toes and fingers; less often on heels, nose and ears
- Pathogenesis unknown but thought to be of vascular origin
- Histology: nonspecific with papillary dermal edema, superficial and deep perivascular infiltrate comprising of lymphocytes

#### Treatment

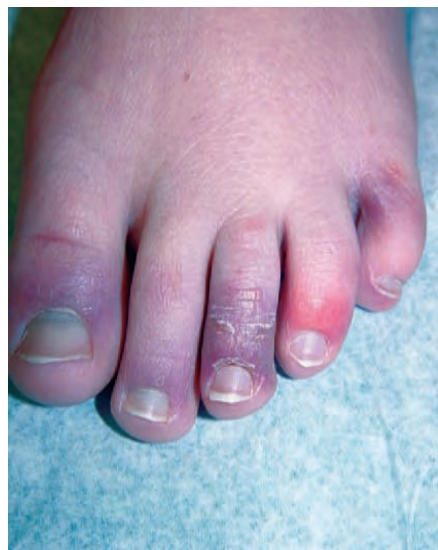- Warming the affected area
- Takes 1–2 weeks to recover

#### Differential diagnosis

- Systemic lupus erythematosus
- Leukemia
- Trauma
- Cryoglobulinemia

#### References

- Goette DK. Chilblains (perniosis). *J Am Acad Dermatol* 1990; 23: 257–62
- Klapman MH, Johnston WH. Localized recurrent postoperative pernio associated with leukocytoclastic vasculitis. *J Am Acad Dermatol* 1991; 24: 811–13
- Weston WL, Morelli JG. Childhood pernio and cryoproteins. *Pediatr Dermatol* 2000; 17: 97–9
- White KP, Rother MJ, Milanese A, Grant-Kels JM. Perniosis in association with anorexia nervosa. *Pediatr Dermatol* 1994; 11: 1–5



**Figure 12.9** Pernio – erythematous painful nodules after cold exposure

### Frostbite

#### Major points

- Erythema, edema, numbness initially followed by hyperemia and pain with re-warming
- Locations: usually nose, ears, fingertips, toes
- Ranges from first-degree frostbite to fourth-degree frostbite with full thickness loss of skin, muscle, tendon and bone

#### Pathogenesis

- Occurs when skin temperature drops below  $-2^{\circ}\text{C}$
- Combination of tissue freezing and vasoconstriction with damage due to inflammatory mediators

#### Diagnosis

- Clinical diagnosis: easily recognizable
- Histology: superficial dermal edema, subepidermal bullae, hemorrhage, necrosis

#### Treatment

- Rapid re-warming with water bath  $\sim 40^{\circ}\text{C}$

#### References

- Biem J, Koehncke N, Classen D, Dosman J. Out of the cold: management of hypothermia and frostbite. *Can Med Assoc J* 2003; 168: 305–11

Huh J, Wright R, Gregory N. Localized facial telangiectasias following frostbite injury. *Cutis* 1996; 57: 97–8

Murphy JV, Banwell PE, Roberts AH, McGrouther DA. Frostbite: pathogenesis and treatment. *J Trauma-Injury Infect Crit Care* 2000; 48: 171–8

Nissen ER, Melchert PJ, Lewis EJ. A case of bullous frostbite following recreational snowmobiling. *Cutis* 1999; 63: 21–2

## CHILD ABUSE

### General

- Dr C. Henry Kempe in 1962 described ‘battered child syndrome’
- Child abuse encompasses: physical abuse, neglect, sexual exploitation
- Physical abuse is the nonaccidental injury of a child
- Statistics: >2 million children abused in USA per year; 55% neglect, 27% physical, 16% sexual, 8% emotional
- Many teens run away from home
- 1200–1300 fatalities per year; 50% are <1 year old

### Major points

- Victim usually 1–5 years of age, considered the ‘vulnerable child’; often preverbal or handicapped
- No predilection for sex, race, social class, or income
- Morbidity is both physical and mental, with 25–30% permanent
- Tends to be self-propagating (i.e. one generation to the next)
- Mortality overall 3–4%, caused by head trauma, or abdominal organ rupture
- Classification of abuse:
  1. Definite abuse: definite act causing harm to child
    - a. Seen by eyewitness
    - b. Physical examination
    - c. Skeletal survey
  2. Probable abuse: most information indicates an act of commission but was not beyond reasonable doubt; unlikely to be the result of an accident
  3. Household violence: not directed at a child

4. Neglect: complete lack of parental supervision; inadequate food, shelter, clothing
5. Medical neglect: inadequate medical care
6. Accident: unpreventable by reasonable parental supervision
7. Accident resulting from neglect: could have been prevented by reasonable parental supervision (e.g. more than one accidental poisoning)
- Cutaneous manifestations:
  1. Incidence 80–100% of child abuse cases
  2. Unusual findings should make one suspect abuse
    - a. Lacerations in a child less than 1 year of age to the face or genitals
    - b. Forced ingestions
  3. Common manifestations
    - a. Bruises (blunt trauma)
      - i Child <1 year, especially facial bruises
      - ii Unusual location (upper lip with torn frenulum, or back of buttocks)
      - iii Multiple bruises
      - iv Pinch marks on penis or ears
      - v Age of bruise is determined by color. Fresh–3 days: reddish blue, purple, black; 7–10 days: greenish yellow; >8 days: yellow brown; 2–4 weeks: resolution
      - vi Linear bruising from rod or stick
      - vii Loop marks such as small ropes, cords, belts (Figure 12.10)
      - viii Normal (not abuse) bruises are common and found on shins, knees, elbows
    - b. Imprints
      - i Buckles
      - ii Slap imprints of fingers
      - iii Human bites cause crushing injuries, not puncture wounds
    - c. Binding or gagging around the ankles, wrists, or mouth means perpetrators are mentally disturbed
    - d. Traumatic alopecia – hair pulled or yanked
    - e. Thermal burns (Figure 12.11)
      - i 4–8% of childhood burn patients have been abused
      - ii 28% of tap water burn victims have been abused
      - iii Hot water dunking
      - iv Cigarette burns
      - v Microwave injuries (baby placed into the microwave oven causes injury to the





10. Sleep disturbances
11. Suicide gestures
12. Substance abuse
13. Urinary tract infection
14. Vaginal bleeding or discharge
- Symptoms of noncutaneous child abuse:
  1. Head injury
  2. Shaking injuries
  3. Abdominal injury (kicking, slamming against an object)

### *Pathogenesis*

- Nonaccidental injury to a child

### *Diagnosis*

- Maintain a high index of suspicion
- Suspect child abuse in the following circumstances:
  1. Physical features
  2. Unusual behavior
  3. Family characteristics
  4. Actions of parents
- Clues which aid in diagnosis
  1. Injury inconsistent with history
  2. Changing history
  3. Delay in seeking medical attention
  4. Evidence of neglect
  5. Injury blamed on someone else
  6. Evidence of doctor shopping
  7. Extremely passive or fearful child
  8. High-risk family situation
    - a. History of abuse to parent, sibling or patient
    - b. Disorganized family relationships
    - c. Parental history of drug or alcohol abuse or psychosis
    - d. Child perceived as 'special'. Parent thinks the child 'deserves what he gets'
    - e. No family support systems

### *Differential diagnosis*

(See Table 12.4)

### *Treatment*

- Evaluation and acute management (Table 12.5)
- Criteria for suspecting child abuse (Tables 12.6–12.8)
- Physicians are mandated to report child abuse or sexual abuse in all 50 states in the USA
  1. Report to child protective services

2. Anticipate hostility and explain your role as a child's advocate
3. Good photographs are imperative to document injuries
  - Treat sexually transmitted diseases
  - Refer for psychological counseling, social services
  - Testify in court if necessary
  - Provide support and follow-up care for the patient and family

### *Prognosis*

- Poor prognosis unless intervention occurs
- Can be self-perpetuating in subsequent generations

### *References*

- American Academy of Pediatrics, and American Academy of Pediatric Dentistry. Oral and dental aspects of child abuse and neglect. *Pediatrics* 1999; 104: 348
- Bar-on ME, Zanga JR. Child abuse: a model for the use of structured clinical forms. *Pediatrics* 1996; 98: 429–33
- Carroll ST, Riffenburgh RH, Roberts TA, Myhre EB. Tattoos and body piercings as indicators of adolescent risk-taking behaviors. *Pediatrics* 2002; 109: 1021–7
- Cohen JA, Mannarino AP, Zhitova AC, Capone ME. Treating child abuse-related posttraumatic stress and comorbid substance abuse in adolescents. *Child Abuse Neglect* 2003; 27: 1345–65
- Dubowitz H, Black M, Harrington D. The diagnosis of child sexual abuse. *Am J Dis Child* 1992; 146: 688–93
- Duhaime A-C, Christian CW, Rorke LB, Zimmerman RA. Nonaccidental head injury in infants – the 'shaken-baby syndrome'. *N Engl J Med* 1998; 338: 1822–9
- Gutman LT, Herman-Giddens ME, Phelps WC. Transmission of human genital papillomavirus disease: comparison data from adults and children. *Pediatrics* 1993; 91: 31–8
- Kivlahan C, Druse R, Furnell D. Sexual assault examinations in children. *Am J Dis Child* 1992; 146: 1365–70
- Ledbetter EO. An ethical approach to intervention/prevention of child maltreatment. *Adv Pediatr* 2003; 50: 215–29
- Raimer BG, Raimer SS, Hebeler JR. Cutaneous signs of child abuse. *J Am Acad Dermatol* 1981; 5: 203–12
- Schachner LA, Hankin D. Assessing child abuse in the dermatologist's office. *Adv Dermatol* 1988; 3: 61–74
- Stiffman MN, Schnitzer PG, Adam P, et al. Household composition and risk of fatal child maltreatment. *Pediatrics* 2002; 109: 615–21
- Wissow LS. Child abuse and neglect. Review. *N Engl J Med* 1995; 332: 1425–31

**Table 12.4 Differential diagnosis of child abuse**

<i>Clinical findings</i>	<i>Differential diagnosis</i>	<i>Differential tests</i>
Bruising	Trauma Hemophilia Von Willebrand disease Henoch–Schönlein purpura Purpura fulminans Ehlers–Danlos syndrome	Skin biopsy Partial thromoplastin time Bleeding time Rule out sepsis, and other causes of vasculitis Rule out sepsis with cultures Hyperextensibility of joints
Local erythema or bullae	Thermal burn Staphylococcal impetigo Bacterial cellulitis Pyoderma gangrenosum Photosensitivity/phototoxicity Frostbite Herpes simplex or zoster Epidermolysis bullosa Contact dermatitis, allergic or irritant Lichen sclerosis Vulvar pemphigoid	History Culture, Gram stain Culture, Gram stain Culture, Gram stain, biopsy History of sensitizing agent (oral or topical) Clinical history and characteristics Tzanck smear, viral culture Skin biopsy, family history Clinical characteristics, patch testing  Clinical characteristics, skin biopsy Skin biopsy, direct immunofluorescence

## DERMATITIS ARTEFACTA

Synonym: factitial dermatitis

### Major points

- Created by self-induced lesions of the skin
- Motive is usually subconscious
- Female/male ratio >1
- Single or multiple skin lesions range from vesicles to purpura, often with bizarre or unnatural appearance and angulated borders (Figures 12.12 and 12.13)
- Patient usually denies doing it
- Munchausen syndrome by proxy
  1. Caused by parent inflicting injury on the child
  2. Readily seeks medical advice, multiple doctors
  3. Parent never leaves the bedside
  4. Perplexing problem to physicians
  5. Unexplained fever, cellulitis, seizures
  6. Injuries caused by caustic solutions, fingernails or implements
  7. Blood in the urine, vomit, sputum

### Pathogenesis

- Psychocutaneous disorder where patients cause cutaneous lesions as a means to satisfy a psychological need of which they are not always consciously aware

**Table 12.5 Evaluation and management of the abused child**

Detailed history (medical and social)  
Physical examination  
Examine entire cutaneous surface (oral, rectal, genital mucosa, retina, tympanic membranes)  
Laboratory data (complete blood count, serology, appropriate cultures)  
Treatment of acute injuries or infections  
Radiographs (skeletal survey)  
Documentation in case records with photographs, diagrams, videos, as indicated  
Report to a local child protective service agency by telephone followed by a detailed written report  
Protection of the child from further injury

### Diagnosis

- Lesions can mimic any dermatosis
- Difficult to make a diagnosis; other primary skin disorders must be ruled out
- Histology: early signs of injury without inflammatory response; material injected; can vary

**Table 12.6 Checklist criteria for suspecting child abuse****Physical findings:**

Fresh bruises; unusual locations or shapes  
 Old scars; unusual locations or shapes  
 Past or current burns; unusual shapes  
 Signs of rectal, genital injury

**Medical experience, abuse or neglect suggested by:**

Current medical problems  
 Prior medical problems  
 Prior emergency visits – ingestions or trauma  
 Prior hospitalizations  
 Current or past venereal disease or pregnancy  
 Poor compliance  
 Incomplete immunizations  
 Poor physical or developmental growth

**Behavioral abnormalities with evidence of:**

Withdrawal  
 Overcompliance  
 Compliant posturing  
 Phobias  
 Sleep problems  
 Recent onset of enuresis or encopresis  
 Sexualized play  
 Excessive interest in genitalia  
 Inappropriate or excessive masturbation

**Psychosocial conditions with evidence of:**

Disturbed parent–child interaction  
 Violent interaction between parents  
 Violent interaction between siblings  
 Violent interaction with friends and relatives  
 Parents abused as children  
 Parents victims of sexual abuse  
 Extra stresses on the family: marital discord, unemployment, alcoholism, substance abuse, recent death or illness in the family

**Inappropriate custodial care of the child:**

Inappropriate responsibilities for a child

**Family isolation:**

Lack of supportive relatives, friends or neighbors

**Previous referrals for abuse or neglect**

Adapted from Schachner L, Hankin DE. Assessing child abuse in childhood condyloma acuminatum. *J Am Acad Dermatol* 1985; 12: 157–60

**Table 12.7 Findings specific for sexual abuse**

Presence of semen, sperm, or acid phosphatase  
 Pregnancy  
 Fresh genital or anal injuries (lacerations, hematomas, ecchymoses, petechiae) in the absence of an adequate accidental explanation  
 Positive test or culture for syphilis or gonorrhea (not perinatally acquired)  
 HIV infection (if not acquired perinatally or through intravenous route)  
 Markedly enlarged hymenal opening for age with associated findings of hymen disruption, including absent hymen, hymenal remnants, or scars in the absence of an adequate accidental or surgical explanation

**Table 12.8 Findings suggestive of sexual abuse**

Genital or anal *Trichomonas*, *Chlamydia*, condyloma acuminatum, herpes simplex type 2, if not perinatally acquired  
 Disruptions of hymen tissue, including posterior or lateral angular, absence, and scars  
 Anal scars outside the midline  
 Anal skin tags outside the midline  
 Anal dilatation >15–20 mm without stool in the ampulla  
 Irregularity of the anal orifice after complete dilatation  
 Marked dilatation of the hymenal opening, persisting in different examination positions

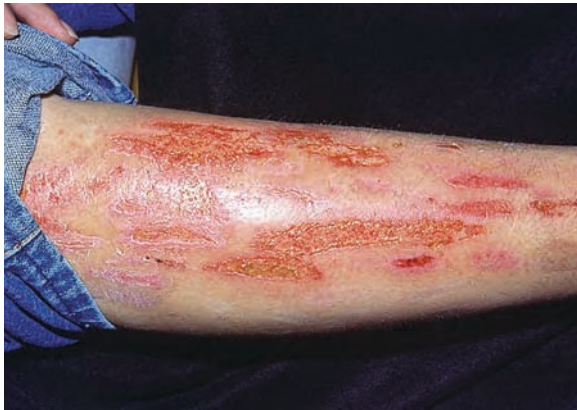widely depending upon how lesions were produced

**Treatment**

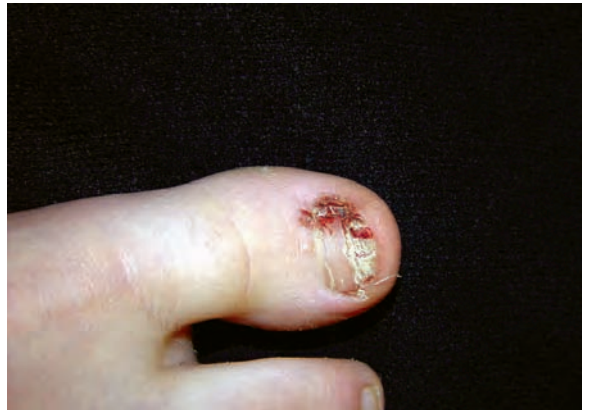- Symptomatic initially
- Psychology referral
- Oral antidepressants

**Prognosis**

- Best for children in whom the lesions represent a response to transient stress
- In chronic cases, severity can wax and wane



**Figure 12.12** Factitial lesions – linear lesions without any signs of dermatitis (published in *An Illustrated Dictionary of Dermatologic Syndromes* by SB Mallory and S Leal-Khoury)



**Figure 12.13** Habitual picking the great toenail

### References

- Driscoll MS, Rother MJ, Grant-Kels JM, Hale MS. Delusional parasitosis: a dermatologic, psychiatric, and pharmacologic approach. *J Am Acad Dermatol* 1993; 29: 1023–33
- Hettler J. Munchausen syndrome by proxy. *Pediatric Emerg Care* 2002; 18: 371–6
- Joe EK, Li VW, Magro CM, et al. Diagnostic clues to dermatitis artefacta. *Cutis* 1999; 63: 209–14
- Koblenzer CS. Dermatitis artefacta. Clinical features and approaches to treatment. *Am J Clin Dermatol* 2000; 1: 47–55
- Mallory SB, Leal-Khoury S. *An illustrated Dictionary of Dermatologic Syndromes*. Carnforth, UK: Parthenon Publishing, 1994
- Puig L, Perez M, Llauro A, et al. Factitial dermatosis of the breast: a possible dermatologic manifestation of Munchausen's syndrome. *Cutis* 1989; 44: 292–4

# DRUG ERUPTIONS

## GENERAL

- Drug reactions occur in 1–3% of all hospitalized patients
- Reactions can occur through allergic, metabolic or toxic mechanisms
- Patients with allergy to one medicine are at risk of developing other drug allergies
- Disease states may cause eruptions or act as cofactors (e.g. Epstein–Barr virus (EBV) and ampicillin, or HIV and trimethoprim–sulfamethoxazole)
- Predisposing factors
  1. Personal or family history of skin disease
  2. Environmental exposure to other etiologic agents (e.g. sunlight)
- Some drugs have a very low incidence of drug eruption (Table 13.1)

## TYPES OF REACTION

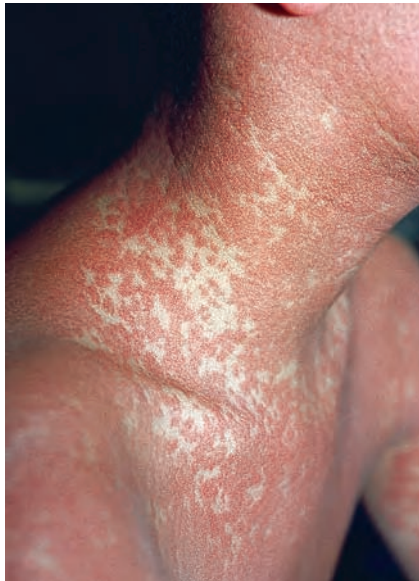### Morbilloform (maculopapular type) eruption

- Most common type of reaction causing ~40% of all reactions
- Symmetric erythematous blanchable macules and papules which coalesce into patches and plaques; can become pustular (Figures 13.1 and 13.2)
- Lesions tend to begin on extremities or in areas of pressure or trauma
- Variable involvement of mucous membranes, palms and soles

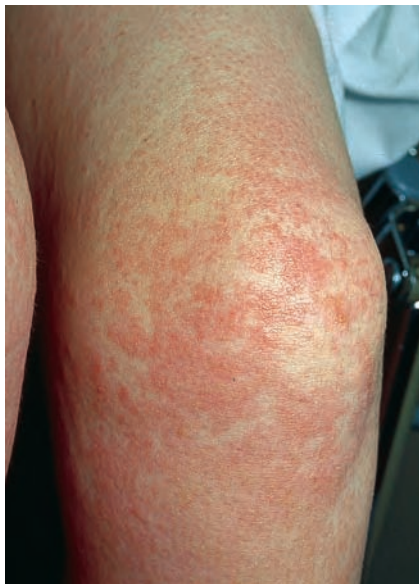**Table 13.1 Drugs with a low incidence of cutaneous reactions**

Acetaminophen
Acyclovir
Aspirin
Aminophylline
Atropine
Chloral hydrate
Chlorpromazine
Cimetidine
Codeine
Desloratadine (Claritin)
Digoxin
Diphenhydramine
Estrogens
Ferrous sulfate
Fexofenadine (Allegra)
Folic acid
Heparin
Hydroxyzine
Lidocaine hydrochloride
Magnesium sulfate
Methyldopa
Milk of magnesia
Morphine
Multivitamins
Nitroglycerin
Oral contraceptives
Potassium chloride
Prednisone/prednisolone
Promethazine hydrochloride
Propranolol
Regular insulin
Spiroglactone
Tetracycline
Warfarin sodium





**Figure 13.1** Morbilliform drug eruption from penicillin



**Figure 13.2** Morbilliform drug eruption from trimethoprim-sulfamethoxazole

- Usual time period between ingestion and drug eruption is 1–2 weeks
- Rash usually lasts 1–2 weeks
- Low-grade fever common
- Rash may not recur with rechallenge
- Main causes: Table 13.2

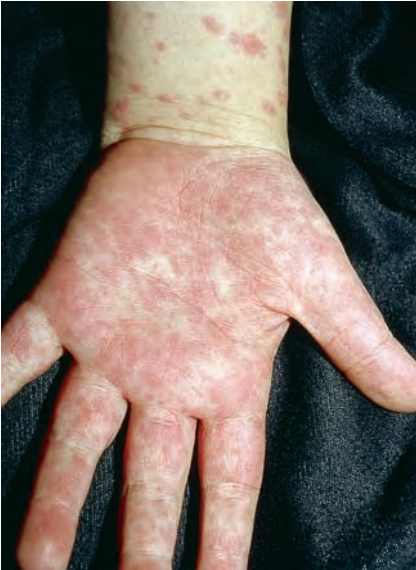**Table 13.2** Common causes of drug reactions

Amoxicillin
Amphotericin B
Ampicillin
Barbiturates
Blood products
Captopril
Carbamazepine
Cephalosporins
Chlorothiazide
Diazepam
Erythromycin
Furosemide
Gentamicin sulfate
Hydralazine
Hydrochlorothiazide
Isoniazid
Mercurial diuretics
Naproxen
Opiates
Penicillin
Phenytoin
Radiologic dyes
Thiazides
Trimethoprim-sulfamethoxazole

1. Ampicillin (patients with infectious mononucleosis have an incidence of >50%)
2. Trimethoprim-sulfamethoxazole (incidence >60% in HIV patients)
3. Penicillin derivatives
4. Antiepileptic drugs

## Urticaria

- Red wheals occur which are very pruritic, ranging in size from pinpoint to >20 cm and last <24 hours (Figure 13.3)
- Immediate reactions: reactions occur within minutes to hours
- Accelerated reactions: reactions occur 12–36 hours after exposure
- Angioedema (deep dermal swelling) may involve mucous membranes
- Anaphylaxis can occur with subsequent administration of the offending drug
- Caused by the degranulation of mast cells with release of histamine and other mediators
- Most common offending drugs causing urticaria:
  1. Penicillins



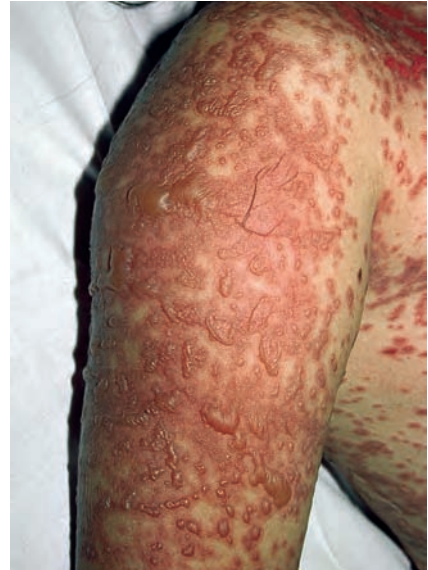**Figure 13.3** Urticarial drug eruption involving palms and soles

2. Cephalosporins
3. Sulfonamides
4. Blood products
5. Radiographic dyes
6. Opiates
7. Curare
8. Aspirin
9. Nonsteroidal anti-inflammatory agents
10. Benzoates (in foods)
11. Food dyes (FD&C yellow dye no. 5)

## Erythema multiforme

See Chapter 11

- Hypersensitivity caused by a drug, infection (e.g. herpes simplex or mycoplasma) or other cause
- Target-shaped lesions with urticaria or bullae (Figure 13.4)
- Onset is sudden and often associated with malaise and sore throat
- Stevens–Johnson syndrome – severe cutaneous lesions with mucous membrane involvement
- Most common drugs involved:
  1. Sulfonamides
  2. Phenytoin
  3. Barbiturates
  4. Penicillins
  5. Cephalosporins



**Figure 13.4** Bullous erythema multiforme which progressed into toxic epidermal necrolysis

## Toxic epidermal necrolysis

See Table 13.3

- Most serious cutaneous drug reaction
- Skin turns red, and the epidermis peels in large sheets, leaving a moist very tender base (Figure 13.5)
- Usually caused by a drug
- Examples:
  1. Phenytoin
  2. Sulfonamides
  3. Nonsteroidal anti-inflammatory agents

## Drug-induced hypersensitivity

See Table 13.4

- Multisystemic idiosyncratic drug reaction
- Fever, rash, lymphadenopathy, hepatitis, eosinophilia, leukocytosis
- Female/male ratio = 1
- Begins 7–60 days (mean 17 days) after starting suspected drug
- Rash (Figures 13.6 and 13.7)
  1. Begins as morbilliform on face, upper trunk
  2. Can progress to erythroderma or chronic exfoliative dermatitis
  3. Can have vesicles, bullae, petechiae, purpura, edema

**Table 13.3 Findings associated with serious cutaneous drug eruptions**

**Cutaneous**

Marked erythema  
Edema, particularly facial  
Cutaneous pain  
Palpable purpura  
Skin necrosis  
Bullae  
Positive Nikolsky sign  
Mucous membrane involvement  
Urticaria

**Other findings**

Fever  $>40^{\circ}\text{C}$   
Arthralgias/arthritis  
Pulmonary symptoms (shortness of breath, wheezing)  
Hypotension

**Laboratory abnormalities**

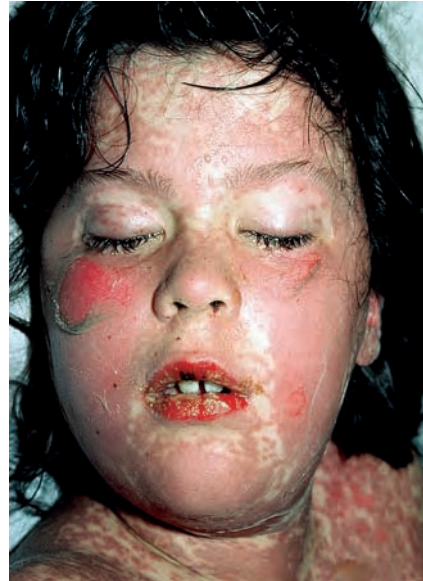Abnormal liver function tests  
Elevated eosinophil count  
Atypical lymphocytosis

**Drugs implicated**

Allopurinol  
Amoxicillin  
Ampicillin  
Carbamazepine  
Lamotrigine  
Phenobarbital  
Phenylbutazone  
Phenytoin  
Piroxicam  
Sulfadiazine  
Sulfadoxime  
Sulfamethoxazole–trimethoprim  
Sulfasalazine  
Valproic acid

Adapted from: Stern RS, Wintroub BU. Cutaneous reactions to drugs. In Fitzpatrick's Dermatology in General Medicine, 5th edn. Freedberg IM, Eisen AZ, Wolff K, et al. McGraw Hill: New York, 1999: 1633–42

4. Mucous membrane findings subtle (erythema, petechiae)
- Systemic involvement
  1. Liver (61%)
  2. Hematologic (48%) – eosinophilia, leukocytosis, reactive lymphocytosis, leukopenia, anemia



**Figure 13.5** Toxic epidermal necrolysis – with sheets of denuded epidermis

3. Renal (15%)
4. Pulmonary (14%)
5. Spleen
6. Myositis
7. Pancreatitis
- Can be associated with recent viral or bacterial infection (e.g. EBV, hepatitis B, parvovirus, *Streptococcus*, *Mycoplasma*)
- Treatment
  1. Oral prednisone 0.5–2.0 mg/kg per day
  2. Topical steroids
  3. Supportive care
  4. May need hospitalization
- Pathogenesis
  1. Possible defect in epoxide hydrolase enzymatic pathway which normally degrades toxic arene oxide metabolites formed during oxidation of antiepileptics; arene oxide metabolites may be directly cytotoxic or act as haptens, leading to hypersensitivity reaction
  2. Sulfonamides – possible defect in glutathione transferase-mediated enzymatic breakdown

**Serum sickness**

- Type III immune complex disease caused by deposition of circulating immune complexes in

**Table 13.4** Drugs associated with hypersensitivity syndrome**Aromatic anticonvulsants**

Carbamazepine  
Phenobarbital  
Phenytoin  
Primidone

**Nonaromatic anticonvulsants**

Lamotrigine  
Valproic acid  
Ethosuximide

**Sulfa drugs**

Dapsone  
Sulfasalazine  
Sulfonamides  
Sulfamethoxazole

**Others**

Allopurinol  
Diltiazem  
Minocycline  
Terbinafine

blood vessels and other tissues, activating the complement cascade

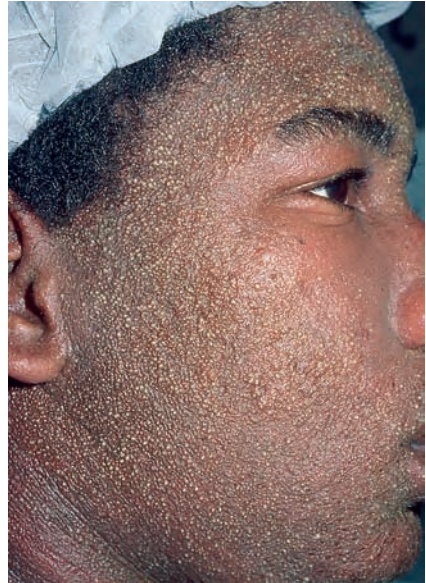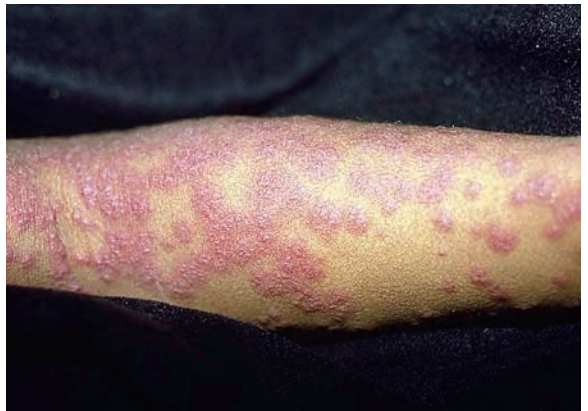- Characterized by urticaria, morbilliform eruption, vasculitis, fever, arthralgia, lymphadenopathy, gastrointestinal disturbance, renal disease

**Serum sickness-like reaction**

- Characterized by rash (urticarial, maculopapular, erythema multiforme-like angioedema), fever, arthralgias, lymphadenopathy, eosinophilia (Figure 13.8)
- No circulating immune complexes, vasculitis or renal disease
- Usually starts 1–3 weeks after administration of offending drug
- Common drugs: cefaclor, amoxicillin, ampicillin,  $\beta$ -blockers, cefprozil, cephalexin, doxycycline, minocycline, penicillin, sulfonamide

**Erythema nodosum**

- Red, tender subcutaneous nodules, usually located on the anterior lower legs
- May be caused by drugs, infection, inflammatory bowel disease or other causes

**Figure 13.6** Drug-induced hypersensitivity from phenytoin**Figure 13.7** Drug-induced hypersensitivity from phenytoin with erythematous plaques

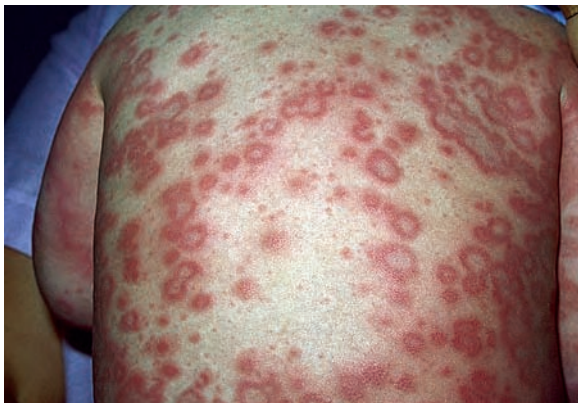- Common drugs:
  1. Oral contraceptives
  2. Sulfonamides
  3. Sulfonylureas

**Photosensitivity eruptions**

See Table 13.5

- Action spectrum is long-wave ultraviolet light (UVA)





**Figure 13.8** Serum sickness-like eruption from a cephalosporin

- Phototoxic reactions are characterized by an exaggerated sunburn reaction
  1. Does not involve immunologic mechanisms
  2. Severity is dose-related
  3. Phototoxic agents generally have a resonating chemical structure capable of absorbing photons of ultraviolet light and moving to an excited state, thus producing damage to cells
  4. Examples: psoralen, tetracyclines
- Photoallergic responses involve primarily type IV reactions
  1. Not dose-related
  2. Occurs in a sensitized individual
  3. Examples: chlorpromazine, sulfanilamide, thiazides, sulfonyleureas
- Topical photosensitizers
  1. Drug applied to the skin and exposed to light causing an eczematous eruption
  2. Examples: para-amino benzoic acid (PABA), phenothiazines, coal tar, oil of bergamot, psoralens

### Lichenoid drug eruption

- Purple-red, flat-topped, pruritic papules, similar to lichen planus
- Often photo-distributed
- Examples: gold, antimalarials, phenothiazines, captopril,  $\beta$ -blockers and thiazide diuretics

### Fixed drug eruption

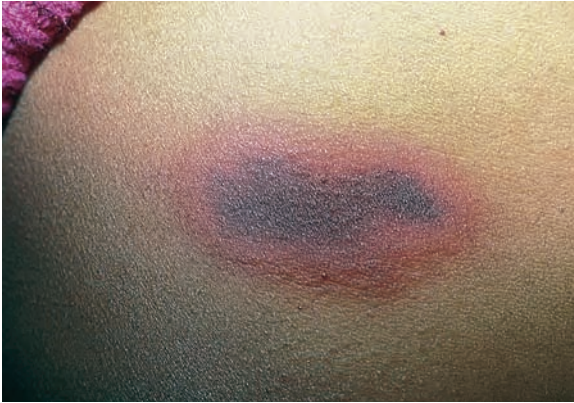- Well-demarcated, red to brown plaque with dusky center

**Table 13.5** Drugs and chemicals that cause photosensitivity reactions

<b>Antidepressants</b>	
Amitriptyline	Desipramine
Doxepin	Imipramine
Nortriptyline	
<b>Antihistamines</b>	
Cyproheptadine	Diphenhydramine
<b>Antimetabolic drugs</b>	
Actinomycin	Methotrexate
Doxorubicin	Vinblastine
5-fluorouracil	Hydroxyurea
<b>Antimicrobials</b>	
Ciprofloxacin	Doxycycline
Enoxacin	Griseofulvin
Minocycline	Nalidixic acid
Sulfasalazine	Tetracycline
Sulfamethoxazole-trimethoprim	
<b>Antiparasitic drugs</b>	
Chloroquine	Quinine
<b>Diuretics</b>	
Acetazolamide	Chlorothiazide
Furosemide	Hydrochlorothiazide
<b>Nonsteroidal anti-inflammatory drugs</b>	
Ketoprofen	Naproxen
Piroxicam	Sulindac
<b>Psychiatric drugs</b>	
Chlorpromazine	Haloperidol
Tricyclic antidepressants	
<b>Other agents</b>	
Acetretin	Amiodarone
Captopril	Carbamazepine
Gold salts	Isotretinoin
Oral contraceptives	Promethazine
Psoralen	Quinidine

- Lesions appear at the same sites after each administration of the medication
- May become vesicular or bullous periodically with introduction of the offending medicine; chronically becomes a hyperpigmented patch (Figure 13.9)
- Location is usually hands, feet, face and genitalia, but can occur anywhere, including mucosal surfaces





**Figure 13.9** Fixed drug eruption – with typical dark center and erythematous halo

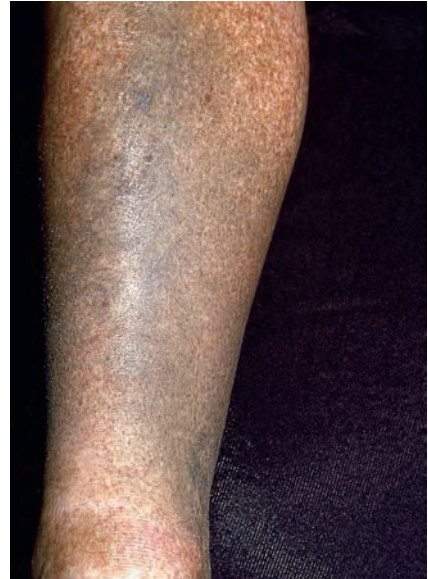- Lesions are solitary or multiple
- Common offenders:
  1. Trimethoprim–sulfamethoxazole
  2. Ampicillin
  3. Amoxicillin
  4. Erythromycin
  5. Phenolphthalein
  6. Tetracycline
  7. Barbiturates
  8. Ibuprofen

### Lupus-like reactions

- Difficult to tell the difference between lupus and drug-induced lupus reaction
- Erythema in the butterfly malar distribution and V of the neck
- Usually: antinuclear antibody-positive, antihistone antibody-positive, antidouble-stranded DNA antibody-negative
- Renal involvement less common in drug-induced lupus
- Examples: minocycline, procainamide, hydralazine (in patients who are slow acetylators), isoniazid, phenytoin, penicillamine

### Pigmentary changes

- Mechanisms: drugs stimulate melanocytic activity or deposit drug in tissues (Figure 13.10)
- Examples:
  1. Heavy metals (gold, silver, mercury)
  2. Phenothiazines



**Figure 13.10** Gray pigmentation of the skin – caused by minocycline

3. Antimalarials
4. Cytotoxic agents (bleomycin)
5. Hydantoin
6. Tetracyclines

### Vasculitis

- Palpable purpura with concentration on the lower extremities
- May involve other organs (e.g. liver, kidney, brain and joints)
- Examples: penicillin, phenytoin, thiazides

### Acneiform eruptions

- Follicular papules and pustules in an acne distribution, often sudden in onset
- Causes: corticosteroids, oral contraceptives, halogens, hydantoin, lithium

### Alopecia

- Anagen arrest caused by cytotoxic agents
- Telogen effluvium caused by anticoagulants, oral contraceptives and  $\beta$ -blockers
- Androgenetic alopecia caused by oral contraceptives

## SPECIFIC DRUGS CAUSING REACTIONS

### Penicillin

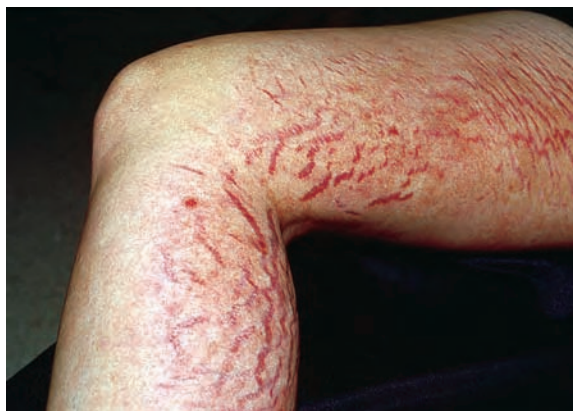- Reactions range from 16 to 52 per 1000 recipients or 5–10% of the population
- Increased use of penicillin increases the risk of developing allergy
- Route of administration: parenterally administered drugs cause more reactions than those administered orally
- Certain diseases (e.g. infection with EBV, HIV, cytomegalovirus (CMV), etc.) may cause an increased risk of reaction
- Manifestations:
  1. Maculopapular and/or papulosquamous reactions most common (associated with IgM antibodies)
  2. Urticarial reactions – risk of developing anaphylaxis on subsequent exposure
- Penicillin can cause any of the four types of immunologic reactions
- Testing available to diagnose allergy to certain components of penicillin

### Cephalosporins

- Erythema which progresses to ‘purple urticaria’ (not true erythema multiforme), with cutaneous swelling (especially feet), migratory pruritic lesions
- No adenopathy
- Serum-sickness-like picture
- Hypersensitivity occurs in ~3% of patients

### Corticosteroids

- Occurs from oral, parenteral, or topical application of corticosteroids
- Manifestations:
  1. Acneiform eruptions
  2. Striae (Figure 13.11)
  3. ‘Moon facies’ caused by fat deposition in the cheeks
  4. ‘Buffalo hump’ caused by fat deposition on the upper back
  5. Telangiectasias
  6. Atrophy
  7. Masking of other dermatoses (e.g. tinea, scabies)



**Figure 13.11** Striae caused by corticosteroids

### Antiepileptic drugs

- Characteristic syndrome of maculopapular rash, fever, facial edema, lymphadenopathy, leukocytosis, hepatitis, nephritis, pneumonitis (see Drug-induced hypersensitivity)
- Most patients develop this syndrome within 2 months of starting the drug
- Cross-sensitivity with phenytoin, carbamazepine and phenobarbital
- Lamotrigine, which is structurally dissimilar, can also cause this reaction

### Tetracyclines

- Phototoxic reactions
- Onycholysis
- Fixed drug eruptions
- Staining of teeth
- Hyperpigmentation
- Serum sickness-like reactions
- Drug-induced lupus (e.g. minocycline)
- Urticaria
- Morbilliform eruptions

### Gold

- Reactions occur in about one-third to one-half of patients
- Clinical manifestations:
  1. Lichenoid reactions
  2. Papulosquamous reactions (resembling pityriasis rosea)
  3. Exfoliative dermatitis

4. Morbilliform eruptions
  5. Erythema nodosum
- Chrysiasis can occur after prolonged use, resulting from deposition of gold salts in the skin, causing blue pigmentation of the skin and ocular conjunctiva

### Antimetabolites (chemotherapy)

- Anagen effluvium (alopecia) caused by the sudden weakening of hair and subsequent breakage
- Stomatitis caused by toxic effect on mucosal cells which have a high mitotic rate
- Acneiform eruptions (e.g. actinomycin-D)
- Onychodystrophy (e.g. bleomycin, hydroxyurea, 5-fluorouracil)
- Chemical cellulitis/phlebitis/ulceration from intravenous extravasation

### Lithium

- Aggravation of acne and psoriasis

### Iodides and bromides

- Acneiform eruptions
- Granulomatous fungating lesions (halogenodermas)

### Antimalarials

- Increased pigmentation (black or yellow) of skin and mucous membranes
- Lichenoid eruptions
- Erythema annulare centrifugum

### Sulfonamides and thiazides

- Thiazides are substituted sulfonamides and may cross-react with sulfonamide antibiotics
- Urticaria
- Morbilliform eruptions
- Erythema multiforme
- Vasculitis
- Toxic epidermal necrolysis

### Nonsteroidal anti-inflammatory drugs

- Morbilliform eruptions
- Bullous fixed drug eruptions

- Vasculitis
- Pseudoporphyria – blistering, erosions and scarring on dorsa of hands, and bridge of nose

### Coumadin

- Sharply – demarcated, erythematous, purpuric plaques which become necrotic and form an eschar
- Lesions occur between days 3 and 10 of anticoagulant therapy
- Thrombosis due to a relative drop in circulating protein C levels

### Pathogenesis

- Molecular characteristics
  1. Increases in molecular size and complexity are associated with increased immunologic reactions
  2. Small molecules form stable bonds with tissue macromolecules forming haptens
- Environmental/other factors
  1. Viral infections can alter the host response, increasing the frequency of reactions (e.g. mononucleosis or HIV plus ampicillin-induced morbilliform eruptions)
  2. Light exposure with photoallergic reactions (e.g. tetracyclines)
  3. Associated diseases: systemic lupus erythematosus predisposes to developing reactions
  4. Genetic factors: deficiency in epoxide hydrolase, an enzyme required for metabolism of a toxic epoxide derived from aromatic anticonvulsants such as phenytoin, carbamazepine and phenobarbital
- Nonimmunologic methods
  1. Drugs may release mast cell mediators directly, causing urticaria (e.g. opiates, curare, radiocontrast media)
  2. Drugs may activate complement in the absence of antibody
  3. Drugs may alter the pathway of arachidonic acid metabolism (e.g. aspirin)
  4. Individual metabolic variation (e.g. defect in clearing reactive intermediate metabolites with thiazides and sulfonamides)
- Type 1 immunologic reactions:
  1. Mediated by IgE
  2. Result in varying degrees of urticaria, pruritus, bronchospasm and anaphylaxis

3. Immediate reactions occur within minutes after exposure
4. Accelerated reactions occur hours or days after drug exposure
5. Production of IgE directed against the drug or drug–haptens complex
6. Drug molecules in general are usually small enough so that they cannot initiate an immune reaction by themselves but require a carrier protein
7. Re-exposure to drug plus antibodies of IgE cause mast cells to release histamine, slow reacting substance of anaphylaxis (SRS-A), eosinophil chemotactic factor of anaphylaxis, neutrophil chemotactic factors and platelet activating factor
8. Examples: penicilloyl polylysins
- Type 2 immunologic reactions (cytotoxic antibody reaction):
  1. Mediated by cytotoxic antibodies
  2. Specific antigens combine with endogenous tissue components which, when combined, act as an antigen, stimulating the formation of antibodies
  3. Antibodies coat the target tissue and stimulate complement activation and tissue destruction
- Type 3 immunologic reactions (immune complex reaction):
  1. Most drug reactions are caused by this type of reaction: serum sickness, possibly erythema multiforme and erythema nodosum
  2. Classic reaction pattern is serum sickness with fever, arthritis, nephritis, neuritis, edema and urticarial or morbilliform eruptions
  3. Symptoms develop >6 days after exposure
  4. Drug or drug–protein complex acts as an antigen, which stimulates antibody production
  5. Sensitization occurs during first exposure with subsequent antibody formation, usually IgG or IgM
  6. When the concentration of antibodies is high enough, there is formation of large immune complexes
  7. Various sizes of immune complex result; size depends upon the rate of antibody production and immune complex clearance rates
  8. Some immune complexes deposit in the peripheral circulation, where they stimulate inflammation and destroy local tissues
  9. Products of the complement cascade, especially C5a and C3a, can degranulate mast cells causing urticaria
- Type 4 immunologic reactions (cell-mediated type):
  1. Keratinocytes are activated and express various cytokines
  2. Associated with morbilliform reactions to some oral drugs (e.g. amoxicillin)
  3. Common as the cause of contact dermatitis (e.g. neomycin)
- Fixed drug eruption:
  1. Histology: superficial and deep perivascular infiltrate with lymphocytes, eosinophils, some neutrophils and necrotic keratinocytes in the epidermis
  2. Hypothesis that intercellular adhesion molecule-1 (ICAM-1) plays a role in site restriction

### Diagnosis

- Clinical evaluation:
  1. History of taking drug
  2. Alternative explanations for the rash (e.g. viral causes, contact history)
  3. Timing of drug exposure with flow chart
  4. Removal of the offending agent
  5. Response to rechallenge
- Laboratory tests:
  1. Drug levels
  2. Complete blood count with differential
  3. Liver function tests
  4. Specific drug evaluations:
    - a. Penicillin: skin tests
    - b. Radioallergosorbent test (RAST) measures specific serum IgE against specific drug
- Histology:
  1. Sparse mixed inflammatory cell infiltrate with eosinophils
  2. Slight vacuolar alteration
  3. Scattered dyskeratotic keratinocytes
  4. Lichenoid drug eruption resembles lichen planus with eosinophils and a deep infiltrate
  5. Fixed drug eruption shows keratinocyte necrosis, melanophages in the papillary dermis and a superficial and deep infiltrate

### Differential diagnosis

- Morbilliform drug eruptions
  1. Viral eruption
  2. Miliaria rubra

3. Graft-versus-host disease
4. Kawasaki syndrome
- Urticaria
  1. Insect bites
  2. Vasculitis
- Erythema multiforme
  1. Urticaria
  2. Kawasaki syndrome
- Erythema nodosum
  1. Ecchymoses
  2. Vasculitis
- Photosensitive eruptions
  1. Sunburn
  2. Contact dermatitis
  3. Eczema
- Lupus-like reactions
  1. Systemic lupus erythematosus

### Treatment

- Discontinue offending drug
- Supportive therapy as indicated by clinical picture
- Corticosteroids early (prednisone 1–2 mg/kg per day)
- Antihistamines
- Topical antipruritic agents
- Baths, with or without additives (e.g. oatmeal)
- Intravenous immunoglobulins for toxic epidermal necrolysis
- If patient is at risk for anaphylaxis or severe reaction, a medical alert bracelet is warranted
- Consider desensitization if drug is necessary

### Prognosis

- Resolution with cessation of drug
- Some pigmentation or scarring can be permanent

### References

- Barbaud AM, Bene M-C, Schmutz J-L, et al. Role of delayed cellular hypersensitivity and adhesion molecules in amoxicillin-induced morbilliform rashes. *Arch Dermatol* 1997; 133: 481–6
- Callot V, Roujeau J-C, Bagot M, et al. Drug-induced pseudolymphoma and hypersensitivity syndrome. *Arch Dermatol* 1996; 132: 1315–21
- Carroll MC, Yueng-Yue KA, Esterly NB, Drolet BA. Drug-induced hypersensitivity syndrome in pediatric patients. *Pediatrics* 2001; 108: 485–93
- Caumes E, Guernonprez G, Lecomte C, et al. Efficacy and safety of desensitization with sulfmethoxazole and trimethoprim in 48 previously hypersensitive patients infected with human immunodeficiency virus. *Arch Dermatol* 1997; 133: 465–9
- Chosidow O, Bourgault I, Roujeau J-C. Drug rashes. What are the targets of cell-mediated cytotoxicity? *Arch Dermatol* 1994; 130: 627–9
- Gonzalez E, Gonzalez S. Drug photosensitivity, idiopathic photodermatoses, and sunscreens. *J Am Acad Dermatol* 1996; 35: 871–85
- Halevy S, Shai A. Lichenoid drug eruptions. *J Am Acad Dermatol* 1993; 29: 249–55
- Hawfield W, Goodrich R, Warren S, Morrell D. Trauma-induced cutaneous pigmentation from tetracycline: a case report. *Pediatr Dermatol* 2004; 21: 164–6
- Hebert AA, Sigman ES, Levy ML. Serum sickness-like reactions from cefaclor in children. *J Am Acad Dermatol* 1991; 25: 805–8
- Huang Y-L, Hong H-S, Wang Z-W, Kuo T-T. Fatal sodium valproate-induced hypersensitivity syndrome with lichenoid dermatitis and fulminant hepatitis. *J Am Acad Dermatol* 2003; 49: 316–19
- Kaur S, Sarkar R, Thami G, Kanwar AJ. Anticonvulsant hypersensitivity syndrome. *Pediatr Dermatol* 2002; 19: 142–5
- Lee WM. Drug-induced hepatotoxicity. *N Engl J Med* 1995; 333: 1118–27
- Levy ML, Barron KS, Eichenfield L, Honig PJ. Naproxen-induced pseudoporphyria: a distinctive photodermatitis. *J Pediatr* 1990; 117: 660–4
- Litt JZ. *Drug Eruption Reference Manual*, 9th edn. Parthenon Publishing: New York, 2003
- Ming ME, Bhawan J, Stefanato CM, et al. Imipramine-induced hyperpigmentation: four cases and a review of the literature. *J Am Acad Dermatol* 1999; 40: 159–66
- Morelli JG, Tay Y-K, Rogers M, et al. Fixed drug eruptions in children. *J Pediatr* 1999; 134: 365–7
- Nigen S, Knowles SR, Shear NH. Drug eruptions – approaching the diagnosis of drug-induced skin diseases. *J Drugs Dermatol* 2003; 3: 278–99
- Sehgal VN, Srivastava G, Sardana K. Erythroderma/exfoliative dermatitis: a synopsis. *Int J Dermatol* 2004; 43: 39–47
- Shapiro LE, Shear NH. Drug interactions: proteins, pumps, and p-450s. *J Am Acad Dermatol* 2002; 47: 467–84
- Shapiro LE, Knowles SR, Shear NH. Comparative safety of tetracycline, minocycline and doxycycline. *Arch Dermatol* 1997; 133: 1224–30
- Stern RS, Wintroub BU. Cutaneous reactions to drugs. In: Fitzpatrick's *Dermatology in General Medicine*, 5th edn. Freedberg IM, Eisen AZ, Wolff K, et al., eds. McGraw Hill: New York, 1999: 1633–42
- Tristani-Firouzi P, Petersen MJ, Saffle JR, et al. Treatment of toxic epidermal necrolysis with intravenous immunoglobulin in children. *J Am Acad Dermatol* 2002; 47: 548–52





## PIGMENTARY DISORDERS

### LINES OF BLASCHKO

- A form of mosaicism with two or more genetically distinct cell lines arising from a postzygotic somatic mutation (see Table 17.1)
- Follow segmental and linear skin lines which are V-shaped or a circling pattern on the chest and a linear distribution on the extremities
- Should not be confused with dermatomes, which are areas of the skin innervated by sensory nerves
- Can be hypopigmented (e.g. hypomelanosis of Ito), hyperpigmented (e.g. linear and whorled hypermelanosis), or verrucous (e.g. epidermal nevus), depending upon the type of defect

#### References

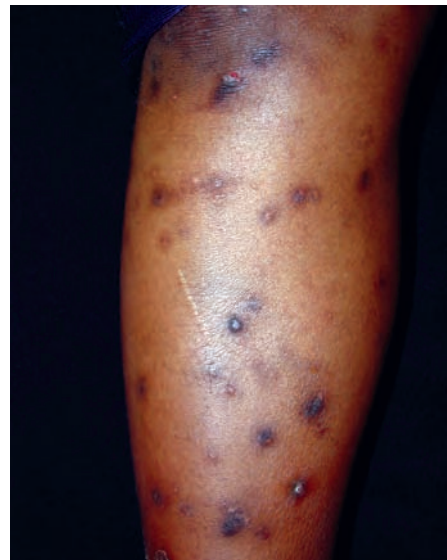
- Bolognia JL, Orlow SJ, Glick SA. Lines of Blaschko. *J Am Acad Dermatol* 1994; 31: 157–90
- Danarti R, Bittar M, Happle R, Konig A. Linear atrophoderma of Moulin: postulation of mosaicism for a predisposing gene. *J Am Acad Dermatol* 2003; 49: 492–8
- Duran-McKinster C, Moises C, Rodriguez-Jurado R, et al. Streptococcal exanthem in a Blaschkolinear pattern: clinical evidence for genetic mosaicism in hypomelanosis of Ito. *Pediatr Dermatol* 2002; 19: 423–5
- Happle R, Assim A. The lines of Blaschko on the head and neck. *J Am Acad Dermatol* 2001; 44: 612–15
- Kabbash C, Laude TA, Weinberg JM, Silverberg NB. Lichen planus in the lines of Blaschko. *Pediatr Dermatol* 2002; 19: 541–5
- Nehal KS, DeBenito R, Orlow SJ. Analysis of 54 cases of hypopigmentation and hyperpigmentation along the lines of Blaschko. *Arch Dermatol* 1996; 132: 1167–70
- Rott HD. Extracutaneous analogies of Blaschko lines. *Am J Med Genet* 1999; 85: 338–41

### HYPERPIGMENTED DISORDERS

#### Postinflammatory hyperpigmentation

##### *Major points*

- Most common cause of increased pigmentation in childhood
- Follows an inflammatory process or traumatic injury to the epidermis, especially following atopic dermatitis, contact dermatitis, or lichen planus (Figure 14.1)
- Lesions usually localized and follow the distribution of the resolving skin disorder
- More common in dark skin types



**Figure 14.1** Postinflammatory hyperpigmentation following insect bites

### Pathogenesis

- Histology: aberrant delivery of melanin to the surrounding keratinocytes and deposition of pigment in the dermal melanophages

### Diagnosis

- Clinical presentation

### Differential diagnosis

- Café au lait macule
- Becker nevus
- Nevus spilus

### Treatment

- No treatment is very effective
- Hydroquinone 2-4% BID may decrease epidermal hyperpigmentation slowly

### Prognosis

- After inflammation is resolved, hyperpigmentation fades slowly over many months

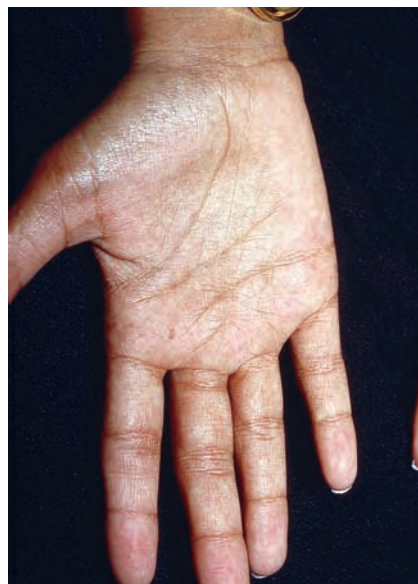### References

Ruiz-Maldonado R, Orozco-Covarrubias ML. Postinflammatory hypopigmentation and hyperpigmentation. *Semin Cutan Med Surg* 1997; 16: 36-43

## Generalized hyperpigmentation

### Major points

- Widespread accentuation of normal areas of melanin pigmentation all over the body with marked increases in skin creases of palms and soles and mucous membranes
- Generalized hyperpigmentation should be differentiated from normal variation or from sun exposure
- Causes:
  1. Endocrine abnormalities (e.g. Addison disease, Cushing syndrome, acromegaly, melanotropin-stimulating hormone (MSH) excess) (Figure 14.2)
  2. Certain drugs (e.g. heavy metals, phenothiazines, antimalarials)
  3. Hemochromatosis
  4. Chronic renal disease
  5. Chronic hepatic disease
  6. Scleroderma
  7. AIDS



**Figure 14.2** Generalized hyperpigmentation caused by Addison disease with accentuation of palmar creases

### Pathogenesis

- Etiology depends upon cause of pigmentation
- Melanogenic action of increased pituitary peptides (e.g. MSH in Addison disease)

### Diagnosis

- Clinical presentation
- Histology: increased melanin in melanocytes and some melanophages in the dermis

### Differential diagnosis

- See Causes (above)

### Treatment

- Depends upon the cause of hyperpigmentation
- Discontinuance of medication or treatment of disease does not always improve hyperpigmentation

### Prognosis

- Generally permanent, unless caused by a medicine which can be discontinued

### References

Fulk CS. Primary disorders of hyperpigmentation. *J Am Acad Dermatol* 1984; 10: 1-16

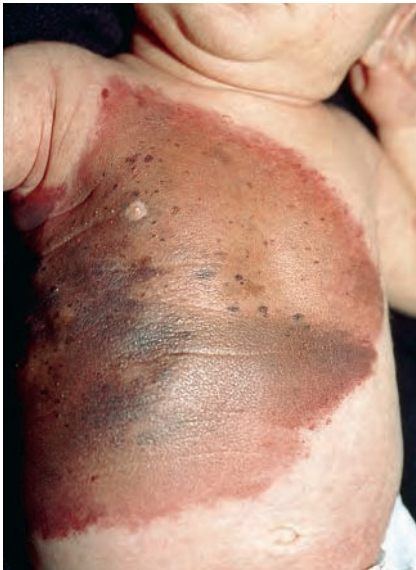Oelkers W. Adrenal insufficiency. *N Engl J Med* 1996; 335: 1206-12

## Congenital nevocellular nevi

Synonym: congenital nevomelanocytic nevi,  
congenital melanocytic nevi

### Major points

- Lesions are apparent at birth or within 1 year of birth (Figure 14.3)
- Surface can be smooth, pebbly, verrucous or lobular
- Pigmentation is usually uniform, medium or dark brown but may have dark brown speckles or black areas. In dark skin, congenital nevocellular nevi (CNN) tend to be more heavily pigmented
- Size ranges from small (2 mm to 1.5 cm) to medium (1.5–19.9 cm) to large (>20 cm) and can cover a large portion of the skin surface
- Except for size, the overall appearance is similar to that of acquired nevi
- Some have coarse long hairs
- Familial tendency has been reported
- CNN of the head or neck (usually large in size) may be associated with leptomeningeal melanocytosis, manifesting as hydrocephalus, seizures, mental retardation, or melanoma, and carries a poor prognosis
- Melanoma arises in ~5–15% in the reported literature



**Figure 14.3** Large congenital nevocellular nevus – with variation in color

- Other tumors developing in CNN: schwannoma, neuroid tumor, lipoma, rhabdomyosarcoma, neurofibroma and others

### Pathogenesis

- CNN form *in utero* between 8 weeks and 6 months
- Histology: nests, sheets or single nevus cells in the dermis, epidermis and sometimes into subcutaneous tissues with features of neuroid appearance, epithelioid cells and/or spindle cells; involvement around appendageal and neurovascular structures is common

### Diagnosis

- Usually clinical, but biopsy might be indicated to confirm the diagnosis in unusual cases

### Differential diagnosis

- Mongolian spot
- Café au lait macule
- Lentigo
- Acquired nevocellular nevus
- Nevus sebaceus
- Smooth muscle hamartoma
- Becker nevus

### Treatment

- Ulceration, nodules or markedly varied pigmentation suggests the possibility of melanoma and should be biopsied
- Treatment is dependent on perceived risk of melanoma, cosmetic and functional considerations. There is some controversy amongst experts whether excision versus watching is advised
- Excision if indicated; goal is to remove as much of the CNN as possible while preserving function and cosmesis
- Management of extensive CNN should be individualized on a case-by-case basis
- Dermabrasion and other destructive methods may be cosmetically helpful but are controversial

### Prognosis

- CNN usually expand in direct proportion to growth of the anatomic site and can actually enlarge. They often darken with time and develop hair; rarely they may become lighter in color

- Incidence of melanoma in CNN is unknown, but ranges from 5 to 15%. In large CNN, half of the cases of melanoma arise before age 5 years
- Prognosis for patients who develop melanoma in a giant CNN is poor, because of early metastasis or late diagnosis

### References

DeDavid M, Orlow SJ, Provost N, et al. A study of large congenital melanocytic nevi and associated malignant melanomas: review of cases in the New York University Registry and the world literature. *J Am Acad Dermatol* 1997; 36: 409–16

Leech SN, Bell H, Leonard N, et al. Neonatal giant congenital nevi with proliferative nodules. *Arch Dermatol* 2004; 140: 83–8

LoGiudice J, Gosain AK. Pediatric tissue expansion: indications and complications. *J Craniofac Surg* 2003; 14: 866–72

Management of congenital melanocytic nevi: a decade later. Special Symposium. *Pediatr Dermatol* 1996; 13: 321–40

Marghoob AA, Borrego JP, Halpern AC. Congenital melanocytic nevi: treatment modalities and management options. *Semin Cutan Med Surg* 2003; 22: 21–32

Marghoob AA, Schoenbach SP, Kopf AW, et al. Large congenital melanocytic nevi and the risk for the development of malignant melanoma. *Arch Dermatol* 1996; 132: 170–5

Makkar HS, Frieden IJ. Congenital melanocytic nevi: an update for the pediatrician. *Curr Opin Pediatr* 2002; 14: 397–403

Shapall S, Frieden I, Chesney M, Newman T. Risk of malignant transformation of congenital melanocytic nevi in blacks. *Pediatr Dermatol* 1994; 11: 204–8

Zutt M, Kretschmer L, Emmert S, et al. Multicentric malignant melanoma in a giant melanocytic congenital nevus 20 years after dermabrasion in adulthood. *Dermatol Surg* 2003; 29: 99–101

### Acquired melanocytic nevi

Synonyms: pigmented nevi, pigmented moles, melanocytic nevi

Singular: nevus

#### Major points

- Nevi begin to develop in early childhood as small 1–2 mm pigmented macules

- Lesions slowly enlarge and become papular with age
- Nevi increase in darkening, size and number at puberty
- Most acquired nevi are <0.5 cm in diameter
- The majority of nevi are in sun-exposed areas, particularly the torso, but can be anywhere, including the palms, soles, buttock, scalp
- Types:
  1. Junctional nevus: flat, with nevus cells located at the dermal–epidermal junction
  2. Dermal nevus: dome shaped; nevus cells located within dermis
  3. Compound nevus: slightly elevated dome-shaped hyperpigmented papule with nevus cells at the dermal–epidermal junction and in the dermis
- Dysplastic nevi
  1. Unusually large, variegated in color, often multiple (Figures 14.4 and 14.5)
  2. Common on back and scalp
  3. If numerous, watch for changes of melanoma
- Increased numbers in: atypical mole syndrome, Noonan syndrome, Langer–Giedion syndrome, Turner syndrome, others

### Pathogenesis

- Histology: nevus cells at the dermal–epidermal junction, within the dermis, or both
- Nevus cells are thought to arise from the neural crest

### Diagnosis

- Clinical presentation

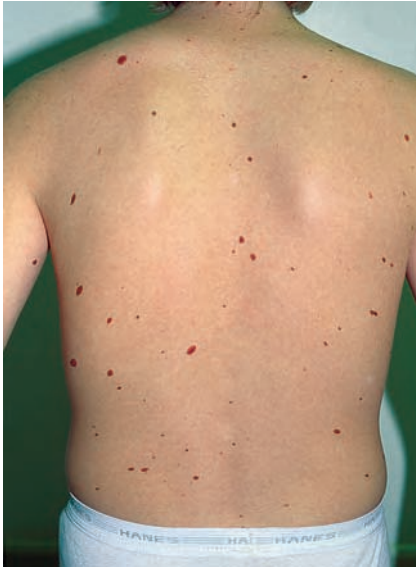### Differential diagnosis

- Congenital nevocellular nevus
- Folliculitis
- Spitz nevus

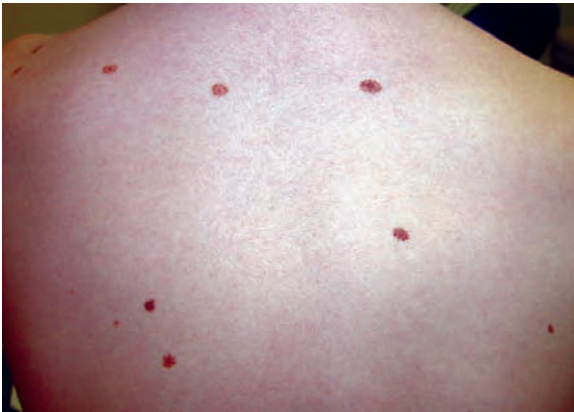### Treatment

- Nevi change slowly over months to years; therefore, only observation is warranted
- When indicated, elliptical excision or deep saucerization removal
- Lesion with atypical histology should be excised completely or followed closely for malignant change
- Destructive modes of therapy (e.g. cryotherapy, laser, etc.) not recommended





**Figure 14.4** Dysplastic nevi – numerous and large nevi



**Figure 14.5** Dysplastic nevi – closer view of a different patient. These lesions are all larger than normal and display variegation in color

### Prognosis

- Natural course: appearance in childhood, number of lesions peaking in second and third decades then disappearing in seventh to ninth decade
- Majority of CNN are benign, growing in proportion to body growth

### References

Bauer J, Garbe C. Acquired melanocytic nevi as risk factor for melanoma development. A comprehensive review of epidemiological data. *Pigment Cell Res* 2003; 16: 297–306

Drake LA, Ceilley RI, Cornelison RL, et al. Guidelines of care for nevi, II: non-melanocytic nevi, hamartomas, neoplasms, and potentially malignant lesions. *J Am Acad Dermatol* 1995;32: 104–8

Guidelines of care for nevi, I (nevocellular nevi and seborrheic keratoses). *J Am Acad Dermatol* 1992; 26: 629–31

Marghoob AA, Orlow SJ, Kopf AW. Syndromes associated with melanocytic nevi. *J Am Acad Dermatol* 1993; 29: 373–88

Naeyaert JM, Brochez L. Clinical practice. Dysplastic nevi. *N Engl J Med* 2003; 349: 2233–40

Pope DJ, Sorahan T, Marsen JR, et al. Benign pigmented nevi in children. *Arch Dermatol* 1992; 128: 1201–6

Salopek TG. The dilemma of the dysplastic nevus. *Dermatol Clin* 2002; 20: 617–28

### Spitz nevus

Synonyms: spindle and epithelioid nevus, benign juvenile melanoma

#### Major points

- Solitary, reddish brown or dark brown, dome-shaped papule, 0.5–10 mm in size (Figure 14.6)
  1. On face, tends to be reddish brown
  2. On extremities, tends to be brown, mottled or verrucous
- Grows rapidly or slowly for about a year, then stops growing
- Affects children aged 3–13 years, primarily
- No racial or sex predilection
- Solitary lesions most common, but can be agminated or in multiple clusters
- Rare bleeding or pruritus

#### Pathogenesis

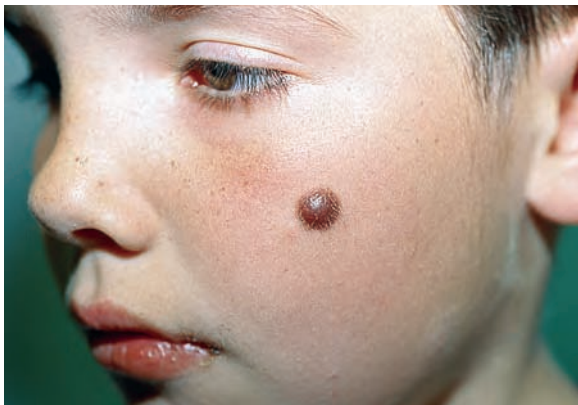- Presumed to be derived from same progenitor cells giving rise to epidermal melanocytes and nevomelanocytes

#### Diagnosis

- Histology: nevus cells are large and/or spindle-shaped and slightly pleomorphic with maturation of melanocytes; little or no evidence of upward migration into epidermis

#### Differential diagnosis

- Pyogenic granuloma
- Hemangioma



**Figure 14.6** Spitz nevus – brown-red papule which appeared quickly on this child's face

- Malignant melanoma
- Juvenile xanthogranuloma
- Mastocytoma
- Acquired intradermal nevus
- Malignant Spitz nevus

#### *Treatment*

- Complete excision

#### *Prognosis*

- Benign, and do not metastasize
- May persist into adult life, becoming intradermal nevi in some cases
- Some case reports in adults who had 'Spitz nevi' really had melanoma, and therefore in an adult or late teen this diagnosis should be suspect

#### *References*

- LeBoit PE. 'Safe' Spitz and its alternatives. *Pediatr Dermatol* 2002; 19: 163–5
- Ruiter DJ, van Dijk MC, Ferrier CM. Current diagnostic problems in melanoma pathology. *Semin Cutan Med Surg* 2003; 22: 33–41
- Shimek CM, Golitz LE. The golden anniversary of the Spitz nevus. *Arch Dermatol* 1999; 135: 333–5
- Sordi E, Ferrari A, Piccolo D, Peris K. Pigmented Spitz nevi. *Dermatol Surg* 2002; 28: 1182–3
- Spatz A, Barnhill RL. The Spitz tumor 50 years later: revisiting a landmark contribution and unresolved controversy. *J Am Acad Dermatol* 1999; 40: 223–8
- Spatz A, Calonje E, Handfield-Jones S, Barnhill RL. Spitz tumors in children. *Arch Dermatol* 1999; 135: 282–5

Su LD, Fullen DR, Sondak VK, et al. Sentinel lymph node biopsy for patients with problematic spitzoid melanocytic lesions: a report on 18 patients. *Cancer* 2003; 97: 499–507

## **Blue nevus**

### *Major points*

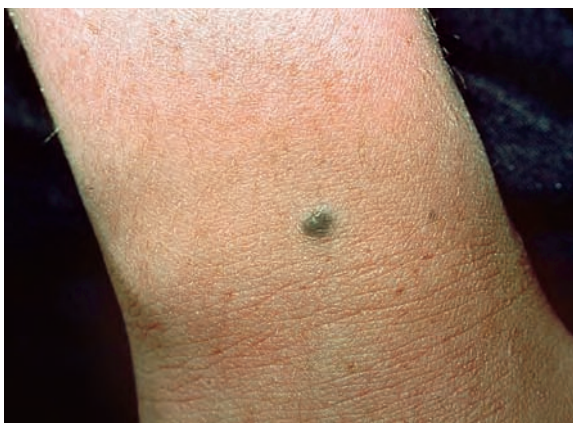- Acquired or congenital
- Usually solitary
- Blue-gray or blue-black papule, nodule or plaque-like aggregate of dermal melanocytes (Figure 14.7)
- Blue-gray color is an optical effect of dermal melanin seen through overlying skin
- Diameter usually <10 mm, but can range up to 3 cm
- Location usually dorsal hands and feet
- Associated with: lentiginos, cardiac myxoma and cutaneous myxomas (Carney complex)

### *Pathogenesis*

- Etiology unknown
- Thought to be ectopic accumulation of melanin-producing melanocytes in the dermis during migration from neural crest to skin
- Origin either Schwann cells, endoneural cells or melanocytes

### *Diagnosis*

- Typical clinical appearance
- Histology: dermal melanocytes with melanin-containing macrophages



**Figure 14.7** Blue nevus – blue-black papule on wrist

### Differential diagnosis

- Melanoma
- Nevocellular nevus
- Traumatic tattoo
- Sclerosing hemangioma
- Dermatofibroma
- Carney complex

### Treatment

- Surgical excision is advised, because differentiation between blue nevus and melanoma is difficult
- Laser treatment controversial

### Prognosis

- Natural evolution has not been studied, but probably benign
- Rare malignant blue nevus found in contiguity with benign blue nevus

### References

- Carney JA, Stratakis CA. Epithelioid blue nevus and psammomatous melanotic schwannoma: the unusual pigmented skin tumors of the Carney complex. *Semin Diag Pathol* 1998; 15: 216–24
- Hendricks WM. Eruptive blue nevi. *J Am Acad Dermatol* 1981; 4: 50–3
- Hsiao G-H, Hsiao C-W. Plaque-type blue nevus on the face: a variant of Ota's nevus. *J Am Acad Dermatol* 1994; 30: 849–51
- Knoell KA, Nelson KC, Patterson JW. Familial multiple blue nevi. *J Am Acad Dermatol* 1998; 39: 322–5
- Milgram SS, Cohen ME, Auletta MJ. Treatment of blue nevi with the Q-switched ruby laser. *J Am Acad Dermatol* 1995; 32: 307–10
- Pinto A, Raghavendra S, Lee R, et al. Epithelioid blue nevus of the oral mucosa: a rare histologic variant. *Oral Surg Oral Med Oral Pathol Oral Radiol Endodontics* 2003; 96: 429–36
- Schaffer JV, Bologna JL. The clinical spectrum of pigmented lesions. *Clin Plast Surg* 2000; 27: 391–408
- Tschen JA, Cartwright J, Font RL. Nonmelanized macromelanosomes in a cellular blue nevus. *Arch Dermatol* 1989; 125: 809–12

### Halo nevus

Synonyms: halo nevocellular nevus, leukoderma acquisitum centrifugum, Sutton nevus

### Major points

- Characterized by a pink or brown central nevus surrounded by a halo of depigmentation usually 0.5–5 cm in diameter, often indicating onset of regression of nevus (Figure 14.8)
- Can be associated with acquired or congenital nevi
- More common in children with mean age of 15 years (majority <20 years)
- Multiple lesions common (25–50%)
- Any race
- Common association: vitiligo (18–26%)
- Can be seen with melanoma at distant sites (very rare)

### Pathogenesis

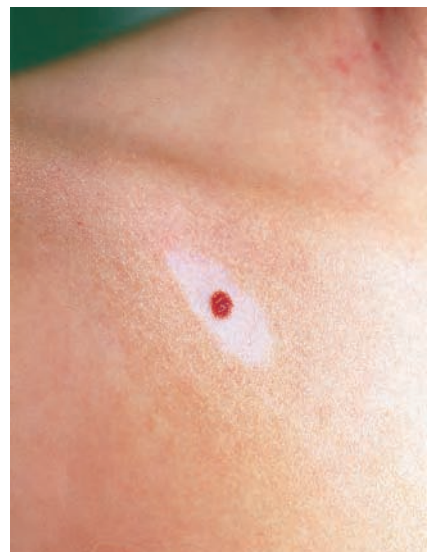- Both humoral and cellular factors may be responsible for nevus destruction

### Diagnosis

- Clinical presentation
- Histology: central melanocytic nevus with dermal lymphocytic infiltrate surrounding the nevus, and depigmented zone devoid of epidermal melanocytes

### Differential diagnosis

- Vitiligo
- Eczematous eruption around molluscum
- Melanoma (usually adults)



**Figure 14.8** Halo nevus – depigmented halo around a typical acquired nevus

### Treatment

- Close examination of skin in order to rule out other associated disorders (e.g. vitiligo, dysplastic nevi, melanoma)
- Surgical removal of normal nevus with halo not usually indicated in children because of benign nature

### Prognosis

- Central nevus may persist, become less pigmented over time, or disappear with eventual repigmentation

### References

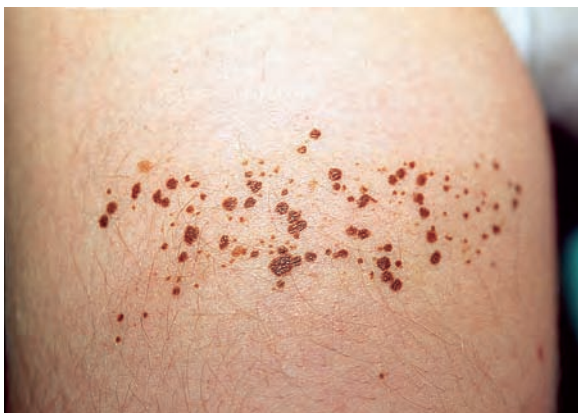- Baranda L, Torres-Alvarez B, Moncada B, et al. Presence of activated lymphocytes in the peripheral blood of patients with halo nevi. *J Am Acad Dermatol* 1999; 41: 567–72
- Inamadar AC, Palit A, Athanikar SB, et al. Unusual course of a halo nevus. *Pediatr Dermatol* 2003; 20: 542–3
- Musette P, Bachelez H, Flageul B, et al. Immune-mediated destruction of melanocytes in halo nevi is associated with the local expansion of a limited number of T cell clones. *J Immunol* 1999; 162: 1789–94
- Zeff RA, Freitag A, Grin CM, Grant-Kels JM. The immune response in halo nevi. *J Am Acad Dermatol* 1997; 37: 620–4

## Nevus spilus

Synonym: speckled lentiginous nevus

### Major points

- Presents at birth or early childhood as a tan or brown macule which becomes speckled with darker pigmented macules over time (Figure 14.9)



**Figure 14.9** Nevus spilus – café au lait macule with nevi

### Pathogenesis

- Histology of the light brown area: lentiginous melanocytic hyperplasia. Darker macules/papules demonstrate nests of nevus cells at the dermal–epidermal junction (junctional or compound nevi)

### Diagnosis

- Clinical diagnosis

### Differential diagnosis

- Becker nevus
- Café au lait macule
- Congenital melanocytic nevus

### Treatment

- Observation usually sufficient
- Surgical excision or biopsy is warranted if lesion demonstrates abnormally rapid growth of dark pigment

### Prognosis

- Risk of malignant change unknown, but probably very small

### References

- Casanova D, Bardot J, Aubert JP, et al. Management of nevus spilus. *Pediatr Dermatol* 1996; 13: 233–8
- Cohen LM. Nevus spilus: congenital or acquired? *Arch Dermatol* 2001; 137: 215–16
- Cramer SF. Speckled lentiginous nevus (nevus spilus): the ‘roots’ of the ‘melanocytic garden’. *Arch Dermatol* 2001; 137: 1654–5
- Johr RH, Binder M. Management of nevus spilus—a better way. *Pediatr Dermatol* 2000; 17: 491–2
- Moreno-Arias GA, Bulla F, Vilata-Corell JJ, Camps-Fresneda A. Treatment of widespread segmental nevus spilus by Q-switched alexandrite laser (755 nm, 100 nsec). *Dermatol Surg* 2001; 27: 841–3
- Rhodes AR. Nevus spilus: a potential precursor of cutaneous melanoma worthy of aggressive surgical excision? *Pediatr Dermatol* 1996; 13: 250–2

## Melanoma

### Major points

- Rare in children, but has been associated with congenital nevocellular nevi, acquired nevi, or *de novo* (Figures 14.10 and 14.11)



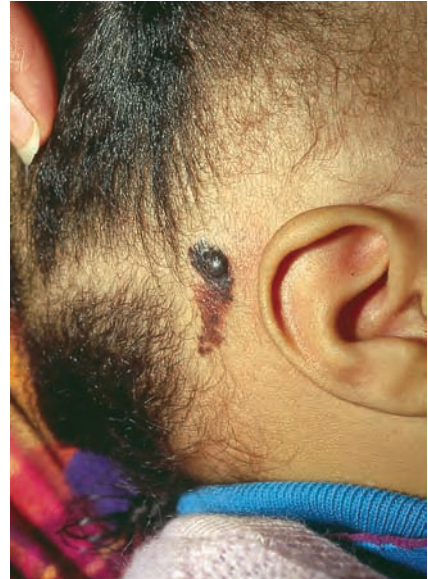- Change in nevus:
  1. Asymmetry. Irregular pigmentation with darkening of one portion of the nevus, a small dark elevated papule within an otherwise flat papule, or flaking, scaling, ulceration or bleeding
  2. Border irregularity. Lesion appears to be growing in one direction with scalloped edges
  3. Color variation. Appearance of black, dark brown or admixture of red, white and black
  4. Diameter >6 mm; most benign acquired nevi are <6 mm
  5. Symptoms: burning, itching, or tenderness
- Risk factors:
  1. New or changing mole
  2. Age >15 years
  3. Dysplastic nevi, prior melanoma and familial melanoma
  4. Congenital nevocellular nevus
  5. 50 nevi, >2 mm in diameter
  6. 12 nevi, >6 mm in diameter
  7. Light skin color
  8. Marked freckling
  9. Sun sensitivity
  10. Excessive sun exposure
- Associations:
  1. Family history of melanoma
  2. Presence of multiple atypical nevi (atypical mole syndrome)
  3. Xeroderma pigmentosum
  4. Transplacental spread of maternal melanoma

### Pathogenesis

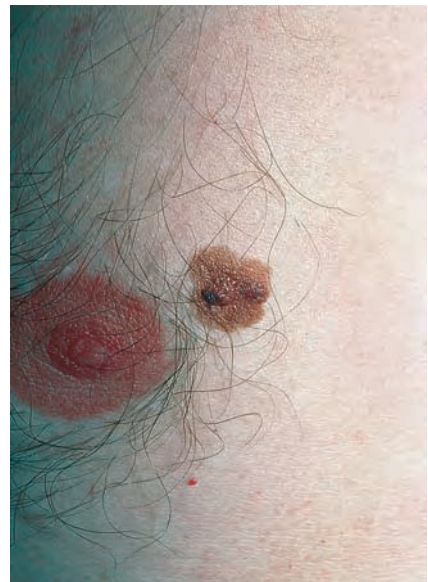- Genetic factors with resultant progressive changes in DNA and inability to repair DNA
- Familial cutaneous malignant melanoma (OMIM no. 15560) can be caused by germline mutations in CDKN2A on chromosome 9p21 and CDK4 on 12q14 and 1p36

### Diagnosis

- Clinical features
- Histology: increased numbers of atypical basal melanocytes with atypical nuclei of different sizes, epidermotropism, nest of melanocytes with variation in size and shape, asymmetrical no maturation of melanocytes, signs of regression



**Figure 14.10** Melanoma – arising in a congenital nevus



**Figure 14.11** Melanoma – changes in color brought this patient to the doctor; it was melanoma *in situ*

### Differential diagnosis

- Spitz nevus
- Congenital nevocellular nevus
- Acquired melanocytic nevus
- Blue nevus



- Traumatic hemorrhage (especially under the nails, on the heels, or on the mucous membranes)
- Pyogenic granuloma

### Treatment

- Excision with wide margins based on microscopic depth of melanoma cells:
  1. In situ: 2–5 mm excision margin
  2. <1 mm: 1 cm excision margin
  3. 1–2 mm: 1–2 cm excision margin
  4. 2.1–4 mm: 2–3 cm excision margin
  5. >4 mm: 2–3 cm excision margin
- Adjunctive treatments:  $\alpha$ -interferon, chemotherapy

### Prognosis

- Influenced by depth of the lesion and involvement of lymph nodes
- Five year survival (in general; many factors influence staging): stages I–II: 79%; stage III: 13–69%; stage IV: 6%

### References

- Arbiser JL. Melanoma. Lessons from metastases. *Arch Dermatol* 1998; 134: 1027–8
- Bevona C, Goggins W, Quinn T, et al. Cutaneous melanomas associated with nevi. *Arch Dermatol* 2003; 139: 1620–4
- de Braud F, Khayat D, Kroon BB, et al. Malignant melanoma. *Crit Rev Oncol Hematol* 2003; 47: 35–63
- Eedy DJ. Surgical treatment of melanoma. *Br J Dermatol* 2003; 149: 2–12
- Handfield-Jones SE, Smith NP. Malignant melanoma in childhood. *Br J Dermatol* 1996; 134: 607–16
- Johnson TM, Hamilton T, Lowe L. Multiple primary melanomas. *J Am Acad Dermatol* 1998; 39: 422–7
- Johnson TM, Yahanda AM, Chang AE, et al. Advances in melanoma therapy. *J Am Acad Dermatol* 1998; 38: 731–41
- Kanzler MH, Swetter SM. Malignant melanoma. Periodic synopsis. *J Am Acad Dermatol* 2003; 48: 780–3
- Monzon J, Liu L, Brill H, et al. CDKN2A mutations in multiple primary melanomas. *N Engl J Med* 1998; 338: 879–87
- Queirolo P, Taveggia P, Gipponi M, Sertoli MR. Sentinel lymph node biopsy in melanoma patients: the medical oncologist's perspective. *J Surg Oncol* 2004; 85: 162–5
- Richardson SK, Tannous ZS, Mihm MC. Congenital and infantile melanoma: review of the literature and report of an uncommon variant, pigment-synthesizing melanoma. *J Am Acad Dermatol* 2002; 47: 77–90
- Saenz NC, Saenz-Badillos J, Busam K, et al. Childhood melanoma survival. *Cancer* 1999; 85: 750–4
- Sahin S, Levin L, Kopf AW, et al. Risk of melanoma in medium-sized congenital melanocytic nevi: a follow-up study. *J Am Acad Dermatol* 1998; 39: 428–33
- Schmid-Wendtner MH, Berking C, Baumert J, et al. Cutaneous melanoma in childhood and adolescence: an analysis of 36 patients. *J Am Acad Dermatol* 2002; 46: 874–9
- Sober AJ, et al. (Task Force). Guidelines of care for primary cutaneous melanoma. *J Am Acad Dermatol* 2001; 45: 579–86
- Wechsler J, Bastuji-Garin S, Spatz A, et al. Reliability of the histopathologic diagnosis of malignant melanoma in childhood. *Arch Dermatol* 2002; 138: 625–8

## Becker nevus

Synonyms: Becker's melanosis, hairy epidermal nevus

### Major points

- Male/female ratio >1
- Clinical:
  1. May be present at birth or childhood as a brown patch with smudged borders
  2. Sharply demarcated irregular hyperpigmented patch with or without coarse dark hair (Figure 14.12)
  3. Location characteristically over the shoulder, anterior chest, or scapula, but can be anywhere
  4. Enlarges slowly over ~2 years, then stabilizes
  5. Usual size: 2–20 cm
  6. Asymptomatic
- Rare association: hypoplasia of underlying structures (e.g. hypoplasia of the breast)

### Pathogenesis

- Organoid hamartoma of ectoderm and mesoderm
- Increase in expression of testosterone receptors and increased sensitivity to androgens may account for expression of lesion around puberty

### Diagnosis

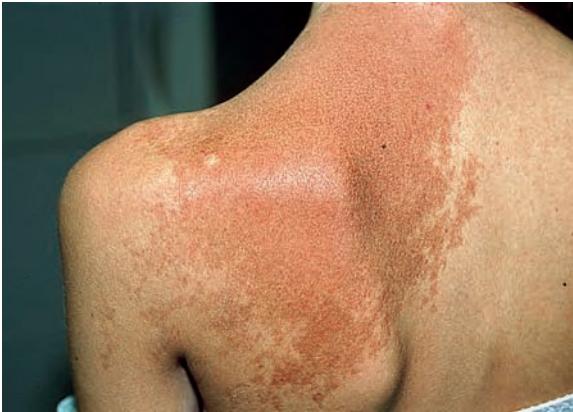- Clinical presentation
- Histology: slight acanthosis, papillomatosis, hyperpigmented basal cell layer and variable increase in smooth muscle fibers

### Differential diagnosis

- Congenital nevocellular nevus
- Smooth muscle hamartoma

### Treatment

- No treatment needed
- Pigmented lesion lasers (Q-switched ruby, neodymium : YAG lasers) may improve hyperpigmentation
- Photoprotection decreases darkening from sun exposure
- Bleaching agents with hydroquinone may be helpful
- For hair removal: shaving, depilatories, electrolysis, laser



**Figure 14.12** Becker nevus – unilateral mottled brown patch with increased hair

### Prognosis

- Lesion persists indefinitely
- Benign

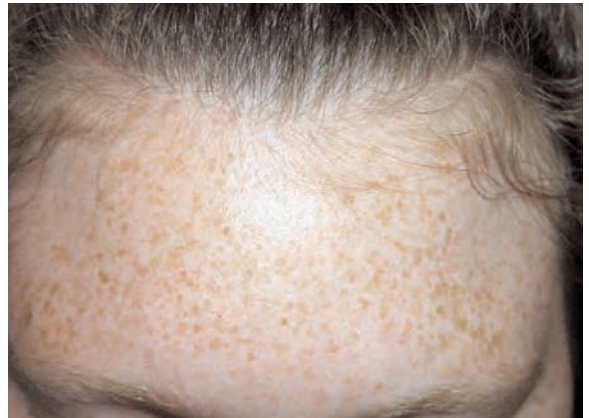### References

- Chima KN, Janniger CK, Schwartz RA. Becker's melanosis. *Cutis* 1996; 57: 311–13
- Formigon M, Alsina MM, Mascaro JN, Rivera F. Becker's nevus and ipsilateral breast hypoplasia androgen-receptor study in two patients. *Arch Dermatol* 1992; 128: 992–3
- Happle R, Koopman RJ. Becker nevus syndrome. *Am J Med Genet* 1997; 68: 357–61
- Nirde P, Dereure O, Belon C, et al. The association of Becker nevus with hypersensitivity to androgens. *Arch Dermatol* 1999; 135: 212–14

### Freckles (ephelides)

#### Major points

- 2–3-mm tan-brown macules appearing in sun-exposed areas, particularly on face, upper torso and arms (Figure 14.13)
- Lightly pigmented individuals usually affected
- Tend to fade in winter and increase in summer



**Figure 14.13** Freckles – this young adult has type 1 skin

### Pathogenesis

- Caused by sun exposure in light-skinned person with a genetic predisposition
- Histology: hyperpigmentation of basal cell layer
- Melanocytes are large and have more numerous and prominent dendritic processes

### Diagnosis

- Clinical presentation

### Differential diagnosis

- Lentigines
- Nevocellular nevi

### Treatment

- No treatment needed
- Sunscreens and protective clothing can decrease the appearance of new freckles

### Prognosis

- Usually permanent but tend to fade with less sun exposure

## References

Levine N, Fulk CS, Rubenzik R. Ephelides (freckles). In: The Pigmentary System. Nordlund JJ, Boissy RE, Hearing VJ, et al. eds. Oxford University Press: New York, 1998: 849–51

Zhang XJ, He PP, Liang YH, et al. A gene for freckles maps to chromosome 4q32-q34. *J Invest Dermatol* 2004; 122: 286–90

## Lentigo simplex

Plural: lentigines

### Major points

- Hyperpigmented macule similar to a freckle, but is darker and does not necessarily show predilection for sun-exposed areas
- Size 2–15 mm in diameter
- Color ranges from brown to black
- Solar lentigines: irregularly shaped, darkly pigmented macules which appear after a severe sunburn; often seen with increased freckles in the same area

### Pathogenesis

- Histology: elongation of rete ridges, increase in numbers of melanocytes in basal layer and increased melanin in melanocytes and keratinocytes

### Diagnosis

- Clinical presentation

### Differential diagnosis

- Junctional nevocellular nevus
- LEOPARD syndrome (multiple lentigines syndrome)
- Peutz–Jeghers syndrome

### Treatment

- Laser ablation: carbon dioxide, Q-switched ruby, neodymium : yttrium–aluminum–garnet, and alexandrite

### Prognosis

- Persists unless treated

## References

Abdelmalek NF, Gerber TL, Menter A. Cardiocutaneous syndromes and associations. *J Am Acad Dermatol* 2002; 46: 161–83

Arnsmeier SL, Paller AS. Pigmentary anomalies in the multiple lentigines syndrome: is it distinct from LEOPARD syndrome? *Pediatr Dermatol* 1996; 13: 100–4

Chamlin SL, Williams ML. Pigmented lesions in adolescents. *Adolesc Med State Art Rev* 2001; 12: 195–212

Chong W-S, Klanwarin W, Giam Y-C. Generalized lentiginosis in two children lacking systemic associations: case report and review of the literature. *Pediatr Dermatol* 2004; 21: 139–45

Cognetta AB Jr, Stolz W, Katz B, et al. Dermatoscopy of lentigo maligna. *Dermatol Clin* 2001; 19: 307–18

Fulk CS. Primary disorders of hyperpigmentation. *J Am Acad Dermatol* 1984; 10: 1–16

O'Neill JF, James WD. Inherited patterned lentiginosis in blacks. *Arch Dermatol* 1989; 125: 1231–5

Rahman SB, Bhawan J. Lentigo. *Intern J Dermatol* 1996; 35: 229–38

Smith SR, O'Grady TC. Reticulated ephelides: 'inkspots' revisited. *Arch Dermatol* 1996; 132: 353–4

Tanzi EL, Lupton JR, Alster TS. Lasers in dermatology: four decades of progress. *J Am Acad Dermatol* 2003; 49:1–31

## Café au lait macules

### Major points

- Discrete brown macules (Figure 14.14)
- Appear at birth or during childhood
- Size 1 mm to >20 cm
- May involve any skin surface
- Neurofibromatosis: >6 macules greater than 0.5 cm in diameter if <15 years old, and 1.5 cm if >15 years (Figure 14.15)

### Pathogenesis

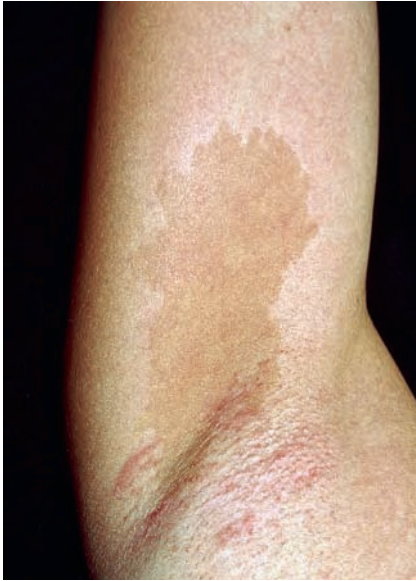- Histology: increased numbers of melanocytes and increased melanin in melanocytes and keratinocytes

### Diagnosis

- Clinical presentation

### Differential diagnosis

- Neurofibromatosis
- McCune–Albright syndrome
- LEOPARD syndrome
- Epidermal nevus



**Figure 14.14** Café au lait macule – associated with neurofibromatosis

- Nevocellular nevus
- Lentigo/lentigines

#### *Treatment*

- None usually needed
- On the face, treatment with a pigmented laser may be temporarily helpful but may need multiple treatments

#### *Prognosis*

- Lesions tend to be stable in size and distribution

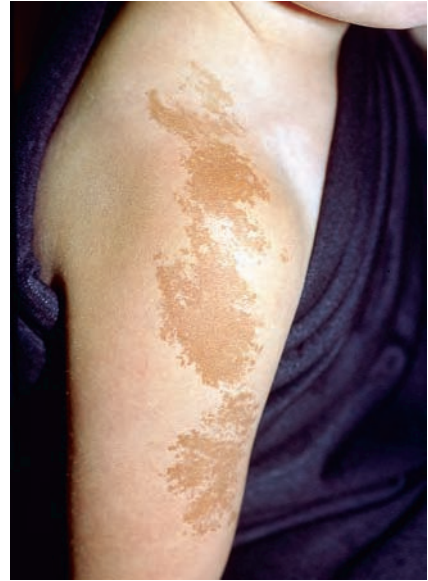#### *References*

Goldberg Y, Dibbern K, Klein J, et al. Neurofibromatosis type 1 – an update and review for the primary pediatrician. *Clin Pediatr* 1996; 35: 545–61

Karabiber H, Sasmaz S, Turanli G, Yakinci C. Prevalence of hypopigmented maculae and café-au-lait spots in idiopathic epileptic and healthy children. *J Child Neurol* 2002; 17: 57–9

Landau M, Krafchik BR. The diagnostic value of café au lait macules. *J Am Acad Dermatol* 1999; 40: 877–90

Okazaki M, Yoshimura K, Suzuki Y, et al. The mechanism of epidermal hyperpigmentation in cafe-au-lait macules of neurofibromatosis type 1 (von Recklinghausen's disease) may be associated with dermal fibroblast-derived stem cell factor and hepatocyte growth factor. *Br J Dermatol* 2003; 148: 689–97



**Figure 14.15** Café au lait macules in a linear distribution, not associated with neurofibromatosis

### **McCune–Albright syndrome**

#### *Major points*

- Triad of findings:
  1. Large irregularly shaped café au lait macules, usually on trunk; may be present at birth, usually evident in infancy
  2. Precocious puberty (especially females)
  3. Polyostotic fibrous dysplasia – usually onset at <10 years of age
- Other findings:
  1. Endocrine abnormalities (e.g. acromegaly, hyperthyroidism, autonomous adrenal hyperplasia)
  2. Ovarian cysts
  3. Facial asymmetry

#### *Pathogenesis*

- Activating missense mutation in gene for alpha subunit of GS, the G protein that stimulates cyclic adenosine monophosphate formation
- Somatic mutation of GS alpha gene in early embryogenesis produces a mosaic of normal and mutant-bearing tissues
- Manifestations and severity depend on number and location of abnormal cells
- Gene locus: 20q13.2

- Gene: GNAS1, stimulatory G protein, alpha subunit (Gsa; activating mutations)

### Diagnosis

- Clinical presentation

### Differential diagnosis

- Neurofibromatosis
- Proteus syndrome

### Treatment

- See Café au lait macules

### Prognosis

- Depends upon endocrine and bony involvement
- Lesions are static

### References

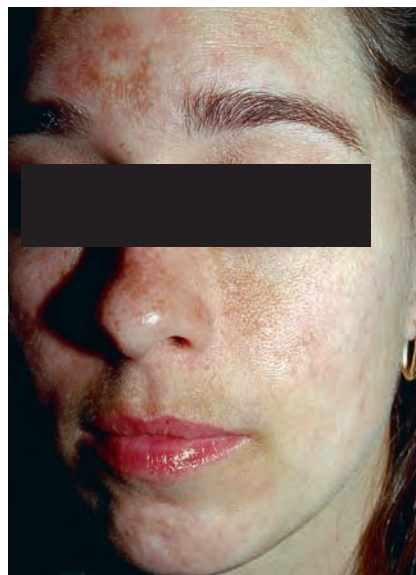
- de Sanctis C, Lala R, Matarazzo P, et al. Pubertal development in patients with McCune-Albright syndrome or pseudohypoparathyroidism. *J Pediatr Endocrinol Metab* 2003; 16 (Suppl 2): 293–6
- Landau M, Krafchik BR. The diagnostic value of café au lait macules. *J Am Acad Dermatol* 1999; 40: 877–90
- Levine MA. Clinical implications of genetic defects in G proteins: oncogenic mutations in G alpha s as the molecular basis for the McCune-Albright syndrome. *Arch Med Res* 1999; 30: 522–31
- Lumbroso S, Paris F, Sultan C. McCune-Albright syndrome: molecular genetics. *J Pediatr Endocrinol Metab* 2002; 15 (Suppl 3): 875–82
- Roth JG, Esterly NB. McCune-Albright syndrome with multiple bilateral café au lait spots. *Pediatr Dermatol* 1991; 8: 35–9
- Shenker A, Weinstein LS, Moran A, et al. Severe endocrine and nonendocrine manifestations of the McCune-Albright syndrome associated with activating mutations of stimulatory G protein GS. *J Pediatr* 1993; 123: 509–18
- Weinstein LS, Shenker A, Gejman PV, et al. Activating mutations of the stimulatory G protein in the McCune-Albright syndrome. *N Engl J Med* 1991; 325: 1688–95

## Melasma

### Major points

- Common acquired hypermelanosis in teenage and adult women

- Increased macular pigmentation in sun-exposed areas (Figure 14.16)
- Symmetric, patchy, facial melanosis
- Often associated with pregnancy or oral contraceptives



**Figure 14.16** Melasma – can be caused by oral contraceptives

- Female/male ratio >1
- More common in Latinos and Asians

### Pathogenesis

- Increase in number and activity of melanocytes
- Histology: increase in epidermal and/or dermal melanin

### Diagnosis

- Clinical presentation

### Differential diagnosis

- Postinflammatory hyperpigmentation
- Phytophotocontact dermatitis

### Treatment

- Discontinuation of oral contraceptives
- Topical sunscreens
- Bleaching creams with hydroquinone 2–4% BID for <6 months
- Cover-up makeup



### Prognosis

- Exacerbated by sun exposure
- Chronic condition which may wax and wane

### References

Grimes PE. Melasma. Etiologic and therapeutic consideration. *Arch Dermatol* 1995; 131: 1453–7

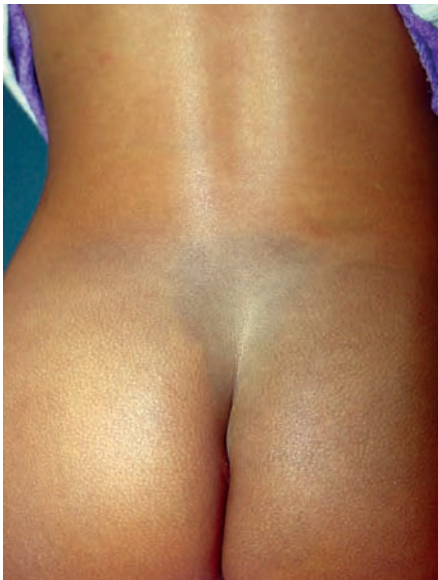Guevara IL, Pandya AG. Safety and efficacy of 4% hydroquinone combined with 10% glycolic acid, antioxidants, and sunscreen in the treatment of melasma. *Int J Dermatol* 2003; 42: 966–72

## Mongolian spot

Synonym: congenital dermal melanocytosis

### Major points

- Clinical
  1. Blue-gray macules with indistinct margins (Figure 14.17)
  2. Common in Asians and Blacks, occasionally in Whites
  3. Locations – lumbosacral area most common; aberrant lesions can be on face, extremities and torso
  4. Size ranges from a few centimeters to >20 cm.
  5. Can be multiple or single



**Figure 14.17** Mongolian spot in the typical location on the lumbar back

### Pathogenesis

- Dermal pigmentation appears gray-blue because of decreased reflectance in longer wavelength region compared with surrounding area

### Diagnosis

- Clinical presentation
- Histology: dermal melanocytes with fully melanized melanosomes

### Differential diagnosis

- Bruises
- Congenital nevocellular nevus

### Treatment

- Opaque cosmetics
- Q-switched ruby laser

### Prognosis

- Natural course of lumbosacral macules is to fade in childhood
- Aberrant lesions stay indefinitely and tend not to fade

### References

Bashiti HM, Blair JD, Triska RA, Keller L. Generalized dermal melanocytosis. *Arch Dermatol* 1981; 117: 791–3

Cordova A. The mongolian spot. *Clin Pediatr* 1981; 20: 714–22

Fulk CS. Primary disorders of hyperpigmentation. *J Am Acad Dermatol* 1984; 10: 1–16

Hori Y, Takayama O. Circumscribed dermal melanoses. Classification and histologic features. *Dermatol Clin* 1988; 6: 315–26

Leung AK, Kao CP. Extensive mongolian spots with involvement of the scalp. *Pediatr Dermatol* 1999; 16: 371–2

Smalek JE. Significance of mongolian spots. *J Pediatr* 1980; 97: 504–5

Stanford DG, Georgouras KE. Dermal melanocytosis: a clinical spectrum. *Aust J Dermatol* 1996; 37: 19–25

Van Gysel D, Oranje AP, Stroink H, Simonsz HJ. Phakomatosis pigmentovascularis. *Pediatr Dermatol* 1996; 13: 33–5

## Nevus of Ota/nevus of Ito

Synonyms for nevus of Ota: oculodermal melanocytosis, nevus fuscoceruleus ophthalmomaxillaris

Synonym for nevus of Ito: nevus fuscoceruleus acromiodeltoideus

### Major points

- Clinical
  1. Sporadic inheritance
  2. More common in Asians and Blacks
  3. Female/male ratio >1
  4. Characterized by unilateral, blue-black macules intermingled with small brown macules, giving a mottled appearance (Figure 14.18)
  5. Location of nevus of Ota: skin innervated by V1 and V2; mucosa, conjunctiva, tympanic membrane may be involved
  6. Location of nevus of Ito: unilateral pigmentation over supraclavicular, deltoid and scapular regions
  7. Half the lesions present at birth; remainder appear at puberty

### Pathogenesis

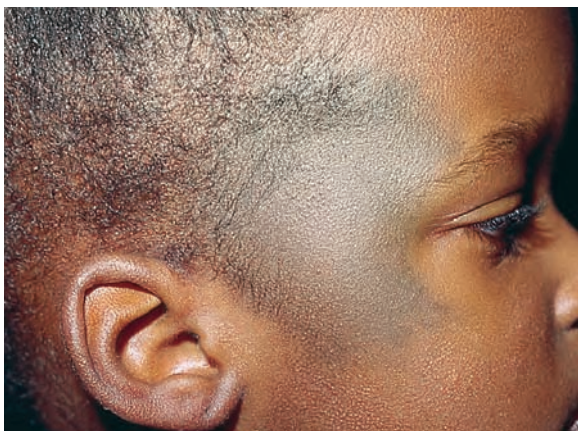- Histology: melanocytes widely scattered in reticular dermis with melanosomes singly dispersed and fully melanized

### Diagnosis

- Clinical presentation

### Differential diagnosis

- Congenital nevocellular nevus
- Mongolian spot



**Figure 14.18** Nevus of Ota – dark gray patch around the eye (published in *An Illustrated Dictionary of Dermatologic Syndromes* by SB Mallory and S Leal-Khoury)

### Treatment

- Q-switched ruby laser – may require multiple treatments
- Cosmetic camouflage

### Prognosis

- Tends to enlarge and darken with time
- Very rarely, melanoma arises within the lesion
- Glaucoma arises in 10%

### References

- Fulk CS. Primary disorders of hyperpigmentation. *J Am Acad Dermatol* 1984; 10: 1–16
- Hirayama T, Suzuki T. A new classification of Ota's nevus based on histopathological features. *Dermatologica* 1991; 183: 169–72
- Kono T, Chan HH, Ercocen AR, et al. Use of Q-switched ruby laser in the treatment of nevus of Ota in different age groups. *Lasers Surg Med* 2003; 32: 391–5
- Lee CS, Lim HW. Cutaneous diseases in Asians. *Dermatol Clin* 2003; 21: 669–77
- Leung AK, Kao CP, Lee TK. Mongolian spots with involvement of the temporal area. *Int J Dermatol* 2001; 40: 288–9
- Liesegang TJ. Pigmented conjunctival and scleral lesions. *Mayo Clin Proc* 1994; 69: 151–61
- Watanabe S, Takahashi H. Treatment of nevus of Ota with the Q-switched ruby laser. *N J Engl J Med* 1994; 331: 1745–50

## Incontinentia pigmenti

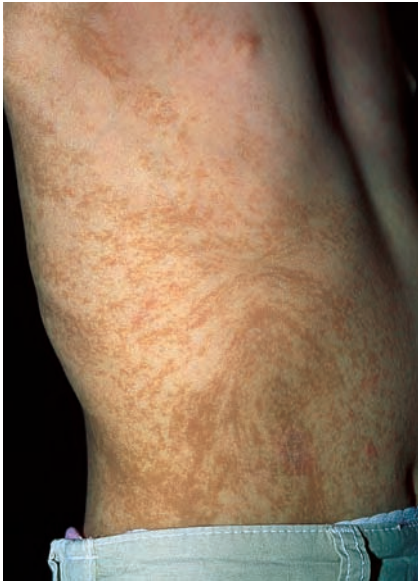Synonym: Block–Sulzberger syndrome

### Major points

- X-linked dominant disorder characterized by linear rows of blisters in first year of life, followed by swirling hyperpigmentation which follow Blaschko lines
- Four stages which can overlap:
  1. Bullous stage (age birth to ~1 year) – linear rows of blisters following Blaschko lines on extremities and occasionally trunk; lesions can recur or new lesions can develop
  2. Verrucous stage (~3 months to 3 years) – linear, verrucous lesions develop usually on extremities
  3. Hyperpigmented stage (1 year to 20 years) – whorls of dirty-brown to slate-gray

hyperpigmentation mainly on the trunk following Blaschko lines; fades in adolescence (Figure 14.19)

4. Hypopigmented stages (adulthood) – streaks of hairless atrophic hypopigmentation on the extremities; often subtle



**Figure 14.19** Incontinentia pigmenti (stage 3) – whorling pigmentation following Blaschko lines

- Associated manifestations:
  1. Dental (65–80%) – anodontia, hypodontia and others
  2. Hair (38–50%) – thin or sparse hair, patches of alopecia (especially vertex), woolly hair nevus
  3. CNS (10–31%) – seizures, mental retardation, hemiplegia and others
  4. Eye (35–40%) – strabismus, abnormalities of developing retinal vessels
  5. Skeletal (14%) – chondrodystrophy, cleft lip and/or palate, clubfoot, contractures, hemiatrophy and others
  6. Nails (7–40%) – onychogryphosis, pitting, ridging, subungual keratotic tumors and others
  7. Breast – unilateral aplasia
  8. Eosinophilia (up to 65%) in infancy

### Pathogenesis

- X-linked dominant disorder, usually lethal in male

- Gene locus Xq28. Gene: NEMO (nuclear factor  $\kappa$ B essential modulator IKK-gamma)

### Diagnosis

- Clinical diagnosis but confirmed with biopsy of skin in early life
- Histology:
  1. Bullous stage: numerous eosinophils with spongiosis in the epidermis
  2. Verrucous stage: eosinophilic dyskeratosis, hyperkeratosis, acanthosis, papillomatosis
  3. Pigmented stage: melanin in dermis or in dermal macrophages
  4. Hypopigmented stage: absence of skin appendages; mild epidermal atrophy; melanocytes decreased or normal

### Differential diagnosis

- Bullous stage:
  1. Herpes simplex
  2. Bullous impetigo
  3. Other bullous disorders (see Chapter 6)
- Verrucous stage:
  1. Linear epidermal nevus
  2. Warts
- Pigmented stage:
  1. Epidermal nevus
  2. Linear and whorled hypermelanosis
- Hypopigmented stage:
  1. Anetoderma
  2. Goltz syndrome

### Treatment

- Symptomatic treatment
- Skin in neonatal period – topical care and topical antibiotics
- Other organ systems should be examined as indicated by specialists: ophthalmology, audiology, neurology, dental, genetics

### Prognosis

- Watch for seizures early in life (which often improve with time) with referral to neurologist if indicated; magnetic resonance imaging (MRI) or computerized tomography (CT) scan do not need to be routinely ordered
- Birth defects (e.g. alopecia, eye abnormalities) are permanent
- Pigmentary changes improve with age

## References

- Hadj-Rabia S, Froidevaux D, Bodak N, et al. Clinical study of 40 cases of incontinentia pigmenti. *Arch Dermatol* 2003; 139: 1163–70
- Happle R. A fresh look at incontinentia pigmenti. *Arch Dermatol* 2003; 139: 1206–8
- Hennel SJ, Ekert PG, Volpe JJ, Inder TE. Insights into the pathogenesis of cerebral lesions in incontinentia pigmenti. *Pediatr Neurol* 2003; 29: 148–50
- Shah SN, Gibbs S, Upton CJ, et al. Incontinentia pigmenti associated with cerebral palsy and cerebral leukomalacia: a case report and literature review. *Pediatr Dermatol* 2003; 20: 491–4
- Zvulunov A, Esterly NB. Neurocutaneous syndromes associated with pigmentary skin lesions. *J Am Acad Dermatol* 1995; 32: 915–35

## Erythema dyschromicum perstans

Synonym: ashy dermatosis

### Major points

- Idiopathic, acquired, generalized, macular, blue-gray hyperpigmentation
- Clinical features
  1. Common in Latin Americans
  2. Sporadic
  3. Healthy individuals from childhood to adolescence
  4. May begin as erythematous macules which fade and becomes slate-gray or ashy or may begin *de novo* as gray macules (Figure 14.20)
  5. Lesions slowly enlarge and coalesce

### Pathogenesis

- Pathogenesis unknown
- Histology: increased melanin in dermis and epidermis with vacuolization of basal cell layer

### Diagnosis

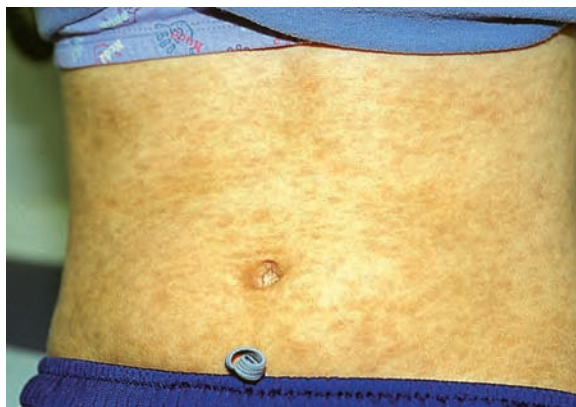
- Clinical presentation

### Differential diagnosis

- Mongolian spots
- Postinflammatory hyperpigmentation
- Lichen planus

### Treatment

- None very effective



**Figure 14.20** Erythema dyschromicum perstans – slate-gray macules with indistinct borders

### Prognosis

- Usually static once process stops

### References

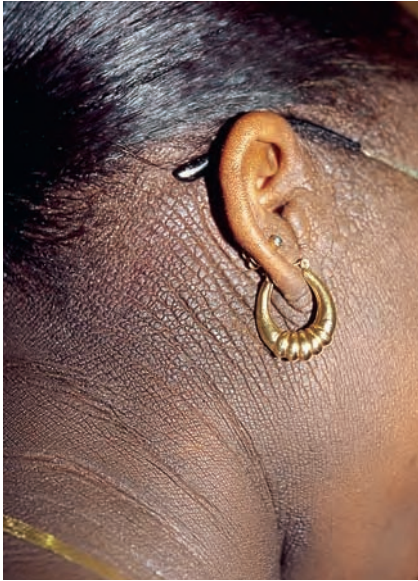- Meffert JJ. Erythema dyschromicum perstans: a case report and review. *Cutis* 2002; 70: 62
- Metin A, Calka O, Ugras S. Lichen planopilaris coexisting with erythema dyschromicum perstans. *Br J Dermatol* 2001; 145: 522–3
- Osswald SS, Proffer LH, Sartori CR. Erythema dyschromicum perstans: a case report and review. *Cutis* 2001; 68: 25–8
- Pandya AG, Guevara IL. Disorders of hyperpigmentation. *Dermatol Clin* 2000; 18: 91–8
- Silverberg NB, Herz J, Wagner A, Paller AS. Erythema dyschromicum perstans in prepubertal children. *Pediatr Dermatol* 2003; 20: 529–30

## Acanthosis nigricans

### Major points

- Clinical manifestations:
  1. Brownish-black, velvety thickening of the skin with increased skin markings (Figure 14.21)
  2. Prominent in axillae, posterior neck, sides of the neck, groin, antecubital, popliteal surfaces and the umbilical area
  3. May have soft papillomas (skin tags) or warty nodules on the affected skin
  4. Rarely may affect mucocutaneous skin: eyelids, conjunctivae, lips, oral cavity, vulva





**Figure 14.21** Acanthosis nigricans – typical velvety, dark appearance on the neck

- Epidemiology:
    1. Male/female ratio = 1
    2. Occurs most commonly during puberty, or in early adulthood
    3. Peak prevalence in childhood is age ~12 years
    4. Strong association with obesity: 66% prevalence in adolescents weighing >200% of their ideal body weight
  - Benign acanthosis nigricans (AN)
    1. Rare autosomal dominant genodermatosis
    2. Associated with multiple melanocytic nevi
    3. Presents at birth or early childhood
  - Obesity-associated AN
    1. Most common form
    2. Clinical course of skin lesions follows weight gain and loss
  - Acral AN
    1. Occurs in healthy individuals
    2. Distribution over dorsal hands and feet
  - Syndromic AN – syndromes with associated insulin resistance
    1. Lawrence–Seip syndrome (lipodystrophy and AN)
    2. Leprechaunism
    3. Polycystic ovary disease
    4. Crouzon syndrome
    5. Others
  - Malignancy-associated AN
    1. Rare in children
    2. Sudden onset and rapid spread of skin involvement
    3. Associated with internal malignancy (e.g. gastric cancer, Wilms tumor)
  - Medication-induced AN – e.g. nicotinic acid, diethylstilbestrol (DES), corticosteroids, estrogens, oral contraceptives
- Pathogenesis**
- Hyperinsulinemia is implicated in pathogenesis
    1. Usually caused by underlying insulin resistance in obesity or syndromes
    2. Excess insulin binds to receptors on keratinocytes and fibroblasts, leading to increased proliferation of epidermal cells
  - Tumor product with insulin-like activity or transforming growth factor (TGF- $\alpha$ ) activity is implicated in malignant AN
  - Histology: hyperkeratosis and epidermal papillomatosis; areas of acanthosis alternating with atrophy
- Diagnosis**
- Clinical features
  - Evaluate for underlying endocrine abnormality or malignancy if indicated
- Differential diagnosis**
- Confluent and reticulate papillomatosis
  - Retained keratin
- Treatment**
- Directed at correcting underlying disease
    1. Weight loss
    2. Correction of underlying endocrine dysfunction
    3. Discontinue offending drug
    4. Treat underlying malignancy
  - If mild AN, may not require treatment
  - Topical emollients, keratolytics, topical retinoid (e.g. tretinoin 0.1% cream once daily for 2 weeks) or low-dose systemic retinoids
- Prognosis**
- Clinical course tends to follow exacerbation or resolution of underlying disorder
  - Obesity-associated AN may improve with weight loss



## References

- Brockow K, Steinkraus V, Rinninger F, et al. Acanthosis nigricans: a marker for hyperinsulinemia. *Pediatr Dermatol* 1995; 12: 323–6
- Hermanns-Le T, Hermanns JF, Pierard GE. Juvenile acanthosis nigricans and insulin resistance. *Pediatr Dermatol* 2002; 19: 12–14
- Panidis D, Skiadopoulou S, Rousso D, et al. Association of acanthosis nigricans with insulin resistance in patients with polycystic ovary syndrome. *Br J Dermatol* 1995; 132: 936–41
- Schroeder B. Early diagnosis, presenting complaints, and management of hyperandrogenism in adolescents. *Curr Wom Health Rep* 2001; 1: 124–30
- Schwartz RA, Janniger CK. Childhood acanthosis nigricans. *Cutis* 1995; 55: 337–9
- Torley D, Bellus GA, Munro CS. Genes, growth factors and acanthosis nigricans. *Br J Dermatol* 2002; 147: 1096–101
- Uyttendaele H, Koss T, Bagheri B, et al. Generalized acanthosis nigricans in an otherwise healthy young child. *Pediatr Dermatol* 2003; 20: 254–6

## Confluent and reticulated papillomatosis

Synonym: Gougerot and Carteaud syndrome

### Major points

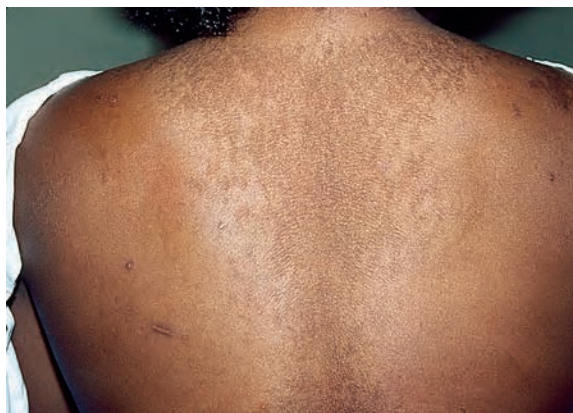- Distinctive clinical disorder of adolescents and young adults
- Female/male ratio >1
- Blacks/Whites ratio >1
- Presents with brown hyperkeratotic papules coalescing into plaques with reticulate periphery (Figure 14.22)
- Location: chest, inframammary area, neck, shoulders, interscapular back and epigastric area

### Pathogenesis

- Unknown etiology
- Considered a variant of acanthosis nigricans or a disorder of keratinization
- May be related to endocrine abnormalities or host response to *Pityrosporum orbiculare*

### Diagnosis

- Clinical findings
- Histology: similar to acanthosis nigricans with undulating hyperkeratosis, papillomatosis and mild acanthosis with basal hyperpigmentation



**Figure 14.22** Confluent and reticulated papillomatosis – lesions can resemble tinea versicolor but a scraping for hyphae is negative, and it does not respond to antifungal therapy

### Differential diagnosis

- Tinea versicolor
- Acanthosis nigricans

### Treatment

- Oral minocycline 100 mg BID
- Variable success with topical therapy: salicylic acid, selenium sulfide, antifungals, 5-fluorouracil, calcipotriene, retinoids
- Oral retinoids if minocycline is ineffective

### Prognosis

- Benign persistent course with recurrences

### References

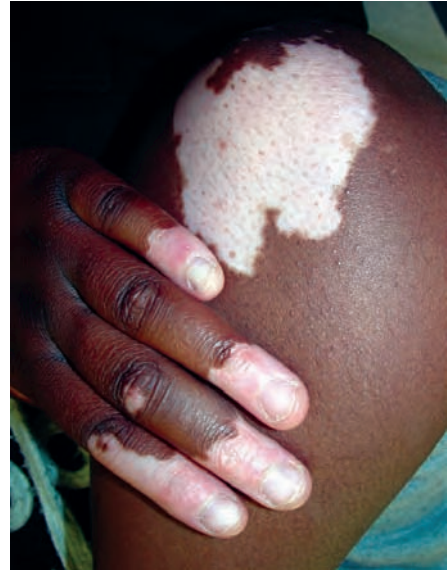- Bowman PH, Davis LS. Confluent and reticulated papillomatosis: response to tazarotene. *J Am Acad Dermatol* 2003; 48(5 Suppl): S80–1
- Hirokawa M, Matsumoto M, Iizuka H. Confluent and reticulated papillomatosis: a case with concurrent acanthosis nigricans associated with obesity and insulin resistance. *Dermatology* 1994; 188: 148–51
- Jang HS, Oh CK, Cha JH, et al. Six cases of confluent and reticulated papillomatosis alleviated by various antibiotics. *J Am Acad Dermatol* 2001; 44: 652–5
- Mutasim DF. Confluent and reticulated papillomatosis without papillomatosis. *J Am Acad Dermatol* 2003; 49: 1182–4
- Shimizu S, Han-Yaku H. Confluent and reticulated papillomatosis responsive to minocycline. *Dermatology* 1997; 194: 59–61

## HYPOPIGMENTED DISORDERS

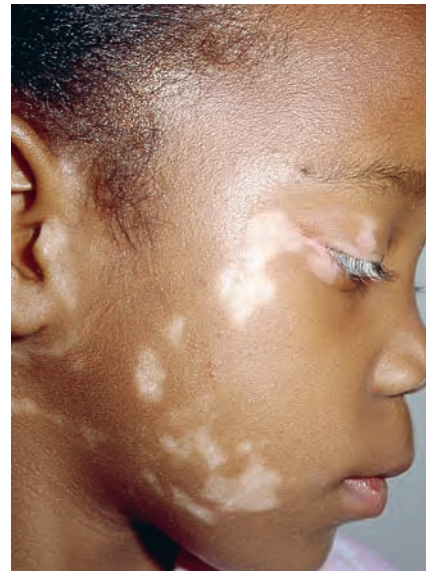### Vitiligo

#### Major points

- Common, sometimes heritable, acquired loss of pigment in interfollicular melanocytes
- Affects ~1–2% of all races
- Types
  1. Generalized – most common type; macules are symmetrical involving extensor surfaces of distal digits, knees, elbows and periorificial areas; mucosal involvement common (Figure 14.23)
  2. Segmental – unilateral macules with dermatomal or segmental configuration which remains stable and is unlikely to be associated with autoimmune diseases; trigeminal area most common (Figure 14.24)
  3. Focal – an isolated macule or a few scattered macules
  4. Universal – widespread vitiligo; often associated with multiple endocrinopathy syndrome
- Clinical:
  1. Onset at any age from birth to 81 years, with majority of cases beginning in childhood
  2. Macules are chalky white, round or oval, with fairly distinct often scalloped margins measuring several millimeters to many centimeters without any epidermal changes
  3. Trichrome vitiligo: presence of a band of lighter skin which interfaces between white and normal color displaying three colors: white, light tan and normal skin color (Figure 14.25)
  4. Lesions begin as small areas and enlarge over time with coalescence, which can be extensive
  5. Can exhibit Koebner phenomenon with involvement after injury
  6. Associated with poliosis, prematurely gray hair, halo nevi and alopecia areata
- Generalized vitiligo can be associated with various autoimmune disorders: thyroid disease, diabetes mellitus, Addison disease, pernicious anemia, multiple autoantibodies, hypoparathyroidism
- Ocular involvement: iritis, retinal pigmentary abnormalities, chorioretinitis; visual acuity usually normal
- Rare syndromes:
  1. Vogt–Koyanagi–Harada syndrome: rare multisystem disease characterized by aseptic



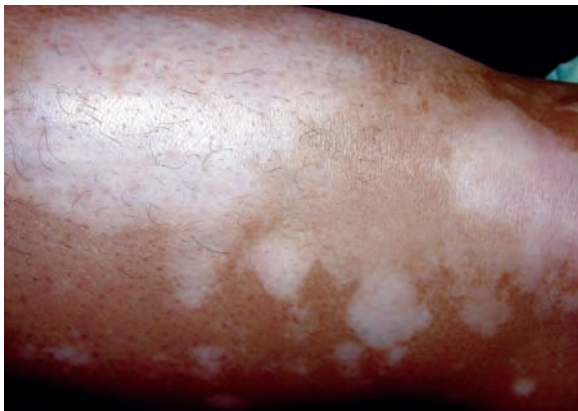**Figure 14.23** Vitiligo classically on the fingertips, knees and elbows



**Figure 14.24** Vitiligo – acquired depigmented patches in a segmental distribution

meningoencephalitis, vitiligo, poliosis, uveitis, dysacusia

2. Azezzandrini syndrome: characterized by unilateral facial vitiligo, poliosis (white patches of hair), ipsilateral pigmentary retinitis with gradual visual loss, and deafness



**Figure 14.25** Vitiligo – trichrome color change

### *Pathogenesis*

- Generalized vitiligo is a polygenic disorder; up to 30% have a family member affected
- Segmental vitiligo is not inherited
- Theories for mechanism of destruction of melanocytes: autoimmune, neurochemical, or self-destruction (toxic)

### *Diagnosis*

- Clinical presentation. Wood's lamp examination may be helpful to identify lesions in light-skinned individuals
- Histology: loss of melanocytes; lymphocytes may be present in upper dermis in evolving macules

### *Differential diagnosis*

- Postinflammatory hypopigmentation
- Pityriasis alba
- Tinea versicolor
- Tuberous sclerosis
- Nevus depigmentosus
- Chemical leukoderma (phenolic compounds)
- Lupus erythematosus
- Melanoma-associated leukoderma
- Piebaldism
- Waardenburg syndrome
- Leprosy

### *Treatment*

- Education about disease is most helpful
- Sunscreens to vitiliginous areas to avoid sunburn

- Repigmentation (slow and requires commitment from patient and parents):
  1. Topical corticosteroids (mid-strength to ultra-potent) 1–2 times a day
  2. Psoralen (oral or topical) plus UVA light (PUVA)
  3. UVB light, 2–3 times per week
  4. Success depends upon presence of follicular melanocytes
- Surgical techniques with micrografts from uninvolved skin can be used only if patches are stable (non-progressive)
- Depigmentation with monobenzylether of hydroquinone 20% should be reserved for only those patients who have lost a large percentage of color and have no hope of repigmenting naturally
- Psychosocial factors should be addressed
- Cover-up cosmetics (e.g. Dermablend®) or temporary dyes

### *Prognosis*

- Natural course of generalized vitiligo is unpredictable, but most vitiligo is slowly progressive. Spontaneous regression rare. Treatment can repigment some areas (face responds best)
- Segmental vitiligo is usually stable but can respond to treatment

### *References*

- Drake LA, Dinehart SM, Farmer ER, et al. Guidelines of care of vitiligo. *J Am Acad Dermatol* 1996; 35: 620–6
- Gauthier Y, Cario Andre M, Taieb A. A critical appraisal of vitiligo etiologic theories. Is melanocyte loss a melanocytorrhagy? *Pigment Cell Res* 2003; 16: 322–32
- Herane MI. Vitiligo and leukoderma in children. *Clin Dermatol* 2003; 21: 283–95
- Hoffman MD, Dudley C. Suspected Alezzandrini's syndrome in a diabetic patient with unilateral retinal detachment and ipsilateral vitiligo and poliosis. *J Am Acad Dermatol* 1992; 26: 496–8
- Majumder PP, Nordlund JJ, Nath SK. Pattern of familial aggregation of vitiligo. *Arch Dermatol* 1993; 129: 994–8
- Ongenae K, Van Geel N, Naeyaert JM. Evidence for an autoimmune pathogenesis of vitiligo. *Pigment Cell Res* 2003; 16: 90–100
- Schaffer JV, Bologna JL. The treatment of hypopigmentation in children. *Clin Dermatol* 2003; 21: 296–310

Tsukamoto K, Osada A, Kitamura R, et al. Approaches to repigmentation of vitiligo skin: new treatment with ultrasonic abrasion, seed-grafting and psoralen plus ultraviolet A therapy. *Pigment Cell Res* 2002; 15: 331–4

## Albinism

Synonym: oculocutaneous albinism

### Major points

- General
  1. Albinism includes a group of genetic disorders with dilution or absence of ocular and cutaneous pigmentation
  2. All races affected
  3. Lack of pigment is caused by an abnormal maturation of melanosomes
- Types of oculocutaneous albinism (OCA):
  1. OCA 1A (tyrosinase-negative OCA)
    - a. Marked hypopigmentation of the skin and eyes (Figure 14.26)
    - b. Skin varies from pink to milky white
    - c. Hair white
    - d. Eyes are pale blue with a pink or red reflex which can be seen through the iris
    - e. Severe photophobia caused by lack of pigment
    - f. Associated ocular abnormalities: decreased visual acuity, nystagmus and strabismus
  2. OCA 1B (minimal pigment OCA, yellow OCA)
    - a. Hair begins white but may progress to dark blonde or brown in adolescence

- b. Irides progressively darken
  - c. Skin can tan minimally
  - d. Nevus and freckles may develop
  - e. Temperature-sensitive variant: darkly pigmented hair on the arms and legs, and lightly pigmented hair centrally
3. OCA 2 (tyrosinase-positive OCA)
  - a. Dilution of pigment of hair and iris but not complete loss
  - b. Skin color paler than in relatives
  - c. Hair white or light blonde
  - d. With maturity, pigment increases and nevi and freckles can develop
  - e. Photophobia and nystagmus are present, but not as severe as in OCA 1A
  - f. More common in African-Americans
4. OCA 3 (rufous OCA)
  - a. Red hair and lighter skin

### Pathogenesis

- OCA 1: mutation of the tyrosinase gene (chromosome 11p1)
  1. Complete loss with phenotype OCA 1A; reduced activity (5–10% of normal) results in OCA 1B
- OCA 2: mutation of the P gene (chromosome 15q11.2-12), membrane transporter gene
- OCA 3: mutation of TYRP1 gene affecting melanin synthesis; chromosome 9p23

### Diagnosis

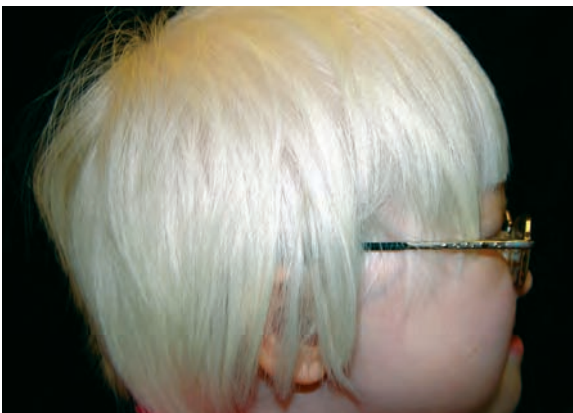- Clinical presentation
- Genetic testing
- Electron microscopy can determine the stages of melanosomes

### Differential diagnosis

- Prader–Willi syndrome
- Angelman syndrome
- Homocystinuria
- Apert syndrome
- Vitiligo (generalized)
- Phenylketonuria

### Treatment

- Photoprotection is most important to reduce risk of cutaneous malignancies
- Ophthalmological evaluation and follow-up



**Figure 14.26** Albinism – type 1 oculocutaneous albinism



### Prognosis

- Cutaneous squamous cell carcinoma and basal cell carcinoma along with other signs of photoaging are common in unprotected skin

### References

- King RA. Albinism. In *The Pigmentary System*. Nordlund JJ, Boissy RE, Hearing VJ, et al. eds). Oxford University Press: New York, 1998: 553–75
- Oetting WS, Fryer JP, Shriram S, King RA. Oculocutaneous albinism type 1: the last 100 years. *Pigment Cell Res* 2003; 16: 307–11
- Oetting WS. The tyrosinase gene and oculocutaneous albinism type 1 (OCA1): a model for understanding the molecular biology of melanin formation. *Pigment Cell Res* 2000; 13: 320–5
- Orlow SJ. Albinism: an update. *Semin Cutan Med Surg* 1997; 16: 24–9
- Sarangarajan R, Boissy RE. Tyrp1 and oculocutaneous albinism type 3. *Pigment Cell Res* 2001; 14: 437–44
- Tomita Y. The molecular genetics of albinism and piebaldism. *Arch Dermatol* 1994; 130: 355–8

## Waardenburg syndrome

### Major points

- Waardenburg syndrome type I
  1. Depigmented patches of the skin and hair
  2. Heterochromia irides
  3. Deafness
  4. Dystopia canthorum
  5. Broad nasal root
  6. Synophrys (confluence of the medial eyebrows)
  7. Hypoplasia of the nasal alae
  8. Gene/gene locus: PAX 3 gene (transcription factor for melanocyte proliferation and migration from the neural crest)/2q35
  9. Autosomal dominant
- Waardenburg syndrome type II
  1. Similar to type I except without dystopia canthorum
  2. Gene/gene locus: MITF gene (microphthalmia-associated transcription factor)/3p14.1-12.3 and others
  3. Autosomal dominant
- Waardenburg syndrome type III (Klein-Waardenburg syndrome)
  1. Similar to type I with limb abnormalities
  2. Gene/gene locus: PAX 3 gene/2q35
  3. Autosomal dominant

- Waardenburg syndrome type IV
  1. Similar to type I with Hirschsprung disease
  2. Gene/gene locus: endothelin B receptor gene/20q13.2-q13.3
  3. Autosomal recessive

### References

- da Silva EO. Waardenburg I syndrome: a clinical and genetic study of two large Brazilian kindreds and literature review. *Am J Med Genet* 1991; 40: 65–74
- Mollaaghababa R, Pavan WJ. The importance of having your SOX on: role of SOX10 in the development of neural crest-derived melanocytes and glia. *Oncogene* 2003; 22: 3024–34
- Read AP, Newton VE. Waardenburg syndrome. *J Med Genet* 1997; 34: 656–65
- Shanske A, Ferreira JC, Leonard JC, et al. Hirschsprung disease in an infant with a contiguous gene syndrome of chromosome 13. *Am J Med Genet* 2001; 102: 231–6
- Shibahara S, Takeda K, Yasumoto K, et al. Microphthalmia-associated transcription factor (MITF): multiplicity in structure, function, and regulation. *Symposium Proceedings. J Invest Dermatol* 2001; 6: 99–104

## Piebaldism

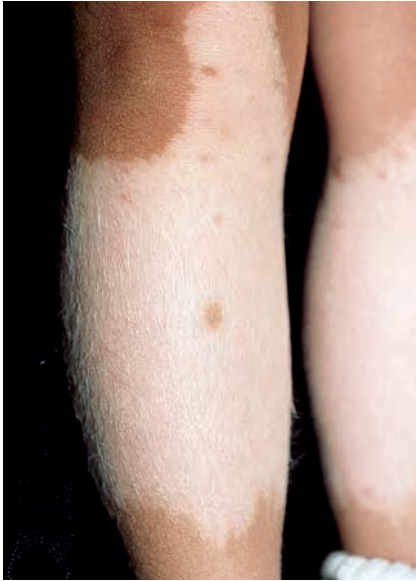### Major points

- Clinical features
  1. Symmetrical well-demarcated patches of depigmented skin and hair with V-shape on forehead and frontal scalp, patches on anterior chest and abdomen, and extremities around elbows and knees with sparing of hands and feet (Figure 14.27)
  2. No progressive loss of pigment
  3. No extracutaneous findings except in a few families with deafness
  4. 80–90% of patients have a white forelock

### Pathogenesis

- Defective cell proliferation and migration of melanocytes during embryogenesis caused by mutation in c-KIT gene which is responsible for melanocytic proliferation; chromosome 14q12





**Figure 14.27** Piebaldism – symmetrical congenital depigmentation with thumbprint hypermelanotic macules within the depigmented patches

### Diagnosis

- Clinical diagnosis
- Confirmed by genetic analysis with mutations on c-KIT gene
- Histology: melanocytes are absent from white patches

### Differential diagnosis

- Waardenburg syndrome
- Vitiligo

### Treatment

- Cosmetic covering
- Sun protection of the white patches

### Prognosis

- White patches stable and may develop actinic keratoses

### References

- Boissy RE, Nordlund JJ. Molecular basis of congenital hypopigmentary disorders in humans: a review. *Pigment Cell Res* 1997; 10: 12–24
- Richards KA, Fukai K, Oiso N, Paller AS. A novel KIT mutation results in piebaldism with progressive depigmentation. *J Am Acad Dermatol* 2001; 44: 288–92

Spritz RA. Molecular basis of human piebaldism. *J Invest Dermatol* 1994; 103: 137S–140S

Spritz RA. Piebaldism, Waardenburg syndrome, and related disorders of melanocyte development. *Semin Cutan Med Surg* 1997; 16: 15–23

Syrris P, Malik NM, Murday VA, et al. Three novel mutations of the proto-oncogene KIT cause human piebaldism. *Am J Med Genet* 2000; 95: 79–81

Tomita Y. The molecular genetics of albinism and piebaldism. *Arch Dermatol* 1994; 130: 355–8

## Hermansky–Pudlak syndrome

### Major points

- Tyrosinase-positive albinism
- Bleeding diathesis with epistaxis, gingival bleeding or bleeding after surgical procedures
- Autosomal recessive; more common in Puerto Ricans and Dutch
- Ceroid storage disease affecting lungs, gut, platelets
- Gene/gene locus: HPS1 (transmembrane protein)/chromosome 10q2 and others

### References

- Gahl WA, Brantly M, Kaiser-Kupfer MI, et al. Genetic defects and clinical characteristics of patients with a form of oculocutaneous albinism (Hermansky–Pudlak syndrome). *N Engl J Med* 1998; 338: 1258–64
- Huizing M, Boissy RE, Gahl WA. Hermansky–Pudlak syndrome: vesicle formation from yeast to man. *Pigment Cell Res* 2002; 15: 405–19
- Huizing M, Gahl WA. Disorders of vesicles of lysosomal lineage: the Hermansky–Pudlak syndromes. *Curr Mol Med* 2002; 2: 451–67
- Starcevic M, Nazarian R, Dell’Angelica EC. The molecular machinery for the biogenesis of lysosome-related organelles: lessons from Hermansky–Pudlak syndrome. *Semin Cell Dev Biol* 2002; 13: 271–8
- Vanhoetghem O, Courtens W, Andre J, et al. Hermansky–Pudlak syndrome: a case report and discussion. *Pediatr Dermatol* 1998; 15: 374–7

## Phenylketonuria

### Major points

- Caused by absence of hepatic phenylalanine hydroxylase (PAH) with build-up of phenylalanine

- If untreated, phenylketonuria results in mental retardation and pigment dilution
- Most patients have blonde hair, blue eyes, fair skin, photosensitivity, mousy body odor and neurologic disturbances
- When treated, skin coloration reverts to normal
- Autosomal recessive
- Gene/gene locus: phenylalanine hydroxylase/12q24.1 and others

### References

Beasley MG, Costello PM, Smith I. Outcome of treatment in young adults with phenylketonuria detected by routine neonatal screening between 1964 and 1971. *Q J Med* 1994; 87: 155–60

Erlandsen H, Patch MG, Gamez A, et al. Structural studies on phenylalanine hydroxylase and implications toward understanding and treating phenylketonuria. *Pediatrics* 2003; 112: 1557–65

Mineroff AD. Phenylketonuria. In *The Pigmentary System*. Nordlund JJ, Boissy RE, Hearing VJ, King RA, Ortonne JP, eds. Oxford University Press: New York, 1998: 590–1

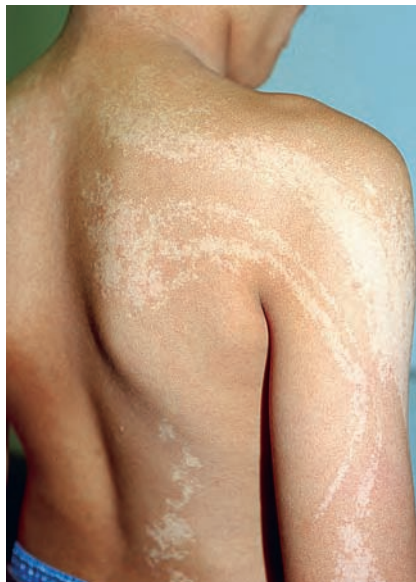Zschocke J. Focus on the molecular genetics of phenylketonuria. *Hum Mutat* 2003; 21: 331–2

## Hypomelanosis of Ito

Synonym: incontinentia pigmenti achromians

### Major points

- Hypopigmented streaks and whorls, mainly on the trunk, following the lines of Blaschko (Figure 14.28)
- Present at birth or becomes apparent during early life
- Macular pigmentation tends to be stable over time or may fade
- Inheritance sporadic or autosomal dominant
- Female/male ratio: 2.5–1
- Other cutaneous findings: aplasia cutis, fibromas, follicular keratosis, angiomas, generalized or focal hypertrichosis, and abnormalities in the teeth, hair, nails and sweat glands
- Extracutaneous findings (30%): mainly CNS, musculoskeletal and ocular system involvement
- Other findings: limb-length discrepancies, facial hemiatrophy, scoliosis, abnormal facies, genitourinary abnormalities, cardiac abnormalities



**Figure 14.28** Hypomelanosis of Ito – hypopigmented streaks following Blaschko lines

### Pathogenesis

- Mosaicism caused by two distinct germ lines formed during embryogenesis

### Diagnosis

- Clinical presentation
- Histology: hypopigmented areas show normal or reduced number of melanocytes with reduction in number of melanosomes

### Differential diagnosis

- Goltz syndrome
- Vitiligo
- Nevus depigmentosus
- Incontinentia pigmenti (stage 4)
- Epidermal nevi
- Lichen striatus
- Segmental vitiligo

### Treatment

- Cosmetic cover-up is rarely needed

### Prognosis

- Majority of children are normal, but in the first 2 years of life children should be observed for developmental delay and CNS abnormalities

- Neurologic and ocular examinations may be indicated
- Hypopigmentation may fade or be stable

### References

- Duran-McKinstler C, Moises C, Rodriguez-Jurado R, et al. Streptococcal exanthem in a blaschkolinear pattern: clinical evidence for genetic mosaicism in hypomelanosis of Ito. *Pediatr Dermatol* 2002; 19: 423–5
- Kuster W, Ehrig T, Happle R. In *The Pigmentary System*. Nordlund JJ, Boissy RE, Hearing VJ, et al. eds. Oxford University Press: . New York, 1998: 594–601
- Kuster W, Konig A. Hypomelanosis of Ito: no entity, but a cutaneous sign of mosaicism. *Am J Med Genet* 1999; 85: 346–50
- Nehal KS, DeBenito R, Orlow SJ. Analysis of 54 cases of hypopigmentation and hyperpigmentation along the lines of Blaschko. *Arch Dermatol* 1996; 132: 1167–70
- Ruggieri M, Pavone L. Hypomelanosis of Ito: clinical syndrome or just phenotype? *J Child Neurol* 2000; 15: 635–44
- Ruiz-Maldonado R, Roussaint S, Tamayo L, et al. Hypomelanosis of Ito: diagnostic criteria and report of 41 cases. *Pediatr Dermatol* 1992; 9: 1–10

## Nevus depigmentosus (nevus achromicus)

### Major points

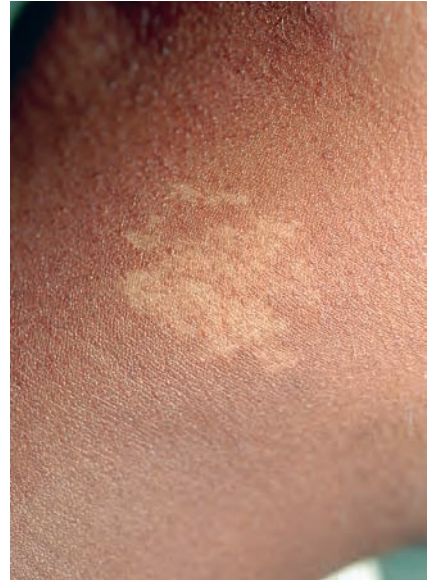- Single, well-circumscribed, hypopigmented patch, sometimes following the lines of Blaschko or in a segmental unilateral distribution (Figure 14.29)
- Border of lesion may be serrated or jagged
- Lesions present at birth or within the first years of life
- Usual locations: trunk and proximal extremities
- Male/female ratio = 1
- Rare associated findings: hemihypertrophy, seizures and mental retardation

### Pathogenesis

- Hypothesis: functional defect of melanocytes and morphologic abnormalities of melanosomes

### Diagnosis

- Clinical examination
- Under Wood's light examination, lesions show off-white accentuation, in contrast to vitiligo, which is bright white



**Figure 14.29** Nevus depigmentosus – congenital hypopigmented well-defined patch

- Electron microscopy: defect in transfer of pigment between the melanocyte and keratinocyte with a decreased number of melanosomes in the keratinocytes; number of melanocytes normal

### Differential diagnosis

- Nevus anemicus
- Segmental vitiligo
- Hypopigmented macules of tuberous sclerosis
- Hypomelanosis of Ito
- Pityriasis alba
- Postinflammatory hypopigmentation

### Treatment

- Usually none needed
- Camouflage makeup such as Dermablend® or Covermark®

### Prognosis

- Stable in size and distribution throughout life

### References

- Alkemade H, Juhlin L. Unilateral lentiginosis with nevus depigmentosus on the other side. *J Am Acad Dermatol* 2000; 43: 361–3
- Dippel E, Utikal J, Feller G, et al. Nevi flammei affecting two contralateral quadrants and nevus depigmentosus: a new

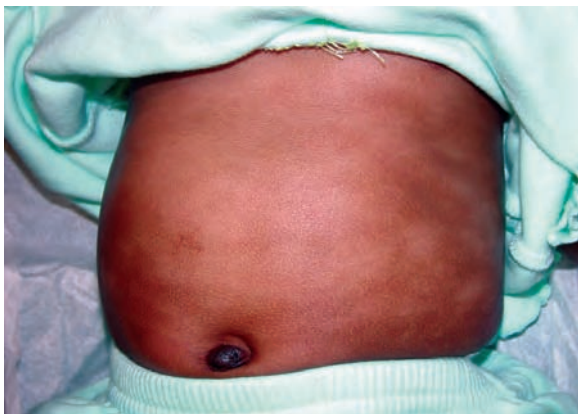
type of phacomatosis pigmentovascularis? Am J Med Genet 2003; 119A: 228–30

Lee HS, Chun YS, Hann SK. Nevus depigmentosus: clinical features and histopathologic characteristics in 67 patients. J Am Acad Dermatol 1999; 40: 21–6

## Postinflammatory hypopigmentation

### Major points

- Partial loss of cutaneous melanin in affected area of skin resulting from an inflammatory process (Figures 14.30 and 14.31)
- Appears as a hypochromic macule or patch in distribution of previous inflammation

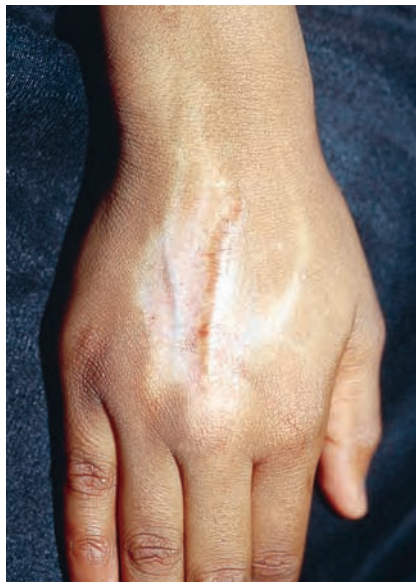

**Figure 14.30** Postinflammatory hypopigmentation from eczema in a baby. The color reverted to normal after therapy

- More easily seen in dark skin
- Trauma and inflammation are thought to cause dysfunction of melanocytes
- Wood's lamp examination enhances hypopigmented areas in light skin and helps distinguish between depigmentation and hypopigmentation

### Pathogenesis

- Histology can help to establish the cause of hypopigmentation



**Figure 14.31** Postinflammatory hypopigmentation caused by a steroid injection for a cyst

### Diagnosis

- Clinical presentation with history of inflammation

### Differential diagnosis

- Tinea corporis
- Tinea versicolor
- Seborrheic dermatitis

### Treatment

- Treat underlying cause of inflammation

### Prognosis

- Can improve with treatment or remain static

### References

- Herane MI. Vitiligo and leukoderma in children. Clin Dermatol 2003; 21: 283–95
- Ruiz-Maldonado R, Orozco-Covarrubias ML. Postinflammatory hypopigmentation and hyperpigmentation. Semin Cutan Med Surg 1997; 16: 36–43

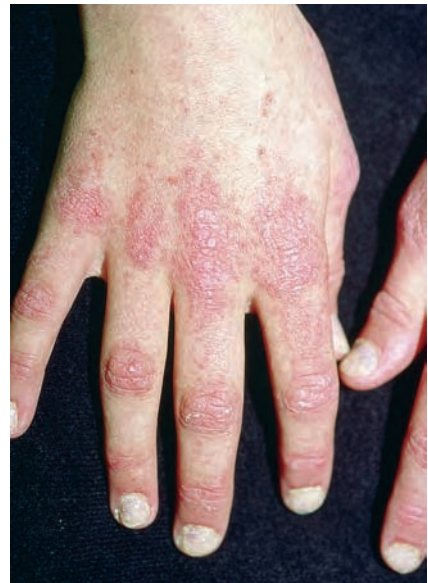

# COLLAGEN VASCULAR DISEASES

## DERMATOMYOSITIS

### Major points

- Affects three children per million per year in the USA
- Bimodal distribution: peaks at 5–9 years of age and again in teenage years
- Equal gender distribution at 5–9 years of age; 10 : 1 female predominance in early teenage years
- Skin manifestations:
  1. Heliotrope rash – violaceous, periorbital erythema with swelling
  2. Gottron papules – scaly, erythematous papules overlying metacarpal–phalangeal joints or interphalangeal joints (Figure 15.1)
  3. Erythematous malar rash and over neck, upper back and arms (shawl sign)
  4. Scaly, erythematous patches of the elbows, knees and cheeks
  5. Nails: periungual telangiectasias and cuticular overgrowth
  6. Poikiloderma
  7. Calcinosis cutis – usually occurs late in the course of disease, occurs much more frequently in children than adults; incidence can be reduced with aggressive treatment
- Noncutaneous manifestations:
  1. Symmetric, progressive, proximal muscle weakness (Gower sign)
  2. Muscle pain
  3. Constitutional symptoms: fever, weight loss, fatigue
  4. Dysphagia
  5. Nasal speech, hoarseness
  6. Abdominal pain
  7. Arthritis and tenosynovitis
  8. Pulmonary disease (diffuse interstitial fibrosis, secondary aspiration and infection)
  9. Cardiac disease: heart block, arrhythmias, pericarditis
  10. Gastrointestinal disease (mucosal ulceration)
  11. Calcinosis around joints and in intermuscular fascial planes
- Differs from adult dermatomyositis in that malignancy is extremely rare (work-up for malignancy is unnecessary)



**Figure 15.1** Dermatomyositis – typical Gottron papules over the knuckles



### Pathogenesis

- Etiology unknown
- Presumed autoimmune disorder
- May be multifactorial: infectious, genetic and environmental etiologies have been implicated

### Diagnosis

- Criteria (Bohan and Peter)
  1. Characteristic rash, plus three of the four following:
    - a. Symmetric proximal muscle weakness
    - b. Elevated muscle enzymes (aldolase, creatine kinase, lactate dehydrogenase, transaminases (AST/ALT))
    - c. Muscle biopsy (chronic inflammation with or without necrosis)
    - d. Abnormal electromyogram (EMG)
- Magnetic resonance imaging (MRI) is useful in determining areas of muscle involvement:
  1. Identifies areas of edema and inflammation
  2. Used to identify appropriate muscle biopsy site
  3. Used to follow disease course

### Differential diagnosis

- Systemic lupus erythematosus
- Photosensitive eruption (e.g. drug-induced dermatitis)
- Postinfectious myositis
- Other myopathies

### Treatment

- Systemic corticosteroids – most cases respond to corticosteroid therapy
  1. Oral prednisone taper over several months
  2. High-dose intravenous pulse methylprednisolone (IVMP)
- Methotrexate is second-line agent of choice with recalcitrant disease
- If no response or there are intolerable adverse effects, other therapies to consider: cytoxan, hydroxychloroquine, azathioprine, cyclosporine, intravenous immunoglobulins (IVIG) and plasmapheresis
- Sun protection and sun avoidance
- Physical therapy to prevent contractures
- Early aggressive therapy is successful in minimizing long-term sequelae, including calcinosis

### Prognosis

- With successful treatment, prognosis is good – overall mortality <7%
- Most children will completely recover after a single course (lasting months to years)
- ~25% will have disease with repeated acute exacerbations or persistence despite treatment
- Causes of mortality: myocarditis, progressive myositis, bowel perforation, aspiration pneumonia
- Causes of morbidity:
  1. Calcinosis may occur in up to 40%
  2. Joint contractures
  3. Cutaneous and gastrointestinal ulcers
  4. Residual muscle weakness and disability
- Cutaneous features can persist for years despite resolution of all other features of the disease

### References

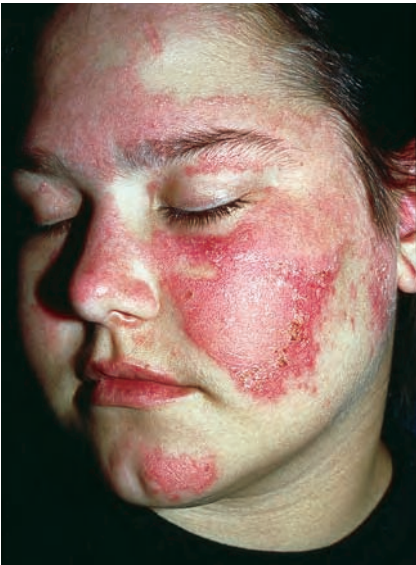- Drake LA, Dinehart SM, Farmer ER, et al. Guidelines of care for dermatomyositis. American Academy of Dermatology. J Am Acad Dermatol 1996; 34: 824–9
- Fisler RE, Liang MG, Fuhlbrigge RC, et al. Aggressive management of juvenile dermatomyositis results in improved outcome and decreased incidence of calcinosis. J Am Acad Dermatol 2002; 47: 505–11
- Pachman LM, Hayford JR, Chung A, et al. Juvenile dermatomyositis at diagnosis: Clinical characteristics of 79 children. J Rheumatol 1998; 25: 1198–204
- Pachman LM. Juvenile dermatomyositis: immunogenetics, pathophysiology, and disease expression. Rheum Dis N Amer 2002; 28: 579–602
- Ruperto N, Ravelli A, Murry KJ, et al. Paediatric Rheumatology International Trials Organization (PRINTO). Pediatric Rheumatology Collaborative Study Group (PRCSG). Preliminary core sets of measures for disease activity and damage assessment in juvenile systemic lupus erythematosus and juvenile dermatomyositis. Rheumatology 2003; 42: 1452–9
- Santmyre-Rosenberger B, Dugan EM. Skin involvement in dermatomyositis. Curr Opin Rheumatol 2003; 15: 714–22.
- Uzel G, Pachman LM. Cytokines in juvenile dermatomyositis pathophysiology: potential and challenge. Curr Opin Rheumatol 2003; 15: 691–7

## SYSTEMIC LUPUS ERYTHEMATOSUS

### Major points

- Incidence is ~5–10 per 100 000
- Disease shows a female predominance after puberty

- Black, Hispanic and Asian children have increased frequency of disease
- 25% of patients with systemic lupus erythematosus (SLE) have onset in the first two decades of life
- 80% of adolescents with SLE have cutaneous findings
- Cutaneous manifestations (presenting sign in 25%):
  1. Photosensitive eruption – malar or ‘butterfly’ rash, erythema with scale (Figure 15.2)
  2. Discoid lesions – round, sharply demarcated, erythematous lesions with adherent scale, follicular plugging, telangiectasias and scarring
  3. Telangiectasias – cuticular and other locations
  4. Livedo reticularis
  5. Scarring or nonscarring alopecia
  6. Nasal or oral ulcerations (particularly the hard palate)
  7. Vasculitis, erythema nodosum, lupus panniculitis can also occur
- Systemic symptoms:
  1. Arthritis, arthralgias
  2. Fever, malaise, weight loss, lymphadenopathy, muscle weakness
  3. Raynaud phenomenon
  4. Pulmonary and cardiac disease
  5. CNS involvement (neuropsychiatric)
  6. Renal disease (extent of involvement related to prognosis)



**Figure 15.2** Systemic lupus erythematosus with butterfly rash

- Association with complement deficiencies, such as C2 deficiency

### *Pathogenesis*

- Autoimmune disorder
- Genetic predisposition
- Many factors potentially contribute: viral, hormonal, environmental and immunogenetic
- Histology: vacuolar change of epidermal cells with a perivascular lymphohistiocytic infiltrate
- Direct immunofluorescence (DIF): granular deposition of IgG, with or without IgM, and complement at the dermal–epidermal junction and around hair follicles; IgA may occasionally be seen
- Circulating antibodies can be detected

### *Diagnosis*

- American College of Rheumatology (ACR) criteria require four of the following 11 for diagnosis:
  1. Malar rash
  2. Discoid rash
  3. Photosensitivity
  4. Oral ulcers
  5. Arthritis: peripheral, nonerosive, involving two or more joints
  6. Serositis: pleuritis or pericarditis
  7. Renal disorder: proteinuria or cellular casts
  8. Neurologic disorder
  9. Hematologic disorder: anemia, leukopenia, lymphopenia, thrombocytopenia
  10. Immunologic disorder: positive antiphospholipid antibody, anti-DNA, or anti-Sm antibody; false positivity for syphilis
  11. Positive antinuclear antibody (ANA)
- Complement levels (C3 and C4) are low – levels may be used to monitor disease activity
- Biopsies may be performed: skin, renal or liver, as indicated

### *Differential diagnosis*

- Dermatomyositis
- Juvenile rheumatoid arthritis
- Fifth disease
- Drug-induced lupus-like reactions (e.g. isoniazid, hydralazine, procainamide, D-penicillamine, minocycline)

### *Treatment*

- High-dose systemic corticosteroids – continuous or pulsed

- Immunosuppressive agents:
  1. Azathioprine (Imuran®), cyclophosphamide (Cytoxan®), methotrexate, chlorambucil, mycophenolate mofetil
  2. Usually reserved for patients with severe systemic involvement (including renal and/or CNS disease)
  3. Combination with steroid therapy is effective and decreases steroid dose needed
- Topical corticosteroids for cutaneous lesions
- Oral hydroxychloroquine – for photosensitive cutaneous lesions
- Sun protection and avoidance
- Renal transplantation for end-stage renal disease

### Prognosis

- Early diagnosis and aggressive treatment can improve prognosis
- Dependent on the degree of systemic involvement
- Frequently a more severe disease in children than in adults (renal and CNS disease common)
- Worst prognosis in children with diffuse proliferative glomerulonephritis and hypertension in the first 6 months of disease
- Infection is the cause of most deaths, especially in patients on chronic corticosteroid therapy

### References

- Barnett NK, Wright DA. Connective tissue diseases and arthritides. In *Pediatric Dermatology*, 3rd edn. Mosby: New York, 2003: 943–50
- Dall'Era M, Davis JC. Systemic lupus erythematosus. How to manage, when to refer. *Postgrad Med* 2003; 114: 31–7, 40
- DeSilva TN, Kress DW. Management of collagen vascular diseases in childhood. *Clin Dermatol* 1998; 16: 579–92
- Drake LA, Dinehart SM, Farmer ER, et al. Guidelines of care for cutaneous lupus erythematosus. *American Academy of Dermatology. J Am Acad Dermatol* 1996; 34: 830–6
- Gibson LE, Specks U, Homburger H. Clinical utility of ANCA tests for the dermatologist. *Int J Dermatol* 2003; 42: 859–69
- Gill JM, Quisel AM, Rocca PV, Walters DT. Diagnosis of systemic lupus erythematosus. *Am Fam Physician* 2003; 68: 2179–86
- Hamasaki K, Mimura T, Kanda H, et al. Systemic lupus erythematosus and thrombotic thrombocytopenic purpura: a case report and literature review. *Clin Rheumatol* 2003; 22: 355–8
- Lyon VB, Nocton JJ, Drolet BA, Esterly NB. Necrotic facial papules in an adolescent: C2 deficiency with eventual

development of lupus erythematosus. *Pediatr Dermatol* 2003; 20: 318–22

Mevorach D. Systemic lupus erythematosus and apoptosis: a question of balance. *Clin Rev Allergy Immunol* 2003; 25: 49–60

Ruperto N, Ravelli A, Murray KJ, et al. Paediatric Rheumatology International Trials Organization (PRINTO). Pediatric Rheumatology Collaborative Study Group (PRCSG). Preliminary core sets of measures for disease activity and damage assessment in juvenile systemic lupus erythematosus and juvenile dermatomyositis. *Rheumatology* 2003; 42: 1452–9

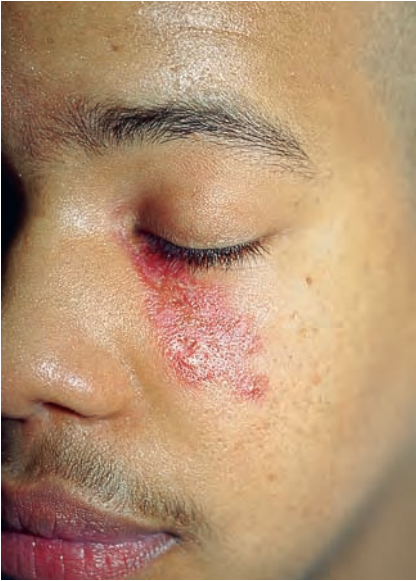## NEONATAL LUPUS ERYTHEMATOSUS

See Chapter 2

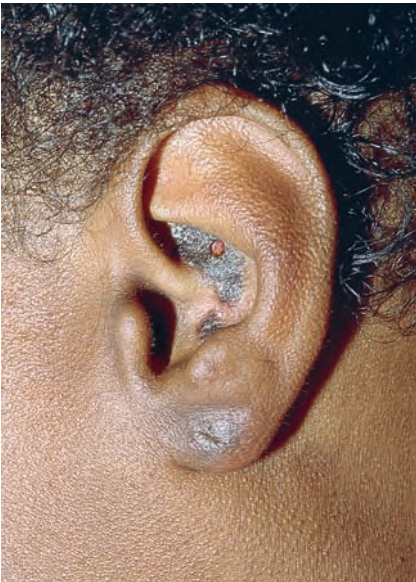## DISCOID LUPUS ERYTHEMATOSUS

### Major points

- Characterized by the presence of discoid skin lesions without systemic involvement
  1. Some children with discoid lupus erythematosus (DLE) may progress to SLE; this transition seems to be more frequent and more severe in children and teens
  2. Discoid lesions may also be seen as a cutaneous manifestation of SLE
- Uncommon in children; <5% of patients with DLE develop disease before age 16 years
- Clinical presentation:
  1. Erythematous, sharply demarcated, scaly round plaques sometimes with telangiectasias (Figures 15.3 and 15.4)
  2. Lesions may be hyperpigmented or hypopigmented
  3. Adnexal involvement with follicular plugging and scarring alopecia
  4. Localized to sun-exposed areas – often over nose and malar eminences
  5. Most frequent locations: face, hands, ears and scalp
    - a. Localized DLE – involvement limited to head
    - b. Disseminated DLE – involvement below neck



**Figure 15.3** Discoid lupus erythematosus – typical erythematous, scaly, atrophic plaque with central atrophy



**Figure 15.4** Discoid lupus erythematosus – keratotic papules in the ear, a common location

- 6. Results in atrophic, dyschromic scars
- Low incidence of photosensitivity as compared to DLE in adults
- Lack of female predominance as compared to other autoimmune diseases

### *Pathogenesis*

- Autoimmune disorder
- Histology: inflammatory, mononuclear infiltrate involving upper and lower dermis and interface, perivascular and periadnexal areas; thickened basement membrane zone; keratinocyte damage; follicular plugging
- DIF: granular deposits at the dermal–epidermal junction
  1. Negative DIF does not rule out the diagnosis
  2. Scarred, burned-out lesions may no longer contain immunoreactants
- Predominance of activated T cells
- Sun exposure has been implicated in the development and exacerbation

### *Diagnosis*

- Characteristic clinical findings
- Skin biopsy for histologic examination and DIF

### *Differential diagnosis*

- Polymorphous light eruption
- Trauma
- Factitial dermatitis
- Sarcoidosis

### *Treatment*

- Sun protection and avoidance
- Topical corticosteroids
- Intralesional corticosteroids
- Systemic therapy: hydroxychloroquine, systemic corticosteroids, dapsone

### *Prognosis*

- Scarring, atrophy and dyspigmentation are common
- May progress to SLE

### *References*

- Cherif F, Mebazaa A, Mokni M, et al. Childhood discoid lupus erythematosus: a Tunisian retrospective study of 16 cases. *Pediatr Dermatol* 2003; 20: 295–8
- George PM, Tunnessen WW. Childhood discoid lupus erythematosus. *Arch Dermatol* 1993; 129: 613–17
- McMullen EA, Armstrong KD, Bingham EA, Walsh MY. Childhood discoid lupus erythematosus: a report of two cases. *Pediatr Dermatol* 1998; 15: 439–42

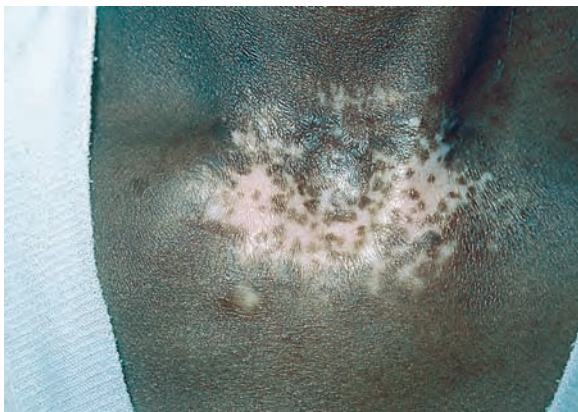

## SCLERODERMA

Synonyms: systemic sclerosis, progressive systemic sclerosis

### Major points

- Childhood cases account for 3% of all cases of scleroderma
- Female/male ratio >1
- Raynaud phenomenon occurs in 90% overall and may precede onset of disease
- Clinical subcategories:
  1. Diffuse disease – trunk and proximal portions of extremities
  2. Limited disease – only face and distal extremities involved
  3. CREST syndrome – Calcinosis, Raynaud phenomenon, Esophageal dysmotility, Sclerodactyly, Telangiectasia (rare in children)
- Clinical findings:
  1. Skin: generalized sclerotic changes, tightening, induration, occasional pruritus; progression to fibrosis and contractures; may be preceded by edema or rarely, an erythematous phase (Figure 15.5)
  2. Nailfold capillary dilatation and dropout
  3. Raynaud phenomenon
  4. Sclerodactyly
  5. Distal fingertip pitting from infarction
  6. Pulmonary disease: most commonly restrictive lung disease, interstitial lung disease



**Figure 15.5** Scleroderma – depigmented, sclerotic patch with retained follicular pigmentation

7. Esophageal disease: symptoms of gastroesophageal reflux from esophageal dysmotility
8. Renal disease
9. Cardiac disease
10. Myositis, arthritis, arthralgias, muscle atrophy

### Pathogenesis

- Most evidence supports an immunologic (autoimmune) mechanism
- Histology: dense sclerosis of the dermis with excessive collagen deposition and trapping of adnexal structures
  1. Early phases: dense lymphocytic infiltrate at the interface between the deep dermis and the subcutaneous fat

### Diagnostics

- Characteristic clinical findings
- Autoantibodies:
  1. ANA (22–100% in children)
  2. Anti-Scl 70 (40% in children)
  3. Anticentromere antibodies common in CREST syndrome, less common in systemic sclerosis (rarely found in children)

### Differential diagnosis

- Scleredema
- Scleromyxedema
- Eosinophilic fasciitis
- Mixed connective tissue disease
- Chronic graft versus host disease
- Drug or chemical exposure

### Treatment

- Early treatment to prevent irreversible organ tissue fibrosis
- Systemic therapies:
  1. Systemic corticosteroids
  2. D-Penicillamine
  3. Methotrexate
  4. PUVA - Psoralen+UVA
  5. Cyclophosphamide
  6. Cyclosporine
- Cutaneous treatment:
  1. Bland emollients (e.g. petrolatum)
  2. Avoidance of extreme temperatures (especially cold)
  3. Physical therapy to prevent joint contractures



- Raynaud phenomenon:
  1. Cold protection and avoidance
  2. Avoidance of smoking
  3. Calcium channel blockers (e.g. nifedipine)
  4. Nitroglycerin patch to fingertips for temporary relief
  5. IV infusion of prostaglandin E<sub>1</sub> and prostacyclin for nonhealing ulcers or debilitating disease
- Gastroesophageal disease with reflux esophagitis:
  1. Proton pump inhibitors (e.g. omeprazole)
  2. Head of bed elevation, light meals
- Pulmonary disease: cyclophosphamide
- Renal disease (with malignant hypertension):
  1. Angiotensin-converting enzyme (ACE)-inhibitors (e.g. captopril)
  2. Hemodialysis

### Prognosis

- Slow progression for years with organ failure and death (similar to adults)
- Young males and patients with significant cardiac, pulmonary, or renal disease have worse prognosis
- Interstitial lung disease is the most common cause of mortality

### References

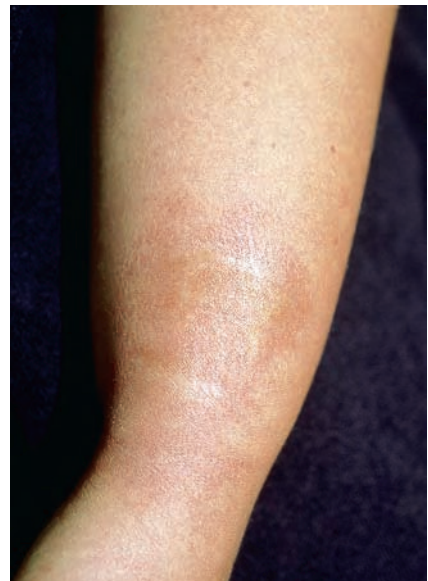- Atamas SP, White B. The role of chemokines in the pathogenesis of scleroderma. *Curr Opin Rheumatol* 2003; 15: 772–7
- Black CM. Scleroderma and fasciitis in children. *Curr Opin Rheumatol* 1995; 7: 442–6
- Drake LA, Dinehart SM, Farmer ER, et al. Guidelines of care for scleroderma and sclerodermoid disorders. *J Am Acad Dermatol* 1996; 35: 609–14
- Harris ML, Rosen A. Autoimmunity in scleroderma: the origin, pathogenetic role, and clinical significance of autoantibodies. *Curr Opin Rheumatol* 2003; 15: 778–84
- Leask A, Denton CP, Abraham DJ. Insights into the molecular mechanism of chronic fibrosis: the role of connective tissue growth factor in scleroderma. *J Invest Dermatol* 2004; 122: 1–6
- Murray KJ, Laxer RM. Scleroderma in children and adolescents. *Rheum Dis Clin North Am* 2002; 28: 603–24
- Vancheeswaran R, Black CM, David J, et al. Childhood-onset scleroderma: is it different from adult-onset disease? *Arth Rheum* 1996; 39: 1041–9

## MORPHEA

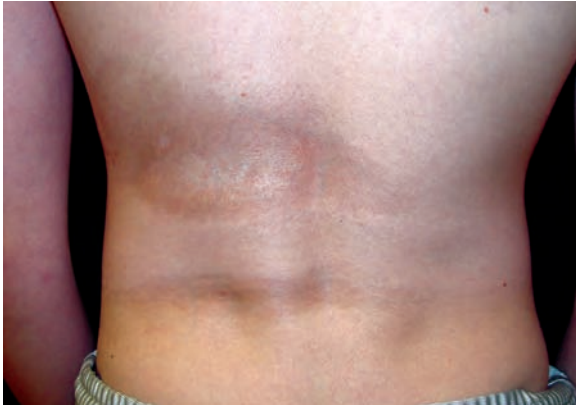Synonym: localized scleroderma

### Major points

- Sclerodermatous patches limited to skin (Figures 15.6 and 15.7)
- Progression to systemic involvement is exceedingly rare
- Self-limited disorder, lasting ~3–5 years
- Often an unsolicited history of trauma to the area
- Clinical course: superficial erythema and inflammation of skin followed by hardening of the area and subdermal structures; loss of hair and anhidrosis; hypo- or hyperpigmentation; may affect muscle or bone if extensive or over a joint
- Linear scleroderma
  1. Most frequent type in children
  2. Usually unilateral along part of an extremity, but may affect thorax, abdomen, or buttocks
  3. Linear lesions are initially erythematous plaques, gradually lose their color centrally and become white, shiny, atrophic or thickened with sclerosis
  4. May cause joint contractures, muscle wasting, or limb growth failure if over a joint

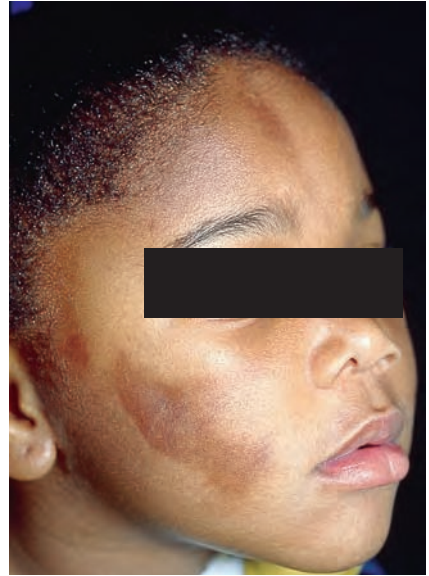

**Figure 15.6** Morphea – hyperpigmented, sclerotic plaque on extremity



**Figure 15.7** Morphea – two large plaques on the back. He later developed a large plaque on one leg

- En coup de sabre
  1. Ivory sclerotic plaque with peripheral hyperpigmentation appears on forehead and scalp (resembling a saber cut) (Figure 15.8)
    - a. May cause alopecia of the scalp, eyebrows, eyelashes
    - b. May affect nose, cheek, chin and neck
    - c. Ranges in severity from minor indentation to severe hemifacial atrophy
  2. May have CNS involvement (e.g. seizures, intracranial calcification, intracranial aneurysm), tongue atrophy, tooth growth abnormalities, uveitis
  3. Parry-Romberg syndrome (progressive facial hemiatrophy) considered by some authors to be a variant of en coup de sabre type
- Plaque morphea
  1. Oval patches or plaques involving the skin and subcutaneous tissue
  2. Most common on trunk, may be seen on extremities, head and neck
  3. Erythematous or hyperpigmented plaques, several centimeters in diameter; central clearing with a violaceous border; later a white center that becomes shiny, firm and waxy
  4. Plaques tend to have no hair or sweating
  5. May see plaque morphea and linear lesions in the same patient
- Generalized morphea
  1. Large plaques in different anatomic locations (>4 plaque lesions in  $\geq 2$  body sites)
  2. Lesions similar to plaque morphea with generalized involvement



**Figure 15.8** Morphea (en coup de sabre) – hyperpigmented, sclerotic indentation on the forehead and cheek

### Pathogenesis

- Thought to be an autoimmune disorder
- Early inflammation with edema and increased vascularity; progressing to sclerosis and abnormal collagen formation; ultimately resulting in atrophy
- Trauma and *Borrelia burgdorferi* infection have been implicated as triggers
- Histology:
  1. Early: dermal edema with swelling and degeneration of collagen fibrils, lymphocytic infiltrate around dermal vessels and appendages
  2. Late: progressive dermal thickening and condensation of collagen – with bundles densely packed and aligned parallel to the dermal – epidermal junction with loss of appendages

### Diagnosis

- Clinical findings
- Skin biopsy may be performed to aid in diagnosis but not always necessary
- Laboratory studies: none specific but may be helpful in following the course; ANA, complete blood count (CBC) with differential, immunoglobulins, rheumatoid arthritis factor
- Consider work-up for other collagen vascular diseases as indicated by history and physical

examination; extensive disease may be more likely to have immunologic abnormalities

- MRI/ultrasound – useful if there is CNS or eye involvement or to determine depth of lesions

### *Differential diagnosis*

- Postinflammatory hyperpigmentation
- Erythema dyschromicum perstans
- Lichen sclerosus
- Traumatic scars
- Eosinophilic fasciitis
- Scleredema of Buschke

### *Treatment*

- Systemic therapy:
  1. Low-dose methotrexate
  2. Systemic corticosteroids (oral or IV pulse)
  3. Oral calcitriol (vitamin D analog)
  4. PUVA (not recommended for <11 years)
  5. D-Penicillamine
- Topical therapy:
  1. Potent topical steroids
  2. Emollients
  3. Topical calcipotriene
- Physical therapy/occupational therapy for joint involvement
- Psychological support as needed

### *Prognosis*

- Lesions tend to have an active, progressive phase for several years then slowly resolve spontaneously with softening of skin
- Progression exceedingly rare to systemic involvement
- Potential sequelae include: residual hyperpigmentation, skin atrophy, limb atrophy, joint contractures and psychological sequelae

### *References*

- Cunningham BB, Landells ID, Langman C, et al. Topical calcipotriene for morphea/linear scleroderma. *J Am Acad Dermatol* 1998; 39: 211–15
- Drake LA, Dinehart SM, Farmer ER, et al. Guidelines of care for scleroderma and sclerodermoid disorders. *J Am Acad Dermatol* 1996; 35: 609–14
- Hawk A, English JC 3rd. Localized and systemic scleroderma. *Semin Cutan Med Surg* 2001; 20: 27–37
- Jablonska S, Blaszczyk M. Scleroderma and sclerotic skin conditions: unapproved treatments. *Clin Dermatol* 2002; 20: 634–7

Murray KJ, Laxer RM. Scleroderma in children and adolescents. *Rheum Dis Clin North Am* 2002; 28: 603–24

Nelson AM. Localized scleroderma including morphea, linear scleroderma and eosinophilic fasciitis. *Curr Prob Pediatr* 1996; 26: 318–24

Sehgal VN, Srivastava G, Aggarwal AK, et al. Localized scleroderma/morphea. *Int J Dermatol* 2002; 41: 467–75

## LICHEN SCLEROSUS

Synonyms: lichen sclerosus et atrophicus

### *Major points*

- Female/male ratio is 10 : 1
- Some clinical overlap seen between morphea and LS
- Clinical findings:
  1. Ivory or white, shiny macules or papules that coalesce into homogeneous hypo- or depigmented plaques; affected area is sharply demarcated from surrounding skin (Figures 15.9 and 15.10)
  2. Commonly encircles the vulvar and perianal areas in a 'figure of eight' pattern
  3. Extragenital involvement on the trunk, forearm, neck and face
  4. Other cutaneous findings: vesicles, bullae (which are occasionally hemorrhagic), ulcerations, excoriations
  5. Symptoms: pruritus, dysuria, painful defecation, and anal and vulvar bleeding
  6. In males, major symptom may be phimosis

### *Pathogenesis*

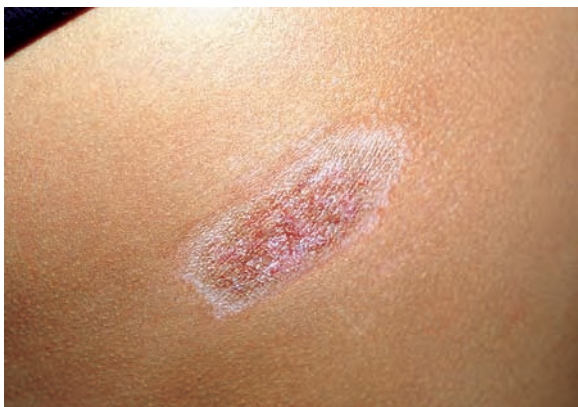- Inflammatory disorder of unknown etiology
- Familial cases have been reported
- LS in children has been associated with trauma
- Histology: homogenized collagen with a band-like lymphocytic infiltrate underlying a normal or atrophic epidermis

### *Diagnosis*

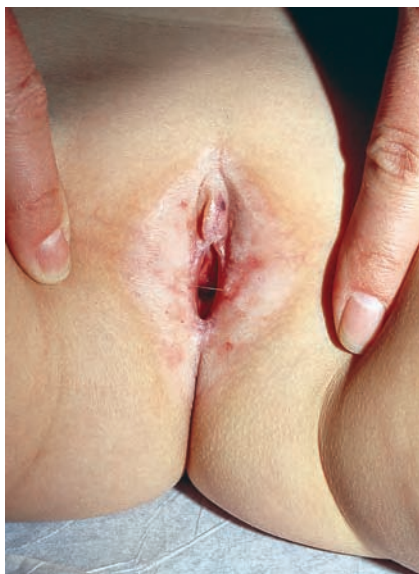- Characteristic clinical findings
- Skin biopsy may be helpful in uncertain cases

### *Differential diagnosis*

- Morphea
- Trauma, including sexual abuse



**Figure 15.9** Lichen sclerosus – hypopigmented, atrophic plaque



**Figure 15.10** Lichen sclerosus – involving the vulva

- Vitiligo
- Postinflammatory hypopigmentation

### *Treatment*

- Topical corticosteroids:
  1. Potent topical corticosteroids (e.g. 0.05% betamethasone ointment) BID for short period of time, usually 2–4 weeks; then tapered to once daily; may need to use intermittently for symptoms
  2. Taper to low-potency steroids when disease under control

- Proper perineal hygiene
- Nonocclusive underwear
- Avoid trauma (e.g. bicycle riding)
- Antimicrobial treatment for secondary bacterial or yeast infections
- Topical tacrolimus or pimecrolimus (off label) BID

### *Prognosis*

- Two-thirds of pre-pubertal girls will have clearing or improvement of lesions at puberty (childhood form has better prognosis than adult form)
- Potential complications of persistent lesions: scarring and labial atrophy; constriction of the vaginal introitus or urethral meatus
- Squamous cell carcinoma is a rare complication of LS in adults

### *References*

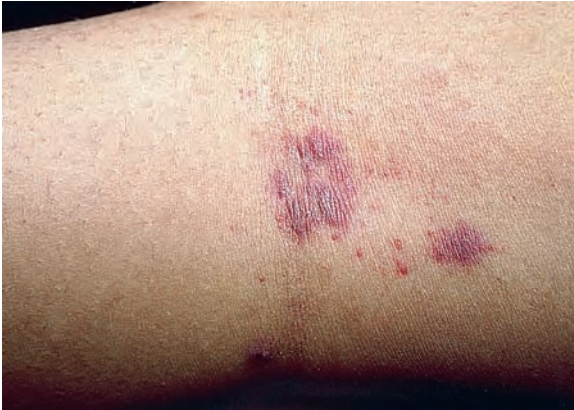- Fischer G, Rogers M. Treatment of childhood vulvar lichen sclerosus with potent topical corticosteroids. *Pediatr Dermatol* 1997; 14: 235–8
- Helm KF, Gibson LE, Muller SA. Lichen sclerosus et atrophicus in children and young adults. *Pediatr Dermatol* 1991; 8: 97–101
- Neill SM, Tatnall FM, Cox NH. British Association of Dermatologists. Guidelines for the management of lichen sclerosus. *Br J Dermatol* 2002; 147: 640–9
- Sahn EE, Bluestein EL, Olivia S. Familial lichen sclerosus et atrophicus in childhood. *Pediatr Dermatol* 1994; 11: 160–3
- Tasker GL, Wojnarowska F. Lichen sclerosus. *Clin Exp Dermatol* 2003; 28: 128–33
- Warrington SA, de San Lázaro C. Lichen sclerosus et atrophicus and sexual abuse. *Arch Dis Child* 1996; 75: 512–16

## **VASCULITIS**

### *Major points*

- Group of disorders characterized by inflammation of blood vessel walls
- Cutaneous manifestations: purpura, petechiae, ecchymosis, erythematous macules, papules, nodules, urticaria, livedo reticularis, necrosis, ulceration, vesicles, pustules, bullae, pyoderma gangrenosum-like lesions, erythema nodosum-like lesions (Figure 15.11)





**Figure 15.11** Vasculitis – associated with systemic lupus erythematosus

- Most common vasculitis in childhood is Henoch–Schönlein purpura (see below)
- Tends to be more self-limited in children than adults
- Classified by the size of vessel affected (small, medium or large vessel)
  1. Large-vessel vasculitis
    - a. Giant cell (temporal) arteritis
    - b. Takayasu arteritis
  2. Medium-vessel vasculitis
    - a. Kawasaki disease (see Chapter 11)
    - b. Classic polyarteritis nodosa (PAN)
  3. Small-vessel vasculitis (leukocytoclastic vasculitis)
    - a. Henoch–Schönlein purpura
    - b. Cutaneous leukocytoclastic vasculitis
    - c. Microscopic polyarteritis nodosa
    - d. Wegener granulomatosis
    - e. Churg–Strauss syndrome
    - f. Essential cryoglobulinemic vasculitis
- Major types of vasculitis seen in children:
  1. Henoch–Schönlein purpura (see below)
  2. Polyarteritis nodosa
    - a. Constitutional symptoms: malaise, fever, weight loss
    - b. Hypertension
    - c. Skin findings: purpuric papules with or without necrosis, livedo reticularis, tender subcutaneous nodules
    - d. Systemic involvement: musculoskeletal, renal, nervous system, gastrointestinal (GI) tract most commonly affected
- 3. Takayasu arteritis
  - a. Granulomatous inflammation of the aorta and its main branches causing stenosis and aneurysms
  - b. In children, thoracic and abdominal aorta most commonly affected
  - c. ‘Pulseless’ disease – diminished or no pulses in the arms and blood pressure discrepancies between arms
  - d. Lacks skin lesions
- 4. Wegener granulomatosis
  - a. Granulomatous inflammation involving the respiratory tract (sinuses, nasal passages, pharynx, lungs) and kidneys (glomerulonephritis)
  - b. Common clinical presentation: malaise, fever, sinusitis, epistaxis and hematuria
  - c. May have necrotizing lesions of the skin, CNS, or gut

### Pathogenesis

- May be triggered by a variety of agents: infection, drugs and malignancy (Table 15.1)
- Infectious vasculitis: bacterial, rickettsial, mycobacterial, spirochetal, fungal, viral
- Immune-mediated vasculitis can be categorized as:
  1. T-cell-mediated inflammation (e.g. Takayasu arteritis)
  2. Antibody-mediated inflammation:
    - a. Immune complex deposition in vessel walls (e.g. IgA immune complex deposition in Henoch–Schönlein purpura)
    - b. Direct binding of antibodies to vessel wall antigens (e.g. Kawasaki disease)
    - c. Activation of leukocytes by leukocyte-specific antigens (e.g. antineutrophilic cytoplasmic autoantibodies (ANCA))

### Diagnosis

- Clinical findings – look for evidence of infection, drug history, environmental/allergen exposure and systemic manifestations on history and physical examination
- Skin biopsy to confirm diagnosis
- Directed biopsies of specific organs to evaluate visceral disease
- Laboratory studies: ANA, cryoglobulins, hepatitis B and C antibodies, ANCA, complement levels, IgA–fibronectin aggregates



**Table 15.1 Common causes and associated underlying diseases in leukocytoclastic vasculitis****Infections**

Streptococcal and neisserial bacterial infections  
 Hepatitis B  
 Cytomegalovirus  
 Epstein–Barr virus

**Medications and drugs**

Sulfa antibiotics  
 Thiazides, phenothiazines, sulfonylureas and other sulfa-related drugs  
 Quinidine  
 Phenytoin  
 Injected illicit drugs  
 Allopurinol  
 Radiographic contrast media  
 Nonsteroidal anti-inflammatory agents

**Autoimmune diseases**

Lupus erythematosus  
 Rheumatoid arthritis  
 Giant cell arteritis  
 Wegener granulomatosis  
 Mixed connective tissue disease  
 Sjögren syndrome  
 Inflammatory bowel disease

**Dysproteinemias**

Cryoglobulinemia  
 Monoclonal and polyclonal gammopathies

**Malignancies**

Myeloma  
 Leukemia  
 Lymphoma

**Food products**

Food dyes and preservatives

Adapted from Schachner and Hansen, *Pediatric Dermatology*, 3rd edn. Mosby, New York 2003; 823

- Imaging studies as indicated: chest X-ray, CT scans, angiography or magnetic resonance angiography – if there are bruits or ischemic symptoms
- Further work-up determined by extent of systemic disease

**Differential diagnosis**

- Coagulopathies (e.g. thrombocytopenia, disseminated intravascular coagulation (DIC), platelet dysfunction)
- Occlusive disorders

**Treatment**

- Should be directed toward symptoms and prevention of visceral disease
- Infection must be ruled out before starting immunosuppressive therapy
- Removal of causative agents: e.g. infectious pathogen, drug, malignancy (rare in childhood)
- Corticosteroids
- Immunosuppressive agents (e.g. azathioprine or cyclophosphamide)

**Prognosis**

- Dependent on disease severity and presence/extent of systemic involvement

**References**

- Crowson AN, Mihm MC Jr, Magro CM. Cutaneous vasculitis: a review. *J Cutan Pathol* 2003; 30: 161–73
- Fiorentino DE. Cutaneous vasculitis. *J Am Acad Dermatol* 2003; 48: 311–40
- Ozen S. The spectrum of vasculitis in children. *Best Pract Res Clin Rheumatol* 2002; 16: 411–25
- Weyard CM, Goronzy JJ. Medium- and large-vessel vasculitis. *N Engl J Med* 2003; 349: 160–9

**HENOCH–SCHÖNLEIN PURPURA**

Synonyms: anaphylactoid purpura

**Major points**

- Leukocytoclastic vasculitis characterized by palpable purpura, joint pain, abdominal pain and renal disease (i.e. glomerulonephritis)
- Incidence is 14 per 100 000 per year in children
- Male/female ratio is ~1.5 : 1
- Peak incidence between 2 and 5 years
- Often a history of a recent upper respiratory infection (66–75%) – viral or streptococcal infection
- Cutaneous findings:
  1. Palpable purpura (but may be only macular) (Figure 15.12)
  2. Distribution is usually symmetric over buttocks and lower extremities but can occur on upper extremities over extensor surfaces (elbows, knees), trunk and face
  3. Petechiae, maculopapular erythematous rash, ulcers, vesicles and bullae (which may become hemorrhagic) and edema

4. Younger children <3 years age have more scalp, periorbital and acral edema
- Extracutaneous findings:
  1. Joint symptoms – arthralgias and/or arthritis
  2. Colicky abdominal pain from GI involvement: bleeding, melena, hematemesis, hemorrhage and intussusception (ileoileal)
  3. Renal involvement – glomerulonephritis
- Acute hemorrhagic edema of childhood
  1. Shares many features with Henoch–Schönlein purpura – once considered a variant, but is likely to be a distinct entity
  2. Age usually <2 years; has been reported at birth
  3. Clinical findings:
    - a. Abrupt onset of fever and tender edema of the face, eyelids, ears, scrotum and acral extremities
    - b. Purpuric, ecchymotic lesions on face and extremities (usually sparing the trunk)
    - c. Circinate, medallion-like pattern
    - d. No other associated systemic symptoms other than fever; good general health
  4. Pathogenesis: small-vessel vasculitis thought to be a hypersensitivity reaction to an infectious agent or following immunization
    - a. Has been reported following staphylococcal or streptococcal infection, upper respiratory infection, otitis, urinary tract infection, conjunctivitis, or adenovirus
    - b. IgA is variably present
  5. Diagnosis:
    - a. Characteristic clinical findings
    - b. Skin involvement only – renal and GI systems should be evaluated to rule out involvement
    - c. Laboratory studies: leukocytosis, thrombocytosis, eosinophilia, elevated erythrocyte sedimentation rate (ESR)
  6. No treatment is usually necessary
  7. Antibiotics for associated infection

### Pathogenesis

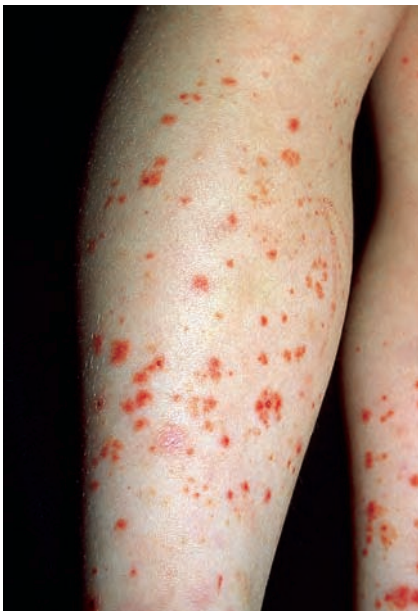- IgA immune complex-mediated small-vessel vasculitis
- Thought to be triggered by a preceding respiratory infection; considered a hypersensitivity reaction
- Histology: leukocytoclastic vasculitis of capillaries in upper dermis with perivascular neutrophils, nuclear debris and extravasated erythrocytes; IgA deposition in vessels on DIF
- Distribution of lesions has been suggested to be gravity dependent (predilection for buttock and lower extremities in older children)
- Henoch–Schönlein purpura nephropathy is caused by mesangial IgA deposition

### Diagnosis

- Characteristic cutaneous findings in the presence of joint swelling and abdominal pain
- Skin biopsy and DIF (important for diagnosis) – leukocytoclastic vasculitis; DIF demonstrates perivascular IgA, C3 and fibrin deposits
- About half the patients have elevated serum IgA; circulating IgA-containing immune complexes may be present
- Urinalysis to establish renal status
- Abdominal ultrasound examination for abdominal pain to evaluate for intussusception
- Guaiac stool for frank or occult blood

### Differential diagnosis

- Other vasculitis
- Septic vasculitis



**Figure 15.12** Henoch–Schönlein purpura with palpable purpura on lower legs

## Treatment

- Supportive, bed rest
- Elevation of swollen areas
- Nonsteroidal anti-inflammatory medications (NSAIDs) for joint symptoms
- Corticosteroids for GI symptoms
- High-dose pulse steroids or immunosuppressive agents (e.g. cyclophosphamide or azathioprine) for progressive renal disease

## Prognosis

- Generally considered benign and self-limited in the pediatric age group
  1. More severe disease in adults
  2. Resolution usually in 2–4 weeks; may relapse for several months (up to 40% of patients); can rarely become chronic (up to years)
- Long-term morbidity and mortality rates due to renal failure
  1. End-stage renal disease occurs in 5% of patients
  2. Risk factors for renal involvement: purpura affecting the upper part of the trunk, fever, elevated ESR, recent history of upper respiratory infection
- Recurrence after a 1-year asymptomatic period can occur in 10% of patients

## References

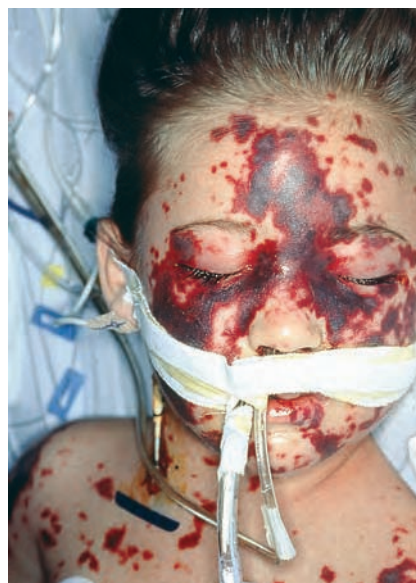- Al-Sheyyab M, El-Shanti H, Ajlouni S, et al. The clinical spectrum of Henoch–Schönlein purpura in infants and young children. *Eur J Pediatr* 1995; 154: 699–701
- Ballinger S. Henoch–Schönlein purpura. *Curr Opin Rheumatol* 2003; 15: 591–4
- Fervenza FC. Henoch–Schönlein purpura nephritis. *Int J Dermatol* 2003; 42: 170–7
- Gonggryp LA, Todd G. Acute hemorrhagic edema of childhood (AHE). *Pediatr Dermatol* 1998; 15: 91–6
- Nussinovitch M, Prais D, Finkelstein Y, et al. Cutaneous manifestations of Henoch–Schönlein purpura in young children. *Pediatr Dermatol* 1998; 15: 426–8
- Magro CM, Crowson AN. A clinical and histologic study of 37 cases of immunoglobulin-A associated vasculitis. *Am J Dermatopathol* 1999; 21: 234–40
- Manzoni APD, Viecili JB, Benvenuto de Andrade C, et al. Acute hemorrhagic edema of infancy: a case report. *Int J Dermatol* 2004; 43: 48–51
- Piette WW. What is Schönlein–Henoch purpura, and why should we care? *Arch Dermatol* 1997; 133: 515–18

Saulsbury FT. Hemorrhagic bullous lesions in Henoch–Schönlein purpura. *Pediatr Dermatol* 1998; 15: 357–9

## PURPURA FULMINANS

### Major points

- Heterogeneous group of disorders characterized by acute onset, rapidly progressing, purpuric lesions which develop into extensive areas of skin necrosis, hemorrhage and peripheral gangrene (Figure 15.13)
- Development of disseminated intravascular coagulation (DIC) is a defining feature
- Occurs in three clinical settings:
  1. Acute infectious purpura fulminans (most common)
    - a. In the setting of overwhelming sepsis
    - b. Majority of cases due to meningococcal sepsis (*Neisseria meningitidis*); develops in 15–25% of those with meningococcemia
    - c. Occurs rarely with other pathogens: *Streptococcus pneumoniae*, group B streptococcus (in neonates), *Haemophilus influenzae* type b and others
  2. Homozygous protein C or protein S deficiency
    - a. Seen in neonatal period



**Figure 15.13** Purpura fulminans – associated with sepsis

3. Idiopathic purpura fulminans (uncommon)
  - a. Postinfectious—after a relatively benign antecedent infection (e.g. varicella or group A streptococcal infection)
  - b. Unknown etiology—after noninfectious condition (e.g. cutaneous hypersensitivity reaction, or stomatitis)
  - c. Differs from acute infectious form in that organ involvement other than skin usually does not occur, extremities are spared, and there is lower mortality (circulatory collapse not initially present)
- Cutaneous lesions:
  1. Early skin discomfort followed by erythema with or without edema and petechiae
  2. Rapid evolution into painful, indurated, well-demarcated purpuric papules and plaques with erythematous borders
  3. Late vesicles and bullae in necrotic areas, hemorrhagic necrosis, and eschar formation
  4. Gangrene of subcutaneous tissues, muscle and/or bone
- Extracutaneous clinical features:
  1. Epiphyseal growth plate necrosis; may lead to limb shortening
  2. Shock, thrombotic hemorrhage of multiple vascular beds and organ systems (e.g. adrenal glands, lungs and kidney), and multi-organ dysfunction are common

### *Pathogenesis*

- Cutaneous lesions caused by widespread dermal vascular thrombosis
- Laboratory evidence of a consumptive coagulopathy (DIC)
  1. Prolonged prothrombin time (PT) and partial thromboplastin time (PTT)
  2. Decreased fibrinogen levels
  3. Elevated fibrin degradation products (e.g. D-dimers)
  4. Reduced protein C, protein S and antithrombin III levels
- Histology: dermal vascular thrombosis and secondary hemorrhagic necrosis

### *Diagnosis*

- Characteristic clinical course
- Laboratory studies: CBC with platelet count, PT, PTT, fibrinogen, fibrin

degradation products, protein C and S, antithrombin III

### *Differential diagnosis*

- Thrombotic thrombocytopenic purpura
- Hemolytic uremic syndrome
- Coumadin (warfarin) necrosis

### *Treatment*

- Acute infectious purpura fulminans:
  1. Treat underlying infection and shock with supportive measures and IV antibiotics
  2. Fresh-frozen plasma or prothrombin complex concentrate – for protein C, protein S and antithrombin III replacement
  3. Blood components as necessary: packed red blood cells, platelets, cryoprecipitate
  4. Vitamin K
  5. Consultation of surgical and nutritional services
  6. Local skin care: topical antibiotics and debridement as needed
- Idiopathic purpura fulminans
  1. Fresh-frozen plasma or prothrombin complex concentrate for replacement of coagulation products
  2. Heparin anticoagulation: full-dose heparin for at least 2 weeks after skin lesions cease to develop
  3. Protein C concentrate if indicated
  4. Antibiotic coverage until culture results are negative – to cover Gram-positive cocci, meningococci, Gram-negative bacilli
  5. Local skin care using topical antibiotics and debridement as needed
- Neonatal purpura fulminans
  1. Acute setting:
    - a. Initiate therapy immediately
    - b. Fresh-frozen plasma or prothrombin complex concentrate – replace protein C and S
    - c. Alternative: protein C concentrate, advantage of avoiding blood volume overload
  2. Long-term treatment:
    - a. Low-dose oral anticoagulants plus replacement therapy
    - b. Topical nitroglycerin may be applied to poorly perfused extremities
    - c. Protein C concentrates for protein C deficiency

## Prognosis

- Can be fatal, especially in cases of acute infectious purpura fulminans
  1. Meningococcemia with purpura fulminans carries a 20–60% mortality rate
  2. Idiopathic purpura fulminans has lower mortality rate (~15%)
- High morbidity related to loss of digits, limbs, or areas of skin

## References

Baselga E, Drolet BA, Esterly NB. Purpura in infants and children. *J Am Acad Dermatol* 1997; 37: 673–705

Darmstadt GL. Acute infectious purpura fulminans: pathogenesis and medical management. *Pediatr Dermatol* 1998; 15: 169–83

Esmon CT. The protein C pathway. *Chest* 2003; 124 (3 Suppl): 26S–32S

Ilan Y, Naparstek Y. Henoch Schönlein purpura in children and adults: is it one entity? *Semin Arthritis Rheum* 2002; 32: 139–40

Levin M, Eley BS, Louis J, et al. Postinfectious purpura fulminans caused by an autoantibody directed against protein C. *J Pediatr* 1995; 127: 355–63

Manco-Johnson MJ, Nuss R, Key N, et al. Lupus anticoagulant and protein S deficiency in children with postvaricella purpura fulminans or thrombosis. *J Pediatr* 1996; 128: 319–23

Pathan N, Faust SN, Levin M. Pathophysiology of meningococcal meningitis and septicemia. *Arch Dis Child* 2003; 88: 601–7

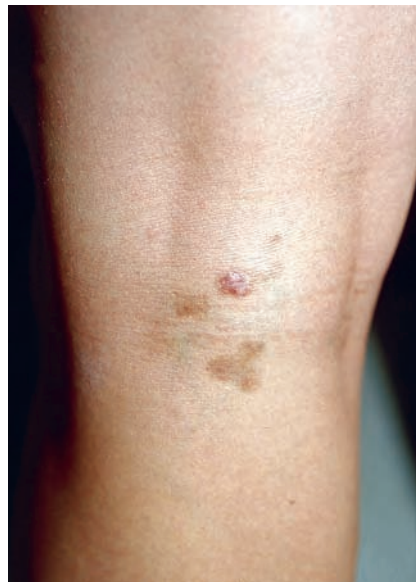Wheeler JS, Anderson BJ, De Chalain TM. Surgical interventions in children with meningococcal purpura fulminans – a review of 117 procedures in 21 children. *J Pediatr Surg* 2003; 38: 597–603

## PIGMENTED PURPURA

Synonym: primary (idiopathic) capillaritis

### General

- Group of closely related, chronic, benign conditions with similar histologic and clinical manifestations
  1. Clinical: nonpalpable petechiae and hemosiderotic eruptions; old and new petechiae can be seen at the same examination (Figure 15.14)



**Figure 15.14** Pigmented purpura with cayenne pepper red dots and hemosiderin deposition

2. Histology: perivascular lymphocytic infiltrate, extravasation of red blood cells, deposit of hemosiderin (mostly inside macrophages), narrowing of the lumen of small vessels, and endothelial swelling
- Unknown etiology
  - Includes:
    1. Schamberg progressive pigmented purpura (see below)
    2. Lichen aureus (see below)
    3. Purpura annularis telangiectodes of Majocchi
    4. Pigmented purpuric lichenoid dermatitis of Gougerot and Blum
    5. Eczematoid-like purpura of Coucas and Kapetanakis

### References

Kim HJ, Skidmore RA, Woosley JT. Pigmented purpura over the lower extremities. *Purpura annularis telangiectodes* of Majocchi. *Arch Dermatol* 1998; 134: 1477–80

Pock L, Capkova S. Segmental pigmented purpura. *Pediatr Dermatol* 2002; 19: 517–19

Reinhold U, Seiter S, Ugurel S, Tilgen W. Treatment of progressive pigmented purpura with oral bioflavonoids and ascorbic acid: an open pilot study in 3 patients. *J Am Acad Dermatol* 1999; 41: 207–8



Satoh T, Yokozeki H, Nishioka K. Chronic pigmented purpura associated with odontogenic infection. *J Am Acad Dermatol* 2002; 46: 942–4

Weston WL, Orchard D. Vascular reaction. In *Pediatric Dermatology*, 3rd edn. Schachner LA, Hansen RC, eds. Mosby: New York, 2003: 821–2

## Schamberg disease

Synonym: Schamberg progressive pigmented purpura

### Major points

- Most common of the pigmented purpuras
- Common cause of chronic petechiae in children
- Clinical findings:
  1. Asymptomatic nonpalpable purpura and petechiae with orange to brown patches; old and new petechiae can be seen within a patch
  2. Usually affects the legs but can be seen elsewhere (e.g. trunk)
  3. Usually bilateral but may be asymmetric or unilateral, especially in adolescents
- Chronic course, often lasts months to years

### Pathogenesis

- Etiology unknown
- Benign chronic capillaritis; capillary fragility leads to red cell extravasation
- Histology: mild perivascular infiltrate, mainly lymphocytes, extravasated red blood cells, and macrophages containing hemosiderin deposits involving the papillary and upper dermis; focal parakeratosis and spongiosis of epidermis

### Diagnosis

- Characteristic clinical findings
- Biopsy helpful

### Differential diagnosis

- Vasculitis
- Cutaneous T-cell lymphoma
- Pityriasis lichenoides

### Treatment

- Treatment is difficult and often ineffective
- Mid-strength topical steroids
- Therapies that have been reported to be effective without serious side-effects: combination therapy

with oral bioflavonoids and ascorbic acid; pentoxifylline

### Prognosis

- Benign but chronic course
- Petechiae and pigmentation may last for months to years

### References

- Hersh CS, Shwayder TA. Unilateral progressive pigmentary purpura (Schamberg's disease) in a 15-year-old boy. *J Am Acad Dermatol* 1991; 24: 651
- Kano Y, Hirayama K, Orihara M, Shiohara T. Successful treatment of Schamberg's disease with pentoxifylline. *J Am Acad Dermatol* 1997; 36: 827–30
- Reinhold U, Seiter S, Ugurel S, Tilgen W. Treatment of progressive pigmented purpura with oral bioflavonoids and ascorbic acid: an open pilot study in 3 patients. *J Am Acad Dermatol* 1999; 41: 207–8
- Torrelo A, Requena C, Mediero IG, Zambrano A. Schamberg's purpura in children: a review of 13 cases. *J Am Acad Dermatol* 2003; 48: 31–3

## Lichen aureus

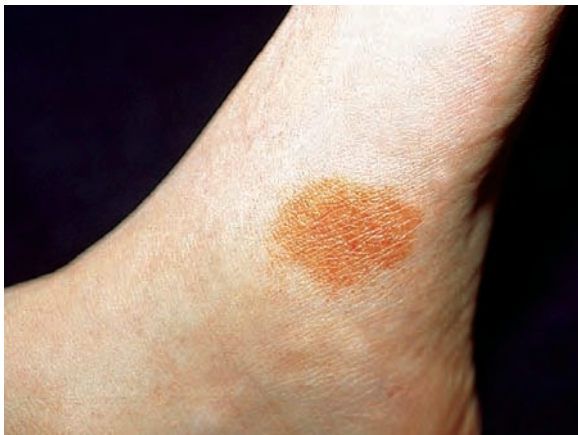Synonym: lichen purpuricus

### Major points

- Type of pigmented purpura
- Male/female ratio = 1
- Onset at any age (17% of cases occur in children)
- Clinical findings:
  1. Yellow-gold (aureus), gold-brown, or burnt-orange papules or macules; isolated or coalescing into patches of 1–20 cm in diameter; with scattered petechiae (Figure 15.15)
  2. Solitary or multiple lesions
  3. Unilateral, bilateral, or rarely a segmental or zosteriform distribution
  4. Occurs more often on the legs, arms, trunk; reported on the abdomen and face
  5. Usually asymptomatic, but rarely is pruritic, painful, or accompanied by a burning sensation

### Pathogenesis

- Etiology unknown
- Benign chronic capillaritis; capillary fragility leads to red cell extravasation



**Figure 15.15** Lichen aureus – yellow-brown persistent patch

- Sporadic cases associated with drug consumption or asymptomatic infection (e.g. lower urinary tract infection, otitis, tonsillitis)
- Histology: lymphohistiocytic band-like infiltrate, sometimes perivascular, in papillary dermis, extravasated erythrocytes, and hemosiderin deposits; overlying epidermis is normal

### Diagnosis

- Characteristic clinical findings
- No associated laboratory abnormalities
- Biopsy helpful

### Differential diagnosis

- Bruising
- Drug eruption
- Dermatitis artefacta

### Treatment

- Largely unresponsive to treatment (topical or systemic)
- Topical steroids useful in rare instances
- PUVA has been used successfully in those >11 years of age

### Prognosis

- Chronic course
- Tends to resolve spontaneously in months to years (variable)

### References

- Aoki M, Kawana S. Lichen aureus. *Cutis* 2002; 69: 145–8
- Gelmetti C, Cerri D, Grimalt R. Lichen aureus in childhood. *Pediatr Dermatol* 1991; 8: 280–3
- Ling TC, Goulden V, Goodfield MJ. PUVA therapy in lichen aureus. *J Am Acad Dermatol* 2001; 45: 145–6
- Patrizi A, Neri I, Marini R, et al. Lichen aureus with uncommon clinical features in a child. *Pediatr Dermatol* 1996; 13: 173
- Rubio FA, Robayna G, Herranz P, et al. Abdominal lichen aureus in a child. *Pediatr Dermatol* 1997; 14: 411

# VASCULAR AND LYMPHATIC DISEASES

## VASCULAR DISORDERS

### General

- Vascular birthmarks are one of the most common forms of congenital lesions
- Occur in 1–2% of children surveyed in the newborn nursery

### Hemangioma of infancy

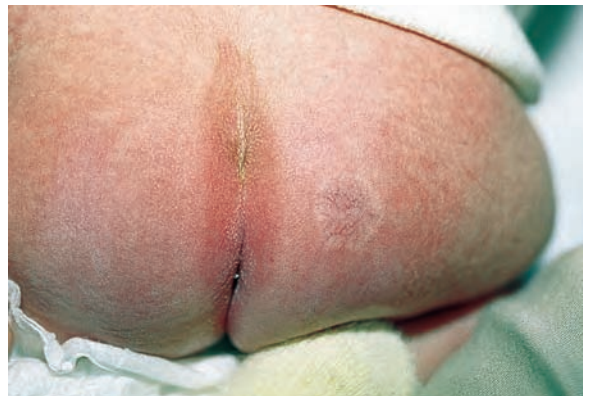Synonym: strawberry hemangioma

### General

- Benign growth of endothelial cells which appears at birth or within the first 2 months of life, and slowly involutes over 5–10 years
- Female/male ratio is 5 : 1
- Premature babies <1500 g are more commonly affected
- 50% on head and neck
- Multiple lesions are seen in 15–30% of cases

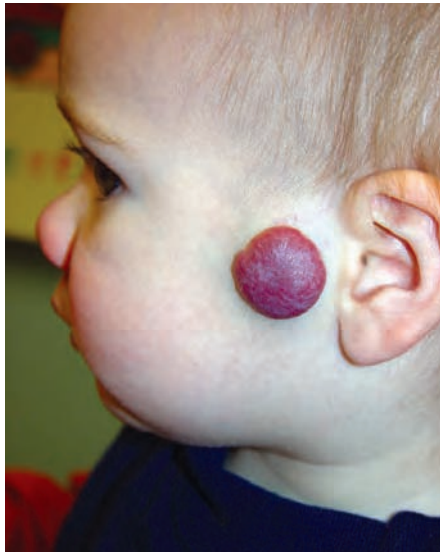### Major points

- At birth, skin may appear normal in color and texture or have a precursor lesion (Figure 16.1)
- Precursor lesions:
  1. Faint hypopigmentation resembling nevus anemicus
  2. Small telangiectatic patch
  3. Area of erythema resembling a capillary malformation
  4. Skin ulceration
  5. Bruise-like area

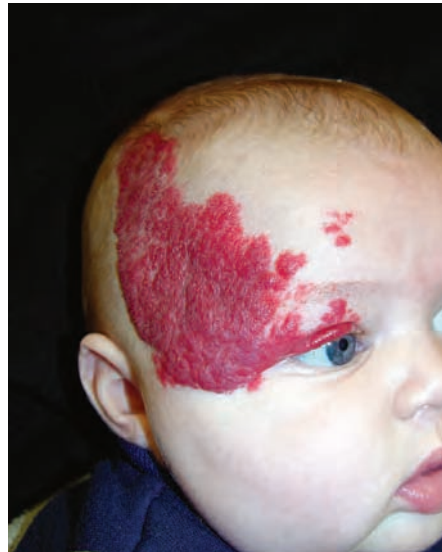

**Figure 16.1** Superficial hemangioma – early, with halo from vasoconstriction

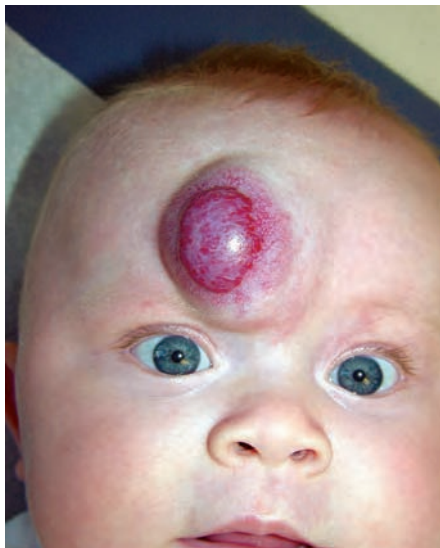- Growth phase:
  1. Begins within first 2 months with a quickly growing, red vascular plaque (Figures 16.2–16.7)
  2. Grows for 6–15 months
  3. Followed by stabilization period where growth plateaus and begins to develop a white surface
  4. After this plateau period, hemangioma begins to involute
  5. Fully developed hemangiomas of infancy are present at birth in about 5% of cases
- Involution: virtually all undergo spontaneous involution
  1. Some leave no trace of previous lesion
  2. Abnormal skin is often left behind: telangiectasias, atrophy, hypopigmentation, anetoderma (Figures 16.8 and 16.9)
  3. Fifty per cent involute by 5 years, 70% involute by 7 years and 90% involute by 9 years



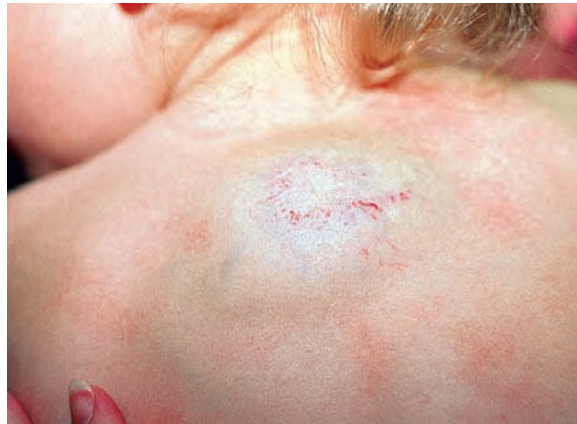**Figure 16.2** Hemangioma – typical vascular nodule on the face



**Figure 16.4** Hemangioma – segmental vascular plaque associated with closure of the eyelid. This child required oral steroids to keep the eyelid open



**Figure 16.3** Superficial and deep hemangioma – typical vascular nodule on the forehead



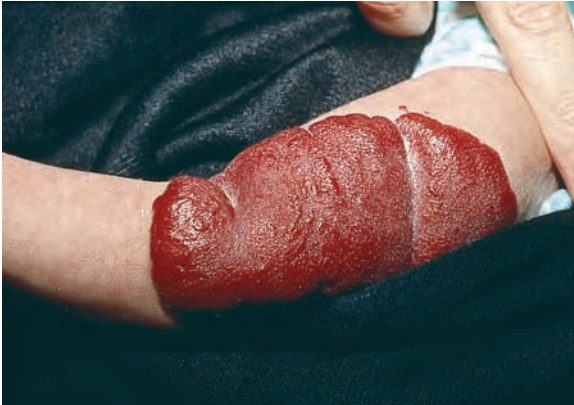**Figure 16.5** Deep hemangioma – deep purple tumor with telangiectasias on the surface

- Clinical subtypes:

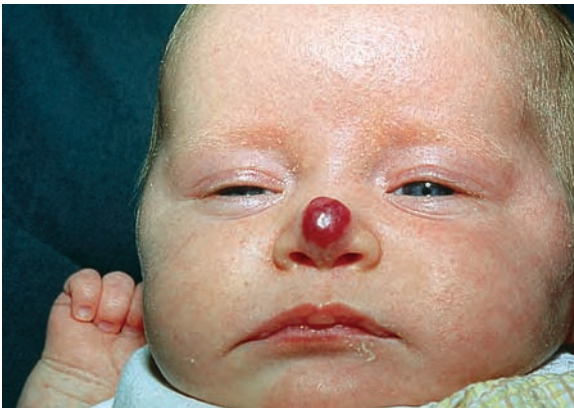1. Superficial hemangiomas are most common and constitute 50–60% of all hemangiomas
2. Deep hemangiomas (previously called 'cavernous hemangiomas') are deep bluish swellings with a telangiectatic surface

3. Mixed hemangiomas have both superficial and deep components
  4. Disseminated neonatal hemangiomatosis – numerous small hemangiomas (1 mm to 2 cm) with high risk of internal involvement (e.g. liver, gastrointestinal tract and/or brain) and heart failure (Figure 16.10)
- Complications
    1. Ulceration may occur in the growth phase, especially around the mouth or in the diaper





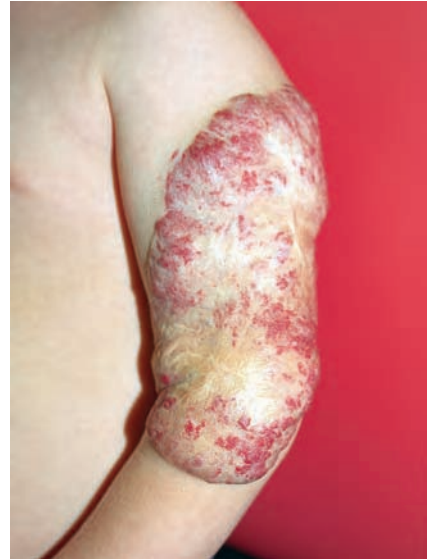**Figure 16.6** Superficial hemangioma – typical vascular plaque with papular surface



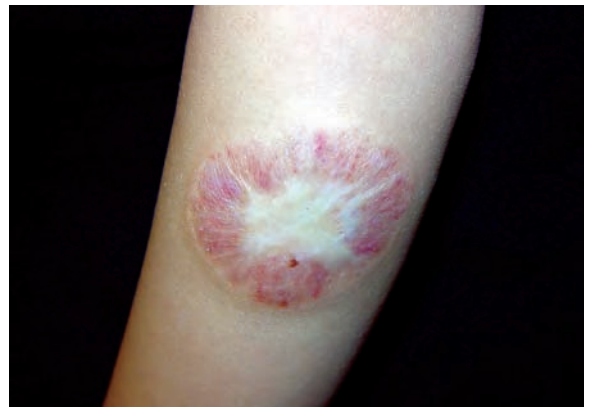**Figure 16.7** Cyrano nose – hemangioma involving the nasal tip

area; heals slowly and can last for months (Figure 16.11)

2. Bleeding is rarely a problem, although frequently expressed by parents as a concern
  - a. If bleeding should occur, direct pressure to the area for several minutes will usually stop the bleeding. If it does not stop, surgical intervention may be warranted
3. Kasabach–Merritt syndrome
  - a. Sudden growth of the lesion, tenseness, tenderness and a purpuric appearance
  - b. Decreased platelets
  - c. Petechiae and purpura
  - d. Average age: 6 weeks
  - e. Histology: tufted angioma, or Kaposiform hemangioendothelioma



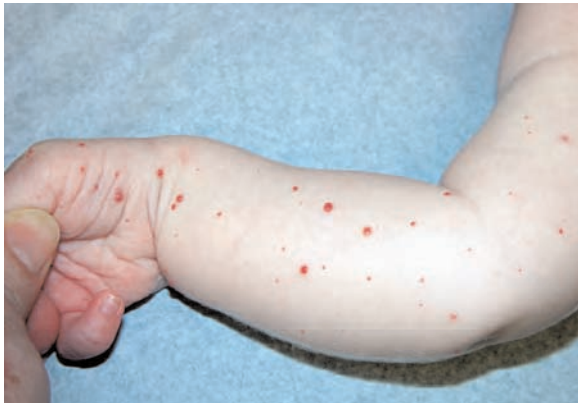**Figure 16.8** Hemangioma – residual scar at age 2 $\frac{1}{2}$  years with crinkly surface changes (same child as Fig 16.6)



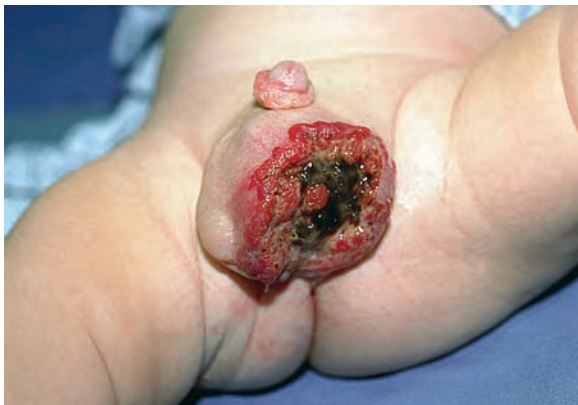**Figure 16.9** Hemangioma – residual scar at age 4 years in another patient

4. PHACES syndrome: Posterior fossa brain malformations (e.g. Dandy–Walker malformation), Hemangiomas (especially large, plaque-like facial lesions), Arterial anomalies, Coarctation of the aorta or other cardiac defects, Eye abnormalities, Sternal cleft or supra-umbilical raphe (Figure 16.12)
5. Sacral hemangioma: associated with tethered cord (Figure 16.13)
6. Airway compromise: usually associated with large hemangiomas in the beard distribution (Figure 16.14)





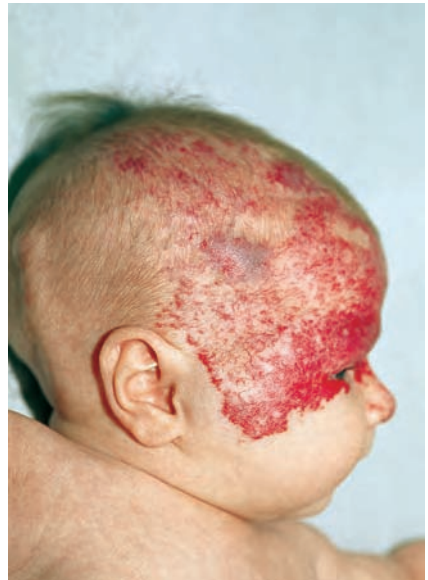**Figure 16.10** Diffuse neonatal hemangiomatosis associated with liver hemangiomatosis



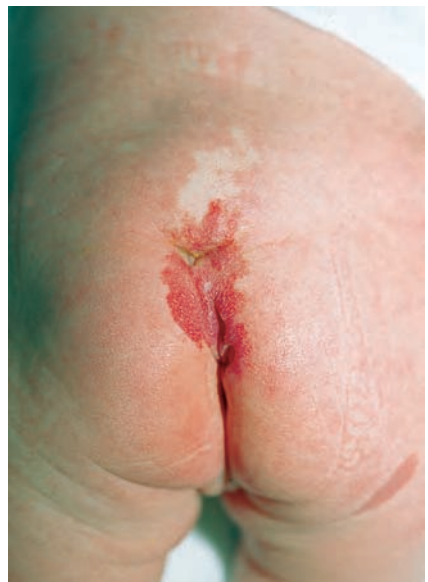**Figure 16.11** Ulcerated hemangiomas often occur in the diaper area

### Pathogenesis

- Etiology unknown, but it is thought that angiogenic factors are involved (overexpression of basic fibroblast growth factor, vascular endothelial growth factor, proliferating cell nuclear antigen, type IV collagenase, etc.)
- Proliferation of endothelial cells
- Embryologically blastogenic factors play a role
- Skin biopsy is rarely needed; however, it can differentiate soft tissue tumors (e.g. Kaposiform hemangioendothelioma, myofibromatosis, rhabdomyosarcoma)
- Endothelia of hemangiomas express GLUT1, a glucose transporter normally restricted to endothelia with blood–tissue barrier function, as in brain and placenta as well as other immunohistochemical markers resembling placental tissue



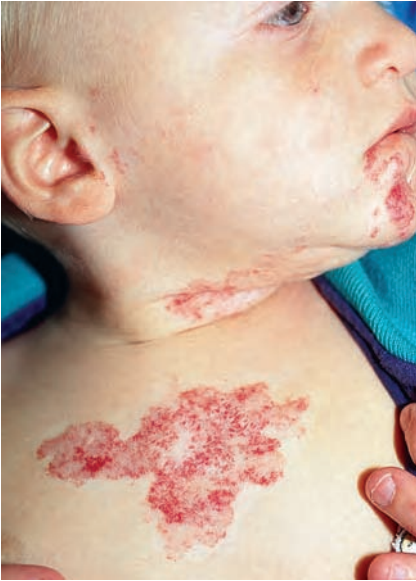**Figure 16.12** PHACES syndrome – associated with Dandy–Walker malformation



**Figure 16.13** Sacral hemangioma – associated with tethered cord

### Diagnosis

- Typical clinical appearance in 95% of cases
- For atypical lesions, diagnostic tests may be helpful:
  1. Platelet count to evaluate for Kasabach–Merritt syndrome



**Figure 16.14** Hemangiomas in the beard area and chest can be associated with tracheal hemangiomas

2. Ultrasound: may be helpful in hepatic hemangiomas, but also useful with large facial hemangiomas to differentiate extent of lesion and possible structural brain abnormalities
3. Magnetic resonance imaging (MRI) can distinguish between hemangiomas and venous malformations, and determine structural brain abnormalities

### *Differential diagnosis*

- Capillary malformation
- Venous malformation
- Arteriovenous malformation
- Pyogenic granuloma
- Nasal glioma
- Spitz nevus
- Dermoid cyst
- Blue nevus
- Myofibromatosis
- Rhabdoid tumor

### *Treatment*

- Parent education: discussion of natural history of hemangiomas; serial photographs helpful; anticipatory guidance on how to handle comments and queries from strangers, family members

- Periodic re-evaluation, particularly in growth and involutional phases
- Therapy should be individualized based on size of lesion, location, presence of complications and age of patient
- Watchful waiting is treatment for majority of hemangiomas of infancy
- Surgery may be indicated when the child is 3–5 years of age, and occasionally earlier
- Indications for treatment:
  1. Life-threatening illness
  2. Loss of vision, amblyopia (hemangioma around the eye should always be followed by an ophthalmologist)
  3. Respiratory distress or stridor
  4. Kasabach–Merritt syndrome
  5. Hepatic hemangiomatosis
  6. Cardiac failure
  7. Skin ulceration
  8. Bleeding
  9. Permanent disfigurement, particularly large hemangiomas on face, nose, lips, ear
- Medical treatment
  1. Intralesional corticosteroids – triamcinolone 3–5 mg/kg per treatment (maximum 20 mg)
  2. Systemic corticosteroids: prednisone 2–5 mg/kg per day given BID initially then once daily for several months until stabilization, then tapered
  3. Interferon- $\alpha$  (subcutaneous) – initial dose of 1–3 million U/m<sup>2</sup> per day and increased as tolerated until hemangioma or symptoms have improved. Side-effect: spastic diplegia in ~10%
  4. Pressure occlusion on an extremity with Ace wrap or Jobst stocking, making sure that the distal portion does not develop necrosis
- Surgical excision
  1. Not necessary in majority of cases
  2. May be indicated for small, easily excisable lesions on face or pedunculated hemangiomas likely to leave significant fibrofatty residua after involution
- Flash-lamp pumped pulsed dye laser
  1. Decreases telangiectasias on surface, and those left over after lesion has resolved
  2. Ulcerated hemangiomas may heal more quickly and less painfully
  3. Other lasers (argon, copper vapor, Nd-YAG, krypton, KTP) may be useful in certain cases

- Cryosurgery with cryoprobe
- Radiation
  1. Generally should be avoided, but may be indicated in severe, uncontrollable hemangiomas
- Embolization may be attempted in selected lesions which have life-threatening consequences
- Photography is very helpful in documenting progression and resolution

### Prognosis

- Depends upon location, complications, results after involution, psychological effects
- Early on, it can be difficult to predict the ultimate size, rate of involution, and results; however, a physician knowledgeable about hemangiomas would be a good source of information

### References

- Barlow CF, Priebe CJ, Mulliken JB, et al. Spastic diplegia as a complication of interferon alfa-2a treatment of hemangiomas of infancy. *J Pediatr* 1998; 132: 527–30
- Bennett ML, Fleischer AB, Chamlin SL, Frieden IJ. Oral corticosteroid use is effective for cutaneous hemangiomas. *Arch Dermatol* 2001; 137: 1208–13
- Boon LM, MacDonald DM, Mulliken JB. Complications of systemic corticosteroid therapy for problematic hemangioma. *Plast Reconstr Surg* 1999; 104: 1616–23
- Bronzetti G, Giardini A, Patrizi A, et al. Ipsilateral hemangioma and aortic arch anomalies in posterior fossa malformations, hemangiomas, arterial anomalies, coarctation of the aorta and cardiac defects and eye abnormalities (PHACE) anomaly: report and review. *Pediatrics* 2004; 113: 412–15
- Ceisler EJ, Santos L, Blei F. Periocular hemangiomas: what every physician should know. *Pediatr Dermatol* 2004; 21: 1–9
- Drolet BA, Esterly NB, Frieden IJ. Hemangiomas in children. *N Engl J Med* 1999; 341: 173–81
- Elsas FJ, Lewis AR. Topical treatment of periocular capillary hemangioma. *J Pediatr Ophthalmol Strabismus* 1994; 31: 153–6
- Enjolras O, Riche MD, Merland JJ, et al. Management of alarming hemangiomas in infancy: a review of 25 cases. *Pediatrics* 1990; 85: 491–7
- Esterly NB. Cutaneous hemangiomas, vascular stains and malformations, and associated syndromes. *Curr Probl Dermatol* 1995; 7: 65–108
- Frieden IJ, Eichenfield LF, Esterly NB, et al. Guidelines of care for hemangiomas of infancy. *J Am Acad Dermatol* 1997; 37: 631–7
- Frieden IJ, Reese V, Cohen D. PHACE Syndrome. *Arch Dermatol* 1996; 132: 307–11
- Herron MD, Coffin CM, Vanderhooft SL. Tufted angiomas: variability of the clinical morphology. *Pediatr Dermatol* 2002; 19: 394–401
- Metry DW, Dowd CF, Barkovich J, Frieden IJ. The many faces of PHACE syndrome. *J Pediatr* 2001; 139: 117–23
- Metry DW, Hebert AA. Benign cutaneous vascular tumors of infancy. When to worry, what to do. *Arch Dermatol* 2000; 136: 905–14
- Mulliken JB, Young AE. *Vascular Birthmarks: Hemangiomas and Malformations*. WB Saunders: Philadelphia, 1988
- North PE, Waner M, Mizeracki A, et al. A unique microvascular phenotype shared by juvenile hemangiomas and human placenta. *Arch Dermatol* 2001; 137: 559–70
- Wananukul S, Nuchprayoon I, Seksarn P. Treatment of Kasabach–Merritt syndrome: a stepwise regimen of prednisolone, dipyridamole, and interferon. *Int J Dermatol* 2003; 42: 741–8
- Wong S-N, Tay YK. Tufted angioma: a report of five cases. *Pediatr Dermatol* 2002; 19: 388–93

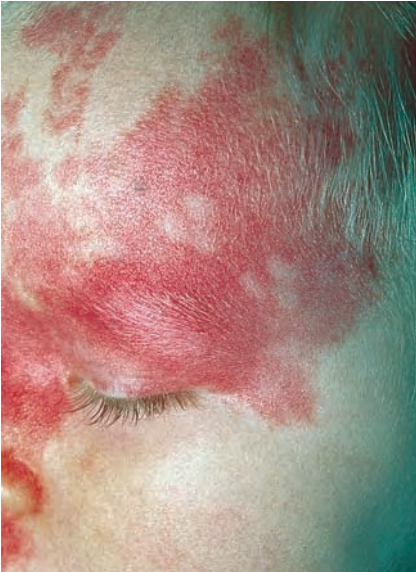## Vascular malformations

### General

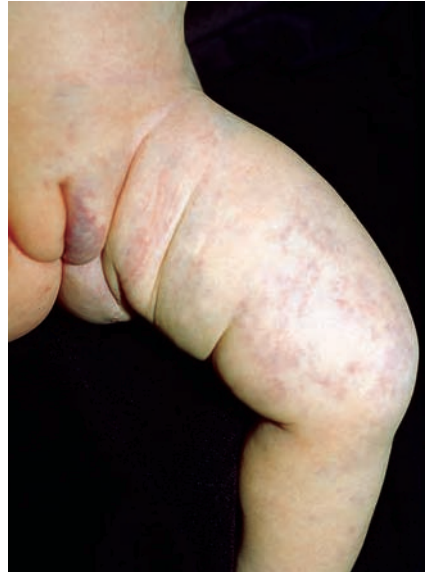- Malformation denotes an abnormal structure resulting from an aberration in embryologic development
- They do not resolve on their own and are always present at birth, although they might not be noticeable at birth
- They can involve veins, arteries, capillaries and occasionally lymphatic channels

### Major points

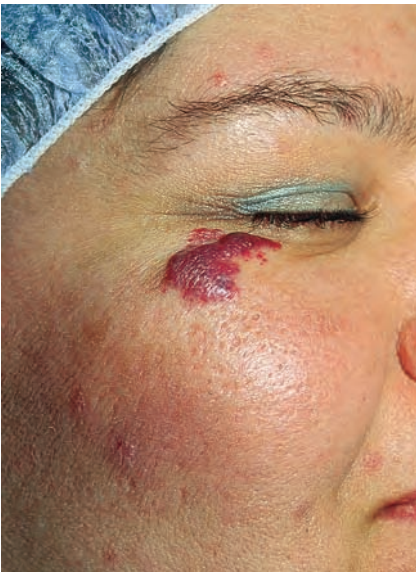- Capillary malformations (port wine stains, nevus flammeus)
  1. Most common type of vascular malformation
  2. Commonly occurs on the face, usually unilaterally, but can be anywhere on the body
  3. Noticeable at birth as pink, red or deep purple, macular patch which blanches with pressure (Figures 16.15 and 16.16)
  4. Involvement of first portion of fifth cranial nerve (V1) involving upper eyelid can be associated with glaucoma (~45%). An ophthalmologist should be consulted



**Figure 16.15** Capillary malformation (port wine stain), which is flat and pink in an infant



**Figure 16.17** Venous malformation – notice purple varicosities



**Figure 16.16** Capillary malformation in an adult, raised with dark red-purple papules

- 5. Small risk of glaucoma occurs in V2; V3 has no risk of glaucoma
- Venous malformations
  1. Appears as blue or purple, grouped, subcutaneous nodules with enlarged neighboring veins (Figure 16.17)

2. Hyperhidrosis overlying the malformation is common
3. Symptoms
  - a. Usually asymptomatic
  - b. May develop pressure on other nearby structures
  - c. Pain may be caused by slow flow and clot formation
  - d. Complications usually later in life
4. Varicosities (varicose veins) commonly occur
5. Complications:
  - a. Glaucoma is associated with lesions in V1 and V2 distribution
6. Blue rubber bleb syndrome (OMIM no. 112200)
  - a. Multiple venous malformations of the skin and gastrointestinal (GI) tract
  - b. Blue or purple soft rubbery nodules which can be easily compressed
  - c. Nocturnal pain in the lesions common
  - d. Bleeding in the GI tract from the lesions may cause melena and anemia
  - e. Other organs may be involved
  - f. Autosomal dominant; chromosome 9p21; gene: receptor tyrosine kinase TIE2
7. Maffucci syndrome (OMIM no. 166000)
  - a. Diffuse asymmetric enchondromatosis and multiple venous malformations



- b. Soft blue subcutaneous nodules which progressively enlarge
- c. Hard nodules appear on long bones, hands, fingers and feet
- d. Gross deformity may occur
- e. Enchondromas can transform into chondrosarcoma (~15%)
- f. Gene map locus 3p22-p21.1; gene: PTH/PTHrP type I receptor

### Pathogenesis

- Vascular ectasias rather than a proliferative process; progressive vascular dilatation of pre-existing blood vessels caused by either a defect in vascular walls or abnormalities of supporting structure of surrounding dermis
- Arterial malformations are high-flow lesions that can cause right-to-left shunting with subsequent heart failure
  1. Doppler testing can reveal shunting
  2. Listen to the lesion with a stethoscope for a bruit

### Diagnosis

- Clinical presentation
- May need further testing: MRI if not straightforward or complications arise

### Differential diagnosis

- Hemangioma of infancy
- Lymphatic malformation

### Treatment

- Pulsed dye laser (577–585 nm)
- Surgery may be warranted in lesions with persistent pain, or bleeding
- Sclerotherapy by interventional radiologist for symptomatic deep venous malformations
- Treatment for tenderness with warm packs and oral aspirin

### Prognosis

- Persist into adult life, becoming darker purple, raised and thickened with cobblestone appearance
- Small angiomatous nodules may appear within the lesion
- Prognosis depends upon location, size and extent

### References

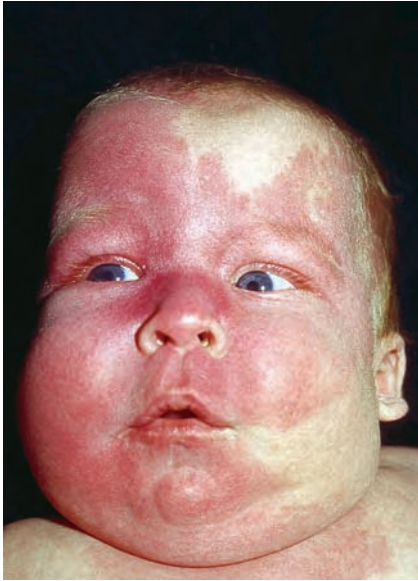- Bedocs PM, Gould JW. Blue rubber-bleb nevus syndrome: a case report. *Cutis* 2003; 71: 315–18
- Cantatore JL, Kriegel DA. Laser surgery: an approach to the pediatric patient. *J Am Acad Dermatol* 2004; 50: 165–84
- Enjolras O, Ciabrini D, Mazoyer E, et al. Extensive pure venous malformations in the upper or lower limb: a review of 27 cases. *J Am Acad Dermatol* 1997; 36: 219–25
- Enjolras O. Vascular tumors and vascular malformations: are we at the dawn of a better knowledge? *Pediatr Dermatol* 1999; 16: 238–41
- Ertem D, Acar Y, Kotiloglu E, et al. Blue rubber bleb nevus syndrome. *Pediatrics* 2001; 107: 418–20
- Gabikian P, Clatterbuck RE, Gailloud P, Rigamonti D. Developmental venous anomalies and sinus pericranii in the blue rubber-bleb nevus syndrome. Case report. *J Neurosurg* 2003; 99: 409–11
- McClellan K, Hanke CW. The medical necessity for treatment of port-wine stains. *Dermatol Surg* 1997; 23: 663–7
- Michel S, Landthaler M, Hohenleutner U. Recurrence of port-wine stains after treatment with flashlamp-pumped pulsed dye laser. *Br J Dermatol* 2000; 143: 1230–4
- Nguyen CM, Yohn JJ, Huff C, et al. Facial port wine stains in childhood: prediction of the rate of improvement as a function of the age of the patient, size and location of the port wine stain and the number of treatments with the pulsed dye (585 nm) laser. *Br J Dermatol* 1998; 138: 821–5
- Requena L, Sanguenza OP. Cutaneous vascular anomalies. Part I. Hamartomas, malformations, and dilatation of preexisting vessels. *J Am Acad Dermatol* 1997; 37: 523–49
- Sheu M, Fauteux G, Chang H, et al. Sinus pericranii: dermatologic considerations and literature review. *J Am Acad Dermatol* 2002; 46: 934–41

## Sturge–Weber syndrome

### Major points

- Facial capillary malformation including the V1 distribution (upper eyelid and forehead), accompanied by ipsilateral leptomeningeal angiomatosis (Figure 16.18)
- Glaucoma is usual but not invariably present
- Vascular malformation may be unilateral with a sharp midline cut-off, or may be bilateral and extensive
- Seizures are the most frequent neurological manifestation





**Figure 16.18** Sturge–Weber syndrome – associated with glaucoma, mental retardation and seizures

- Mental retardation common
- Other neurological abnormalities: hemiplegia, hemisensory defects, homonymous hemianopsia
- Other eye findings: buphthalmos, blindness
- Other skin findings: overgrowth of soft tissue and underlying bone of the face

#### *Pathogenesis*

- Etiology unknown
- Vascular malformation of vessels of brain, eye and skin
- Histology: increase in dilated venules, mainly in upper reticular dermis

#### *Diagnosis*

- MRI or computerized tomography (CT) scan can identify abnormal vasculature and extent of cortical calcifications
- Eye examination demonstrates glaucoma

#### *Differential diagnosis*

- Capillary malformation without internal involvement
- Other vascular malformations

#### *Treatment*

- Glaucoma should be followed by an ophthalmologist and may require surgery

- Seizures and mental retardation should be followed by pediatrician and/or neurologist

#### *Prognosis*

- Lesions are static or progressive

#### *References*

- Bebin EM, Gomez MR. Prognosis in Sturge–Weber disease: comparison of uni-hemispheric and bi-hemispheric involvement. *J Child Neurol* 1988; 3:181–4
- Dahan D, Fenichel GM, El-Said R. Neurocutaneous syndromes. *Adolesc Med State Art Rev* 2002; 13: 495–509
- Eerola I, Boon LM, Mulliken JB, et al. Capillary malformation–arteriovenous malformation, a new clinical and genetic disorder caused by RASA1 mutations. *Am J Hum Genet* 2003; 73: 1240–9
- Enjolras O, Riche MC, Merland JJ. Facial port-wine stains and Sturge–Weber syndrome. *Pediatrics* 1985; 76: 48–51

### **Klippel–Trenaunay syndrome**

#### *Major points*

- Cutaneous capillary and venous malformations, congenital varicosities, and hypertrophy of involved limb (Figures 16.19 and 16.20)
- Occasionally with an arteriovenous fistula (Parkes–Weber syndrome)
- Involved limb hypertrophied, with enlargement of muscles, thickened skin and excess subcutaneous fat
- Lymphedema can be present
- Venous thrombosis common
- Female/male ratio = 1
- Single lower limb is most common area involved, but bilateral lower limbs or upper limbs may be involved
- Lesions present at birth
- Sporadic

#### *Pathogenesis*

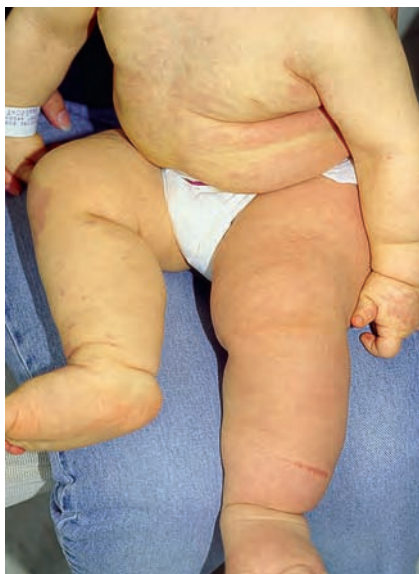- Etiology of overgrowth of tissues unknown but may be secondary to oversupply of blood to the subcutaneous tissues

#### *Diagnosis*

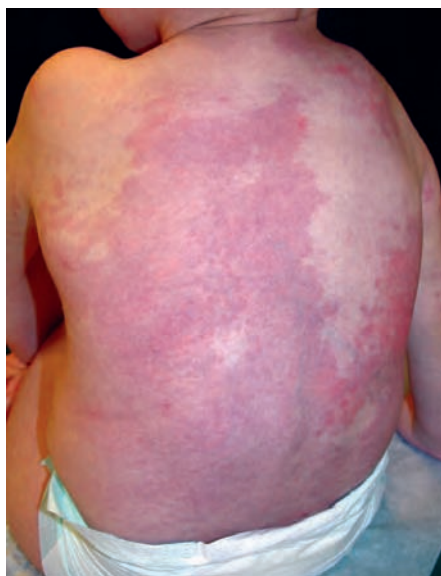- Clinical presentation

#### *Differential diagnosis*

- Vascular malformation without internal involvement



**Figure 16.19** Klippel-Trenaunay syndrome demonstrating hypertrophy of the limb with a capillary malformation



**Figure 16.20** Klippel-Trenaunay syndrome with extensive vascular malformation of the back as well as the extremities

### Treatment

- Superficial component can be treated with pulsed dye laser
- If there is leg length discrepancy, orthopedic referral
- Possible embolization if complications arise

### Prognosis

- Variable: may be static or progressive in hypertrophy
- May have increased leg length discrepancy

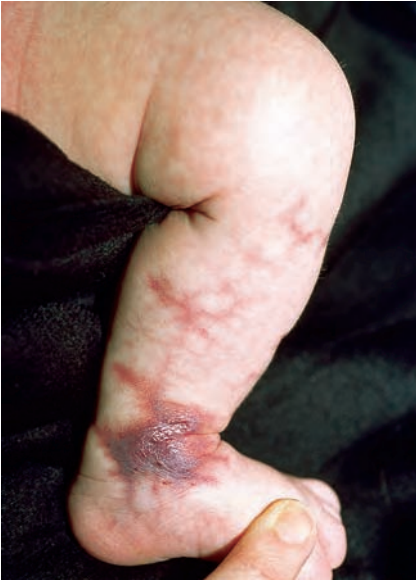### References

- Aelvoet GE, Jorens PG, Roelen LM. Genetic aspects of the Klippel-Trenaunay syndrome. *Br J Dermatol* 1992; 126: 603-7
- Bird LM, Jones MC, Kuppermann N, Huskins WC. Gram-negative bacteremia in four patients with Klippel-Trenaunay-Weber syndrome. *Pediatrics* 1996; 98: 739-41
- Dogan R, Faruk Dogan O, Oc M, et al. A rare vascular malformation, Klippel-Trenaunay syndrome. Report of a case with deep vein agenesis and review of the literature. *J Cardiovasc Surg* 2003; 44: 95-100
- Eerola I, Boon LM, Mulliken JB, et al. Capillary malformation-arteriovenous malformation, a new clinical and genetic disorder caused by RASA1 mutations. *Am J Hum Genet* 2003; 73: 1240-9
- Marler JJ, Fishman SJ, Upton J, et al. Prenatal diagnosis of vascular anomalies. *J Pediatr Surg* 2002; 37: 318-26
- Requena L, Sanguenza OP. Cutaneous vascular anomalies. Part I. Hamartomas, malformations, and dilatation of preexisting vessels. *J Am Acad Dermatol* 1997; 37: 523-49

## Cutis marmorata telangiectatica congenita

### Major points

- Malformation of blood vessels characterized by blue-violet, reticulated, marbled, cutaneous, vascular pattern present at birth, often with atrophy of involved tissues
- Unresponsive to warming
- Often segmental, involving one limb (frequently the leg) with a sharp cut-off at the midline (89%) or may be generalized (11%)
- Reticulated pattern frequently indented, atrophic, or may have ulcerations (Figure 16.21)
- Purplish color accentuated by crying, vigorous movement, or cold temperatures
- Telangiectasias often seen within area
- Associated with various congenital anomalies in 50% of patients (usually minor):
  1. Hypertrophy or atrophy of involved limb
  2. Other vascular anomalies



**Figure 16.21** Cutis marmorata telangiectatica congenita – reticulated, atrophic, vascular pattern on an extremity

3. Macrocephaly
  4. Glaucoma (if face involved)
  5. Persistent ductus arteriosus
  6. Congenital nevus
  7. Mental retardation
- Sporadic inheritance

#### Pathogenesis

- Etiology unknown, but thought to be ectasia of veins and possibly of capillaries from vasospasm *in utero*
- Histology: dilated capillaries and veins in all layers of dermis and subcutaneous fat

#### Diagnosis

- Clinical presentation

#### Differential diagnosis

- Cutis marmorata (normal variant)
- Klippel–Trenaunay syndrome
- Sturge–Weber syndrome
- Diffuse phlebectasia (appears later and is progressive)

#### Treatment

- Treatment is usually not needed
- If lesions persist, pulsed dye laser

#### Prognosis

- Gradual improvement in first 2 years
- Some lesions do not resolve completely

#### References

- Devillers ACA, de Waard-van der Spek FB, Oranje AP. Cutis marmorata telangiectatica congenita. Clinical features in 35 cases. *Arch Dermatol* 1999; 135: 34–8
- Fujita M, Darmstadt GL, Dinulos JG. Cutis marmorata telangiectatica congenita with hemangiomatous histopathologic features. *J Am Acad Dermatol* 2003; 48: 950–4
- Happle R. Dohi Memorial Lecture. New aspects of cutaneous mosaicism. *J Dermatol* 2002; 29: 681–92
- Mazereeuw-Hautier J, Carel-Caneppele S, Bonafe JL. Cutis marmorata telangiectatica congenita: report of two persistent cases. *Pediatr Dermatol* 2002; 19: 506–9
- Requena L, Sanguenza OP. Cutaneous vascular anomalies. Part I. Hamartomas, malformations, and dilatation of preexisting vessels. *J Am Acad Dermatol* 1997; 37: 523–49

#### Glomuvenous malformations

Synonyms: glomus tumors, glomangiomas

#### Major points

- Present as single or multiple, purple papules, nodules or plaques scattered over body (Figure 16.22)
- Size ranges from 5 mm to large plaques
- Usually asymptomatic but may be painful
- Congenital large plaques have been reported
- Lesions progressively enlarge slowly with time
- Usually sporadic but may be inherited – autosomal dominant with incomplete penetrance and variable expressivity

#### Pathogenesis

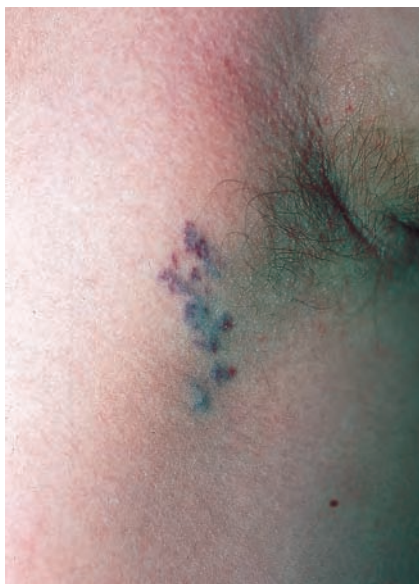- Abnormality of glomulin gene mapped to chromosome 1p21
- Uncontrolled growth of glomus cells

#### Diagnosis

- Clinical diagnosis with histologic confirmation
- Histology: nonencapsulated tumors with vascular spaces lined by one or two layers of glomus cells

#### Differential diagnosis

- Venous malformation
- Varicosities



**Figure 16.22** Glomuvenous malformation – typical purple intermittently painful vascular plaque

### *Treatment*

- Surgical excision
- Large lesions may be difficult, and usually do not respond to pulsed dye laser

### *Prognosis*

- Slowly progressive enlargement; can develop pain

### *References*

Brouillard P, Boon LM, Mulliken JB, et al. Mutations in a novel factor, glomulin, are responsible for glomuvenous malformations ('glomangiomas'). *Am J Hum Genet* 2002; 70: 866–74

Brouillard P, Viskula M. Vascular malformations: localized defects in vascular morphogenesis. *Clin Genet* 2003; 63: 340–51

Enjolras O, Mulliken JB. Vascular tumors and vascular malformations. New issues. *Adv Dermatol* 1997; 13: 375–423

## **Nevus anemicus**

### *Major points*

- Uncommon congenital vascular lesion which appears lighter than surrounding skin as a pale macule; no pigment involved

- Female/male ratio = 1
- Circumscribed, pale macule with irregular margins (Figure 16.23)
- Sometimes surrounded by satellite pink macules
- Location anywhere on body, but most often seen on upper chest
- Not accentuated by Wood's lamp examination

### *Pathogenesis*

- Pharmacologic anomaly responding to catecholamines rather than an anatomic one
- Vascular structures are histologically normal

### *Diagnosis*

- With diascopy, lesion is indistinguishable from blanched surrounding skin
- Friction, cold or heat accentuates normal surrounding skin but does not induce erythema within the lesion

### *Differential diagnosis*

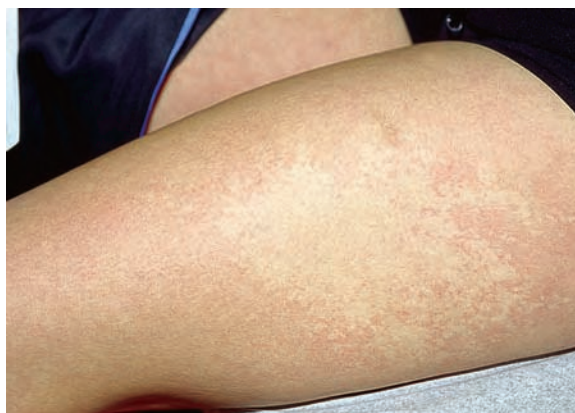- Nevus depigmentosus
- Vitiligo
- Hypopigmented macules of tuberous sclerosis

### *Treatment*

- Not needed, but camouflage make-up may be desired

### *Prognosis*

- Static



**Figure 16.23** Nevus anemicus – vasoconstricted patch unchanged by rubbing



## References

Eichenfield L, Larralde M. Neonatal skin and skin disorders. In *Pediatric Dermatology*, 3rd edn. Schachner LA, Hansen RC, eds. Mosby: Edinburgh, 2003: 221

Requena L, Sanguenza OP. Cutaneous vascular anomalies. Part I. Hamartomas, malformations, and dilatation of preexisting vessels. *J Am Acad Dermatol* 1997; 37: 523–49

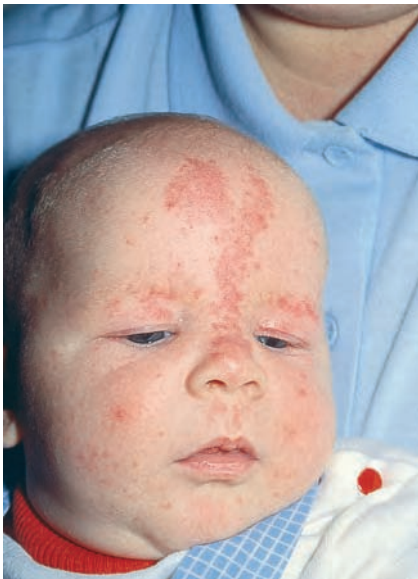## Nevus simplex (salmon patch)

### Major points

- Benign, erythematous, macular patch on newborn's glabellar region (Figure 16.24)
- Tends to disappear or lighten significantly in first year of life
- On face, colloquially called 'angel's kiss'
- On posterior neck, known as 'stork bite'
- 25–40% of newborns of all races have pink–red macular lesions on face, usually in midline glabella (salmon patch), or in occipital or nuchal regions

### Pathogenesis

- Thought to represent persistence of fetal circulatory patterns



**Figure 16.24** Salmon patch (nevus simplex) – typical glabellar distribution which improved in the first year of life

## Diagnosis

- Clinical presentation

## Differential diagnosis

- Capillary malformation

## Treatment

- None needed
- If persistent, pulsed dye laser

## Prognosis

- Nuchal lesions persist through life unchanged
- Sacral lesions persist through life, and are rarely associated with underlying anomalies
- Facial lesions usually lighten within the first years of life

## References

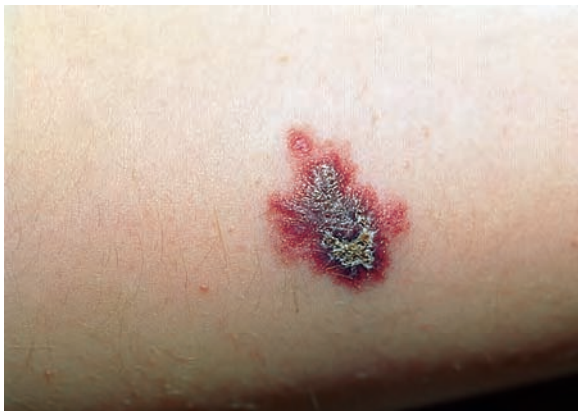Frieden I, Enjolras O, Esterly NB. Vascular lesions. In *Pediatric Dermatology*, 3rd edn. Schachner LA, Hansen RC, eds. Churchill Livingstone: New York, 2003: 833–62

## Angiokeratoma

### Major points

- Acquired, hyperkeratotic, superficial vascular abnormality with ectasia of pre-existing blood vessels in the papillary dermis
- Location usually lower extremities
- Presents either at birth or appears early in life as flat red, purple or blue patch (Figure 16.25)
- Slowly enlarges with time and becomes progressively verrucous or scaly
- Satellite lesions frequent
- Lesions bleed with trauma
- Types of angiokeratomas:
  1. Solitary angiokeratoma
    - a. Small, warty, purple-black papule usually on lower extremities
    - b. Thought to be caused by injury, trauma or chronic irritation
    - c. Thrombosis may occur
  2. Angiokeratoma circumscriptum
    - a. Large, solitary, hyperkeratotic, vascular, verrucous plaques
    - b. Usually present at birth
    - c. Occurs in bands, streaks or linear arrangements
    - d. Commonly on extremity





**Figure 16.25** Angiokeratoma – purple-red, hyperkeratotic plaque

3. Angiokeratoma of Mibelli
  - a. Several red-purple papules with hyperkeratotic surface on dorsal hand or foot, particularly fingers and toes
  - b. Appears in childhood or adolescence
  - c. More common in females
  - d. May be associated with cold injury, acrocyanosis or chilblains
  - e. Autosomal dominant
4. Angiokeratoma of Fordyce
  - a. Multiple red-purple 2–4-mm papules on scrotum or vulva
  - b. Most common in elderly patients
5. Angiokeratoma corporis diffusum
  - a. Cutaneous manifestation of Fabry disease, an X-linked recessive disorder caused by the deficiency of lysosomal hydrolase  $\alpha$ -galactosidase A
  - b. Multiple lesions appear in late childhood
  - c. Small, punctuate, dark, red-purple papules 1–2 mm in size usually more prominent on the lower trunk and legs
  - d. Enlarge and become more prominent with time
  - e. Neutral glycosphingolipids (trihexosylceramide) accumulates within lysosomes of endothelial cells, fibroblasts, and other cells throughout the body resulting in renal, cardiac, ocular and neurological abnormalities
  - f. Can also be seen in fucosidosis, galactosidosis and other rare enzymatic deficiencies

### Pathogenesis

- Etiology unknown
- Histology: thickened epidermis with hyperkeratosis, dilated capillaries and venules in papillary and reticular dermis. In Fabry disease, vacuolization of endothelial cells and smooth muscle cells as well as other cells
- Electron microscopy: lipid deposits in endothelial cells, pericytes and other cells which have characteristic lamellar structure

### Diagnosis

- Clinical presentation
- Biopsy often needed for confirmation

### Differential diagnosis

- Hemangioma of infancy
- Vascular malformation
- Angiomas
- Pyogenic granuloma

### Treatment

- Excision
- CO<sub>2</sub> laser
- Enzyme replacement for Fabry disease

### Prognosis

- Static or progressive

### References

- Kiyohara T, Kumakiri M, Kawasaki T, et al. Linear acral pseudolymphomatous angiokeratoma of children (APACHE): further evidence that APACHE is a cutaneous pseudolymphoma. *J Am Acad Dermatol* 2003; 48 (2 Suppl): 15–7
- Mohrenschlager M, Braun-Falco M, Ring J, Abeck D. Fabry disease: recognition and management of cutaneous manifestations. *Am J Clin Dermatol* 2003; 4: 189–96
- Schiller PI, Itin PH. Angiokeratomas: an update. *Dermatology* 1996; 193: 275–82

## LYMPHATIC MALFORMATIONS

### General

- Term used to describe localized or diffuse malformations of cutaneous, subcutaneous, or submucous lymphatic vessels

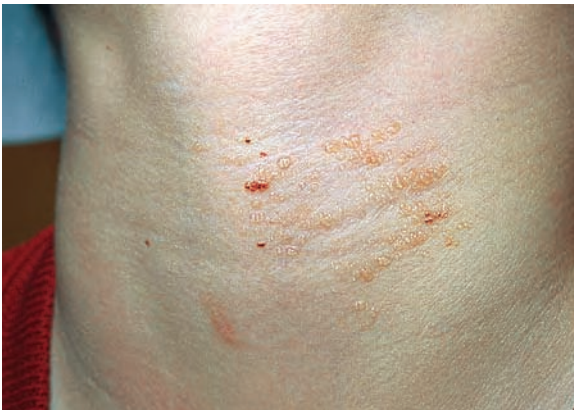## Lymphangioma circumscriptum

### Major points

- Most common variant of cutaneous lymphatic malformations
- Present at birth but may not be apparent, and may be noticed in childhood as a solitary soft tissue swelling
- Superficial lymphatic malformations are characterized by clear vesicles on the surface of the skin, grouped in plaques (Figure 16.26)
- Often small areas of bleeding within lymphatic channels from abnormal blood vessels which run parallel to abnormal lymph channels
- Verrucous surface sometimes seen
- Often involves deeper tissues
- Location can be anywhere but has a predilection for axilla, shoulder, neck, tongue and proximal parts of extremities
- Usually asymptomatic, but may ooze lymph fluid

### Pathogenesis

- Congenital malformation of lymphatics with formation of large cysts that lie in subcutaneous tissue and communicate with superficial lymphatic system by dilated dermal lymphatics
- Histology: dilated lymph vessels lined by flat endothelial cells situated beneath the epidermis and within the reticular dermis
- Deeper involvement is common, with individual lymph channels arranged in clusters
- Erythrocytes may be seen within some channels



**Figure 16.26** Lymphangioma circumscriptum – clear vesicles with some hemorrhage into the vesicles

### Diagnosis

- Clinical presentation
- Biopsy may be indicated, especially in deeper lesions without characteristic clinical features

### Differential diagnosis

- Herpes simplex
- Hemangioma
- Kaposi sarcoma
- Warts
- Molluscum contagiosum

### Treatment

- Surgical excision frequently results in recurrences because of interconnecting lymphatic channels
- Surgery should depend upon severity of signs and symptoms
- CO<sub>2</sub> laser can ablate superficial component, but often recurs
- Sclerotherapy by interventional radiologists for macrocystic lesions followed by surgery in some cases

### Prognosis

- Static or slowly progressive

### References

- Axt-Flidner R, Hendrik HJ, Schwaiger C, et al. Prenatal and perinatal aspects of a giant fetal cervicothoracic lymphangioma. *Fetal Diagn Ther* 2002; 17: 3–7
- Giguere CM, Bauman NM, Smith RJ. New treatment options for lymphangioma in infants and children. *Ann Otol Rhinol Laryngol* 2002; 111: 1066–75
- Hilliard RI, McKendry JBJ, Phillips MJ. Congenital abnormalities of the lymphatic system: a new clinical classification. *Pediatrics* 1990; 86: 988–94
- McAlvany JP, Jorizzo JL, Zanolli D, et al. Magnetic resonance imaging in the evaluation of lymphangioma circumscriptum. *Arch Dermatol* 1993; 129: 194–7
- Mulliken JB, Fishman SJ, Burrows PE. Vascular anomalies. *Curr Probl Surg* 2000; 37: 517–84
- Ryan TJ, Mortimer PS, Jones RL. Lymphatics of the skin, neglected but important. *Inter J Dermatol* 1986; 25: 411–19

## Macrocystic lymphatic malformations

### Major points

- Abnormal lymphatic channels in deeper portions of the lymphatic system

- Characterized by subcutaneous painless nodules covered by normal skin
- Usually asymptomatic, but may be painful when pressed or bumped
- Cystic hygroma occurs around neck, axillae and inguinal regions with prominent deep component (Figure 16.27)
  1. Presents at birth or early childhood as a large cystic mass; demonstrated by transillumination
  2. Cystic hygromas of posterior neck associated with Turner or Noonan syndrome, hydrops fetalis and other congenital malformations

### Pathogenesis

- Histology: irregular, dilated and interconnecting lymphatic vessels with multilocular cystic cavities in subcutaneous fat
- Some lymph channels contain smooth muscle bundles in walls

### Diagnosis

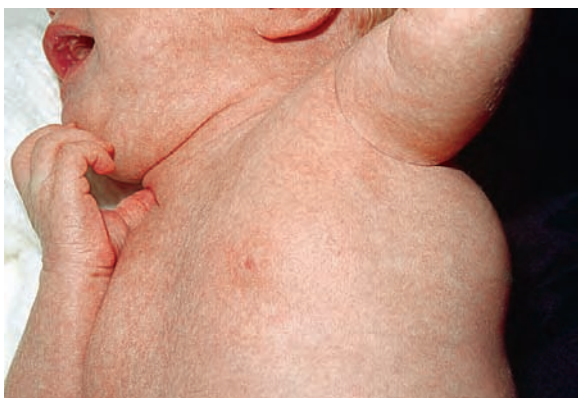- Clinical presentation
- Biopsy may be needed

### Differential diagnosis

- Lipoma
- Epidermal cyst
- Tumors

### Treatment

- Surgical removal of bulk of lesion is usually indicated; high rate of recurrence
- Sclerosing agents by interventional radiology



**Figure 16.27** Cystic hygroma – congenital deep swelling under arm

### Prognosis

- Static or slowly progressive
- Painful if traumatized

### References

- Gallagher PG, Mahoney MJ, Gosche JR. Cystic hygroma in the fetus and newborn. *Semin Perinatol* 1999; 23: 341–56
- Requena L, Sanguenza OP. Cutaneous vascular anomalies. Part I. Hamartomas, malformations, and dilatation of preexisting vessels. *J Am Acad Dermatol* 1997; 37: 523–49
- Weintraub AS, Holzman IR. Neonatal care of infants with head and neck anomalies. *Otolaryngol Clin North Am* 2000; 33: 1171–89

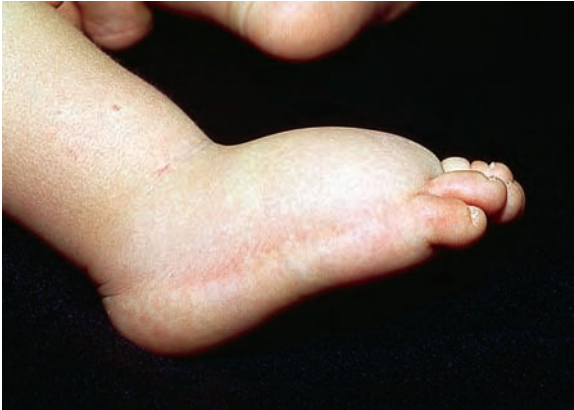## Lymphedema

### Major points

- Malformation or destruction of lymphatic channels and subsequent swelling of tissues
- Primary lymphedema
  1. Congenital lymphedema (Figure 16.28)
  2. Milroy disease: congenital, autosomal dominant
  3. Idiopathic
    - a. Lymphedema praecox appears between ages of 10 and 25 years
    - b. Lymphedema tardum (after age 35 years)
- Secondary lymphedema
  1. Infection
  2. Surgical destruction
  3. Malignant infiltration
  4. Fibrosis (radiation, stasis)
- Female/male ratio >1
- Swelling of limb or limbs is gradual and painless
- Swelling improves when feet are elevated overnight
- Soft, pitting edema of distal extremities

### Pathogenesis

- Malformation of lymphatic channels with aplasia, hypoplasia or varicosities of lymphatic channels
- Milroy disease: gene map locus 5q35.3; FLT4 gene, which encodes the vascular endothelial growth factor receptor-3
- Lymphedema praecox: gene map locus 16q24.3; forkhead family transcription factor gene MFH1 (FOXC2)



**Figure 16.28** Congenital lymphedema – swelling of the feet and legs

### Diagnosis

- Clinical presentation
- Lymphoscintigraphy with radioisotopic preparations can differentiate lymphedema from other causes of edema
- MRI of area involved
- Abdominal MRI may be needed to rule out extensive involvement or tumor
- Secondary causes should be ruled out

### Differential diagnosis

- Lipodystrophy
- Panniculitis
- Myxedema

### Treatment

- Minimize edema to prevent progression
- Prevent secondary complications (e.g. cellulitis) and further destruction of lymphatic channels
- Elastic garments (e.g. Jobst stockings) with pressures of >20 mmHg should be worn during the day
- Lymphedema pumps with sequential chambers

### Prognosis

- Progressive or stable
- In Turner syndrome, lymphedema can resolve

### References

Araujo JA, Curbelo JG, Mayol AL, et al. Effective management of marked lymphedema of the leg. *Int J Dermatol* 1997; 36: 389–92

Evans AL, Brice G, Sotirova V, et al. Mapping of primary congenital lymphedema to the 5q35.3 region. *Am J Hum Genet* 1999; 64: 547–55

Irrthum A, Karkkainen MJ, Devriendt K, et al. Congenital hereditary lymphedema caused by a mutation that inactivates VEGFR3 tyrosine kinase. *Am J Hum Genet* 2000; 67: 295–301

Makhoul IR, Sujov P, Ghanem N, Bronshtein M. Prenatal diagnosis of Milroy's primary congenital lymphedema. *Prenat Diagn* 2002; 22: 823–6

Veraart JCJM, Neumann HAM. Effects of medical elastic compression stockings on interface pressure and edema prevention. *Dermatol Surg* 1996; 22: 867–71

Wu JJ, Wagner AM. Verruciform xanthoma in association with Milroy disease and leaky capillary syndrome. *Pediatr Dermatol* 2003; 20: 44–7

## ACQUIRED LESIONS

### Pyogenic granuloma

#### Major points

- Common vascular tumor in childhood and pregnancy, accounting for 0.5% of pediatric nodules
- No racial or sex predilection
- A misnomer: neither bacterial (pyogenic) nor granulomatous in origin
- Commonly occurs between 1 and 4 years of age
- Location: face and neck most common but can occur anywhere
- Begins as small (5–8 mm) vascular papules
- Rapidly enlarges over several weeks to a dull red, dome-shaped, smooth, nontender papule (Figure 16.29)
- Usually solitary
- Rarely, multiple grouped satellite lesions develop around the original lesion
- Often pedunculated with a collarette of scale
- Surface becomes crusted and bleeds easily

#### Pathogenesis

- Etiology unknown
- Trauma may play a role
- May represent an inflammatory repair mechanism with granulation tissue and blood vessels



### Diagnosis

- Histology: hemangioma-like proliferation of capillaries with flattened epidermis and epidermal collarette

### Differential diagnosis

- Hemangioma of infancy
- Telangiectasia (spider angioma)
- Traumatized wart or molluscum
- Irritated melanocytic nevi
- Spitz nevus
- Amelanotic melanoma
- Eccrine poroma (on sole of the foot)
- Solitary glomus tumor
- Bacillary angiomatosis (seen in HIV-positive male patients)

### Treatment

- Shave excision with curettage and electrodesiccation or surgical excision
- Pulsed dye laser may be effective in small lesions, but may require multiple treatments

### Prognosis

- Small risk of recurrence after removal
- Untreated lesions tend to enlarge slowly, ulcerate and bleed

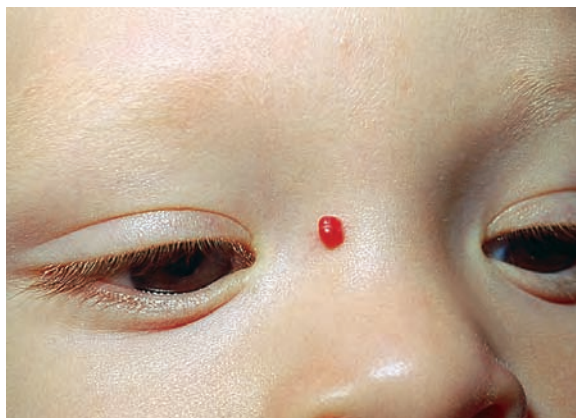### References

- Frieden I, Enjolras O, Esterly NB. Vascular Lesions. In Pediatric Dermatology, 3rd edn. Schachner LA, Hansen RC, eds. Churchill Livingstone: New York, 2003: 833–62
- Fleming AN, Smith PJ. Vascular cell tumors of the hand in children. *Hand Clin* 2000; 16: 609–24
- Morelli JG. Use of lasers in pediatric dermatology. *Dermatol Clin* 1998; 16: 489–95
- Pagliai KA, Cohen BA. Pyogenic granuloma in children. *Pediatr Dermatol* 2004; 21: 10–13

## Livedo reticularis

### Major points

- Mottled, reddish-blue macular discoloration of skin forming net-like pattern (Figure 16.30)
- Pattern is persistent, but darkens when environment is cold, and lightens when skin is warmed
- Idiopathic livedo reticularis



**Figure 16.29** Pyogenic granuloma – typical bleeding, friable, vascular papule

1. Most often seen in women
  2. Symmetrical diffuse mottling, usually on extremities
  3. Numbness and tingling common
  4. Painful ulceration uncommon
- Secondary causes:
    1. Intravascular obstruction
      - a. Hematologic stasis: paralysis, emboli, cryoglobulinemia, anticardiolipin antibody syndrome
      - b. Vessel wall disease: anticardiolipin antibody syndrome, polyarteritis nodosa, lupus erythematosus, dermatomyositis, syphilis, tuberculosis
      - c. Drugs: amantadine, quinine, quinidine

### Pathogenesis

- Thought to be due to slow venous drainage at margins of areas of skin richly supplied by arterial cones
- Increased viscosity and low flow rates in superficial venous plexus caused by cold
- Deoxygenation occurs and bluish pattern becomes more pronounced

### Diagnosis

- Clinical presentation
- Rule out causes

### Differential diagnosis

- Cutis marmorata (physiologic)
- Congenital abnormalities of blood vessels

- Congenital heart disease
- Cutis marmorata telangiectatica congenita
- Angioma serpiginosum
- Erythema ab igne

### *Treatment*

- Usually persistent despite treatment of underlying disorder
- Avoidance of cold

### *Prognosis*

- Persistent or progressive

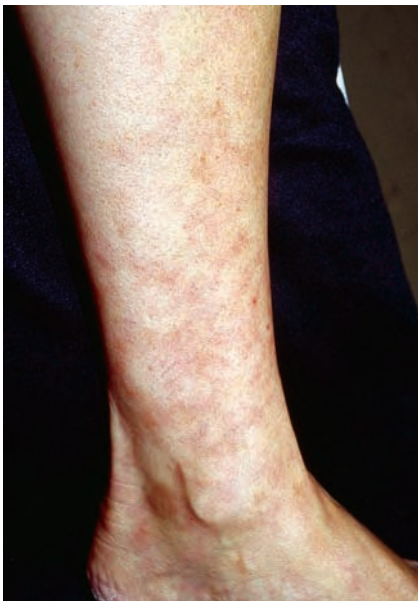### *References*

Abrahamian LM, Berke A, Van Voohees AS. Type 1 diabetes mellitus associated with livedo reticularis: case report and review of the literature. *Pediatr Dermatol* 1991; 8: 46–50

Asherson RA, Cervera R. Unusual manifestations of the antiphospholipid syndrome. *Clin Rev Allergy Immunol* 2003; 25: 61–78

Gibson GE, Su WP, Pittelkow MR. Antiphospholipid syndrome and the skin. *J Am Acad Dermatol* 1997; 36: 970–82

Quintero-Del-Rio AI. Antiphospholipid antibodies in pediatrics. *Curr Rheumatol Rep* 2002; 4: 387–91



**Figure 16.30** Livedo reticularis – reticulated vascular pattern associated with collagen vascular disease (anticardiolipin antibodies)

## **Spider angioma**

Synonyms: telangiectasia, nevus araneus

### *Major points*

- Most common type of telangiectasia in childhood
- Benign fixed pinpoint vascular punctum (0.5–4 mm) with radiating, tiny capillaries resembling legs of a spider
- Central vascular papule is a superficial arteriole which feeds into web of surrounding telangiectasias, occasionally pulsing
- Occurs either as single lesions or in crops
- Most common on sun-exposed areas, such as face and arms
- Occurs in 10–15% of normal adults and children
- More common in northern Europeans

### *Pathogenesis*

- Etiology unknown
- Genetic predisposition
- Sun or trauma may play a role
- Histology: ascending arteriole which ends in a thin-walled ampulla just beneath the epidermis with radiating arterial branches in the papillary dermis

### *Diagnosis*

- Clinical presentation
- Diascopy (pressure with a glass slide) results in disappearance of lesion

### *Differential diagnosis*

- Multiple telangiectasias

### *Treatment*

- Pulsed dye laser
- Light electrodesiccation of central feeder vessel
- Treatment does not prevent new lesions in other areas
- Recurrence rare

### *Prognosis*

- Natural history has not been well studied, but most lesions are persistent; some may spontaneously disappear

### *References*

Geronemus RG. Treatment of spider telangiectases in children using the flashlamp-pumped pulsed dye laser. *Pediatr Dermatol* 1991; 8: 61–3

Requena L, Sanguenza OP. Cutaneous vascular anomalies. Part I. Hamartomas, malformations, and dilatation of preexisting vessels. *J Am Acad Dermatol* 1997; 37: 523–49

## Telangiectasias

### Major points

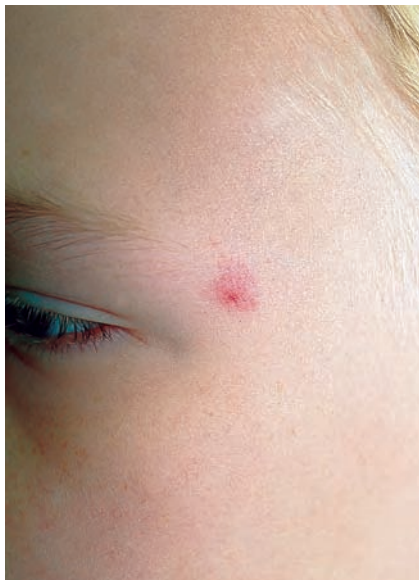- Abnormal permanent dilatation of venules and occasionally capillaries and arterioles of subpapillary plexus (Figure 16.31)
- Telangiectasias may be seen in:
  1. Collagen vascular diseases
  2. Mastocytosis
  3. Trauma
  4. Sun damage
  5. Radiodermatitis
  6. Poikiloderma
  7. Ataxia telangiectasia
  8. Essential or benign telangiectasias

### Pathogenesis

- Histology: capillaries are dilated within papillary dermis, affecting venous portion of capillary loop

### Diagnosis

- Clinical presentation
- Diascopy causes disappearance of lesion



**Figure 16.31** Typical spider angioma on the face

### Differential diagnosis

- Spider angioma

### Treatment

- Pulsed dye laser
- Light electrodesiccation of the central feeder vessels
- Treatment does not prevent new lesions in other areas
- Sunscreens may prevent new lesions

### Prognosis

- Persistent unless treated
- Recurrence is occasionally seen

### References

Abrahmian LM, Rothe MJ, Grant-Kels JM. Primary telangiectasia of childhood. *Int J Dermatol* 1992; 31: 307–13

Gold MH, Eramo L, Prendiville JS. Hereditary benign telangiectasia. *Pediatr Dermatol* 1989; 6: 194–7

Goldman MP, Bennett RG. Treatment of telangiectasia: a review. *J Am Acad Dermatol* 1987; 17: 167–82

Gonzalez E, Gange RW, Momtaz KT. Treatment of telangiectasias and other benign vascular lesions with the 577 nm pulsed dye laser. *J Am Acad Dermatol* 1992; 27: 220–6

Marchuk DA, Srinivasan S, Squire TL, Zawistowski JS. Vascular morphogenesis: tales of two syndromes. *Hum Mol Genet* 2003; 12: R97–112

## Generalized essential telangiectasias

### Major points

- More common in females in late teens to adults and made worse in pregnancy
- Rarely involve conjunctivae and oral mucosa
- No bleeding diathesis or associated internal disease (e.g. liver disease)

### Pathogenesis

- Etiology unknown
- Histology: dilated horizontal subpapillary venous plexus

### Diagnosis

- Clinical presentation

### Differential diagnosis

- Hereditary hemorrhagic telangiectasia
- Collagen vascular diseases

**Treatment**

- Pulsed dye or other vascular laser

**Prognosis**

- Persistent and can be progressive

**References**

Abrahmian LM, Rothe MJ, Grant-Kels JM. Primary telangiectasia of childhood. *Int J Dermatol* 1992; 31: 307–13

Gold MH, Eramo L, Prendiville JS. Hereditary benign telangiectasia. *Pediatr Dermatol* 1989; 6: 194–7

**Hereditary hemorrhagic telangiectasia**

Synonym: Osler–Weber–Rendu syndrome

**Major points**

- Characterized by telangiectases involving the skin, mucous membranes and internal organs (especially GI tract, lungs)
- Dark red, slightly elevated, central punctum with radiating vessels which can become matted with age
- In childhood, epistaxis from telangiectasias in nose
- Location most prominent on palms, soles, lips, tongue, palate, nasal mucous membranes and under nails
- GI involvement: bleeding is frequent and melena and anemia are common
- Lungs: arteriovenous fistulas or other venous malformations
- Other organs: kidney, spleen, bladder, liver, meninges and brain
- Autosomal dominant

**Pathogenesis**

- Histology: dilated thin-walled post-capillary venules, closely apposing overlying epidermis, lined by one layer of flattened endothelial cells

- Perivascular connective tissue is abnormal and is thought to be responsible for telangiectasias and hemorrhage
- Gene locus/gene: OWR1-9q34.1/ENG (endoglin); OWR2- 12q11-q14/ACVRL1 (activin A receptor-like kinase-1)

**Diagnosis**

- Clinical presentation
- Evaluation of GI tract and lungs

**Differential diagnosis**

- Essential telangiectasias

**Treatment**

- Pulsed dye laser or other vascular laser
- Electrocautery

**Prognosis**

- Slow progression of cutaneous, gastrointestinal and pulmonary lesions with bleeding, anemia
- Arteriovenous fistula in lungs can develop

**References**

Azuma H. Genetic and molecular pathogenesis of hereditary hemorrhagic telangiectasia. *J Med Invest* 2000; 47: 81–90

Begbie ME, Wallace GM, Shovlin CL. Hereditary haemorrhagic telangiectasia (Osler–Weber–Rendu syndrome): a view from the 21st century. *Postgrad Med J* 2003; 79: 18–24

Guttmacher AE, Marchuk DA, White RI. Hereditary hemorrhagic telangiectasia. *N Engl J Med* 1995; 333: 918–24

Peery WH. Clinical spectrum of hereditary hemorrhagic telangiectasia. *Am J Med* 1987; 82: 989–97

Swanson DL, Dahl MV. Embolic abscesses in hereditary hemorrhagic telangiectasia. *J Am Acad Dermatol* 1991; 24: 580–3

van den Driesche S, Mummery CL, Westermann CJ. Hereditary hemorrhagic telangiectasia: an update on transforming growth factor beta signaling in vasculogenesis and angiogenesis. *Cardiovasc Res* 2003; 58: 20–31



ashry

# TUMORS, CYSTS AND GROWTHS

## BLASCHKO LINES

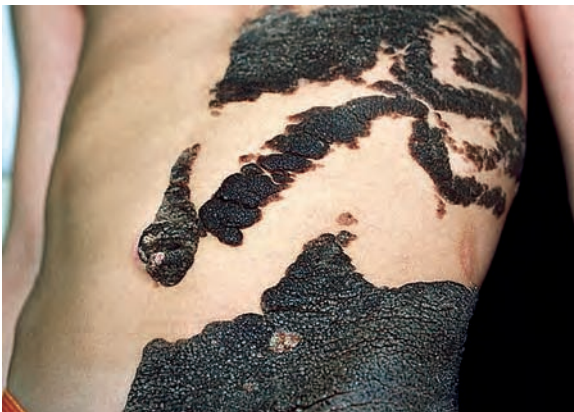See Chapter 14 for definition

Lesions that follow Blaschko lines (Table 17.1)

### Epidermal nevus

#### Major points

- Hamartoma of cutaneous elements
- No racial predilection
- Sporadic, with a few cases in families
- 60% present at birth; 95% present by age 7 years
- Types:
  1. Nevus verrucosus – most common type
    - a. Hyperpigmented, warty plaque measuring 2 to >10cm (Figure 17.1)
    - b. Usually solitary



**Figure 17.1** Epidermal nevus – on the body following Blaschko lines (published in An Illustrated Dictionary of Dermatologic Syndromes by SB Mallory and S Leal-Khoury)

**Table 17.1 Disorders which follow Blaschko lines/segmental disorders**

#### *Nevoid/hamartomas*

Epidermal nevus/ILVEN  
Nevus sebaceus  
Nevus comedonicus  
Porokeratotic eccrine ostial and dermal duct nevus  
Nevus lipomatosus  
CHILD syndrome

#### *Pigmented lesions*

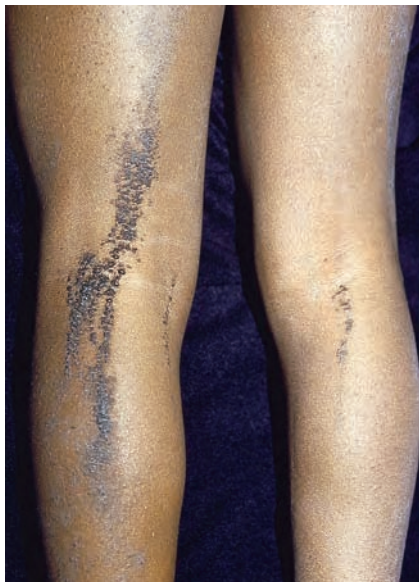Incontinentia pigmenti  
Hypomelanosis of Ito  
Nevus depigmentosus  
Linear and whorled nevoid hypermelanosis  
Segmental vitiligo  
Tuberous sclerosis with leukodermic macules  
Café au lait macules (McCune–Albright syndrome)  
Congenital nevus

#### *Vascular lesions*

Angiokeratoma circumscriptum  
Verrucous hemangioma  
Glomuvenous malformations  
Venous malformations  
Angioma serpiginosum  
Lymphangioma circumscriptum  
Unilateral nevoid telangiectasia

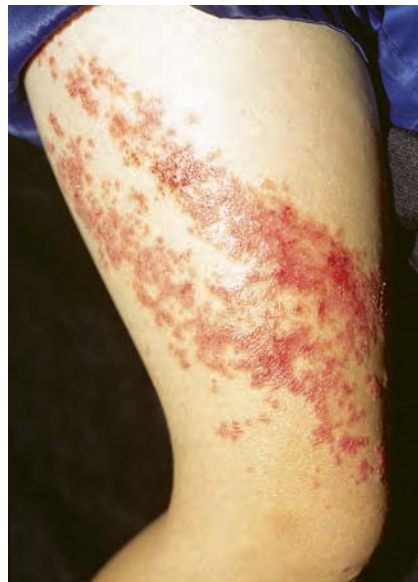#### *Other*

Lichen striatus  
Linear lichen planus  
Focal dermal hypoplasia (Goltz syndrome)  
Conradi–Hünemann syndrome (X-linked dominant)  
Menkes syndrome (female carriers)  
X-linked hypohidrotic ectodermal dysplasia (female carriers)  
Oral–facial–digital syndrome, type 1  
Linear porokeratosis  
Linear keratosis follicularis



**Figure 17.2** Epidermal nevus – on the legs following Blaschko lines

- c. Linear or oval in shape
- d. Most common on extremities, but can be anywhere
- e. Does not continue to grow after age 7 years except in proportion to the child
2. Nevus unius lateris (systematized epidermal nevus)
  - a. Extensive lesions which can be unilateral or bilateral (Figure 17.2)
  - b. Can continue to expand into adolescence, following Blaschko lines
  - c. Associated with underlying systemic deformities in 30% of patients (called 'epidermal nevus syndrome' with CNS, skeletal, cardiovascular, ocular abnormalities)
3. Ichthyosis hystrix
  - a. Extensive lesions following Blaschko lines
  - b. Histology: epidermolytic hyperkeratosis
4. Inflammatory linear verrucous epidermal nevus (ILVEN)
  - a. Erythematous scaly linear plaque/plaques (Figure 17.3)
  - b. Small or large
  - c. Intensely pruritic
  - d. Often in groin
  - e. More common in females (4:1)



**Figure 17.3** Inflammatory linear verrucous epidermal nevus – scaly, erythematous streaks following Blaschko lines on the leg

### Pathogenesis

- Mosaicism arising from somatic mutations early in embryogenesis. Two distinct cell lines result and migrate along developmental lines (Blaschko lines) producing patchy and linear abnormalities
- If epidermal nevus has histology of epidermolytic hyperkeratosis and if the gonads are involved in the somatic mutation, offspring may be affected with widespread epidermolytic hyperkeratosis

### Diagnosis

- Histology:
  1. Papillomatous hyperplasia of the epidermis with or without epidermolytic hyperkeratosis
  2. Inflammation in the dermis may be seen in the inflammatory types

### Differential diagnosis

- Nevus verrucosus
  1. Nevus sebaceus
  2. Seborrheic keratosis
  3. Verrucae
- Inflammatory linear verrucous epidermal nevus
  1. Psoriasis
  2. Linear lichen planus
  3. Lichen simplex chronicus
  4. Darier disease

### Treatment

- Solitary epidermal nevi usually require no treatment
- Surgery must include upper levels of dermis in order to prevent recurrences
- Other techniques which may be effective for removal: CO<sub>2</sub> laser, dermabrasion, chemical peels, liquid nitrogen
- Pruritus in ILVEN may be improved with potent topical or intralesional steroids, pulsed dye laser or short contact dithranol

### Prognosis

- Lesions persist unless fully removed

### References

- Alam, M, Arndt KA. A method for pulsed carbon dioxide laser treatment of epidermal nevi. *J Am Acad Dermatol* 2002; 46: 554–6
- Boyce S, Alster TS. CO<sub>2</sub> laser treatment of epidermal nevi: long-term success. *Dermatol Surg* 2002; 28: 611–14
- Grebe TA, Rimsza ME, Richter SF, et al. Further delineation of the epidermal nevus syndrome: two cases with new findings and literature review. *Am J Med Genetics* 1993; 47: 24–30
- Happle R, Rogers M. Epidermal nevi. *Adv Dermatol* 2002; 18: 175–201
- Ivker R, Resnick SD, Skidmore RA. Hypophosphatemic vitamin D-resistant rickets, precocious puberty, and the epidermal nevus syndrome. *Arch Dermatol* 1997; 133: 1557–61
- Paller AS, Syder AJ, Chan Y-M, et al. Genetic and clinical mosaicism in a type of epidermal nevus. *N Engl J Med* 1994; 331: 1408–15
- Prayson RA, Kotagal P, Wyllie E, Bingaman W. Linear epidermal nevus and nevus sebaceus syndrome. *Arch Pathol Lab Med* 1999; 123: 301–5
- Rogers M, McCrossin I, Commens C. Epidermal nevi and the epidermal nevus syndrome. *J Am Acad Dermatol* 1989; 20: 476–88

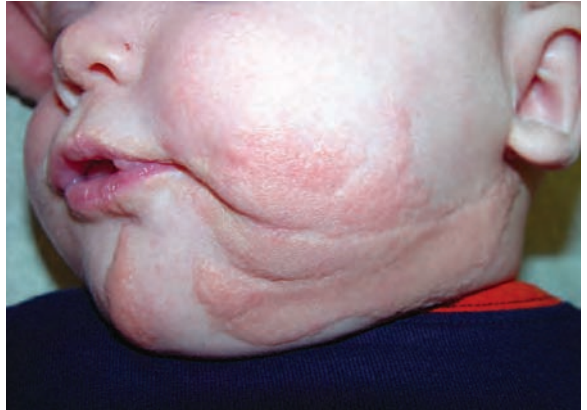### Nevus sebaceus

Synonym: nevus sebaceus of Jadassohn, organoid nevus

### Major points

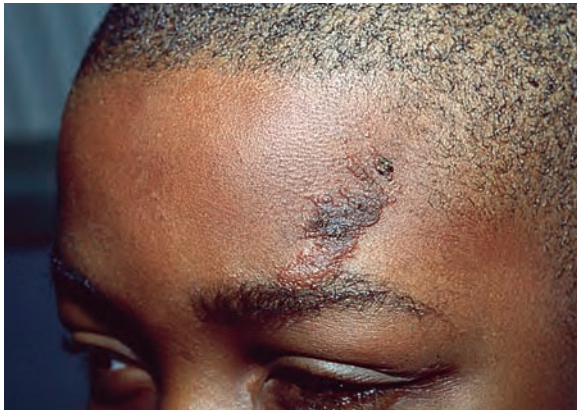- Congenital hamartoma of skin and adnexae, predominantly sebaceous glands, abortive hair follicles and ectopic apocrine glands

- Sporadic in occurrence; familial cases have been reported
- No racial or sexual predilection
- Incidence 0.3% of the population
- Solitary oval or linear hairless plaque on the scalp, head or neck (Figure 17.4)



**Figure 17.4** Nevus sebaceus – extensive, yellowish plaque on the face following Blaschko lines

- Surface smooth, velvety or wart-like with a yellowish color
- Size ranges from 0.5 to >6 cm; can be extensive
- In childhood, the lesions flatten and become less apparent; thought to be caused by the reduction of maternal hormones and sebaceous glands
- At puberty, most plaques thicken and become verrucous (Figure 17.5)
- Development of hamartomatous tumors within the lesion usually after puberty
  1. Tumors: syringocystadenoma papilliferum, trichoblastoma, hidradenoma, basal cell carcinoma, others
  2. Malignant tumors such as squamous cell carcinoma, apocrine carcinoma and other adnexal carcinomas are rare before age 40 years
  3. Detected by development of a papule with ulceration within the lesion
- Extensive lesions may be associated with multiple systemic manifestations in the nevus sebaceus syndrome (Schimmelpenning syndrome): seizures, mental retardation, arteriovenous malformations of the brain, skeletal abnormalities, ophthalmologic abnormalities



**Figure 17.5** Nevus sebaceus – verrucous plaque on the forehead of an 11-year-old

### *Pathogenesis*

- Complex hamartoma of pilosebaceous follicles, epidermis and adnexal structures that are under hormonal control

### *Diagnosis*

- Histology:
  1. Early: small underdeveloped sebaceous glands and hair follicles
  2. Childhood: small, immature ectopic appendageal structures
  3. Puberty: hyperplasia and maturation of the sebaceous glands. Hair follicles remain rudimentary; fully developed apocrine glands occur

### *Differential diagnosis*

- Epidermal nevus
- Aplasia cutis
- Congenital triangular alopecia
- Cutaneous infection (e.g. staphylococcal, streptococcal, herpes simplex)

### *Treatment*

- Full-thickness surgical excision around the time of puberty is recommended
- If excision will result in a worse cosmetic defect, then observation may be reasonable
- CO<sub>2</sub> laser is a second choice for destruction of the lesion in a difficult area; however, recurrences may occur

### *Prognosis*

- Lesions persist throughout life
- Potential in adulthood to develop nodules or skin tumors

### *References*

- Cribier B, Scrivener Y, Grosshans E. Tumors arising in nevus sebaceus: a study of 596 cases. *J Am Acad Dermatol* 2000; 42: 263–8
- LeSueur BW, Silvis NG, Hansen RC. Basal cell carcinoma in children: report of 3 cases. *Arch Dermatol* 2000; 136: 370–2
- Oranje AP, Przyrembel H, Meradji M, et al. Solomon's epidermal nevus syndrome (type: linear nevus sebaceus) and hypophosphatemic vitamin D-resistant rickets. *Arch Dermatol* 1994; 130: 1167–71
- Rogers M, McCrossin I, Commens C. Epidermal nevi and the epidermal nevus syndrome. *J Am Acad Dermatol* 1989; 20: 476–88
- Santibanez-Gallerani A, Marshall D, Duarte AM, et al. Should nevus sebaceus of Jadassohn in children be excised? A study of 757 cases, and literature review. *J Craniofac Surg* 2003; 14: 658–60
- Turner CD, Shea CR, Rosoff PM. Basal cell carcinoma originating from a nevus sebaceus on the scalp of a 7-year-old boy. *J Pediatr Hematol Oncol* 2001; 23: 247–9

## **Nevus comedonicus**

### *Major points*

- Presents at birth or early childhood
- Dilated follicular orifices on top of papules, closely set and usually linear (Figure 17.6)
- Site: face, neck, upper arms and chest
- Usually solitary
- If systematized (rare), developmental defects of the CNS, eyes, bone and skin can be associated
- Usually asymptomatic, but individual papules and cysts within plaques may become inflamed, resembling acne vulgaris

### *Pathogenesis*

- Considered to be a variant of epidermal nevus, a hamartoma of abnormal hair follicle infundibula

### *Diagnosis*

- Clinical diagnosis
- Histology: multiple dilated follicles filled with keratinous plugs



### Differential diagnosis

- Acne vulgaris
- Nevus sebaceus

### Treatment

- Topical retinoids
- Keratolytic agents: 12% ammonium lactate lotion (LacHydrin), tretinoin
- Surgical excision

### Prognosis

- Persistent

### References

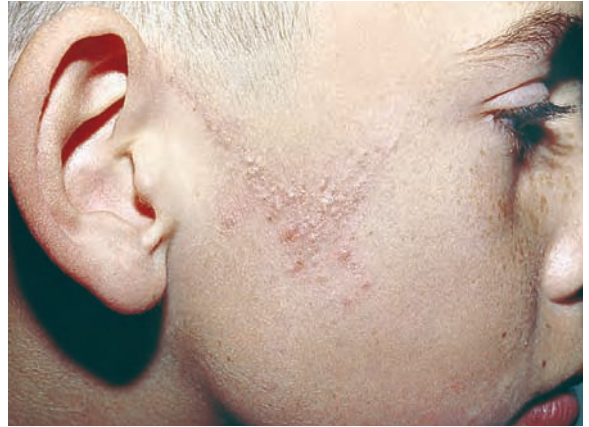- Beck MH, Dave VK. Extensive nevus comedonicus. Arch Dermatol 1980; 116: 1048–50
- Cestari TF, Rubim M, Valentini BC. Nevus comedonicus: case report and brief review of the literature. Pediatr Dermatol 1991; 8: 300–5
- Patrizi A, Neri I, Fiorentini C, Marzaduri S. Nevus comedonicus syndrome: a new pediatric case. Pediatr Dermatol 1998; 15: 304–6
- Seo YJ, Piao YJ, Suhr KB, et al. A case of nevus comedonicus syndrome associated with neurologic and skeletal abnormalities. Int J Dermatol 2001; 40: 648–50
- Vasiloudes PE, Morelli JG, Weston WL. Inflammatory nevus comedonicus in children. J Am Acad Dermatol 1998; 38: 834–6

## CYSTS

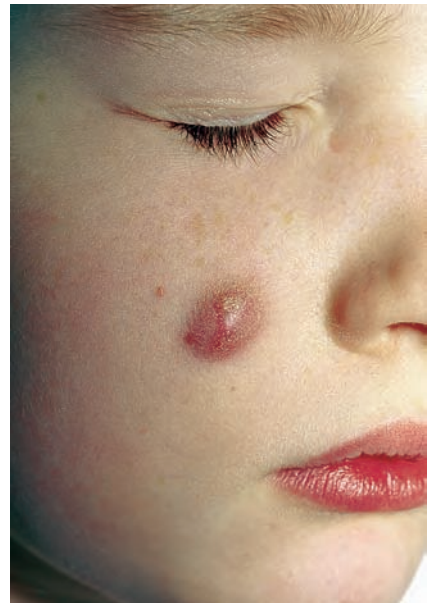
### Epidermal cyst

#### Major points

- Slow-growing, firm, ballotable round dermal nodule (Figure 17.7)
- Range in size from 0.5 to 15 cm
- Neonates:
  1. Can be seen anywhere
  2. If present in the midline (face, nose) and associated with pits or cysts, may indicate intracranial connection
- Adolescents:
  1. Solitary cysts with acne vulgaris
  2. Multiple cysts in childhood or adolescents might suggest Gardner syndrome
- Ruptured epidermal cysts become markedly inflamed; caused by keratin inciting a foreign body reaction



**Figure 17.6** Nevus comedonicus – note the inflamed open and closed comedones



**Figure 17.7** Epidermal cyst – inflamed tender ruptured cyst on the cheek

### Pathogenesis

- Epidermal cysts result from the proliferation of surface epidermal cells within the dermis producing keratin. They arise from cells of the follicular infundibulum, or from implantation of epidermal cells into the dermis through trauma, or from trapping of epidermal cells along embryonal fusion planes

### Diagnosis

- Easy to diagnose if there is a central punctum from which keratinous material can be expressed
- Clinically difficult to distinguish between epidermal and dermoid cysts without a biopsy

### Differential diagnosis

See Table 17.2

### Treatment

- Surgical excision with removal of the entire cyst wall

### Prognosis

- Cysts persist and slowly enlarge over time
- If traumatized, the cyst wall can break, extruding keratinous material into the surrounding dermis, causing marked inflammation

### References

- Knight PJ, Reiner CB. Superficial lumps in children. *Pediatrics* 1983; 72: 147–53
- Pariser RJ. Benign neoplasms of the skin. *Med Clin North Am* 1998; 82: 1285–307

**Table 17.2 Benign skin papules, nodules and cysts in infants and children**

Epidermal cyst  
 Dermoid cyst  
 Pilomatrixoma  
 Nasal glioma  
 Encephalocele  
 Branchial cleft cyst  
 Milia  
 Eruptive vellus hair cysts  
 Fibroma  
 Neurofibroma  
 Lipoma  
 Panniculitis  
 Juvenile xanthogranuloma  
 Mastocytoma  
 Lymphangioma  
 Granuloma annulare  
 Syringoma  
 Trichoepithelioma  
 Dermatofibroma  
 Keloid  
 Calcinosis cutis  
 Osteoma cutis  
 Foreign body granuloma

Vasiloudes PE, Morelli JG, Weston WL. Plantar epidermal cysts in children. *Arch Dermatol* 1997; 133: 1465

Zuber TJ. Minimal excision technique for epidermoid (sebaceous) cysts. *Am Fam Physician* 2002; 65: 1409–12, 1417–18, 1420

## Milia

### Major points

- A milium (plural, milia) is a 1–2 mm superficial white globoid papule within the epidermis or upper dermis
- Consists of a tiny ball of keratin with a thin cyst wall
- Common on the face of newborns, and within scars (especially in epidermolysis bullosa)
- Milia on the palate of newborns called Epstein pearls

### Pathogenesis

- Etiology unknown
- Milia are thought to be derived from pilosebaceous follicles

### Diagnosis

- Clinical diagnosis
- Histology: identical to an epidermal cyst, differing only in size

### Differential diagnosis

- Molluscum contagiosum
- Keratosis pilaris

### Treatment

- Lesions can be easily expressed with a comedone extractor after incision with a surgical blade or needle

### Prognosis

- Superficial milia can spontaneously extrude; deeper ones may be persistent

### References

- Bridges AG, Lucky AW, Haney G, Mutasim DF. Milia en plaque of the eyelids in childhood: case report and review of the literature. *Pediatr Dermatol* 1998; 15: 282–4
- Cairns ML, Knable AL. Multiple eruptive milia in a 15-year-old boy. *Pediatr Dermatol* 1999; 16: 108–10

Girardi M, Federman GL, McNiff JM. Familial multiple basaloid follicular hamartomas: a report of two affected sisters. *Pediatr Dermatol* 1999; 16: 281–4

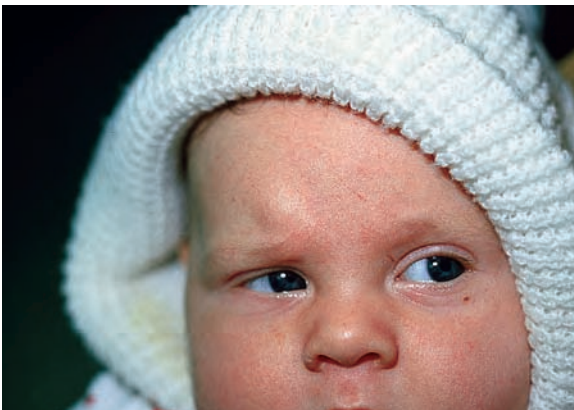Langley RGB, Walsh NMG, Ross JB. Multiple eruptive milia: report of a case, review of the literature, and a classification. *J Am Acad Dermatol* 1997; 37: 353–6

Stefanidou MP, Panayotides JG, Tosca AD. Milia en plaque: a case report and review of the literature. *Dermatol Surg* 2002; 28: 291–5

## Dermoid cyst

### Major points

- Manifest at birth (40%) or before age 5 years (70%)
- Solitary, soft round subcutaneous cyst which is freely moveable within the dermis (Figure 17.8)
- Sinus opening or hairs may be associated
- Size usually 1–4 cm
- Location usually on the forehead, most common in the lateral third of the eyebrow or midline nasal bridge. Also seen on the anterior or lateral neck, sternum, scrotum, perineal raphe and sacral areas
- In the periorbital area, may cause proptosis or eyelid displacement
- Most dermoid cysts are superficial, but up to 45% may have intracranial connections to extradural or intradural compartments often indicated by a sinus pit
- Usually asymptomatic; rarely recurrent infections with cellulitis or abscess; pressure erosion of the bone may occur



**Figure 17.8** Dermoid cyst – above the eyebrow of an infant

### Pathogenesis

- Caused by the sequestration of epithelium along the planes of closure of embryonic clefts

### Diagnosis

- Biopsy should not be performed unless it is certain there is no intracranial connection
- Histology: an encapsulated cyst with a wall composed of keratinizing, stratified squamous epithelium with hair follicles, sebaceous glands, eccrine and apocrine glands; within the cyst are lipids, keratin and hair

### Differential diagnosis

See Table 17.2

### Treatment

- Simple excision
- Midline lesions of the face should be evaluated with an MRI looking for intracranial connections
- Surgery by a pediatric neurosurgeon is essential for lesions with intracranial connections in order to avoid ascending infection
- Dermoid cysts located along the lateral eyebrows rarely have intracranial connections and do not require MRI

### Prognosis

- Excellent if completely excised

### References

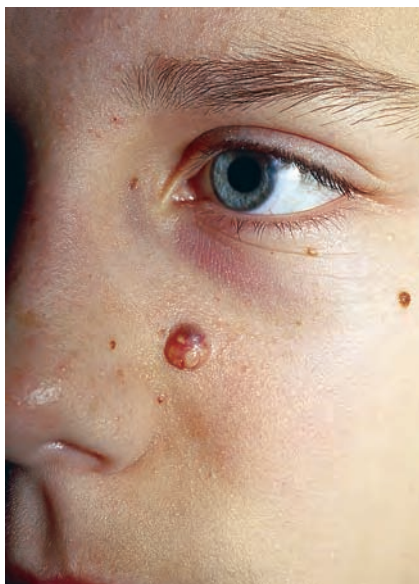- Ackerman LL, Menezes AH, Follett KA. Cervical and thoracic dermal sinus tracts. A case series and review of the literature. *Pediatr Neurosurg* 2002; 37: 137–47
- Brownstein MH, Helwig EB. Subcutaneous dermoid cysts. *Arch Dermatol* 1973; 107: 237–9
- Drolet BA. Cutaneous signs of neural tube dysraphism. *PediatrClin North Am* 2000; 47: 813–23
- Paller AS, Pensler JM, Tomita T. Nasal midline masses in infants and children. *Arch Dermatol* 1991; 127: 362–6

## Pilomatrixoma

Synonym: calcifying epithelioma of Malherbe

### Major points

- Firm, freely movable slowly growing papule/nodule usually <1 cm (can be up to 5 cm) (Figure 17.9)



**Figure 17.9** Pilomatrixoma – enlarging hard cyst on the cheek

- Overlying skin may have a bluish hue
- Usually solitary; multiple lesions have been reported
- Location: common on the face of a child but can be seen anywhere
- May feel rock-hard
- Slight female predominance
- No racial predilection
- Sporadic; familial cases reported
- If cyst ruptures to the surface, it may drain chalky calcium-containing material
- If ruptured under the skin, it may be very inflamed and painful

#### *Pathogenesis*

- Benign hyperplasia of the cells of hair matrix
- Cyst composed of elements of normal hair cortex
- Characteristic calcium phosphate deposition within the cyst
- Not usually associated with underlying disease

#### *Diagnosis*

- Histology: two populations of cells: irregular islands of basophilic cells at the periphery, and pale shadow cells containing no nuclei
  1. Within cyst: keratin, foreign body reaction, calcification and sometimes ossification

2. Cyst is irregular in shape, with connective tissue capsule

#### *Differential diagnosis*

See Table 17.2

#### *Treatment*

- Surgical excision

#### *Prognosis*

- Persistent
- Natural history: slow enlargement over months

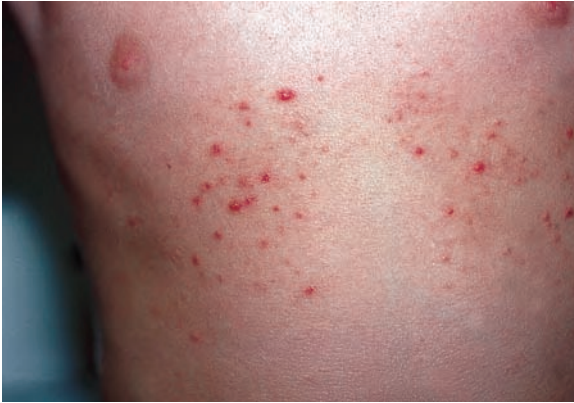#### *References*

- Ahmad M, Khan IU, Khan AH, et al. Pilomatrixoma: a retrospective study. *Int J Dermatol* 1992; 31: 703–5
- Cambiaghi S, Ermacora E, Brusasco A, et al. Multiple pilomatrixomas in Rubinstein–Taybi syndrome: a case report. *Pediatr Dermatol* 1994; 11: 21–5
- Demircan M, Balik E. Pilomatrixoma in children: a prospective study. *Pediatr Dermatol* 1997; 14: 430–2
- Julian CG, Bowers PW. A clinical review of 209 pilomatrixomas. *J Am Acad Dermatol* 1998; 39: 191–5
- Kopeloff I, Orlow SJ, Sanchez MR. Multiple pilomatrixomas: report of two cases and review of the association with myotonic dystrophy. *Cutis* 1992; 50: 290–2
- Mencia-Gutierrez E, Gutierrez-Diaz E, Garcia-Suarez E, Ricoy JR. Eyelid pilomatrixomas in young adults: a report of 8 cases. *Cutis* 2002; 69: 23–6
- Yencha MW. Head and neck pilomatrixoma in the pediatric age group: a retrospective study and literature review. *Int J Pediatr Otorhinolaryngol* 2001; 57: 123–8

### **Eruptive vellus hair cysts**

#### *Major points*

- Multiple small, discrete, soft 1–4 mm skin-colored or hyperpigmented papules (Figure 17.10)
- Location: lower chest and upper abdomen in a follicular pattern is typical; other areas can be involved
- Occasional umbilication
- Asymptomatic
- Ages usually 4–18 years
- No systemic associations
- No sexual or racial predilection
- Autosomal dominant and familial cases have been reported



**Figure 17.10** Eruptive vellus hair cysts – typical mid-chest follicular papules resembling comedones

### *Pathogenesis*

- Defect in the development of vellus hair follicles which predispose to follicular occlusion at the infundibular level
- Relation to steatocystoma multiplex has been suggested, because the cyst wall can contain sebaceous glands

### *Diagnosis*

- Clinical diagnosis
- Biopsy may be necessary to confirm the diagnosis
- Histology: small mid-dermal cysts lined by squamous epithelium; cysts contain lamellar keratin and tiny nonpigmented vellus hair shafts

### *Differential diagnosis*

- Epidermoid cysts
- Syringomas
- Steatocystoma multiplex
- Acne
- Viral exanthems
- Molluscum contagiosum

### *Treatment*

- Topical keratolytics (e.g. lactic acid, tretinoin cream) may hasten resolution
- Excision or other destructive measures may be needed for larger lesions

### *Prognosis*

- Lesions may spontaneously resolve over months to years
- New lesions can continue to form

## *References*

- Mahendran R, Pollock B, Clark S. Multiple asymptomatic papules in a child. *Pediatr Dermatol* 2003; 20: 451–2
- Ohtake N, Kubota Y, Takayama O, et al. Relationship between steatocystoma multiplex and eruptive vellus hair cysts. *J Am Acad Dermatol* 1992; 26: 876–8
- Reep MD, Robson KJ. Eruptive vellus hair cysts presenting as multiple periorbital papules in a 13 year old boy. *Pediatr Dermatol* 2002; 19: 26–7

## **FAT**

### **Lipoma**

#### *Major points*

- Common, benign, asymptomatic, well-demarcated nodule with a doughy consistency
- Size: 1 cm to >15 cm
- If a lesion compresses a nerve, it may be painful
- Location often on neck and trunk but can be anywhere
- Usually solitary but may be multiple

#### *Pathogenesis*

- Benign mesenchymal tumor of unknown etiology

#### *Diagnosis*

- Histology: well-circumscribed sheets of mature, uniform adipocytes with thin strands of fibrous tissue intersecting the sheets of adipocytes

#### *Differential diagnosis*

See Table 17.2

#### *Treatment*

- Surgical excision if indicated

#### *Prognosis*

- Most lipomas are asymptomatic and stable
- Trauma or ischemia can cause necrosis of lipomas with pain, and later dystrophic calcification

## *References*

- McAtee-Smith J, Hebert AA, Rapini RP, Goldberg NS. Skin lesions of the spinal axis and spinal dysraphism. *Arch Pediatr Adolesc Med* 1994; 148: 740–8
- Salam GA. Lipoma excision. *Am Fam Physician* 2002; 65: 901–4



Sanchez MR, Colomb FM, Moy JA, Petožkin JR. Giant lipoma: case report and review of the literature. *J Am Acad Dermatol* 1993; 28: 266–8

Trapp CF, Baker EJ. Mobile encapsulated lipomas. *Cutis* 1992; 49: 63–4

Zvijac JE, Sheldon DA, Schurhoff MR. Extensive lipoma causing suprascapular nerve entrapment. *Am J Orthop* 2003; 32: 141–3

## Nevus lipomatosus

### Major points

- Presents at birth or childhood
- Multiloculated yellowish or skin-colored plaque of rubbery papules and nodules
- Location usually in lumbosacral area or thighs but may be anywhere
- Size usually several centimeters or larger
- Asymptomatic
- No underlying associations

### Pathogenesis

- Rare, benign hamartoma of mature fat cells

### Dagnosis

- Histology: mature, polypoid fat with the appearance of an acrochordon (skin tag)

### Differential diagnosis

- Goltz syndrome (focal dermal hypoplasia)
- Encephalocraniocutaneous lipomatosis

### Treatment

- None usually needed
- Surgical excision
- Liposuction

### Prognosis

- Benign with no malignant potential

### References

Bergonse FN, Cymbalista NC, Nico MM, et al. Giant nevus lipomatosus cutaneus superficialis: case report and review of the literature. *J Dermatol* 2000; 27: 16–19

Inoue M, Ueda K, Hashimoto T. Nevus lipomatosus cutaneus superficialis with follicular papules and hypertrophic pilo-sebaceous units. *Int J Dermatol* 2002; 41: 241–3

Knuttel R, Silver EA. A cerebriiform mass on the right buttock. *Dermatol Surg* 2003; 29: 780–1

Lane JE, Clark E, Marzec T. Nevus lipomatosus cutaneus superficialis. *Pediatr Dermatol* 2003; 20: 313–14

## Anetoderma

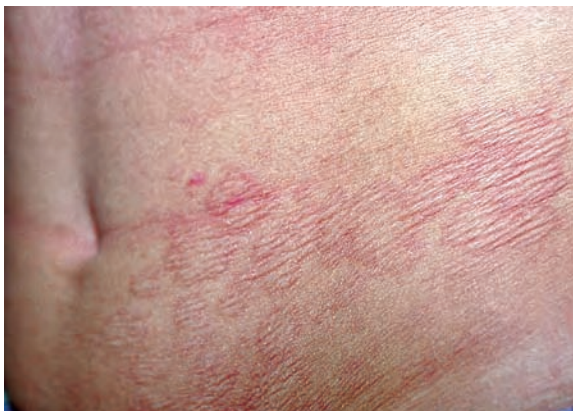Synonym: macular atrophy

### Major points

- Multiple oval depressions or slightly bulging papules with wrinkled surface (Figure 17.11)
- Herniates inward with fingertip pressure
- Location: mainly upper trunk and upper arms, but can be anywhere
- May or may not be preceded by inflammation
- Secondary anetoderma may develop after certain cutaneous processes such as syphilis, leprosy, lupus and others

### Pathogenesis

- Results from increased degradation or reduced synthesis of elastic tissue
- Histology:
  1. Perivascular infiltrate of lymphocytes (predominantly helper T cells)
  2. Scattered macrophages, giant cells with some elastophagocytosis
  3. In established lesion, elastic fibers are sparse in superficial dermis and almost completely absent in mid-dermis



**Figure 17.11** Anetoderma – note wrinkly skin overlying slightly raised plaques

### Diagnosis

- Clinical diagnosis

### Differential diagnosis

- Connective tissue nevus
- Nevus lipomatosis

### Treatment

- None known to help

### Prognosis

- Stable or may increase in number

### References

- Colditz PB, Dunster KR, Joy GJ, et al. Anetoderma of prematurity in association with electrocardiographic electrodes. *J Am Acad Dermatol* 1999; 41: 479–81
- Ghomrasseni S, Dridi M, Gogly B, et al. Anetoderma: an altered balance between metalloproteinases and tissue inhibitors of metalloproteinases. *Am J Dermatopathol* 2002; 24: 118–29
- Karrer S, Szeimies R-M, Stolz W, Landthaler M. Primary anetoderma in children: report of two cases and literature review. *Pediatr Dermatol* 1996; 13: 382–5
- Prizant TL, Lucky AW, Frieden IJ, et al. Spontaneous atrophic patches in extremely premature infants. *Arch Dermatol* 1996; 132: 671–4
- Sparsa A, Piette JC, Wechsler B, et al. Anetoderma and its prothrombotic abnormalities. *J Am Acad Dermatol* 2003; 49: 1008–12
- Thomas JE, Mehregan DR, Holland J, Mehregan DA. Familial anetoderma. *Int J Dermatol* 2003; 42: 75–7

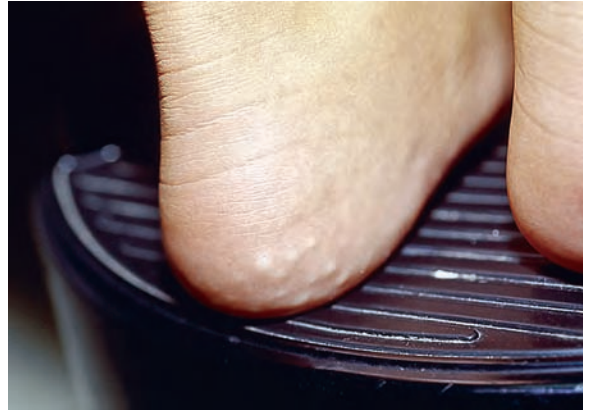## Piezogenic pedal papules

### Major points

- Common entity found in 10–20% of the general population
- More common in women
- Asymptomatic skin-colored papules seen along the sides of the plantar surface only when weight-bearing (Figure 17.12)
- Occasionally painful
- Often seen in runners

### Pathogenesis

- Caused by herniations of subcutaneous fat into the dermis on the sides of the feet caused by weight bearing



**Figure 17.12** Piezogenic pedal papules – herniations of fat which are more pronounced when standing

- Histology: thickened dermis, loss of normal small fat compartments in the lower dermis and subcutis with many protrusions of enlarged fat lobules into the dermis caused by degeneration of the thin fibrous septa

### Diagnosis

- Clinical diagnosis

### Differential diagnosis

- Lipomas
- Connective tissue nevus
- Plexiform neurofibroma

### Treatment

- Special orthotic heel cups for severely painful lesions

### Prognosis

- Usually stable unless there is chronic stress on the feet, in which case it may progress

### References

- Boni R, Dummer R. Compression therapy in painful piezogenic pedal papules. *Arch Dermatol* 1996; 132: 127–8
- Van Straaten EA, Van Langen IM, Oorthuys JWE, Oosting J. Piezogenic papules of the feet in healthy children and their possible relation with connective tissue disorders. *Pediatr Dermatol* 1991; 8: 277–9
- Woodrow SL, Brereton-Smith G, Handfield-Jones S. Painful piezogenic pedal papules: response to local electroacupuncture. *Br J Dermatol* 1997; 136: 628–30

## Panniculitis

### Major points

- Panniculitis is a term used to describe a group of diseases with inflammation in the subcutaneous fat (see Table 17.3)
- Presents with erythematous or violaceous, painful, subcutaneous nodules (Figures 17.13 and 17.14)
- Size usually 1–4 cm
- Common location: lower legs, symmetrical, but nodules may be anywhere
- Usually do not ulcerate
- Recurrent crops
- Lesions involute over a few weeks, and erythema is replaced with hyperpigmentation
- Erythema nodosum – most common type of panniculitis (see Table 17.4)

### Pathogenesis

- Inflammation of fat; etiology depends upon type of panniculitis

### Diagnosis

- Histology: degeneration and necrosis of lipocytes with an infiltrate of polymorphonuclear leukocytes and lymphocytes within the lobules of fat or in the septae

### Differential diagnosis

- Epidermal cyst (ruptured)
- Cellulitis

### Treatment

- Bed rest if lesions occur on legs
- Withdrawal of offending agent (e.g. drugs)
- Nonsteroidal anti-inflammatory agents
- Oral steroids may be indicated, particularly in cases of vasculitis

### Prognosis

- Course variable, depending upon the type of panniculitis
- May spontaneously resolve or persist with new lesions occurring in crops

### References

Aronson IK, Zeitz HJ, Variakojis D. Panniculitis in childhood. *Pediatr Dermatol* 1988; 5: 216–30

**Table 17.3** Types of panniculitis

#### **Neonatal panniculitis**

Sclerema neonatorum  
Subcutaneous fat necrosis of the neonate

#### **Physical panniculitis**

Cold-induced (popsicle panniculitis)  
Traumatic  
Chemical-induced  
Factitial  
Post-steroid injection

#### **Systemic diseases with panniculitis**

Systemic lupus erythematosus  
Pancreatitis  
Sarcoidosis  
Renal failure  
Lymphoma  
Leukemia  
Infections  
 $\alpha_1$ -antitrypsin deficiency

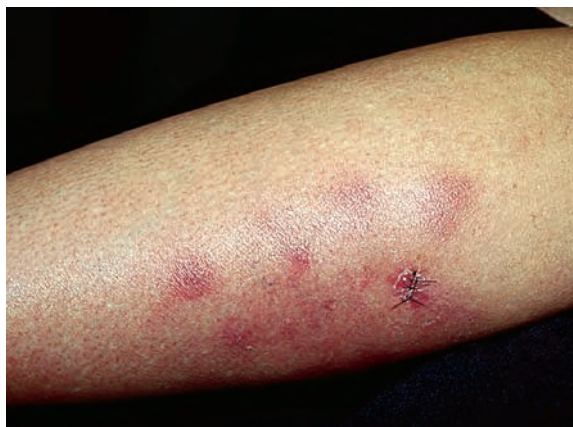#### **Vasculitis**

Nodular vasculitis  
Polyarteritis nodosa  
Cutaneous polyarteritis nodosa  
Superficial migratory thrombophlebitis

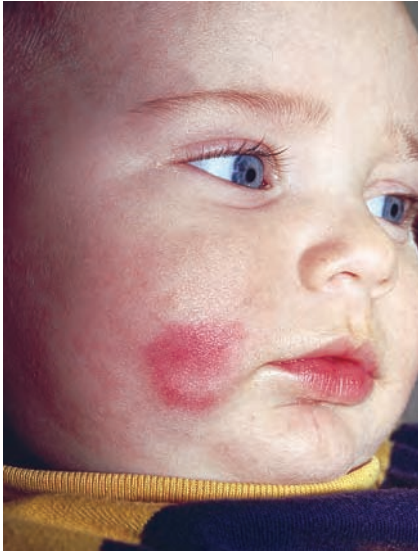#### **Septal panniculitis without vasculitis**

Erythema nodosum  
Scleroderma panniculitis  
Eosinophilic fasciitis  
Eosinophilic myalgia syndrome

#### **Idiopathic lobular panniculitis (Weber–Christian disease)**



**Figure 17.13** Panniculitis associated with Crohn disease



**Figure 17.14** Popsicle panniculitis – caused by sucking on a cold popsicle

Eberhard BA, Ilowite NT. Panniculitis and lipodystrophy. *Curr Opin Rheumatol* 2002; 14: 566–70

McBean J, Sable A, Maude J, Robinson-Bostom L. Alpha1-antitrypsin deficiency panniculitis. *Cutis* 2003; 71: 205–9

Ruiz-Maldonado R, Parrilla FM, Luz Orozco-Covarrubias M, et al. Edematous, scarring vasculitic panniculitis: a new multisystemic disease with malignant potential. *J Am Acad Dermatol* 1995; 32: 37–44

Sutra-Loubet C, Carlotti A, Guillemette J, Wallach D. Neutrophilic panniculitis. *J Am Acad Dermatol* 2004; 50: 280–5

**Table 17.4** Major etiologies of erythema nodosum

**Drug-induced**

Sulfonamides  
Bromides  
Oral contraceptives

**Bacterial infections**

Streptococcal infections  
*Yersinia enterocolitica*  
*Mycoplasma pneumoniae*  
Leprosy  
Leptospirosis  
Tularemia  
*Bartonella henselae* (cat scratch disease)

**Fungal infections**

Coccidioidomycosis  
Blastomycosis  
Histoplasmosis  
Dermatophytosis

**Viral infections/other infections**

Paravaccinia  
Infectious mononucleosis  
Hepatitis B  
Psittacosis  
Tuberculosis

**Other diseases**

Sarcoidosis  
Ulcerative colitis  
Crohn disease  
Lymphoma  
Leukemia  
Behçet syndrome

## CONNECTIVE TISSUE

### Fibromatoses

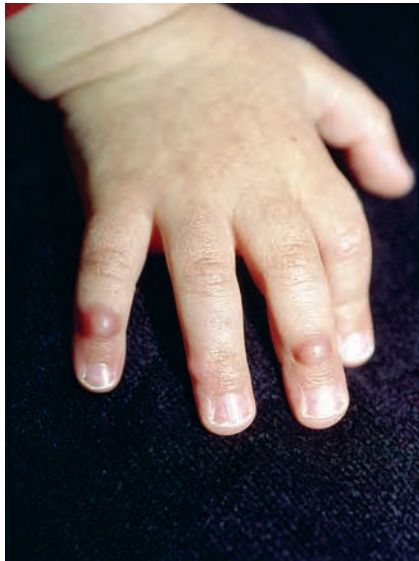#### General

- Two broad groups: superficial (fascial) fibromatoses, and deep (musculoaponeurotic) fibromatoses
- Benign proliferations of myofibroblasts

#### Major points

- Infantile digital fibromatosis
  1. Most common fibrous proliferation in the first year of life
  2. Solitary, smooth, dome-shaped nodule on the distal digital phalanx, which is either skin-colored or red (Figure 17.15)
  3. Size reaches 1–3 cm
  4. Multiple tumors common
  5. Fingers affected commonly (86%)
  6. No sex predilection
  7. Can spontaneously involute
  8. May need to be surgically excised, but there is a high recurrence rate
- Infantile myofibromatosis
  1. Seen at birth or early life
  2. Multiple cutaneous nodules with underlying tumors in the muscle, bone and visceral organs
  3. Lesions are firm, skin-colored to red-purple nodules ranging in size from 0.5 to 7 cm
  4. If limited to skin and bones, does not require treatment unless there is functional

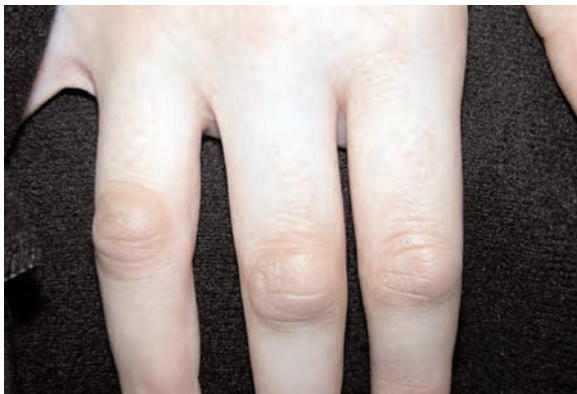



**Figure 17.15** Infantile digital fibromatosis – painless, firm papules on an infant's fingers

impairment. More aggressive types may require chemotherapy or radiation and may be fatal

- Plantar fibromatosis
  1. Firm, nontender nodule on mid-plantar surface of foot present at birth
  2. Uncomfortable when child walks
  3. Requires excision when symptomatic; recurrence is uncommon if completely excised
- Knuckle pads
  1. Solitary or multiple thickenings over the metacarpophalangeal or proximal interphalangeal joints (Figure 17.16)
  2. Require no treatment



**Figure 17.16** Knuckle pads on all the fingers

- Fibrous hamartoma of infancy
  1. Solitary (or multiple) nodules usually located on the shoulder, arm or axilla
  2. Present at birth or shortly after
  3. Treat with excision; recurrence is uncommon
- Juvenile hyaline fibromatosis
  1. Very rare triad of fibrous growths on the head and neck, flexion contractures and gingival hyperplasia
  2. Skull and encephalic abnormalities
  3. Autosomal recessive
  4. Relentless progression

### *Pathogenesis*

- Etiology is unknown, but fibromatoses are characterized by a proliferation of fibrous/myofibrous tissue

### *Diagnosis*

- Histology is essential
  1. Infantile digital fibromatosis: perinuclear cytoplasmic inclusions seen with trichrome stain (may represent actin microfilaments) within a proliferation of fibrous tissue
  2. Infantile myofibromatosis: spindle-shaped fibroblasts in whorls and interlacing bundles
  3. Fibrous hamartoma of infancy: distinctive tracts of fibroblasts, fat and small blue cells within the lesion
  4. Juvenile hyaline fibromatosis: hyalinized collagen with fibroblast proliferation

### *Differential diagnosis*

- Knuckle pads: Gottron papules (dermatomyositis), acanthosis nigricans
- Infantile myofibromatosis: soft tissue sarcomas, hemangioendotheliomas, fibrosarcomas, lipomas, fibrous histiocytomas, lipoblastomas, neurofibromas, rhabdomyosarcomas
- Infantile digital fibroma/fibrous hamartoma of infancy: sarcoma

### *Prognosis*

- Deeper variants can behave aggressively and become infiltrative but do not metastasize

### *References*

Bellman B, Wooming G, Landsman L, et al. Infantile myofibromatosis: a case report. *Pediatr Dermatol* 1991; 8: 306–9

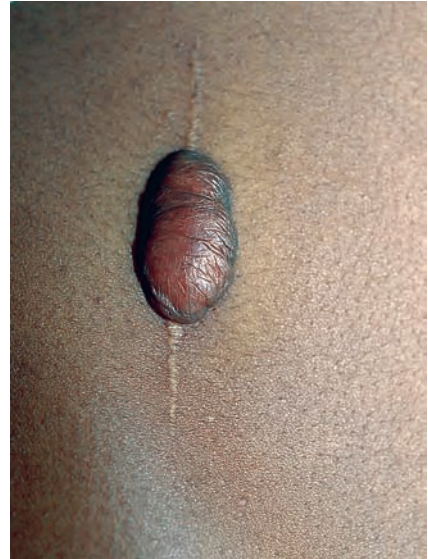


- Caylakli F, Cakmak O, Seckin D, et al. Juvenile hyaline fibromatosis: a case report. *Int J Pediatr Otorhinolaryngol* 2003; 67: 557–61
- Counsell SJ, Devile C, Mercuri E, et al. Magnetic resonance imaging assessment of infantile myofibromatosis. *Clin Radiol* 2002; 57: 67–70
- Dickey GE, Sotelo-Avila C. Fibrous hamartoma of infancy: current review. *Pediatr Dev Pathol* 1999; 2: 236–43
- Eich GF, Hoeffel JC, Tschappeler H, et al. Fibrous tumours in children: imaging features of a heterogeneous group of disorders. *Pediatr Radiol* 1998; 28: 500–9
- Gandhi MM, Nathan PC, Weitzman S, Levitt GA. Successful treatment of life-threatening generalized infantile myofibromatosis using low-dose chemotherapy. *J Pediatr Hematol Oncol* 2003; 25: 750–4
- Goldberg NS, Bauer BS, Kraus H, et al. Infantile myofibromatosis: a review of clinicopathology with perspectives on new treatment choices. *Pediatr Dermatol* 1988; 5: 37–46
- Haleem A, Al-Hindi HN, Juboury MA, et al. Juvenile hyaline fibromatosis: morphologic, immunohistochemical, and ultrastructural study of three siblings. *Am J Dermatopathol* 2002; 24: 218–24
- Ikediodi NI, Iyengar V, Hwang L, et al. Infantile myofibromatosis: support for autosomal dominant inheritance. *J Am Acad Dermatol* 2003; 49 (2 Suppl): S148–50
- Kang SK, Chang SE, Choi JH, et al. A case of congenital infantile digital fibromatosis. *Pediatr Dermatol* 2002; 19: 462–3
- Kanwar AJ, Kaur S, Thami GP, Mohan H. Congenital infantile digital fibromatosis. *Pediatr Dermatol* 2002; 19: 370–1
- Keltz M, DiCostanzo D, Desai P, Cohen SR. Infantile (desmoid-type) fibromatosis. *Pediatr Dermatol* 1995; 12: 149–51
- Rahman N, Dunstan M, Teare MD, et al. The gene for juvenile hyaline fibromatosis maps to chromosome 4q21. *Am J Hum Genet* 2002; 71: 975–80

## Keloids

### Major points

- Mildly tender, firm papule or nodule arising in site of previous injury (e.g. surgery, ear piercing, cystic acne, burns) and extends beyond the border of the original injury (Figure 17.17)
- Lesions are skin-colored, pink or hyperpigmented



**Figure 17.17** Keloid – firm plaque in a scar

- Can be disfiguring
- May be painful, especially when growing
- Common locations are shoulders, chest and earlobes
- More common in dark-skinned teenagers

### Pathogenesis

- Caused by unchecked proliferation of fibrous tissue and collagen following an injury to the dermis which invades the surrounding skin

### Diagnosis

- Histology: whorls of young fibrous tissue and fibroblasts arranged in a haphazard manner with thick, eosinophilic, acellular bands of collagen and thickening of dermis; mast cells and plasma cells increased in number; elastin usually absent

### Differential diagnosis

- Hypertrophic scar
- Fibrosarcoma

### Treatment

- Intralesional steroids (e.g. triamcinolone 10–40 mg/ml) given every 2–4 weeks until flattened and not growing
- Larger lesions should be excised with subsequent steroid injections until growth of the lesion has stopped

### Prognosis

- Keloids tend to persist and enlarge slowly over time and can recur even when treated

### References

- Berman B, Bielewicz HC. Keloids. *J Am Acad Dermatol* 1995; 33: 117–23
- Gold MH. A controlled clinical trial of topical silicone gel sheeting in the treatment of hypertrophic scars and keloids. *J Am Acad Dermatol* 1994; 30: 506–7
- Kelly AP. Pseudofolliculitis barbae and acne keloidalis nuchae. *Dermatol Clin* 2003; 21: 645–53
- Marneros AG, Norris JEC, Olsen JR, Reichenberger E. Clinical genetics of familial keloids. *Arch Dermatol* 2001; 137: 1429–34
- Poochareon VN, Berman B. New therapies for the management of keloids. *J Craniofac Surg* 2003; 14: 654–7
- Rahban SR, Garner WL. Fibroproliferative scars. *Clin Plast Surg* 2003; 30: 77–89
- Sahl WJ, Clever J. Cutaneous scars: part II. *Int J Dermatol* 1994; 33: 763–9

## Acne keloidalis nuchae

### Major points:

- Chronic scarring folliculitis located on posterior neck in young Black men
- Characteristic follicular papules that coalesce into firm plaques and nodules (Figure 17.18)
- Begins with a chronic folliculitis which heals with keloid-like papules
- Can form small to large plaques
- Lesions usually pruritic or painful

### Pathogenesis

- Etiology uncertain
- Aggravated by shaving tightly curled hair at the nape of the neck and having the new hair curve back into the skin, causing inflammation at the deep infundibular and isthmic levels of the hair follicle
- Histology:
  1. Early: inflammatory cells in the upper one-third of hair follicle; sebaceous glands diminished
  2. Later: dermal fibrosis and scar formation

### Diagnosis

- Clinical diagnosis

### Differential diagnosis

- Folliculitis
- Hypertrophic scars
- Pseudofolliculitis barbae

### Treatment

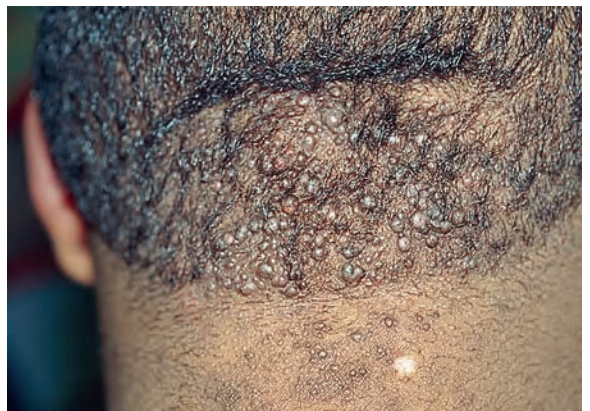- Early treatment essential
- Intralesional steroids or short course of oral steroids for acute inflammation
- Surgical excision followed by intralesional steroids if extensive
- Oral antibiotics (e.g. minocycline, doxycycline) and topical retinoids

### Prognosis

- Chronic unless treated

### References

- Dinehart SM, Herzberg AJ, Kerns BJ, Pollack SV. Acne keloidalis: a review. *J Dermatol Surg Oncol* 1989; 15: 642–7
- Giovannini UM. Treatment of scars by steroid injections. *Wound Repair Regeneration* 2002; 10: 116–17
- Glenn MJ, Bennett RG, Kelly AP. Acne keloidalis nuchae: treatment with excision and second-intention healing. *J Am Acad Dermatol* 1995; 33: 243–6
- Tsao SS, Dover JS, Arndt KA, Kaminer MS. Scar management: keloid, hypertrophic, atrophic, and acne scars. *Semin Cutan Med Surg* 2002; 21: 46–75



**Figure 17.18** Acne keloidalis nuchae – typically seen at the nape of the neck

## Hypertrophic scars

### Major points

- Firm, slightly raised, flat, pink or red nodule or plaque in the area of previous injury or inflammation but stays within the site of original injury

### Pathogenesis

- Caused by unchecked proliferation of fibrous tissue following an injury to the dermis

### Diagnosis

- Histology: whorls of young fibrous tissue and fibroblasts arranged in a haphazard manner with marked thickening of the dermis

### Differential diagnosis

- Keloid
- Basal cell carcinoma
- Skin appendage tumors
- Dermatofibroma

### Treatment

- Intralesional steroids (e.g. triamcinolone 10–40 mg/ml) given every 2–4 weeks until flattened
- Silicone gel sheeting worn continuously for several months

### Prognosis

- Hypertrophic scars can flatten with time, but are usually stable after 1 year

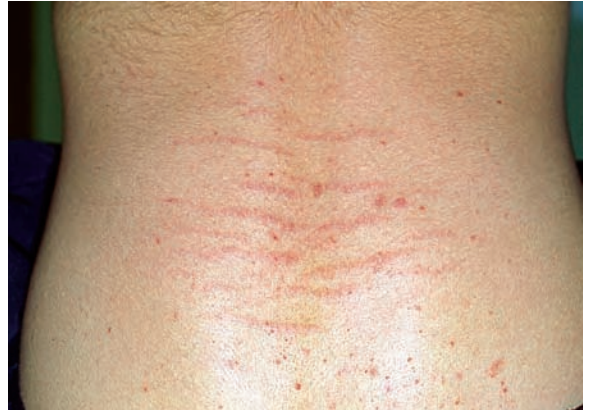### References

- Brissett AE, Sherris DA. Scar contractures, hypertrophic scars, and keloids. *Fac Plast Surg* 2001; 17: 263–72
- Gold MH. A controlled clinical trial of topical silicone gel sheeting in the treatment of hypertrophic scars and keloids. *J Am Acad Dermatol* 1994; 30: 506–7
- Nemeth AJ. Keloids and hypertrophic scars. *J Dermatol Surg Oncol* 1993; 19: 738–46
- Sahl WJ, Clever J. Cutaneous scars: part II. *Intern J Dermatol* 1994; 33: 763–9
- Shaffer JJ, Taylor SC, Cook-Bolden F. Keloidal scars: a review with a critical look at therapeutic options. *J Am Acad Dermatol* 2002; 46 (2 Suppl): S63–97

## Striae distensae

### Major points

- Visible scars with linear, smooth bands of atrophic skin (Figure 17.19)
- Begin as reddish streaks, then turn purple, and finally white



**Figure 17.19** Striae distensae ('stretch marks') occur commonly in teens on the lower back, inner thighs and breasts

- Most common sites: thighs, buttocks, breasts in girls, lower back in boys

### Pathogenesis

- Histology: thin overlying epidermis, fine dermal collagen bundles arranged in straight parallel lines, some inflammation, and elastolysis; late stages show dermal collagen in thin eosinophilic bundles, oriented in straight lines
- Pathogenesis unknown, probably relates to changes in extracellular matrix components
- Causes: puberty, obesity, corticosteroids, pregnancy, increased adrenocortical function, genetic factors

### Diagnosis

- Clinical inspection

### Differential diagnosis

- Ehlers–Danlos syndrome
- Marfan syndrome
- Child abuse

### Treatment

- Usually no treatment is necessary
- Pulsed dye laser can improve redness in early lesions
- Discontinuance of steroids, if this is a precipitating factor
- Emollients (e.g. petrolatum, cocoa butter)

### Prognosis

- Lesions are permanent

### References

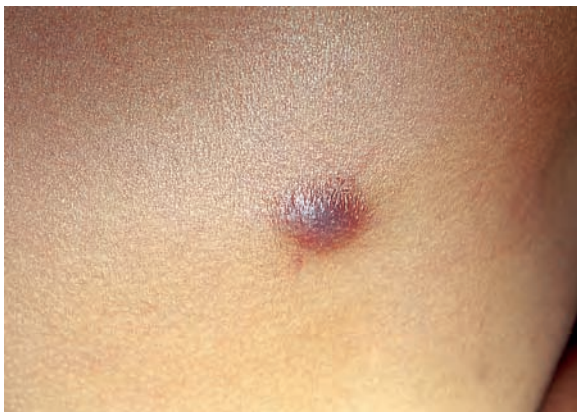- Di Lernia V, Bonci A, Cattania M, Bisighini G. Striae distensae (rubrae) in monozygotic twins. *Pediatr Dermatol* 2001; 18: 261–2
- Garcia Hidalgo L. Dermatological complications of obesity. *Am J Clin Dermatol* 2002; 3: 497–506
- Jabbour SA. Cutaneous manifestations of endocrine disorders: a guide for dermatologists. *Am J Clin Dermatol* 2003; 4: 315–31
- McDaniel DH. Laser therapy of stretch marks. *Dermatol Clin* 2002; 20: 67–76

## Dermatofibroma

Synonym: fibrous histiocytoma

### Major points

- Common, benign, asymptomatic papule or papules ranging from 0.5 mm to 1 cm, commonly found on the lower legs, but may occur anywhere (Figure 17.20)



**Figure 17.20** Dermatofibroma – firm brown papule commonly seen on the lower legs

- Usually solitary but may be multiple
- Color varies: yellow, red, purple or dark brown with rim of brown pigment and variation in color
- Palpation: firm or hard; feels like a pea which is fixed to the skin surface and freely movable over the subcutis
- Lateral pressure produces a ‘dimple sign’ with an overlying depression in the center of the papule

### Pathogenesis

- Cause unknown but thought to be the result of trauma, insect bites, or viral infection

### Diagnosis

- Clinical features characteristic
- Histology: whorling fascicles of spindle cells; edges are poorly defined. A Grenz zone of normal tissue lies above the lesion in the papillary dermis; epidermis is acanthotic

### Differential diagnosis

- Nevocellular nevus
- Melanoma
- Xanthoma
- Prurigo nodularis
- Seborrheic keratosis
- Dermatofibrosarcoma protuberans

### Treatment

- None usually needed
- Excision if painful or large

### Prognosis

- Lesions are benign and usually stable
- Can resolve, leaving hypo- or hyperpigmentation

### References

- Bouyssou-Gauthier M-L, Labrousse F, Longis B, et al. Dermatofibrosarcoma protuberans in childhood. *Pediatr Dermatol* 1997; 14: 463–5
- Curco N, Jucgla A, Bordas X, Moreno A. Dermatofibroma with spreading satellitosis. *J Am Acad Dermatol* 1992; 27: 1017–18
- Holst VA, Junkins-Hopkins JM, Elenitsas R. Cutaneous smooth muscle neoplasms: clinical features, histologic findings, and treatment options. *J Am Acad Dermatol* 2002; 46: 477–90
- Kutzner H. Expression of the human progenitor cell antigen CD34 (HPCA-1) distinguishes dermatofibrosarcoma protuberans from fibrous histiocytoma in formalin-fixed,



paraffin-embedded tissue. *J Am Acad Dermatol* 1993; 28: 613–17

Lew W, Lim HS, Kim YC. Cutaneous metastatic malignant fibrous histiocytoma. *J Am Acad Dermatol* 2003; 48 (2 Suppl): S39–40

Niiyama S, Katsuoka K, Happle R, Hoffmann R. Multiple eruptive dermatofibromas: a review of the literature. *Acta Derm Venereol* 2002; 82: 241–4

## Neurofibroma

### Major points

- Presents as a skin-colored papule or nodule, soft to palpation ranging in size from 0.5 to >3 cm
- Upon pressure to the lesion, the neurofibroma pushes into the skin giving the sensation that one is pushing a button through a buttonhole
- Some lesions are pedunculated
- Usually solitary unless seen in the context of neurofibromatosis (see Chapter 20)
- Variants such as plexiform neurofibroma can be seen in neurofibromatosis

### Pathogenesis

- Hyperplasia of nerve elements arising in nerves, composed of Schwann cells, fibroblasts and endothelial cells

### Diagnosis

- Biopsy often needed for confirmation
- Histology: Schwann cells, fibroblasts, endothelial cells, mast cells, perineural fibroblasts and axons arranged haphazardly in a matrix containing collagen and myxoid ground substance; circumscribed but not encapsulated

### Differential diagnosis

- Dermal nevus
- Skin tag (acrochordon)
- Dermatofibroma

### Treatment

- Usually no treatment needed
- Simple excision if indicated

### Prognosis

- Small neurofibromas not associated with neurofibromatosis tend to remain stable or slowly enlarge with time

- Those associated with neurofibromatosis tend to enlarge slowly

## References

- DeBella K, Szudek J, Friedman JM. Use of the National Institutes of Health criteria for diagnosis of neurofibromatosis 1 in children. *Pediatrics* 2000; 105: 608–14
- Johnson NS, Saal HM, Lovell AM, Schorry EK. Social and emotional problems in children with neurofibromatosis type 1: evidence and proposed interventions. *J Pediatr* 1999; 134: 767–72
- Kandt RS. Tuberous sclerosis complex and neurofibromatosis type 1: the two most common neurocutaneous diseases. *Neurol Clin* 2003; 21: 983–1004
- Riccardi VM. Of mass and men. Neurofibromas and histogenesis [Editorial]. *Arch Dermatol* 2000; 136: 1257–8
- Viskochil DH. It takes two to tango: mast cell and Schwann cell interactions in neurofibromas. *J Clin Invest* 2003; 112: 1791–3

## Corns and calluses

Synonym: clavus (multiple: clavi)

### Major points

- Hyperkeratotic plaque seen over pressure or frictional areas typically on the feet
- When pared with a blade, there is a central translucent core, without thrombosed capillaries (as seen in warts)
- Corns can be hard, soft, vascular, or neurovascular
- Hard corns are usually over the dorsal interphalangeal joints, on the plantar surface underlying the metatarsal heads, or on the great toe
- Soft corns arise interdigitally, typically in the fourth web space

### Pathogenesis

- Corns are caused by ill-fitting footwear with pointed toes causing crowding in the shoe toe box, or from the digits pressing on each other

### Diagnosis

- Clinical features

### Differential diagnosis

- Verruca vulgaris
- Verruca plantaris



- Glomus tumors
- Eccrine poroma

### *Treatment*

- Pare with scalpel blade
- Salicylic acid plasters and other keratolytics used in combination with paring
- Obtain shoes that fit better

### *Prognosis*

- Lesions are stable or progressive unless underlying cause is addressed

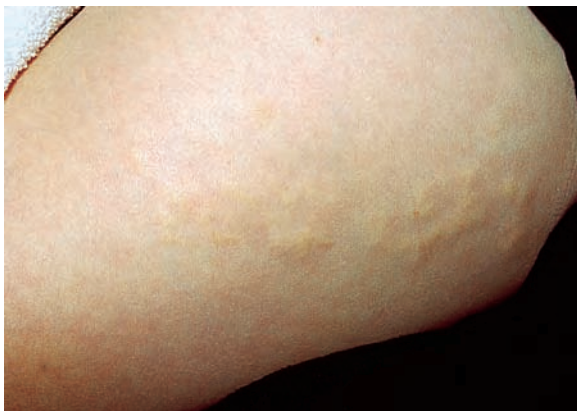### *References*

Smith M. Environmental and sports-related skin diseases. In Dermatology. Bologna JL, Jorizzo JL, Rapini R, eds. Mosby: London, 2003: 1399

## **Connective tissue nevus**

### *Major points*

- Connective tissue nevi (CTN) are hamartomas of either collagen or elastin or an abnormality in ground substance plus structural components of connective tissue
- Male/female ratio = 1
- Sporadic or autosomal dominant inheritance
- Usually present at birth or in early childhood
- Characteristic firm, nontender, irregularly shaped, or oval skin-colored plaque (Figure 17.21)
- Common locations: trunk, buttocks, or extremities



**Figure 17.21** Connective tissue nevus – skin-colored plaque

- Surface of plaque has a pebbled appearance (termed *peau d'orange*, 'skin of an orange')
- Solitary lesions usually measure 2–10 cm, whereas clustered lesions usually are 4–5 mm
- Associations:
  1. Tuberous sclerosis: shagreen plaques
  2. Buschke–Ollendorff syndrome (dermatofibrosis lenticularis disseminata) shows multiple small CTN and osteopoikilosis (bony dysplasia of the long bones, pelvis, hands and feet)

### *Pathogenesis*

- Hamartoma with various amounts of collagen, elastin and adipose tissue without increase in fibroblasts

### *Diagnosis*

- Often requires biopsy for confirmation
- Biopsy should be a small wedge biopsy including lesional and nonlesional skin in order to compare normal and abnormal dermal tissues

### *Differential diagnosis*

- Smooth muscle hamartoma
- Plexiform neurofibroma
- Neurofibroma
- Amyloidosis
- Colloid millium
- Nevus lipomatosus

### *Treatment*

- Reassurance to parents of benign nature
- Surgical excision

### *Prognosis*

- Most solitary CTN are benign and not associated with other syndromes

### *References*

Chang SE, Kang SK, Kim ES, et al. A case of congenital mucinous nevus: a connective tissue nevus of the proteoglycan type. *Pediatr Dermatol* 2003; 20: 229–31

Crivellato E. Disseminated nevus anelasticus. *Int J Dermatol* 1986; 25: 171–3

DePadova-Elder S, Mols-Kowalczewski BL, Lambert WC. Multiple connective tissue nevi. *Cutis* 1988; 42: 222–4

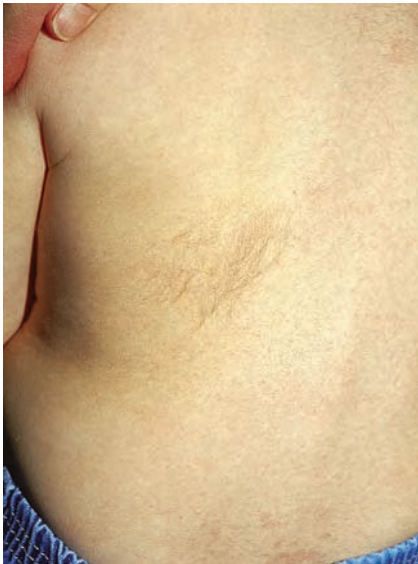Uitto J, Santa Cruz DJ, Eisen AZ. Connective tissue nevi of the skin. *J Am Acad Dermatol* 1980; 3: 441–61

Yeh SW, Magalhaes AM, Vasconcellos MR, et al. Zosteriform connective tissue nevus: a case report. *Int J Dermatol* 2003; 42: 720–2

## Smooth muscle hamartoma

### Major points

- Lesions are solitary, skin-colored or hyperpigmented, infiltrative patches or plaques with accentuation of hair follicles (Figure 17.22)



**Figure 17.22** Smooth muscle hamartoma – with overlying hypertrichosis

- Size usually 1–5 cm
- Hypertrichosis develops in two-thirds of lesions
- Often overlooked in infancy
- Rarely acquired in later life
- Common location in lumbosacral area (67%)
- No associated systemic abnormalities
- When firmly stroked, fasciculation of the skin causes the appearance of goosebumps or cobblestones (pseudo-Darier sign) from the stimulation of aberrant arrector pili muscles
- Slight male predominance

### Pathogenesis

- Some authors think smooth muscle hamartoma and Becker nevus are hamartomas of a single

spectrum, with varying increases of epidermis, smooth muscle and hair appendages

### Diagnosis

- Histology: numerous smooth muscle fibers oriented haphazardly within the dermis

### Differential diagnosis

- Mastocytoma
- Connective tissue nevus
- Plexiform neurofibroma
- Congenital nevus
- Becker nevus

### Treatment

- None needed
- Seldom requires excision

### Prognosis

- Lesion is benign and stable

### References

- D'Addario SF, Morgan M, Talley L, Smoller BR. h-Caldesmon as a specific marker of smooth muscle cell differentiation in some soft tissue tumors of the skin. *J Cutan Pathol* 2002; 29: 426–9
- Grau-Massanes M, Raimer SS, Colome-Grimmer M, et al. Congenital smooth muscle hamartoma presenting as a linear atrophic plaque: case report and review of the literature. *Pediatr Dermatol* 1996; 13: 222–5
- Gualandri L, Cambiaghi S, Ermacora E, et al. Multiple familial smooth muscle hamartomas. *Pediatr Dermatol* 2001; 18: 17–20
- Holst VA, Junkins-Hopkins JM, Elenitsas R. Cutaneous smooth muscle neoplasms: clinical features, histologic findings, and treatment options. *J Am Acad Dermatol* 2002; 46: 477–90

## INFILTRATIONS

### Juvenile xanthogranuloma

#### Major points

- Most common non-Langerhans cell histiocytosis of childhood
- Sporadic in occurrence
- No sexual or racial predilection
- Usually appear in early infancy, between 1 and 4 years

- One lesion (25% of cases) to hundreds of firm, reddish-yellow papules/nodules; size 1–10 mm (Figure 17.23)
- Continues to develop lesions over 2 years
- Telangiectasias on surface are common
- Occasional superficial erosions
- Types:
  1. Disseminated micronodular juvenile xanthogranuloma (JXG): small papular lesions (<6 mm) are most common
  2. Patients who have larger nodules tend to have fewer lesions
  3. Solitary giant JXG (4–10 cm)
  4. Clustered variant
  5. Generalized lichenoid variant
- Typical locations: face, neck, scalp, but trunk and extremities can be involved
- Extracutaneous sites (very rare): eyes, lungs, pericardium, spleen, liver, testes, meninges
  1. Rarely symptomatic except eye involvement
  2. Eye involvement more common in disseminated micronodular variant. Usually unilateral and can be confused with retinoblastoma
- Numerous associations. Most are probably coincidental except JXG associated with neurofibromatosis and juvenile chronic myelogenous leukemia

### Pathogenesis

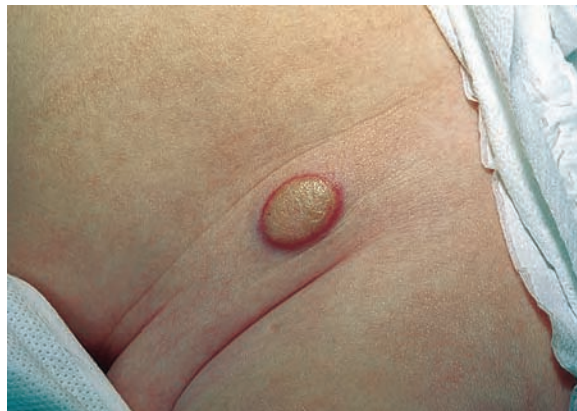- Cause unknown
- May be a reactive histiocytic process rather than a neoplasia
- Blood lipid levels normal

### Differential diagnosis

- Histology:
  1. Early lesions show accumulation of macrophages without lipid droplets
  2. Well-developed lesions demonstrate granulomatous infiltrate with foamy lipid-laden macrophages and Touton giant cells
  3. No Birbeck granules on electron microscopy or S-100 protein present

### Differential diagnosis

- Mastocytoma
- Spitz nevus
- Benign cephalic histiocytosis



**Figure 17.23** Juvenile xanthogranuloma – yellow papule with red halo

- Langerhans cell histiocytosis
- Tuberous xanthoma
- Papular xanthoma (Figure 17.24)
- Multicentric reticulohistiocytosis

### Treatment

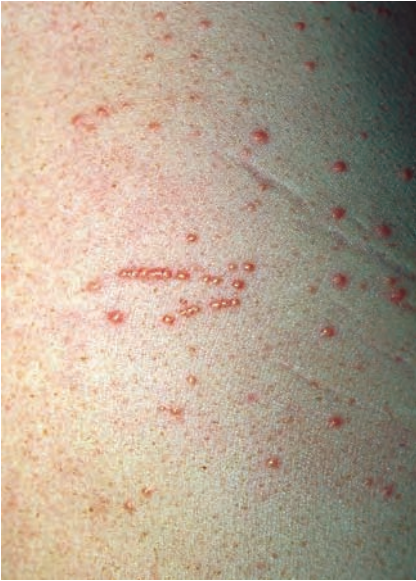- None is necessary except in ulcerated or large lesions where surgical intervention may be warranted

### Prognosis

- Excellent, with complete involution within 6 months in 30%
- Spontaneous involution in the remainder by 3–6 years
- Residual pigmentation or atrophy may occur

### References

- Chang MW. Update on juvenile xanthogranuloma: unusual cutaneous and systemic variants. *Semin Cutan Med Surg* 1999; 18: 195–205
- Chang MW, Frieden IJ, Good W. The risk of intraocular juvenile xanthogranuloma: survey of current practices and assessment of risk. *J Am Acad Dermatol* 1996; 34: 445–9
- Freyer DR, Kennedy R, Bostrom BC, et al. Juvenile xanthogranuloma: forms of systemic disease and their clinical implications. *J Pediatr* 1996; 129: 227–37
- Piraccini BM, Fanti PA, Iorizzo M, Tosti A. Juvenile xanthogranuloma of the proximal nail fold. *Pediatr Dermatol* 2003; 20: 307–8
- Zelger B, Burgdorf WH. The cutaneous ‘histiocytoses’. *Adv Dermatol* 2001; 17: 77–114



**Figure 17.24** Eruptive xanthomas – in a patient with elevated triglycerides and diabetes

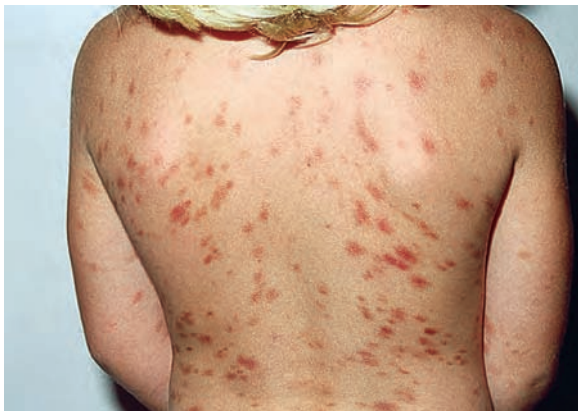Zvulunov A, Barak Y, Metzker A. Juvenile xanthogranuloma, neurofibromatosis, and juvenile chronic myelogenous leukemia. *Arch Dermatol* 1995; 131: 904–8

## Mastocytosis

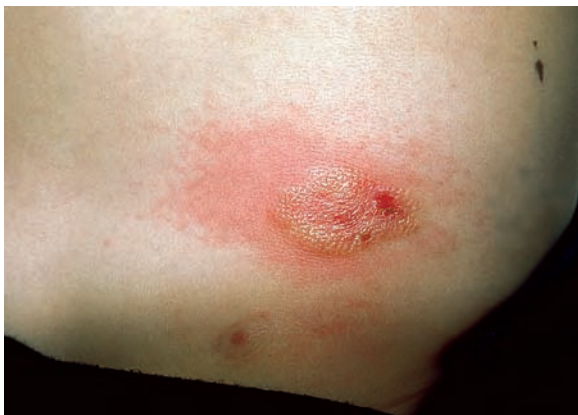### Major points

- Group of disorders characterized by the infiltration of mast cells into the tissues, particularly the skin
  - Usually begins in childhood and distinct from adult mastocytosis which tends to have a poor prognosis
  - No sex predilection
  - More common in Whites
  - Sporadic occurrence; however, a familial form exists
  - Onset between birth and 2 years in the majority of cases, with fewer presenting later in childhood
  - Types of mastocytosis: solitary mastocytoma, urticaria pigmentosa, diffuse mastocytosis, telangiectasia macularis eruptiva perstans, systemic mastocytosis and mast cell leukemia
    1. In pediatrics, the following account for >95% of cases of mastocytosis: solitary mastocytoma, urticaria pigmentosa and diffuse mastocytosis
- Solitary mastocytoma
    1. Usually solitary, but occasionally several lesions
    2. New lesions develop for several months after the first lesion appears, but tend not to continue to develop past 1 year
    3. Most common on neck, arms and trunk, but can be anywhere
    4. Typical oval to round 1–5 cm slightly brownish yellow nodule which feels thickened or rubbery with a pebbly surface
    5. Darier sign: urtication can be demonstrated by stroking the lesion with a typical wheal and flare
    6. History of bulla formation, generalized pruritus, flushing, colicky abdominal pain, diarrhea
    7. Symptoms often resolve within 2 years, even when the lesion persists
    8. Most plaques have flattened or disappeared by age 10 years
  - Urticaria pigmentosa (UP)
    1. Most common form of mastocytosis
    2. Predominantly a disease of infants and young children
    3. Symptoms begin between 3 and 9 months
    4. Numerous 5 mm to 2 cm reddish brown to yellowish brown slightly elevated nodules, predominantly on the trunk, but can be anywhere; generally has fewer lesions (Figure 17.25)
    5. Darier sign is positive in most lesions (Figure 17.26)
    6. May be associated with dermatographism
    7. New lesions may continue to develop for many years
    8. Bullae may develop within the lesions
    9. Pruritus is often the only symptom
    10. History of bulla formation, generalized pruritus, flushing, colicky abdominal pain, diarrhea
  - Diffuse cutaneous mastocytosis (DCM)
    1. Rare in childhood
    2. Neonates born with erythematous, thickened doughy feeling skin which appears lichenified
    3. Severe widespread bullae may occur
    4. Systemic involvement is prominent with flushing, diarrhea, vomiting, abdominal pain, respiratory distress, shock; can be fatal





**Figure 17.25** Mastocytosis – typical urticaria pigmentosa with numerous brown-yellow papules



**Figure 17.26** Mastocytosis – Darier sign can be elicited by rubbing a lesion of mastocytosis

- Malignant mast cell disease
    1. Involvement of hematopoietic and reticuloendothelial systems
    2. Occurs in 30% of adults with mastocytosis; very rare in children
    3. One reported case of acute lymphoblastic leukemia associated with UP in a child
  - Mastocytosis syndrome
    1. Results from massive release of vasoactive mediators from mast cells
    2. Can be caused by any mast cell degranulator (see Table 17.5)
    3. Symptoms: flushing, tachycardia, diarrhea, projectile vomiting, abdominal pain, respiratory distress (wheezing), hypotension, severe pruritus and potential shock
    4. Should be treated immediately
- Pathogenesis**
- Thought to represent a reactive hyperplasia of normal mast cells, rather than a neoplasia

**Table 17.5 Mast cell degranulators**

**Drugs**

Aspirin  
 Nonsteroidal anti-inflammatory drugs (e.g. ibuprofen, naproxen)  
 Alcohol  
 Caffeine  
 Codeine  
 Morphine  
 Narcotics  
 Polymyxin B (can be in topical antibiotics)  
 Radiographic dyes  
 Some anesthetics

**Physical stimuli**

Hot baths  
 Exercise  
 Rubbing the skin  
 Cold stress (entering a cold lake or exiting a swimming pool)  
 Hot spicy foods (also in some candies)

**Other**

Snake venom  
 Shellfish  
 Emotional stress  
 Insect bites

- Telangiectasia eruptiva macularis perstans (TMEP)
  1. Seen in <1% of cases of mastocytosis
  2. Appears as tan to brown macules and patchy erythema with telangiectasias
  3. Mainly in teens or adults
- Systemic mastocytosis
  1. More common in widespread disease of UP and DCM
  2. Skeletal system may show evidence of involvement on X-ray (e.g. lytic, cystic or sclerotic lesions), but in most cases of UP and DCM these lesions resolve
  3. Involvement of other systems: lungs, liver, spleen, kidney and heart with hepatosplenomegaly, anemia, bone pain, failure to thrive



- Normal mast cells help protect the body by surveillance of environmental antigens
  1. Found in skin, respiratory tract, GI tract, genitourinary tract and adjacent to neurovascular bundles
  2. Receptors on mast cells have a high affinity for Fc portion of IgE antibody with subsequent degranulation
- Soluble mediators released from keratinocytes may cause accumulation of mast cells in the upper dermis
- Patients with mastocytosis do not have an increase in allergies

### Diagnosis

- With a solitary mastocytoma or UP, clinical appearance and typical Darier sign will usually make the diagnosis
- Histology: dense infiltration of normal-appearing mast cells in the upper dermis
  1. Biopsy should not be performed on a recently stroked lesion, because the mast cells have degranulated and will not be seen with Giemsa stain
- Mast cells contain active mediators: histamine, heparin, tryptase, chymase, acid hydrolases, prostaglandin D<sub>2</sub> (PGD<sub>2</sub>), leukotriene C<sub>4</sub>, platelet-activating factor and tumor necrosis factor- $\alpha$
- Routinely, no laboratory tests are necessary. However, in some patients, the following tests may be monitored (depending upon symptoms): complete blood count, serum chemistry profiles, radiologic skeletal survey, bone marrow aspiration
- In diffuse disease, the following may be helpful in following the disease: serum or urinary histamine levels, urinary *N*-methylhistamine, *N*-methylimidazoleacetic acid (metabolites of histamine)
- Other markers of mast cell degranulation: PGD<sub>2</sub>, tryptase and heparin
- Skeletal survey or technetium bone scan may be indicated for bone pain

### Differential diagnosis

- Solitary mastocytoma/urticaria pigmentosa
  1. Juvenile xanthogranuloma
  2. Spitz nevus
  3. Nodular scabies

4. Congenital nevus
- Diffuse cutaneous mastocytosis
    1. Histiocytosis
    2. Bullous erythema multiforme
    3. Staphylococcal scalded skin syndrome
    4. Epidermolysis bullosa
    5. Infiltrative leukemias
  - TMEP
    1. Telangiectasias
    2. Urticaria
    3. Ephiledes

### Treatment

- No treatment of a solitary mastocytoma is usually needed
- Excision of a solitary mastocytoma is reserved for severely symptomatic lesions only
- Antihistamines may relieve pruritus (H1 blockers with or without H2 blockers)
- Oral disodium chromoglycate for GI symptoms
- Topical application of high-potency steroid ointments under occlusion may be helpful in isolated lesions or TMEP, with reduction of symptoms
- Intralesional steroids may reduce symptoms in individual lesions
- Systemic steroids are not effective
- Topical antibiotics, if used on the lesions, should not contain polymyxin B; mupirocin is recommended
- Psoralen with ultraviolet A light can be used in children aged >11 years for extensive disease
- Symptoms of mastocytosis syndrome (e.g. hypotension, wheezing, shock) should be treated aggressively with intravenous fluids, antihistamines, epinephrine, corticosteroids and vasopressors
- Parents of children should always carry a list of potential drugs which can degranulate mast cells to avoid complications (Table 17.5)
- Some children with extensive disease would benefit from an identification bracelet and a syringe of epinephrine kept nearby (e.g. EpiPen®)

### Prognosis

- Solitary mastocytoma resolves with few sequelae; bullae rarely scar
- Urticaria pigmentosa in childhood spontaneously resolves. A small number of patients with more

systemic manifestations will continue into adulthood, and have a more guarded prognosis

- Diffuse cutaneous mastocytosis with early onset of blisters has a poor prognosis. Without blisters, the prognosis is better. Eventually, the skin improves in symptoms and texture
- Malignant mast cell disease with infiltration of bone marrow and other organs has a very poor prognosis
- Severe symptoms should be treated in the emergency room

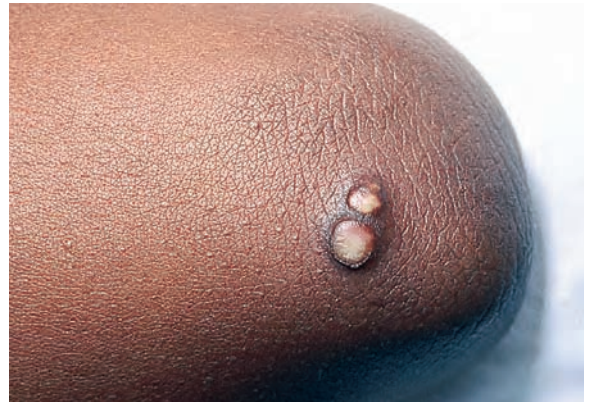### References

- Almahroos M, Kurban AK. Management of mastocytosis. *Clin Dermatol* 2003; 21: 274–7
- Caken H, Ciftci A, Kisaarslan AF, et al. A child with systemic mastocytosis who had a facial appearance resembling an aged man. *Pediatr Dermatol* 2002; 19: 184–5
- Golkar L, Bernhard JD. Mastocytosis. *Lancet* 1997; 349: 1379–85
- Heide R, Tank B, Oranje AP. Mastocytosis in childhood. *Pediatr Dermatol* 2002; 19: 375–81
- Longley J, Duffy TP, Kohn S. The mast cell and mast cell disease. *J Am Acad Dermatol* 1995; 32: 545–61
- Murphy M, Walsh D, Drumm B, Watson R. Bullous mastocytosis: a fatal outcome. *Pediatr Dermatol* 1999; 16: 452–5
- Shah PY, Sharma V, Worobec AS, et al. Congenital bullous mastocytosis with myeloproliferative disorder and *c-kit* mutation. *J Am Acad Dermatol* 1998; 39: 119–21
- Tharp MD. Understanding mast cells and mastocytosis. *J Invest Dermatol* 1997; 108: 698–9
- Tharp MD, Chan IJ. Mastocytosis. *Adv Dermatol* 2003; 19: 207–36
- Valent P, Akin C, Sperr WR, et al. Diagnosis and treatment of systemic mastocytosis: state of the art. *Br J Haematol* 2003; 122: 695–717
- Valent P, Akin C, Sperr WR, et al. Mast cell proliferative disorders: current view on variants recognized by the World Health Organization. *Hematol Oncol Clin North Am* 2003; 17: 1227–41

### Calcinosis cutis

#### Major points

- Presents with firm, stony 1–30-mm papules or plaques which may have an erythematous border (Figure 17.27)



**Figure 17.27** Calcinosis cutis – rock-hard, white papules on an elbow

- May be tender and ulcerate, discharging gritty material
- Distribution can be anywhere, but most common on the extremities, face and scrotum
- With extensive calcinosis, complications of contractures, pain and suppuration with or without superinfection may occur
- Dystrophic calcinosis cutis
  1. Most common form of calcinosis cutis
  2. Caused by deposition of calcium salts within previously damaged tissues with no metabolic abnormalities
  3. Localized forms arise in acne scars, ulcers, foreign body granulomas, subcutaneous fat necrosis of the newborn, neonatal heel sticks, cysts, lipomas and pilomatrixomas
  4. Widespread calcification is seen in systemic sclerosis, CREST syndrome, dermatomyositis, pseudoxanthoma elasticum, systemic lupus erythematosus and Ehlers–Danlos syndrome
  5. Iatrogenic causes: extravasation of intravenous calcium salts, electroencephalogram leads and electromyogram leads
- Idiopathic calcinosis cutis
  1. No evidence of local tissue injury or systemic metabolic disorder
  2. Localized
    - a. Idiopathic calcinosis circumscripta
    - b. Solitary congenital calcified nodule of the ear
    - c. Idiopathic calcinosis of the scrotum or vulva

3. Generalized
  - a. Milia-like idiopathic calcinosis cutis, seen in Down syndrome
- Metastatic calcinosis cutis
  1. Occurs with abnormal metabolism of calcium and/or phosphorous: chronic renal failure, vitamin D intoxication, sarcoidosis, parathyroid neoplasms, tumors
  2. Calcinosis is rarely seen in the skin, but more commonly in kidney, lung, gastric mucosa, eyes and arteries

### *Pathogenesis*

- Precipitation or deposition of hydroxyapatite crystals of calcium phosphate within cutaneous tissues
- Etiology not understood, but unidentified local factors may promote calcification within tissues
- Calcium deposits tend to occur in areas of damaged tissue or elastic fibers

### *Diagnosis*

- Radiographs reveal radio-opaque densities in areas of calcification
- Laboratory abnormalities are found only in metastatic form
- Histology: calcium deposits in the dermis or subcutaneous tissues with or without a foreign body reaction

### *Differential diagnosis*

- Osteoma cutis
- Myositis ossificans
- Pilomatrixoma

### *Treatment*

- Excision of isolated lesions may be indicated
- Correcting a metabolic disorder usually does not resolve the calcinosis, but may stop progression

### *Prognosis*

- Lesions rarely resolve spontaneously
- Superficial lesions may self-extrude through the skin

### *References*

Ahn SK, Kim KT, Lee SH, et al. The efficacy of treatment with triamcinolone acetonide in calcinosis cutis following extravasation of calcium gluconate: a preliminary study. *Pediatr Dermatol* 1997; 14: 103–9

Evans MJ, Blessing K, Gray ES. Subepidermal calcified nodule in children: a clinicopathologic study of 21 cases. *Pediatr Dermatol* 1995; 12: 307–10

Kotsuji T, Imakado S, Iwasaki N, et al. Milia-like idiopathic calcinosis cutis in a patient with translocation Down syndrome. *J Am Acad Dermatol* 2001; 45: 152–3

Lai CH, Farah R, Mallory SB. Congenital calcinosis cutis of the ear. *J Am Acad Dermatol* 2003; 49: 122–4

Ostrov BE, Goldsmith DP, Eichenfield AH, Athreya BH. Hypercalcemia during the resolution of calcinosis universalis in juvenile dermatomyositis. *J Rheumatol* 1991; 18: 1730–4

Rodriguez-Cano L, Garcia-Patos V, Creus M, et al. Childhood calcinosis cutis. *Pediatr Dermatol* 1996; 13: 114–17

Touart DM, Sau P. Cutaneous deposition diseases. Part II. *J Am Acad Dermatol* 1998; 39: 527–44

Walsh JS, Fairley JA. Calcifying disorders of the skin. *J Am Acad Dermatol* 1995; 33: 693–706

## **Osteoma cutis**

### *Major points*

- Present as multiple or solitary, hard, raised 1–5-cm nodules with surrounding normal or erythematous skin
- Lesions commonly seen on the face
- Usually asymptomatic; may be painful or tender
- Superficial lesions may become inflamed and extrude bony particles
- Primary ossification:
  1. Albright hereditary osteodystrophy (AHO)
    - a. Includes: pseudohypoparathyroidism and pseudopseudohypoparathyroidism
    - b. Heterogeneous disorder with multiple areas of subcutaneous ossification which are present at birth or may occur later
    - c. Lesions may occur anywhere and range in size from pinpoint to 5 cm
    - d. Other associated abnormalities: short stature, round facies, multiple skeletal abnormalities (curvature of the radius and shortened metacarpals and metatarsals), short broad nails, basal ganglia calcification, hypothyroidism, mental retardation, defective teeth and cataracts
    - e. Dimpling sign seen over knuckles caused by the shortened metacarpals
    - f. Inherited disorder: autosomal dominant or X-linked dominant

- g. Pseudohypoparathyroidism is characterized by a low serum calcium, hyperphosphatemia, and no response to parathyroid hormone (PTH), no renal diseases or other cause
- h. Pseudopseudohypoparathyroidism has normal calcium and phosphorus levels and no response to PTH
- i. Progression to pseudohypoparathyroidism with hypocalcemia and seizures may occur, and patients need to be monitored closely
- 2. Other forms of primary osteoma cutis:
  - a. Widespread osteomas present since birth or early life without AHO
  - b. Single, large, plaque-like osteomas present since birth on the scalp or extremities
  - c. Single, small osteomas arising in later life with or without epidermal elimination
  - d. Multiple miliary osteomas of the face: multiple 0.1–0.4-cm bluish white papules on the face. Most common in women with longstanding acne who have taken tetracycline or minocycline
- Secondary ossification (also called metaplastic osteoma cutis)
  - 1. Associated with neoplasms, cysts, inflammatory processes (e.g. dermatomyositis, scleroderma), scarring, metabolic conditions, trauma and pre-existing cutaneous mineralization

### Pathogenesis

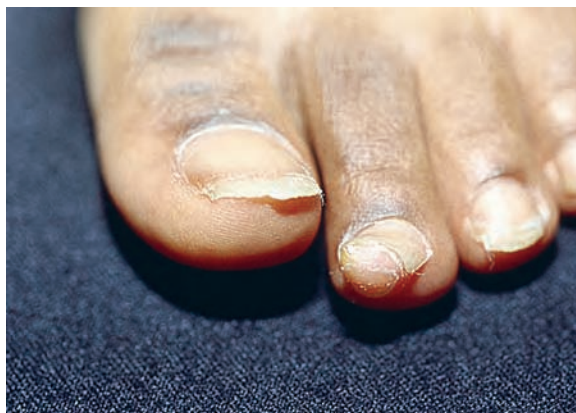- AHO: gene locus: 20q13.2
  - 1. Gene: GNAS1; partial deficiency of the protein which couples hormone receptors to stimulate adenylate cyclase, which causes multiple hormone resistance
- Secondary forms: hypothesized to follow inflammatory process or other insult

### Diagnosis

- Histology: proliferation of bony tissue with spicules of bone within the dermis and subcutaneous tissue, calcification, lamellae, lacunae, osteoblasts, osteocytes and rarely bone marrow formation

### Differential diagnosis

- Calcinosis cutis
- Subungual exostosis of the finger or toe (Figure 17.28)



**Figure 17.28** Exostosis – bony nodule on the tip of the toe requiring surgical excision

- Calcifying epithelioma
- Pilomatrixoma

### Treatment

- Surgical excision of larger or painful lesions
- Isotretinoin may aggravate osteoma formation
- Close follow-up of patients with AHO is important, with routine checking of calcium, phosphorous and thyroid hormone

### Prognosis

- Persists indefinitely, but occasionally extrudes spontaneously

### References

- Altman JF, Nehal KS, Busam KJ, Halpern AC. Treatment of primary miliary osteoma cutis with incision, curettage, and primary closure. *J Am Acad Dermatol* 2001; 44: 96–9
- Bergonse FN, Nico MM, Kavamura MI, Sotto MN. Miliary osteoma of the face: a report of 4 cases and review of the literature. *Cutis* 2002; 69: 383–6
- Chan I, Hamada T, Hardman C, et al. Progressive osseous heteroplasia resulting from a new mutation in the GNAS1 gene. *Clin Exp Dermatol* 2004; 29: 77–80
- Izraeli S, Metzker A, Horev G, et al. Albright hereditary osteodystrophy with hypothyroidism, normocalcemia, and normal Gs protein activity: a family presenting with congenital osteoma cutis. *Am J Med Genet* 1992; 43: 764–7
- Miller ES, Esterly NB, Fairley JA. Progressive osseous heteroplasia. *Arch Dermatol* 1996; 132: 787–91
- Moritz DL, Elewski B. Pigmented postacne osteoma cutis in a patient treated with minocycline: report and review of the literature. *J Am Acad Dermatol* 1991; 24: 851–3



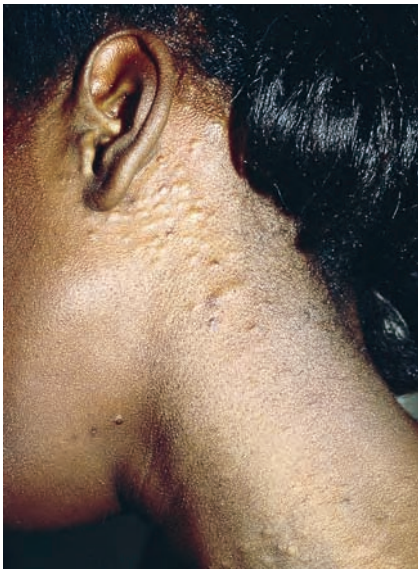Prendiville JS, Lucky W, Mallory SB, et al. Osteoma cutis as a presenting sign of pseudohypoparathyroidism. *Pediatr Dermatol* 1992; 9: 11–18

## GROWTHS

### Steatocystoma multiplex

#### Major points

- Uncommon cause of cysts in childhood
- Appears as asymptomatic, multiple, firm, skin-colored or yellowish papules several millimeters to 1–3 cm in size (Figure 17.29)



**Figure 17.29** Steatocystoma multiplex – numerous yellowish papules on the neck

- When punctured, a characteristic oily or creamy fluid is discharged
- Common areas are axillae, chest and arms, but may appear anywhere
- Usually begins in adolescence or early adulthood
- Male/female ratio = 1
- Autosomal dominant or sporadic
- Can be associated with pachyonychia congenita type 2

#### Pathogenesis

- Etiology unknown

#### Diagnosis

- Histology: flattened sebaceous gland lobules and folded cyst walls within the cyst

#### Differential diagnosis

See Table 17.2

#### Treatment

- Because lesions are usually numerous, surgical excision is difficult
- Inflamed lesions can be excised or treated with incision and drainage

#### Prognosis

- Lesions persist indefinitely

#### References

Ahn SK, Swang SM, Lee SH, Lee WS. Steatocystoma multiplex localized only in the face. *Int J Dermatol* 1997; 36: 372

Cho S, Chang SE, Choi JH, et al. Clinical and histologic features of 64 cases of steatocystoma multiplex. *J Dermatology* 2002; 29: 152–6

Kaur T, Kanwar AJ. Steatocystoma multiplex in four successive generations. *J Dermatol* 2003; 30: 559–61

Kaya TI, Ikizoglu G, Kokturk A, Tursen U. A simple surgical technique for the treatment of steatocystoma multiplex. *Int J Dermatol* 2001; 40: 785–8

Ohtake N, Kubota Y, Takayama O, et al. Relationship between steatocystoma multiplex and eruptive vellus hair cysts. *J Am Acad Dermatol* 1992; 26: 876–8

Sato K, Shibuya K, Taguchi H, et al. Aspiration therapy in steatocystoma multiplex. *Arch Dermatol* 1993; 129: 35–7

### Syringomas

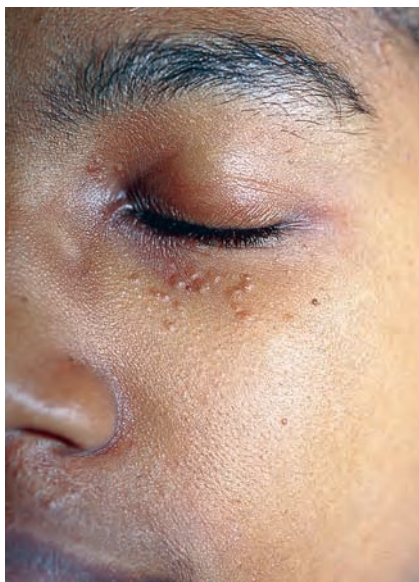#### Major points

- Appear at puberty as 1–2-mm skin-colored to yellowish papules (Figure 17.30)
- Location: most common around eyes, lids, upper cheeks, axillae and abdomen
- Female/male ratio >1
- May be autosomal dominant

#### Pathogenesis

- Thought to be a benign hyperplasia of the cells of the eccrine sweat ducts





**Figure 17.30** Syringomas – multiple, familial skin-colored papules around the eyes, a typical location

### Diagnosis

- Histology: numerous small eccrine ducts in the dermis with surrounding fibrosis; some ducts bulge out to form small comma-like excrescences (tadpole appearance)

### Differential diagnosis

See Table 17.2

### Treatment

- Difficult to treat
- Electrocautery somewhat helpful

### Prognosis

- Lesions persist and may become numerous

### References

- Goyal S, Martins CR. Multiple syringomas on the abdomen, thighs, and groin. *Cutis* 2000; 66: 259–62
- Guitart J, Rosenbaum MM, Requena L. 'Eruptive syringoma': a misnomer for a reactive eccrine gland ductal proliferation? *J Cutan Pathol* 2003; 30: 202–5
- Karma P, Benedetto AV. Intralesional electrodesiccation of syringomas. *Dermatol Surg* 1997; 23: 921–4
- Nguyen DB, Patterson JW, Wilson BB. Syringoma of the moustache area. *J Am Acad Dermatol* 2003; 49: 337–9

Pruzan DL, Esterly NB, Prose NS. Eruptive syringoma. *Arch Dermatol* 1989; 125: 1119–20

## Trichoepithelioma

### Major points

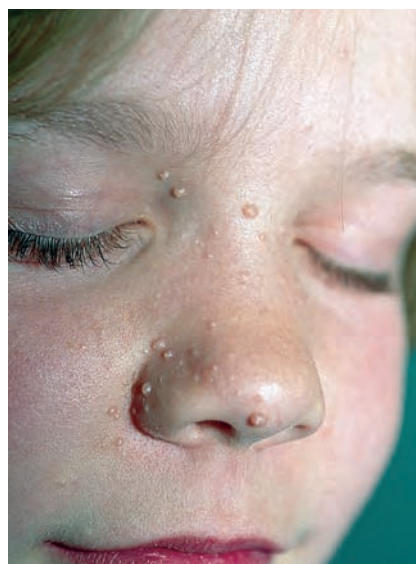- Presents in late childhood and adolescence
- Appears as solitary or numerous 2–8-mm skin-colored papules on the face, usually around the nose and mid-face (Figure 17.31)
- Fine telangiectasias on the surface
- May be seen on other parts of the body, especially the scalp, neck and upper trunk
- Multiple lesions are seen in Spiegler-Brooke syndrome (OMIM no. 605041), an autosomal dominant disorder; gene map locus 16q12-q13; gene CYLD
- Solitary lesions are not inherited

### Pathogenesis

- Benign tumor with follicular germinative differentiation

### Diagnosis

- Histology: multiple horn cysts and basophilic tumor islands in mid-dermis; can be difficult to distinguish from basal cell carcinoma



**Figure 17.31** Trichoepithelioma – multiple, skin-colored, asymptomatic, slow-growing papules on the face

*Differential diagnosis*

- Basal cell carcinoma
- Pilomatricoma
- Nevocellular nevus
- Syringoma
- Acne vulgaris

*Treatment*

- Surgical excision; recurrence common unless completely removed

*Prognosis*

- Gradually increase in number and size, then stabilize
- Lesions do not resolve spontaneously

*References*

- Centurion SA, Schwartz RA, Lambert WC. Trichoepithelioma papulosum multiplex. *J Dermatol* 2000; 27: 137–43
- Johnson SC, Bennett RG. Occurrence of basal cell carcinoma among multiple trichoepitheliomas. *J Am Acad Dermatol* 1993; 28: 322–6
- Matt D, Xin H, Vortmeyer AO, et al. Sporadic trichoepithelioma demonstrates deletions at 9q22.3. *Arch Dermatol* 2000; 136: 657–60
- Puig L, Nadal C, Fernandez-Figueras MT, et al. Brooke-Spiegler syndrome variant: segregation of tumor types with mixed differentiation in two generations. *Am J Dermatopathol* 1998; 20: 56–60
- Requena L, Farina MC, Robledo M, et al. Multiple hereditary infundibulocystic basal cell carcinomas: a genodermatosis different from nevoid basal cell carcinoma syndrome. *Arch Dermatol* 1999; 135: 1227–35
- Shaffelburg M, Miller R. Treatment of multiple trichoepithelioma with electrosurgery. *Dermatol Surg* 1998; 24: 1154–6

**TUMORS/MALIGNANCIES****Basal cell carcinoma***Major points*

- Appear on the face or upper body as a skin-colored papule with telangiectasias on the surface
- Seen in light-skinned individuals (skin types 1–3) with increased sun exposure

- If left untreated, basal cell carcinoma is slow growing and may ulcerate
- Rare in childhood and should suggest a syndrome: basal cell nevus syndrome (see Chapter 20), xeroderma pigmentosum (see Chapter 12), or Bazex syndrome

*Pathogenesis*

- Malignant growth arising from basal cells in patient with chronic sun exposure and genetic susceptibility
- For basal cell nevus syndrome: gene locus/gene: 9q22/PTCH1 gene

*Diagnosis*

- Biopsy necessary
- Histology: solid masses of basal cells with a large nucleus and little cytoplasm

*Differential diagnosis*

- Pilomatricoma
- Nevocellular nevus
- Trichoepithelioma
- Syringoma
- Acne vulgaris
- Tuberous sclerosis (angiofibromas)

*Treatment*

- Excision
- Radiation should be avoided in childhood
- Prophylactic avoidance of sun, use of sunscreens

*Prognosis*

- Chronic slow progression of individual lesions
- Rarely metastasize, but may be disfiguring if orbit or nasal area invaded

*References*

- Comstock J, Hansen RC, Korc A. Basal cell carcinoma in a 12-year-old boy. *Pediatrics* 1990; 86: 460–2
- Drake LA, Ceilley RI, Comelison RL, et al. (Committee on Guidelines of Care) Guidelines of care for basal cell carcinoma. *J Am Acad Dermatol* 1992; 26: 117–20
- Gaspari AA, Sauder DN. Immunotherapy of basal cell carcinoma: evolving approaches. *Dermatol Surg* 2003; 29: 1027–34
- Ledwig PA, Paller AS. Congenital basal cell carcinoma. *Arch Dermatol* 1991; 127: 1066–7

Orozco-Covarrubias M, Tamayo-Sanchez L, Duran-McKinster C, et al. Malignant cutaneous tumors in children: twenty years of experience at a large pediatric hospital. *J Am Acad Dermatol* 1994; 30: 243–9

Strayer SM, Reynolds PL. Diagnosing skin malignancy: assessment of predictive clinical criteria and risk factors. *J Fam Pract* 2003; 52: 210–18

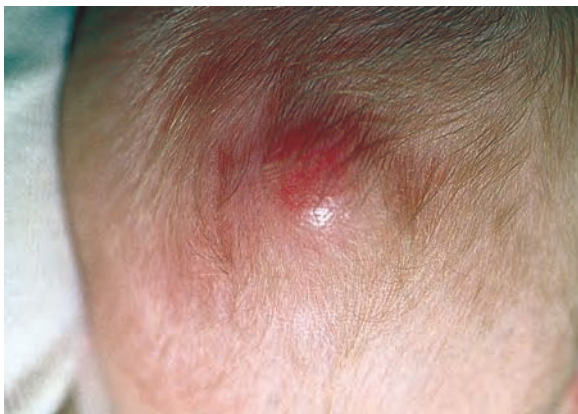Tsao H. Update on familial cancer syndromes and the skin. *J Am Acad Dermatol* 2000; 42: 939–69

Wong CS, Strange RC, Lear JT. Basal cell carcinoma. *Br Med J* 2003; 327: 794–8

## Leukemia cutis

### Major points

- Primary (specific) lesions are caused by direct invasion of leukemic cells; appear as multiple, brown-red or violaceous papules and nodules (Figure 17.32)
- Acute lymphocytic leukemia (ALL) is the most common form of childhood leukemia
  1. Peak incidence is 4 years of age
  2. Petechiae are seen in 50% of cases at the time of presentation
- Acute nonlymphocytic leukemia has myelocytic or monocytic differentiation
  1. Leukemia cutis is more common in acute monoblastic leukemia and congenital leukemias (50%)
  2. Congenital leukemia often presents with 'blueberry muffin lesions' which show on histology dermal erythropoiesis



**Figure 17.32** Leukemia cutis – large, firm, quickly growing nodule on the scalp of an infant who had acute lymphocytic leukemia

3. Other presentations:
  - a. Gingival hypertrophy
  - b. Soft tissue mass, most common in the deep soft tissues of the head and neck
4. More common in children with Fanconi anemia, Down syndrome, Bloom syndrome, ataxia telangiectasia, Wiscott–Aldrich syndrome and neurofibromatosis
- Chronic lymphocytic leukemia is rare in childhood
- Chronic nonlymphocytic leukemia
  1. Accounts for <5% of leukemias in childhood
  2. Adult form, seen in teenagers with Philadelphia chromosome
  3. Juvenile form is seen most commonly in neurofibromatosis
- Nonspecific or secondary lesions which may suggest the diagnosis:
  1. Erythematous plaques or nodules, purpura, petechiae, ecchymoses, erythema nodosum, pyoderma gangrenosum, diffuse erythroderma, Sweet syndrome

### Pathogenesis

- Uncontrolled replication of immature bone marrow cells

### Diagnosis

- Histology of a lesion of primary leukemia cutis reveals a diffuse infiltrate of leukemic cells around blood vessels and in between collagen bundles

### Differential diagnosis

- Congenital lesions: congenital infections (cytomegalovirus toxoplasmosis, other viral infections)
- Tumors
- Granuloma annulare
- Cysts

### Treatment

- Refer to pediatric oncologist
- Treatment of leukemia cures skin manifestations

### Prognosis

- Prognosis depends upon type of leukemia

### References

Baselga E, Drolet BA, Esterly NB. Purpura in infants and children. *J Am Acad Dermatol* 1997; 37: 673–705

Buescher L, Anderson PC. Circinate plaques heralding juvenile chronic myelogenous leukemia. *Pediatr Dermatol* 1990; 7: 122–5

Chang HY, Wong KM, Bosenberg M, et al. Myelogenous leukemia cutis resembling stasis dermatitis. *J Am Acad Dermatol* 2003; 49: 128–9

Grundy RG, Martinez A, Kempinski H, et al. Spontaneous remission of congenital leukemia: a case for conservative treatment. *J Pediatr Hematol Oncol* 2000; 22: 252–5

Maher-Wiese VL, Wenner NP, Grant-Kels JM. Metastatic cutaneous lesions in children and adolescents with a case report of metastatic neuroblastoma. *J Am Acad Dermatol* 1992; 26: 620–8

Millot F, Robert A, Bertrand Y, et al. Cutaneous involvement in children with acute lymphoblastic leukemia or lymphoblastic lymphoma. *Pediatrics* 1997; 100: 60–4

Pui C-H. Childhood leukemias. *N Engl J Med* 1995; 332: 1618–30

## Lymphoma

### Major points

- Lymphomas are the third most common malignancy in childhood, after leukemia and CNS tumors
- Presents as an infiltrative plaque, nodule or asymptomatic scaly dermatitis
- Most common in adults, but can be seen in children
- Cutaneous T-cell lymphoma (CTCL) (See Chapter 3)
  1. Presents with a scaly eczematous dermatitis (patch or plaque stage), poikiloderma vasculare atrophicans, or tumor nodules
  2. Indolent T-helper cell lymphoma which affects the skin primarily with late spread to lymph nodes, bone marrow and viscera
  3. Sézary syndrome manifests as a diffuse erythroderma with circulating abnormal T cells
- Hodgkin lymphoma:
  1. Occurs in adolescence; rarely before age 5 years
  2. Usual presentation is painless lymphadenopathy in the neck
  3. Male/female ratio >1
  4. Skin manifestations rare (e.g. papules, tumors, ulcerated nodules), but seen in advanced disease which has failed aggressive chemotherapy and radiation
- 5. Secondary signs: pruritus, acquired ichthyosis and herpes zoster
- B-cell lymphomas:
  1. Painless enlarging lymphadenopathy most common
  2. Rapidly growing and poorly differentiated
  3. Cutaneous lesions: papules or nodules which may ulcerate and form arcuate lesions
  4. Common location: scalp

### Pathogenesis

- Anaplasia of B or T cells

### Diagnosis

- Biopsy of tissue confirms and differentiates the diagnosis

### Differential diagnosis

- Pseudolymphoma
- Persistent insect bite reaction
- Granuloma annulare
- Lymphomatoid papulosis
- Follicular mucinosis

### Treatment

- Depends upon type of lymphoma
- CTCL is treated with psoralen plus ultraviolet light A (PUVA) or topical nitrogen mustard or, for a single plaque, ultrapotent steroids

### Prognosis

- Depends upon the type of lymphoma
- CTCL has a good prognosis, but requires life-long observation and therapy

### References

- Burg G, Kempf W, Haeflner AC, et al. Cutaneous lymphomas. *Curr Prob Dermatol* 1997; 9: 137–204
- Jones D, Duvic M. The current state and future of clonality studies in mycosis fungoides. *J Invest Dermatol* 2003; 121: ix–x
- Maher-Wiese VL, Wenner NP, Grant-Kels JM. Metastatic cutaneous lesions in children and adolescents with a case report of metastatic neuroblastoma. *J Am Acad Dermatol* 1992; 26: 620–8
- Orozco-Covarrubias ML, Tamayo-Sanchez L, Duran-McKinster C, et al. Malignant cutaneous tumors in children. *J Am Acad Dermatol* 1994; 30: 243–9



Querfeld C, Rosen ST, Kuzel TM, Guitart J. Cutaneous T-cell lymphomas: a review with emphasis on new treatment approaches. *Semin Cutan Med Surg* 2003; 22: 150–61

Sandlund JT, Downing JR, Crist WM. Non-Hodgkin's lymphoma in childhood. *N Engl J Med* 1996; 334: 1238–48

Shani-Adir A, Lucky AW, Prendiville J, et al. Subcutaneous panniculitic T-cell lymphoma in children: response to combination therapy with cyclosporine and chemotherapy. *J Am Acad Dermatol* 2004; 50 (2 Suppl): S18–22

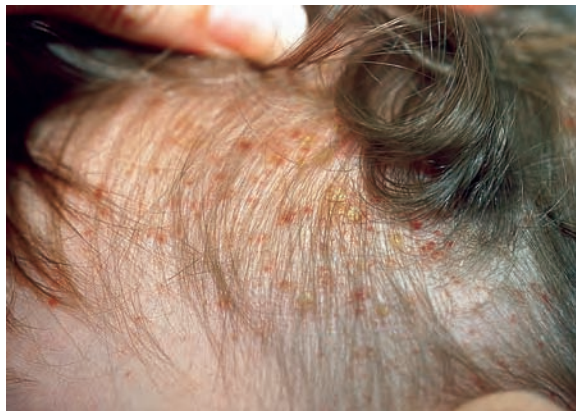Thorley-Lawson DA, Gross A. Persistence of the Epstein-Barr virus and the origins of associated lymphomas. *N Engl J Med* 2004; 350: 1328–37

Zackheim HS, Vonderheid EC, Ramsay DL, et al. Relative frequency of various forms of primary cutaneous lymphomas. *J Am Acad Dermatol* 2000; 43: 793–6

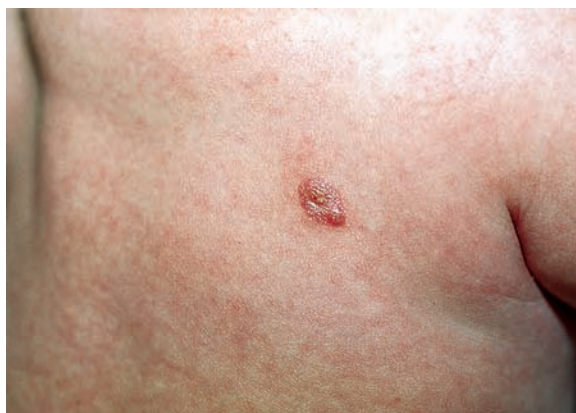## Histiocytosis

### Major points

- Histiocytoses includes a group of benign and fatal disorders which may be manifested in a variety of ways
- Langerhans cell histiocytosis (LCH) was traditionally separated into the following groups, but these are now included under the heading of LCH:
  1. Eosinophilic granuloma (localized bony lesions)
  2. Hand-Schuller-Christian disease (multiple organ involvement with skull defects, diabetes insipidus and exophthalmos)
  3. Letterer-Siwe disease (visceral lesions in lungs, lymph nodes, liver, spleen, bone marrow and skin)
- Letterer-Siwe disease is most common
  1. Peak incidence occurs between 1 and 4 years, but can occur at any age
  2. Discrete yellow-brown scaly papules which coalesce in the seborrheic areas (e.g. diaper area, postauricular area, scalp, etc.) and may show petechiae (Figure 17.33)
  3. Other involvement
    - a. Bone lesions: lytic lesions (typical in skull), proptosis, mastoid involvement and others
    - b. Lymph nodes
    - c. Bone marrow (pancytopenia)
    - d. Liver enlargement
    - e. Spleen enlargement
    - f. Lungs
    - g. GI tract
    - h. Thymic enlargement
    - i. Endocrine glands (diabetes insipidus, anterior pituitary involvement with growth hormone deficiency)
    - j. CNS involvement rare (intracranial hypertension, seizures)
- Other forms of histiocytosis:
  1. Self-healing reticulohistiocytosis presents with papules and nodules that frequently ulcerate at birth (Figure 17.34)
  2. Benign cephalic histiocytosis: 2–5-mm yellow-red papules on the face and neck in a child <1 year of age (non-Langerhans cell histiocytosis)



**Figure 17.33** Langerhans cell histiocytosis – keratotic hemorrhagic papules resembling seborrheic dermatitis



**Figure 17.34** Self-healing histiocytosis – isolated congenital papule



### *Pathogenesis*

- Clonal neoplastic disorder of Langerhans cells (monocyte/macrophage which contains Birbeck granules; expresses CD1 glycoprotein)

### *Diagnosis*

- Biopsy necessary for confirmation of diagnosis
- Histology: histiocytes with clear or eosinophilic cytoplasm and indented nuclei, macrophages, lymphocytes and other cells; stains positive for CD1a and S100 protein
- Electron microscopy demonstrates Birbeck granules in LCH

### *Differential diagnosis*

- Seborrhea
- Eczema
- Scabies
- Irritant diaper dermatitis
- Mastocytosis
- Juvenile xanthogranuloma

### *Treatment*

- Refer to pediatric hematologist/oncologist
- Therapy depends upon the extent of involvement of disease and location of infiltrates
- In milder cases, observation may be indicated
- For extensive disease, chemotherapy (e.g. corticosteroids, vinblastine or etoposide)
- Skin lesions may respond to topical steroids, topical nitrogen mustard or PUVA

### *Prognosis*

- Depends upon age of patient at diagnosis (younger patients have poorer prognosis), extent of disease and rate of disease progression

### *References*

- Bhatia S, Nesbit ME, Egeler RM, et al. Epidemiologic study of Langerhans cell histiocytosis in children. *J Pediatr* 1997; 130: 774–84
- Egeler RM, D'Angio GJ. Langerhans cell histiocytosis. *J Pediatr* 1995; 127: 1–11
- Kilborn TN, Teh J, Goodman TR. Paediatric manifestations of Langerhans cell histiocytosis: a review of the clinical and radiological findings. *Clin Radiol* 2003; 58: 269–78
- Seward JL, Malone JC, Callen JP. Generalized eruptive histiocytosis. *J Am Acad Dermatol* 2004; 50: 116–20

Shani-Adir A, Chou P, Morgan E, Mancini AJ. A child with both Langerhans and non-Langerhans cell histiocytosis. *Pediatr Dermatol* 2002; 19: 419–22

Snow JL, Su WPD. Histiocytic disease. *J Am Acad Dermatol* 1995; 33: 111–16

Willman CL, Busque L, Griffith BB, et al. Langerhans'-cell histiocytosis (histiocytosis X) – a clonal proliferative disease. *N Engl J Med* 1994; 331: 154–60

## **Rhabdomyosarcoma**

### *Major points*

- Most common malignant soft-tissue tumor in childhood
- Causes 5% of childhood solid malignancies
- Peak ages: 1–5 years and adolescence
- Predilection for the head and neck region, genitourinary tract, the retroperitoneum and soft tissues of the extremities
- Local signs of destruction may occur with progression of the lesion
- May spread by local extension or lymphatic/hematogenous metastases
- Sporadic inheritance

### *Pathogenesis*

- Malignant tumor of striated muscles

### *Diagnosis*

- Histology: composed of small round cells, spindle or polygonal cells or large pleomorphic cells; variants: embryonal (including botryoid variant), alveolar, pleomorphic
- Immunoperoxidase stains positive for vimentin, desmin, myoglobin and muscle actin

### *Differential diagnosis*

- Epidermal cyst
- Lymphangioma
- Leukemia cutis
- Other tumors
- Infectious (fasciitis)

### *Treatment*

- Refer to hematologist/oncologist
- Radiation and combination chemotherapy followed by surgical excision

### Prognosis

- Determined by extent and location of disease

### References

- Brecher AR, Reyes-Mugica M, Kamino H, Chang MW. Congenital primary cutaneous rhabdomyosarcoma in a neonate. *Pediatr Dermatol* 2003; 20: 335–8
- Pisick E, Skarin AT, Salgia R. Recent advances in the molecular biology, diagnosis and novel therapies for various small blue cell tumors. *Anticancer Res* 2003; 23: 3379–96
- Herzog CE, Stewart JM, Blakely ML. Pediatric soft tissue sarcomas. *Surg Oncol Clin North Am* 2003; 12: 419–47
- Sebire NJ, Malone M. Myogenin and MyoD1 expression in paediatric rhabdomyosarcomas. *J Clin Pathol* 2003; 56: 412–16

## Neuroblastoma

### Major points

- Second most common solid tumor malignancy in childhood
- Usually presents before age 5 years with an enlarging mass in the upper abdomen or retroperitoneal space
- Cutaneous lesions are uncommon outside the neonatal period
- Metastatic disease occurs early and frequently
- Cutaneous metastases appear as multiple 2 mm to 2 cm bluish papules or nodules scattered over the body ('blueberry muffin' appearance) which tend to blanch centrally and develop an erythematous halo 2–3 minutes after stroking, which lasts about 1 hour, resulting from local tumor catecholamine release causing vasoconstriction
- Metastatic cutaneous lesions common on the trunk and extremities, but can be anywhere on the body
- Bilateral periorbital ecchymoses, described as 'raccoon eyes' (from orbital metastases)
- Heterochromia irides
- Nonspecific signs and symptoms include: fever, weight loss, flushing, sweating, joint pains and others
- Occurrence is usually sporadic but may be autosomal dominant
- Male/female ratio = 1

### Pathogenesis

- Tumor of primitive neural crest cells of the sympathetic nervous system in the adrenal medulla, sympathetic side chain, visceral ganglia, paraganglia, bladder, or genitalia. Tumors can be seen anywhere these cells migrate

### Diagnosis

- Histology: dermal or subcutaneous infiltrate of small blue cells with large nuclei, mitoses, hemorrhage
- Staging important to determine treatment and prognosis
- Laboratory findings: elevated levels of urinary catecholamines or their metabolites (vanillylmandelic acid and homovanillic acid)

### Differential diagnosis

- Leukemia cutis
- Sarcomas
- Lymphoma
- Child abuse ('raccoon eyes')
- Congenital infections (TORCH and other 'blueberry-muffin' syndromes)
- Vascular tumors
- Histiocytosis

### Treatment

- Refer to pediatric oncologist and pediatric surgeon

### Prognosis

- Staging, classification and prognosis determined by tumor burden, nodal involvement and distant metastases
  1. Stages I and II have 60–80% 2-year survival rate
  2. Stages III and IV have 7–13% 2-year survival rate
  3. Stage IV-S has 60–90% survival rate

### References

- Dominey AM, Hawkins H, Levy ML. Congenital cutaneous and subcutaneous nodules. *Pediatr Dermatol* 1992; 9: 301–3
- Lee KL, Ma JF, Shortliffe LD. Neuroblastoma: management, recurrence, and follow-up. *Urol Clin North Am* 2003; 30: 881–90
- Maher-Wiese VL, Wenner NP, Grant-Kels JM. Metastatic cutaneous lesions in children and adolescents with a case report of metastatic neuroblastoma. *J Am Acad Dermatol* 1992; 26: 620–8

---

Matthay KK. Neuroblastoma: a clinical challenge and biologic puzzle. *Cancer J Clin* 1995; 45: 179–92

Moore SW, Satge D, Sasco AJ, et al. The epidemiology of neonatal tumours. Report of an international working group. *Pediatr Surg Int* 2003; 19: 509–19

Weinstein JL, Katzenstein HM, Cohn SL. Advances in the diagnosis and treatment of neuroblastoma. *Oncologist* 2003; 8: 278–92





# HAIR DISORDERS

## Major points

- Alopecia: general term for sparseness of hair
- Loss of 25–50% of scalp hair is necessary for diffuse loss to be clinically noticeable in most people
- Scalp has ~100 000–150 000 hairs
- Anagen and telogen hairs randomly distributed
- Growth rate 0.3–0.4 mm/day (1 cm/month)
  - a. Depends upon site (vertex faster than temples)
- Normal hair growth is cyclical
  1. Anagen phase
    - a. Active growth phase
    - b. Lasts ~2–6 years
    - c. 80–90% of scalp hairs
    - d. Shiny, white sheath near proximal end
    - e. Pigmented bulb
  2. Catagen phase
    - a. Transitional phase
    - b. 5% of scalp hairs
    - c. Lasts few days to 2 weeks
  3. Telogen phase
    - a. Resting phase
    - b. Lasts ~100 days (2–4 months)
    - c. 10–15% of scalp hairs
    - d. Club-shaped root
    - e. Depigmented terminal bulbs

## Diagnosis

- Classification of non-scarring alopecia (See Table 18.1)
- Evaluation of hair loss in childhood (See Table 18.2)

## References

Ahmad W, Panteleyev A, Christiano AM. Molecular basis of congenital atrichia in humans and mice. *Cutis* 1999; 64: 269–76

Messenger AG. The control of hair growth: an overview. *J Invest Dermatol* 1993; 101: 4S–9S

Miller J, Djabali K, Chen T, et al. Atrichia caused by mutations in the vitamin D receptor gene is a phenocopy of generalized atrichia caused by mutations in the hairless gene. *J Invest Dermatol* 2001; 117: 612–17

Milner Y, Sudnik J, Filippi M, et al. Exogen, shedding phase of the hair growth cycle: characterization of a mouse model. *J Invest Dermatol* 2002; 119: 639–44

Paus R, Christoph T, Muller-Rover S. Immunology of the hair follicle: a short journey into terra incognita. *Invest Dermatol Symp* 1999; 4: 226–34

Paus R, Cotsarelis G. The biology of hair follicles. *N Engl J Med* 1999; 341: 491–7

Shapiro J, Price VH. Hair regrowth. Therapeutic agents. *Dermatol Clin* 1998; 16: 341–56

Sperling LC. Evaluation of hair loss. *Curr Prob Dermatol* 1996; 8: 97–136

**Table 18.1 Types of non-scarring hair loss**

Telogen effluvium
Anagen effluvium
Alopecia areata
Androgenetic alopecia
Hair shaft abnormalities
Trauma
Infectious disorders (e.g. dermatophytes, syphilis)
Systemic disease (e.g. thyroid disease, systemic lupus erythematosus, iron deficiency anemia)
Intoxications (e.g. vitamin A, bismuth)
Nutritional deficiencies (e.g. zinc, biotin)
Medications

Tobin DJ, Slominski A, Botchkarev V, Paus R. The fate of hair follicle melanocytes during the hair growth cycle. *Invest Dermatol Symp Proc* 1999; 4: 323–32

**Table 18.2 Evaluation of hair loss in childhood**

### *History*

Duration of loss  
Rate of shedding  
Breakage versus falling out from roots  
Drug intake  
Hair care  
Trauma  
General health, developmental history  
Family history of hair disorders  
Symptoms (pruritus, etc.)  
Pregnancy

### *Physical examination*

Scalp examination: scarring versus nonscarring  
Hair texture, length, color  
Pattern and distribution of loss; diffuse versus patchy  
Tips tapered versus broken ends  
General hair distribution  
Teeth, nails, sweating abnormalities  
Mentation  
Other anomalies

### *Useful procedures*

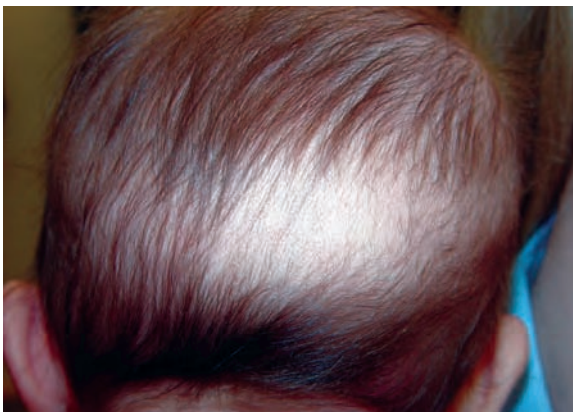Hair pull: 30–50 hairs grasped between thumb and forefinger with firm, steady traction applied along the lengths of the hairs; 2–5 telogen hairs – normal; >6 hairs extracted considered abnormal  
Hair pluck: forcefully extracting ~50 hairs from the scalp by clamping hairs about 1 cm from skin surface with a rubber coated hemostat and pulling  
Microscopic examination: anagen versus telogen hairs  
KOH preparation  
Fungal, bacterial cultures  
Scalp biopsy  
Laboratory evaluation: complete blood count, thyroxine, thyroid stimulating hormone, rapid plasma reagin, serum iron, dehydroepiandrosterone sulfate, free testosterone

## CONGENITAL ALOPECIA: LOCALIZED

### Occipital alopecia

#### *Major points*

- Normal process
- Common disorder in first year
- Well-defined patch of alopecia with broken hairs over occiput (Figure 18.1)



**Figure 18.1** Occipital alopecia – this common patchy hair loss occurs in infants in the first year of life

#### *Pathogenesis*

- Lanugo hairs on posterior scalp shed at ~8–12 weeks of age, then replaced with normal anagen hairs

#### *Diagnosis*

- Clinical diagnosis

#### *Differential diagnosis*

- Alopecia areata
- Hair shaft disorders

#### *Treatment*

- None needed

#### *Prognosis*

- Excellent

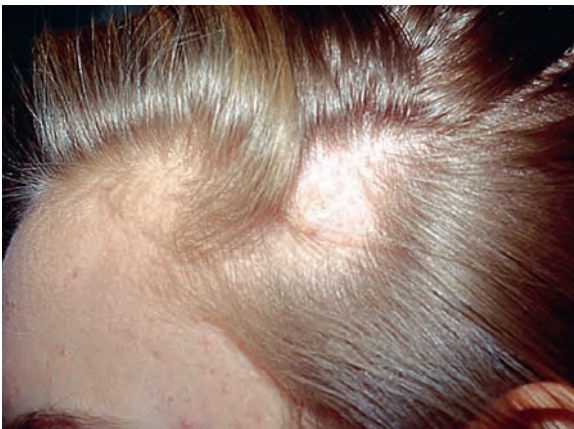#### *References*

Olsen EA. Hair loss in childhood. In *Disorders of Hair Growth*. Olsen EA, ed. McGraw-Hill: New York, 1994: 139–88

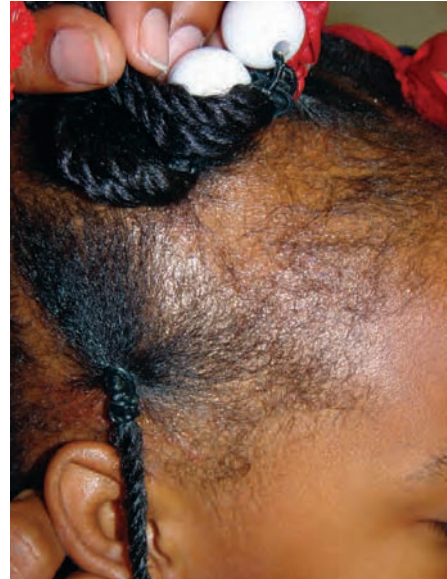## Patchy alopecia

### Major points

- Aplasia cutis congenita: irregularly shaped erosion which leads to scarring or oval patch covered by membrane (see Chapter 2)
- Melanocytic nevus: associated with hyper- or hypotrichosis
- Hemangioma of infancy: after resolution, may have localized alopecia
- Nevus sebaceus: linear or oval patch of alopecia with yellowish papules (see Chapter 17)
- Epidermal or organoid nevi: linear, grouped, verrucous papules
- Temporal triangular alopecia (Figure 18.2)
  1. Well-circumscribed triangular or lance-shaped area of alopecia at the temple
  2. Appears at 2–5 years of age; unilateral (80%) or bilateral
  3. Vellus hairs present; occasionally a few terminal hairs
  4. Erroneously thought to be from forceps delivery
- Cranial meningoceles, encephaloceles, heterotopic brain tissue: can be surrounded by collar of thick hair (called 'hair collar sign')
- Birth trauma (forceps) from pressure on hair follicles
- Rare syndromes with patchy hair loss
  1. Conradi–Hünemann syndrome
  2. Goltz syndrome



**Figure 18.2** Triangular alopecia – congenital and familial patch of alopecia usually over one or both temples



**Figure 18.3** This type of hair loss resembles triangular alopecia but is caused by styling practices where the hair is pulled tightly into braids

3. Hallerman–streiff syndrome
  4. CHILD syndrome
- Causes of scarring alopecia (Table 18.4)

### References

- Armstrong DKB, Burrows D. Congenital triangular alopecia. *Pediatr Dermatol* 1996; 13: 394–6
- Elmer KB, George RM. Congenital triangular alopecia: a case report and review. *Cutis* 2002; 69: 255–6
- Garcia-Hernandez MJ, Rodriguez-Pichardo A, Camacho F. Congenital triangular alopecia (Brauer nevus). *Pediatr Dermatol* 1995; 12: 301–3
- Trakimas C, Sperling LC, Skelton HG, et al. Clinical and histologic findings in temporal triangular alopecia. *J Am Acad Dermatol* 1994; 31: 205–9

## CONGENITAL ALOPECIA: DIFFUSE

### Early-onset diffuse alopecia

#### Major points

- Causes:
  1. Metabolic disorders/nutritional deficiencies
    - a. Acrodermatitis enteropathica (zinc deficiency)

- b. Biotin deficiency
- c. Essential fatty acid deficiency
- d. Amino acid disorders
- 2. Congenital alopecia universalis
- 3. Loose anagen syndrome
- 4. Hair shaft defects
- 5. Genetic syndromes
  - a. KID syndrome
  - b. Trichorhinophalangeal syndrome

## References

Ahmad W, Panteleyev AA, Christiano AM. The molecular basis of congenital atrichia in humans and mice: mutations in the hairless gene. *Invest Dermatol Symp Proc* 1999; 4: 240–3

Cambiaghi S, Barbareschi M. A sporadic case of congenital hypotrichosis simplex of the scalp: difficulties in diagnosis and classification. *Pediatr Dermatol* 1999; 16: 301–4

Carrington PR, Chen H, Altick JA. Trichorhinophalangeal syndrome, type I. *J Am Acad Dermatol* 1994; 31: 331–6

Ludecke H-J, Wagner MJ, Nardmann J, et al. Molecular dissection of a contiguous gene syndrome: localization of the genes involved in the Langer–Giedion syndrome. *Hum Mol Genet* 1995; 4: 31–6

Nardmann J, Tranebjaerg L, Horsthemke B, Ludecke H-J. The tricho-rhino-phalangeal syndromes: frequency and parental origin of 8q deletions. *Hum Genet* 1997; 99: 638–43

Roberts JL, Whiting DA, Henry D, et al. Marie Unna congenital hypotrichosis: clinical description, histopathology, scanning electron microscopy of a previously unreported large pedigree. *Invest Dermatol Symp Proc* 1999; 4: 261–7

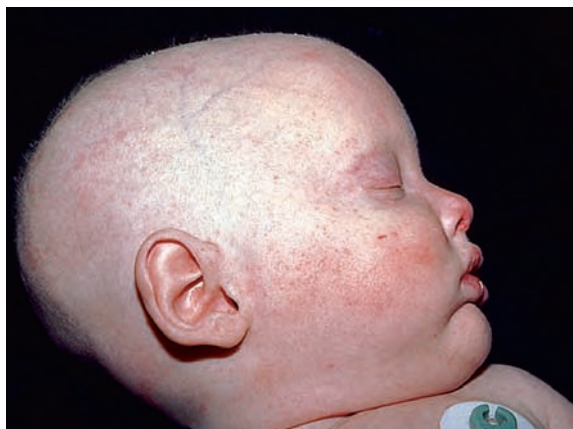Zlotogorski A, Hochberg Z, Mirmirani P, et al. Clinical and pathologic correlations in genetically distinct forms of atrichia. *Arch Dermatol* 2003; 139: 1591–6

## Ectodermal dysplasia (hypohidrotic/anhidrotic)

Synonym: anhidrotic ectodermal dysplasia, Christ–Siemens–Touraine syndrome

### Major points

- Presents at birth
- Hair-fine, sparse, light and twisted terminal hairs and eyebrows; may thicken at puberty (Figure 18.4)
- Sweat glands – partial or complete absence with heat intolerance; sweat pores absent on visual inspection of fingertips



**Figure 18.4** Hypohidrotic ectodermal dysplasia – newborn with absence of hair

- Teeth – hypodontia, anodontia, and conical incisors
- Nails – normal or brittle, thin, ridged
- Characteristic facies
  1. Thick, everted lips
  2. Frontal bossing
  3. Large, pointed ears
  4. Saddle nose
  5. Maxillary hypoplasia
- Other findings
  1. Frequent bronchitis and pneumonia
  2. Recurrent otitis media, impacted cerumen
  3. Hoarse voice
  4. Failure to thrive (20%)
  5. Unexplained fever in infancy and childhood
  6. Poorly developed mucous glands in respiratory and gastrointestinal tract
  7. Periorbital hyperpigmentation
  8. Skin – soft, dry, finely wrinkled
  9. X-linked recessive
  10. Increased frequency of atopic dermatitis

### Pathogenesis

- Gene locus: Xq12-q13.1
- Gene: ectodysplasin-A (ED1)

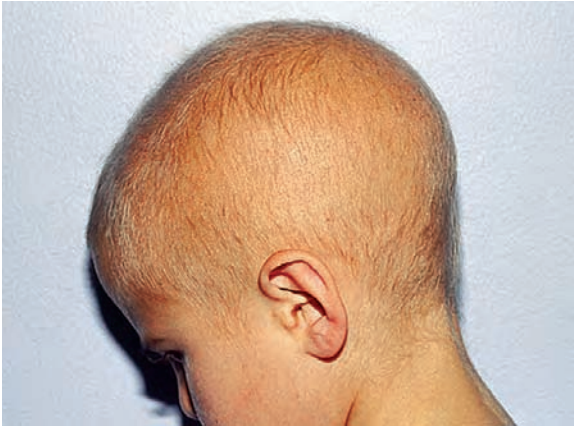### Diagnosis

- Clinical presentation

### Differential diagnosis

- Other (Figure 18.5)





**Figure 18.5** Isolated scalp hypotrichosis – with no other ectodermal defects

### Treatment

- Environmental control for temperature stability: air conditioning or specialized cooling units
- Dental consultation for abnormal teeth, with dentures and dental implants
- Hair appliances (wigs) if necessary
- Treatment of infections as needed
- National Foundation for Ectodermal Dysplasias ([www.nfed.org](http://www.nfed.org))

### Prognosis

- Good with close supervision
- Increased mortality in infancy

### References

- Aswegan AL, Josephson KD, Mowbray R, et al. Autosomal dominant hypohidrotic ectodermal dysplasia in a large family. *Am J Med Genet* 1997; 72: 462–7
- Azon-Masoliver A, Ferrando J. Loose anagen hair in hypohidrotic ectodermal dysplasia. *Pediatr Dermatol* 1996; 13: 29–32
- Cambiaghi S, Restano L, Paakkonen K, et al. Clinical findings in mosaic carriers of hypohidrotic ectodermal dysplasia. *Arch Dermatol* 2000; 136: 217–24
- Dahan D, Fenichel GM, El-Said R. Neurocutaneous syndromes. *Adolesc Med State Art Rev* 2002; 13: 495–509
- Hummel P, Guddack S. Psychosocial stress and adaptive functioning in children and adolescents suffering from hypohidrotic ectodermal dysplasia. *Pediatr Dermatol* 1997; 14: 180–5
- Lamartine J. Towards a new classification of ectodermal dysplasias. *Clin Exp Dermatol* 2003; 28: 351–5

Wisniewski SA, Kobiela A, Trzeciak WH, Kobiela K. Recent advances in understanding of the molecular basis of anhidrotic ectodermal dysplasia: discovery of a ligand, ectodysplasin A and its two receptors. *J Appl Genet* 2002; 43: 97–107

## Ectodermal dysplasia (hidrotic)

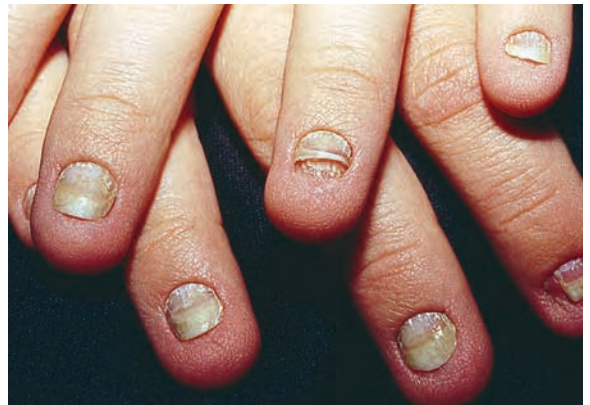Synonym: Clouston syndrome

### Major points

- Generalized hypotrichosis (sparse, fine, blond, wiry, brittle hair); hair loss may be progressive
- Nail dystrophy: nails may be white in early childhood; thickened nails; slow growth; paronychia infections (Figure 18.6)
- Hyperkeratosis of the palms and soles with pebbling on the fingertips, which increases with age
- Teeth – normal
- Mild mental retardation or normal mentation
- Sweating normal
- Conjunctivitis
- Blepharitis possible secondary to absence of protection from eyelashes
- More common in French Canadian families
- Autosomal dominant

### Pathogenesis

- Gene locus: 13q12
- Gene: GJB6 (gap junction protein) which encodes CX30 (connexin-30)



**Figure 18.6** Hidrotic ectodermal dysplasia – small nails with pebbling of fingertips in a patient with hypotrichosis



### Diagnosis

- Clinical presentation
- Histology: orthohyperkeratosis of palms and soles with normal granular layer
- Abnormal hair with nonspecific narrowing and fraying

### Differential diagnosis

- Other ectodermal dysplasias
- Ankyloblepharon ectodermal dysplasia clefting (AEC) syndrome
- Pachyonychia congenita

### Treatment

- Hair appliance (wig) if necessary

### Prognosis

- Hair and nail abnormalities permanent

### References

Chitty LS, Dennis N, Baraitser M. Hidrotic ectodermal dysplasia of hair, teeth, and nails: case reports and review. *J Med Genet* 1996; 33: 707–10

Hayflick SJ, Taylor T, McKinnon W, et al. Clouston syndrome (hidrotic ectodermal dysplasia) is not linked to keratin gene clusters on chromosomes 12 and 17. *J Invest Dermatol* 1996; 107: 11–14

Lamartine J, Essenfelder GM, Kibar Z, et al. Mutations in GJB6 cause hidrotic ectodermal dysplasia. *Nature Genet* 2000; 26: 142–4

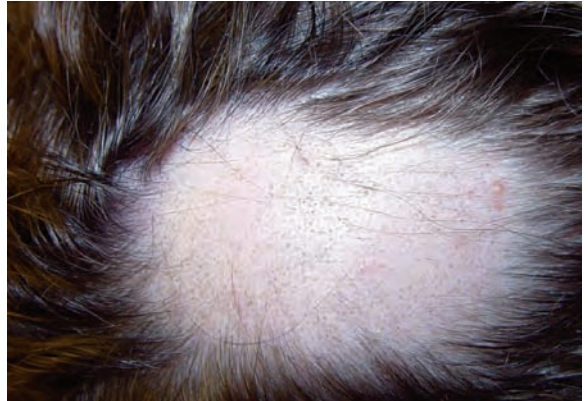
Priolo M, Silengo M, Lerone M, Ravazzolo R. Ectodermal dysplasias: not only 'skin' deep. *Clin Genet* 2000; 58: 415–30

## ACQUIRED NON-SCARRING ALOPECIA

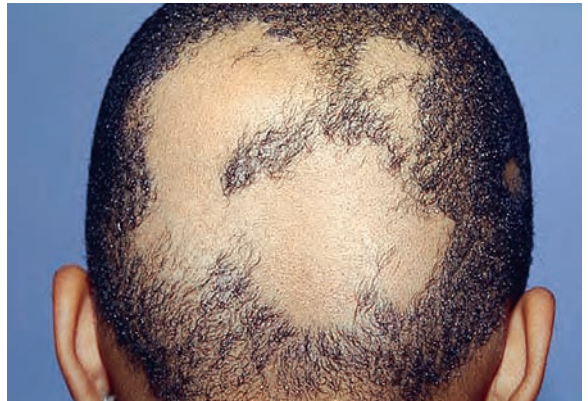### Alopecia areata

#### Major points

- Common disorder
- Incidence: 17 per 100 000 population per year
- 24–50% begins at age <16 years
- Male/female ratio = 1
- Family history found in ~10–20%
- Sudden onset of asymptomatic well-defined oval or round patches of hair loss (Figures 18.7 and 18.8)
- Location



**Figure 18.7** Alopecia areata – sudden loss of hair with exclamation point hairs appearing as broken-off hairs along the periphery



**Figure 18.8** Alopecia areata – patchy, smooth hair loss of sudden onset

1. Alopecia areata – patchy hair loss
  2. Alopecia totalis – loss of entire scalp hair with retention of other hair
  3. Alopecia universalis – loss of all body hair
  4. Can occur in any hair-bearing area: scalp, eyebrows, eyelashes, beard, body hair
  5. Ophiasis region – along the nape of the neck
- Characteristic exclamation point hairs: hairs that taper as they approach the scalp
  - Regrowth hair often depigmented initially
  - Nail changes in 10–44%
    1. Fine grid-like pitting, regularly arranged in horizontal or vertical rows
    2. Trachyonychia (rough sandpaper nails)
  - Associated with: thyroid disease, vitiligo and other autoimmune disorders

- Increased incidence in Down syndrome
- Atopy seen in 10–22% of cases

### *Pathogenesis*

- Etiology unknown, generally thought to be an autoimmune disorder
- Histology
  1. Perifollicular lymphocytic infiltrate surrounding hair bulbs resembling a 'swarm of bees'
  2. Infiltrate: activated T lymphocytes with macrophages and Langerhans cells
  3. Reduction in anagen : telogen ratio
  4. Miniaturized dystrophic hairs

### *Diagnosis*

- Clinical appearance
- Hair pull test positive in active areas, especially at periphery of patch with increased number of telogen hairs and dystrophic anagen hairs

### *Differential diagnosis*

- Telogen effluvium
- Trichotillomania
- Androgenetic alopecia
- Syphilis (secondary)
- Tinea capitis

### *Treatment*

- Treatments only control the problem
- Treatments should be used for a long time (minimum 3–6 months) because of the chronic nature of the disease
- Patient education and psychological support
- Corticosteroids
  1. Topical: mid- to ultrapotent steroids BID
  2. Intralesional: triamcinolone acetonide 2.5–5 mg/ml administered with 30-gauge needle with multiple intradermal injections of 0.1 ml per site, approximately 1 cm apart; maximum total 3 ml on scalp per visit; repeat every 4–6 weeks until improvement seen
  3. Systemic steroids: recommended for extensive cases with sudden onset; high relapse rate
    - a. Prednisone 20–40 mg/day with tapering by 5 mg /week for 4–6 weeks followed by alternate day therapy, and slow tapering with eventual discontinuation

- Topical irritants
  1. Anthralin 0.25–1% cream, applied overnight or as short contact therapy, initially for 30 minutes and gradually increasing to 1 hour. Mild dermatitis is desired for a therapeutic effect
- Topical sensitizers
  1. Squaric acid dibutyl ester (SADBE) or diphenylcyclopropanone (DPCP): sensitization of the skin with resultant contact allergic reaction, followed by repeated treatments of the low-dose agent to maintain a low-grade allergic reaction. Response should be seen after 12 weeks
- Topical minoxidil 2–5% applied BID
- PUVA: psoralen taken orally or applied topically followed by UVA irradiation; administered 2–3 times per week; not recommended for children aged <10 years
- Wig (prosthesis)
- Support group: National Alopecia Areata Foundation

Web site: [www.alopeciaareata.com](http://www.alopeciaareata.com)

### *Prognosis*

- Variable and unpredictable
- Course recurrent in ~50%
- Natural history: spontaneous remissions and recurrences
- Limited involvement: prognosis good with growth in 1 year seen in 95%
- 7–10% develop severe chronic form
- Prognosis worse if there is:
  1. Early onset
  2. Ophiasis pattern
  3. Atopy
  4. Nail dystrophy
  5. Long duration
  6. Presence of other autoimmune diseases
  7. Family history
  8. Extensive hair loss

### *References*

- Bodemer C, Peuchmaur M, Fraitaig S, et al. Role of cytotoxic T cells in chronic alopecia areata. *J Invest Dermatol* 2000; 114: 112–16
- Cotelless C, Peris K, Caracciolo E, et al. The use of topical diphenylcyclopropanone for the treatment of extensive alopecia areata. *J Am Acad Dermatol* 2001; 44: 73–6

Freyschmidt-Paul P, Happle R, McElwee KJ, Hoffmann R. Alopecia areata: treatment of today and tomorrow. *J Invest Dermatol Symp Proc* 2003; 8: 12–17

Hoffmann R. The potential role of cytokines and T cells in alopecia areata. *Invest Dermatol Symp Proc* 1999; 4: 235–8

Madani S, Shapiro J. Alopecia areata update. *J Am Acad Dermatol* 2000; 42: 549–66

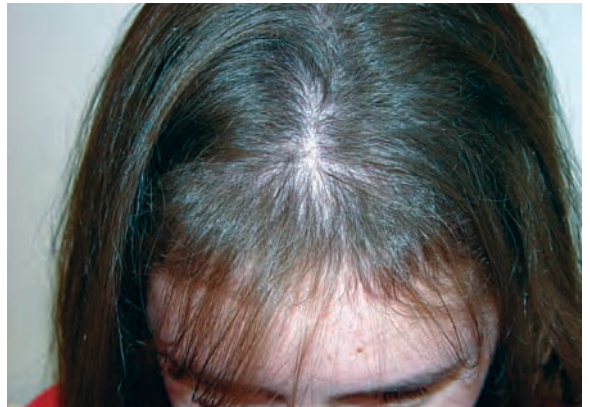McElwee KJ, Freyschmidt-Paul P, Sundberg JP, Hoffmann R. The pathogenesis of alopecia areata in rodent models. *J Invest Dermatol Symp Proc* 2003; 8: 6–11

Olsen E, Hordinsky M, McDonald-Hull S, et al. Alopecia areata investigations assessment guidelines. *J Am Acad Dermatol* 1999; 40: 242–6

Sehgal VN, Jain S. Alopecia areata: clinical perspective and an insight into pathogenesis. *J Dermatol* 2003; 30: 271–89

Tosti A, Guidetti MS, Bardazzi R, Misciali C. Long-term results of topical immunotherapy in children with alopecia totalis or alopecia universalis. *J Am Acad Dermatol* 1996; 35: 199–201

Whiting DA. Histopathologic features of alopecia areata. *Arch Dermatol* 2003; 139: 1555–9



**Figure 18.9** Telogen effluvium – caused by severe, febrile illness with obvious regrowth of anagen hairs at the periphery of the scalp

## Telogen effluvium

### Major points

- Common type of hair loss
- Sparse diffuse loss of scalp hair (Figure 18.9)
- Hallmark: excessive shedding of telogen hairs caused by altered growth cycle
- Occurs 6 weeks to 4 months after inciting event
- Lasts 6–24 weeks
- Regrowth within 6 months

### Pathogenesis

- Abnormally large shift from anagen to telogen hairs within a short period of time
- Instead of 10% hairs in telogen (normal), there are 30–50% in telogen
- Etiologies:
  1. Drugs: anticonvulsants, anticoagulants, angiotensin-converting enzyme (ACE) inhibitors,  $\beta$ -blockers, interferons, lithium, oral contraceptive pills (during or after discontinuation), retinoids, excessive vitamin A
  2. Febrile or systemic illness
  3. Crash diets
  4. Postpartum
  5. Major surgical procedures, anesthesia

6. Endocrine disorders: hypo- or hyperthyroidism
7. Severe emotional stress
8. Deficiencies: iron, zinc, biotin
9. Physiologic effluvium of the newborn

### Diagnosis

- History very helpful
- Hair pull or pluck: increased telogen hairs up to 50% of hairs
- If precipitating factor not found, consider doing: complete blood count (CBC), chemistry profile, serum iron, thyroid studies

### Differential diagnosis

- Kwashiorkor
- Acrodermatitis enteropathica
- Celiac disease

### Treatment

- Patient education as to cause and prognosis, with reassurance
- Gentle hair care: avoid manipulation, vigorous shampooing, combing, brushing

### Prognosis

- Complete regrowth within 6 months if precipitating factor eliminated

### References

Ben-Amitai D, Garty BZ. Alopecia in children after cardiac surgery. *Pediatr Dermatol* 1993; 10: 32–33

Chartier MB, Hoss DM, Grant-Kels JM. Approach to the adult female patient with diffuse nonscarring alopecia. *J Am Acad Dermatol* 2002; 47: 809–18

Harrison S, Sinclair R. Telogen effluvium. *Clin Exp Dermatol* 2002; 27: 389–5

Headington JT. Telogen effluvium. *Arch Dermatol* 1993; 129: 356–63

Pillans PI, Woods DJ. Drug-associated alopecia. *Int J Dermatol* 1995; 34: 149–58

Rebora A. Telogen effluvium: an etiopathogenetic theory. *Int J Dermatol* 1993; 32: 339–40

Sperling LC. Hair and systemic disease. *Dermatol Clin* 2001; 19: 711–26

## Anagen effluvium

### Major points

- Inhibition of anagen hair-matrix metabolism with resultant hair loss
- Since >80% of scalp hair is normally in anagen, hair loss is marked
- Hairs shed in growing (anagen) phase
- Rapid loss of majority of scalp hair

### Pathogenesis

- Chemotherapeutic agents
- Radiation
- Toxins: thallium, boric acid, arsenic, mercury

### Diagnosis

- History very helpful
- Hair pull: 'pencil point' dystrophic hairs with proximal tips tapering to a point
- Hair pluck: anagen and telogen hairs

### Differential diagnosis

- Telogen effluvium
- Alopecia totalis
- Loose anagen syndrome

### Treatment

- Discontinuance of toxic agent or cause

### Prognosis

- Excellent if toxic agent removed

### References

Botchkarev VA. Molecular mechanisms of chemotherapy-induced hair loss. *J Invest Dermatol Symp Proc* 2003; 8: 72–5

Duvic M, Lemak NA, Valero V, et al. A randomized trial of minoxidil in chemotherapy-induced alopecia. *J Am Acad Dermatol* 1996; 35: 74–8

Feldman J, Levisohn DR. Acute alopecia: clue to thallium toxicity. *Pediatr Dermatol* 1993; 10: 29–31

Pillans PI, Woods DJ. Drug-associated alopecia. *Intern J Dermatol* 1995; 34: 149–58

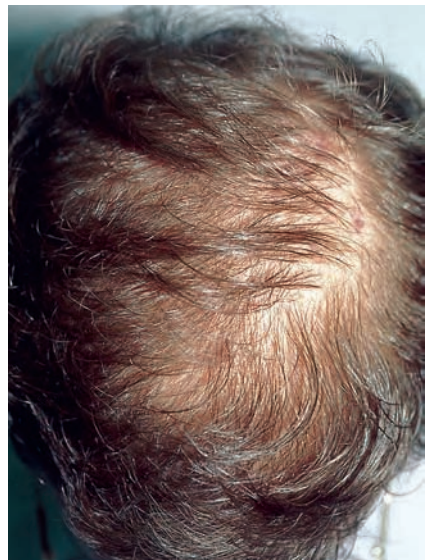Sommer M, Wilson C. Therapeutic approaches to the management of common baldness. *Int J Clin Pract* 1999; 53: 381–5

## Androgenetic alopecia

Synonym: male pattern baldness

### Major points

- Most common type of alopecia in adults
- Characterized by progressive pattern of hair loss from scalp (Figure 18.10)
- Patterns:
  1. Bitemporal recession
  2. Frontal thinning
  3. Vertex thinning leaving occipital and temporal margins with hair
  4. Women have diffuse thinning, usually worse centrally; widened parting, with retention of frontal hairline or M-pattern



**Figure 18.10** Male pattern alopecia in a 14-year-old with a strong genetic history for androgenetic alopecia



- Caused by circulating androgens in genetically susceptible men and women
- Begins between teens and 30 years in both sexes
- Affects 70% of all males in later life and >30% of older women
- Common complaint: thinning
- Inheritance probably polygenic

### Pathogenesis

- Gradual transformation of thick scalp hair follicles to smaller follicles over many cycles, resulting in progressively shorter, finer, miniaturized hairs
- Regulated by dihydrotestosterone, which is formed by conversion of testosterone by 5 $\alpha$ -reductase
- Histology shows miniaturized follicle with streamer of collapsed connective tissue sheath; increase ratio of telogen to anagen hairs and increase of vellus hairs; mild perifollicular lymphohistiocytic inflammation (nonspecific)

### Diagnosis

- Clinical diagnosis
- Family history
- Hair pull test negative

### Differential diagnosis

- Virilizing tumors of adrenal or ovary
- Telogen effluvium

### Treatment

- Evaluation in teenage girls: free testosterone, dehydroepiandrosterone sulfate, luteinizing hormone, follicle stimulating hormone, prolactin
- Aim of treatment is to retard further thinning
- Topical minoxidil 2 or 5% BID, used for at least 1 year to assess efficacy; must maintain treatment to avoid shedding new growth
- Males: finasteride 1 mg PO daily; response seen as early as 3 months; needs continued treatment (contraindicated in women who may potentially become pregnant)
- Girls:
  1. Oral spironolactone (aldosterone antagonist), 50–200 mg/day
  2. Estrogen

### Prognosis

- Slowly progressive

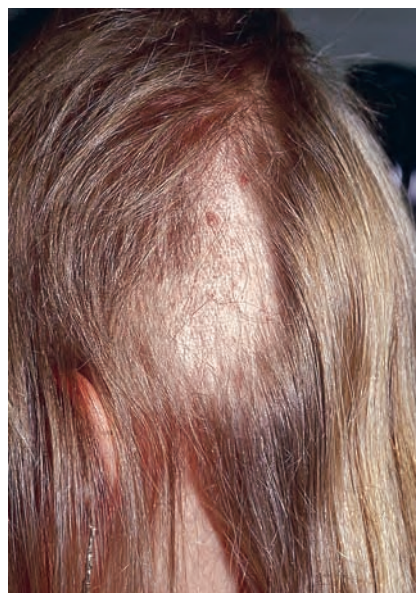### References

- Ellis JA, Sinclair R, Harrap SB. Androgenetic alopecia: pathogenesis and potential for therapy. *Expert Rev Mol Med* 2002; 4: 1–11
- Kaufman KD. Androgens and alopecia. *Mol Cell Endocrinol* 2002; 198: 89–95
- Price VH. Androgenetic alopecia in adolescents. *Cutis* 2003; 71: 115–21
- Price VH. Androgenetic alopecia in women. *J Invest Dermatol Symp Proc* 2003; 8: 24–7
- Price VH. Treatment of hair loss. *N Engl J Med* 1999; 341: 964–73

### Trichotillomania

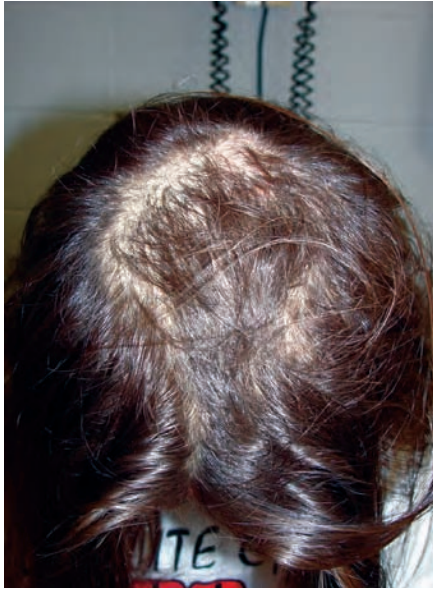#### Major points

- Location often frontal or frontoparietal scalp; can occur in scalp, eyebrows, eyelashes, pubic hair
- Irregularly shaped, angular patches with stubbly, broken-off hairs; area is never completely bald (Figures 18.11 and 18.12)
- Begins insidiously as irregular linear or rectangular area of partial hair loss
- Nonscarring
- Occurs in 8 million Americans



**Figure 18.11** Trichotillomania – angular patches of broken-off hairs with areas of normal hair





**Figure 18.12** Trichotillomania – hair breakage in an unusual pattern on the posterior scalp

- Occurs in all ages >2 years; two-thirds are children, adolescents and young adults
- Two types:
  1. Temporary localized childhood pattern:
    - a. Ages 2–6 years
    - b. Harmless habit, tends to occur before child falls asleep or when reading, writing, or watching television
    - c. No necessary treatment
    - d. Good prognosis
  2. Teenage/adult pattern:
    - a. Obsessive compulsive disorder
    - b. Irresistible urge to pluck hair, either unconscious or semi-conscious
    - c. More severe form
    - d. Prognosis worse
    - e. Most deny doing it
    - f. Female/male ratio >1
    - g. Often refractory to treatment
    - h. Occurs frequently during psychosocial stress
- Other clinical features: focal perifollicular erythema, hemorrhage, excoriations
- Examination of hairs: blunt hair tips
- Concomitant occurrence with alopecia areata has been described

### *Pathogenesis*

- Caused by plucking, pulling, breaking, or twisting one's own hair either consciously or subconsciously
- Histology:
  1. Marked increase in catagen and telogen hairs
  2. Presence of pigment casts
  3. Trichomalacia with abnormally small, distorted, bizarre-shaped hairs
  4. Dilated ostia with empty follicles
  5. Absence of bulbar inflammation

### *Diagnosis*

- Clinical diagnosis
- Confirmed by finding wads of hair or observation of habit
- Histology helpful

### *Differential diagnosis*

- Alopecia areata
- Trichorrhhexis nodosa

### *Treatment*

- Supportive
- Psychological evaluation and treatment
- Behavior modification
- Oral anti-obsessive compulsive agents: selective serotonin uptake inhibitors: paroxetine (Paxil®), sertraline (Zoloft®), fluoxetine (Prozac®)
- Topical mild steroid to reduce any inflammation or sense of itching

### *Prognosis*

- Good in childhood type, poor in teenage type if no treatment is given or if problem has been prolonged

### *References*

- Hautmann G, Hercogova J, Lotti T. Trichotillomania. *J Am Acad Dermatol* 2002; 46: 807–21
- Khouzam HR, Battista MA, Byers PE. An overview of trichotillomania and its response to treatment with quetiapine. *Psychiatry* 2002; 65: 261–70
- Oranje AP, Peereboom-Wynia JDR, De Raeymaecker DMJ. Trichotillomania in childhood. *J Am Acad Dermatol* 1986; 15: 614–19
- Papadopoulos AJ, Janniger CK, Chodynicky MP, Schwartz RA. Trichotillomania. *Int J Dermatol* 2003; 42: 330–4
- Trueb RM, Cavegn B. Trichotillomania in connection with alopecia areata. *Cutis* 1996; 58: 67–70

## Traction alopecia

### Major points

- Common in females with tightly pulled hairstyles, especially Black girls
- Outermost hairs are subject to most tension, so margin of scalp usually affected (Figure 18.3 and 18.13)
- Commonly involves temporal region and frontal scalp
- Scalp surface appears normal, with no scarring
- Insidious onset

### Pathogenesis

- Chronic traction of ponytails or braids, with tension on hair shafts or friction from headgear, rubber bands with hair breakage

### Diagnosis

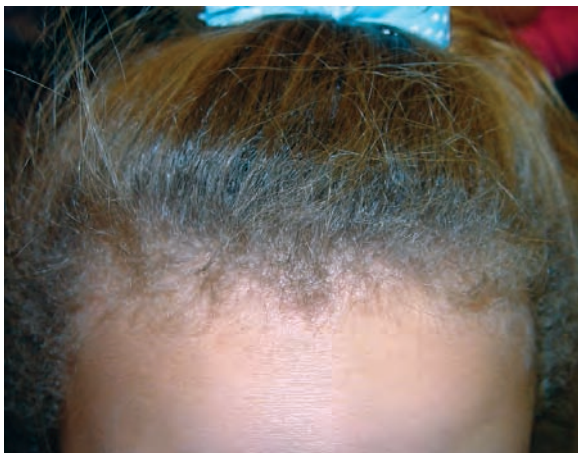- Clinical diagnosis

### Differential diagnosis

- Alopecia areata
- Trichotillomania

### Treatment

- Gentle hair care (Table 18.3)
- Change hairstyle which includes loose braids, parting hair at different site
- Discontinue rubber bands and manipulation of hair



**Figure 18.13** Traction alopecia – caused by over-processing extremely curly hair

### Prognosis

- Early disease (few months) – hair will recover
- Late disease (years) can cause permanent loss of hair follicles

### References

Wilborn WS. Disorders of hair growth in African Americans. In Disorders of Hair Growth. Olsen EA, ed. McGraw-Hill: New York, 1994: 389–407

## Traumatic alopecia

### Major points

- Sudden onset caused by forceful extraction of hairs or prolonged pressure on scalp during surgery, resulting in focal tissue ischemia
- Clinical features: pain, inflammation, edema, followed by ulceration
- Forcible removal: consider child abuse
- Hair loss usually not permanent

## Syndromes with late-onset hypotrichosis

- Ectodermal dysplasias
- Dyskeratosis congenita
- Werner syndrome
- Progeria (Hutchinson–Gilford syndrome)
- Cockayne syndrome
- Rothmund–Thomson syndrome

**Table 18.3** Handout for hair care

1. Be gentle
2. Take time with brushing and combing. Brush and comb as little and as gently as possible
3. Use a soft bristle brush or wide-toothed plastic brush
4. Comb: use a wide-toothed, round-tipped comb, bone or plastic; never metal
5. Cream rinse or condition the hair after shampooing, especially if the hair is long. Choose one with protein added
6. If your lifestyle does not include time for gentle combing and brushing, then keeping the hair short might be an option

## HAIR SHAFT ABNORMALITIES

### Trichorrhexis nodosa

#### Major points

- Fracture of hair shaft with splaying out and release of individual cortical cells, suggesting the appearance of two brushes being pushed together
- Hairs very fragile and break with trauma
- Common in Black females, whose hairstyles include routine straightening
- Hairs along scalp edge are subject to most tension
- Can be seen with argininosuccinic aciduria (congenital trichorrhexis nodosa), citrullinemia and hypothyroidism

#### Pathogenesis

- Results from chronic trauma (mechanical or chemical) to hair shafts: traction, twisting, brushing, hot combing, drying, straightening and other chemical treatments

#### Diagnosis

- Clinical features
- Microscopy of hair shaft

#### Differential diagnosis

- Other hair shaft abnormalities

#### Treatment

- Avoid manipulating hair as much as possible (Table 18.3)

#### Prognosis

- Slow recovery if trauma avoided

#### References

Lurie R, Hodak E, Ginzburg A, David M. Trichorrhexis nodosa: a manifestation of hypothyroidism. *Cutis* 1996; 57: 358–9

Quinn CR, Quinn TM, Kelly AP. Hair care practices in African American women. *Cutis* 2003; 72: 280–9

### Trichorrhexis invaginata

Synonym: bamboo hair

#### Major points

- Characteristic of Netherton syndrome

- Variability of clinical picture
- Hair fragile, short, dull; may affect eyebrows, eyelashes and body hair
- Other features
  1. Ichthyosis linearis circumflexa
  2. Atopic dermatitis
  3. Erythroderma
  4. Secondary colonization with *Staphylococcus aureus*
  5. Increased absorption of topical agents (e.g. tacrolimus)

#### Pathogenesis

- Microscopy of hair shaft: ball and socket configuration or shallow invagination of distal into proximal shaft, resembling bamboo (Figure 18.14)

#### Diagnosis

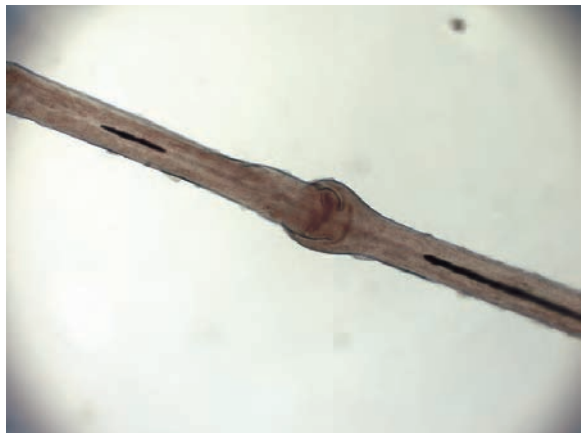- Clinical features with characteristic microscopy of hair shaft
- Gene locus/gene: chromosome 5q32/ SPINK5 gene encoding the serine protease inhibitor LEKTI

#### Differential diagnosis

- Atopic dermatitis
- Erythroderma
- Immune deficiencies

#### Treatment

- Gentle hair care
- Wigs



**Figure 18.14** Netherton syndrome – bamboo hair (courtesy of Dr Dongshi Li)

- Intermittent topical corticosteroids for atopic dermatitis and scaling
- Emollients

### Prognosis

- As hair becomes thicker, it may become slightly less fragile

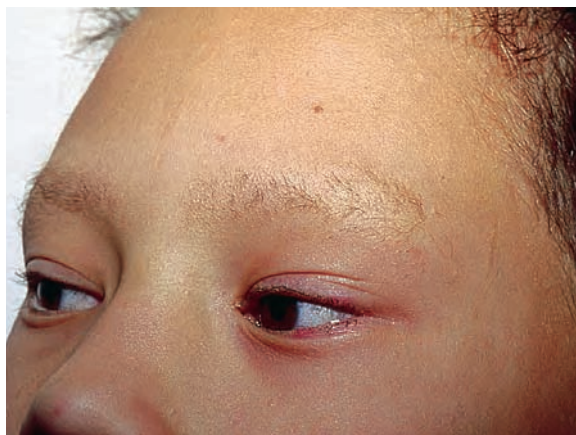### References

- Allen A, Siegfried E, Silverman R, et al. Significant absorption of topical tacrolimus in 3 patients with Netherton syndrome. *Arch Dermatol* 2001; 137: 747–50
- Chavanas S, Bodemer C, Rochat A, et al. Mutations in SPINK5, encoding a serine protease inhibitor, cause Netherton syndrome. *Nature Genet* 2000; 25: 141–2
- Hausser I, Anton-Lamprecht I. Severe congenital generalized exfoliative erythroderma in newborns and infants: a possible sign of Netherton syndrome. *Pediatr Dermatol* 1996; 13: 183–99
- Muller FB, Hausser I, Berg D, et al. Genetic analysis of a severe case of Netherton syndrome and application for prenatal testing. *Br J Dermatol* 2002; 146: 495–9
- Siegel DH, Howard R. Molecular advances in genetic skin diseases. *Curr Opin Pediatr* 2002; 14: 419–25

## Pili torti

### Major points

- Twisting of hair shaft on its own axis, usually through an angle of 180°
- Location: scalp, eyebrows, eyelashes
- Onset at birth or early months
- Hair: light in color, spangled, dry, brittle, breaks at different lengths and tends to stand out from scalp (Figure 18.15)
- Autosomal dominant, recessive or sporadic
- Syndromes that show pili torti:
  1. Classic pili torti
    - a. May be isolated finding
    - b. Can be seen with teeth, nail, eye defects, keratosis pilaris
  2. Björnstad syndrome
    - a. Associated with sensorineural deafness
    - b. Autosomal dominant
  3. Menkes 'kinky hair' syndrome
    - a. Progressive neurodegeneration
    - b. Connective tissue abnormalities



**Figure 18.15** Pili torti – twisted hairs involving the scalp and eyebrows

- c. Hair twisted, coarse, sparse, hypopigmented or silvery; fragile, especially in areas of trauma
- d. Untreated disease usually lethal in early years
- e. Gene mutation in copper transporting P type ATPase protein (ATP7A) on chromosome X 13.3; blocks export of dietary copper from GI tract, leading to decreased bioavailability of copper with functional deficiencies of copper-dependent enzymes

### Pathogenesis

- Histology of hair shaft: three or four regularly spaced twists, each 0.4–0.9 mm in width, occurring at irregular intervals along the shaft
- Twists almost always through 180° but can be less or more

### Diagnosis

- Clinical features with microscopy of hair shaft

### Differential diagnosis

- Uncombable hair syndrome
- Other hair shaft abnormalities

### Treatment

- Gentle hair care

### Prognosis

- Stable; may improve slightly with age



## References

- Richards KA, Mancini AJ. Three members of a family with pili torti and sensorineural hearing loss: the Bjornstad syndrome. *J Am Acad Dermatol* 2002; 46: 301–3
- Selvaag E. Pili torti and sensorineural hearing loss. A follow-up of Bjornstad's original patients and a review of the literature. *Eur J Dermatol* 2000; 10: 91–7
- Whiting DA. Hair shaft defects. In *Disorders of Hair Growth*. Olsen EA, ed. McGraw-Hill: New York, 1994: 91–137

## Monilethrix

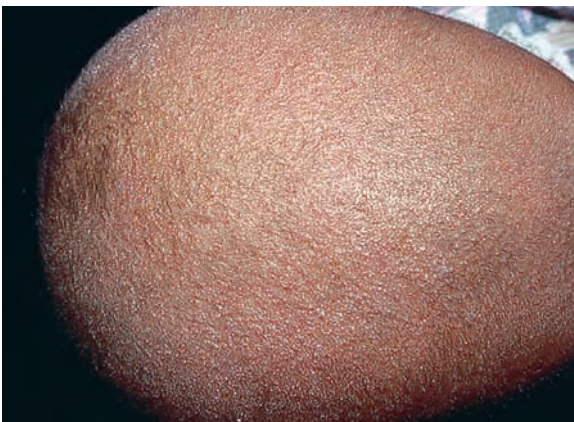Synonym: beaded hair

### Major points

- Beaded hairs on microscopy; nodes have diameter of normal hair, whereas internodes are narrow and are sites of fracture
- Hair usually normal at birth, but replaced by dry, dull, brittle hair which breaks spontaneously
- Scalp has stubbly appearance of hairs (Figure 18.16)
- Follicular keratosis often associated (scalp, face, limbs can have severe involvement)
- Autosomal dominant with high penetrance, but expressivity variable

### Pathogenesis

- Characteristic elliptic nodes, 0.7–1 mm apart, with intervening tapered constrictions that are nonmedullated



**Figure 18.16** Monilethrix – very short hairs with keratotic papules

- Hairs fracture at internodal spaces
- Mutations in human basic hair keratins: hHb1 and hHb6
- Gene map locus 12q13

### Diagnosis

- Clinical features with microscopy of hair shaft

### Differential diagnosis

- Pseudomonilethrix: artifact caused by hairs pressed between two glass slides
- Other hair shaft anomalies

### Treatment

- Gentle hair care

### Prognosis

- May improve slightly as hair becomes thicker with age

## References

- DeBerker DAR, Ferguson DJP, Dawber RPR. Monilethrix: a clinicopathological illustration of a cortical defect. *Br J Dermatol* 1993; 128: 327–31
- Korge BP, Hamm H, Jury CS, et al. Identification of novel mutations in basic hair keratins hHb1 and hHb6 in monilethrix: implications for protein structure and clinical phenotype. *J Invest Dermatol* 1999; 113: 607–12
- Landau M, Brenner S, Metzker A. Medical pearl: an easy way to diagnose severe neonatal monilethrix. *J Am Acad Dermatol* 2002; 46: 111–12
- Smith F. The molecular genetics of keratin disorders. *Am J Clin Dermatol* 2003; 4: 347–64

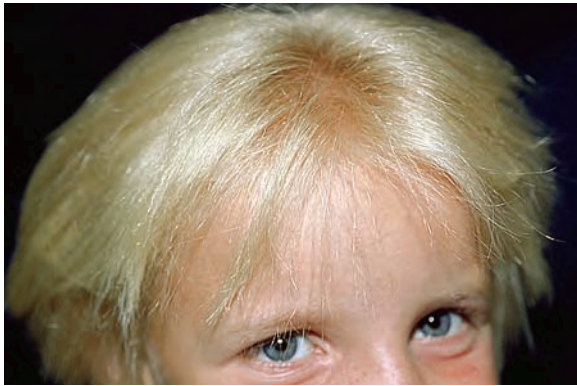## Uncombable hair syndrome

Synonyms: spun glass hair, pili trianguli et canaliculi

### Major points

- Onset early in childhood
- Hair light silvery-blond, pale, frizzy; stands away from the scalp, cannot be combed flat; often spangled in appearance (Figure 18.17)
- Hair usually normal in length, quantity and strength
- Eyebrows, lashes and body hair normal
- Autosomal dominant, recessive or sporadic





**Figure 18.17** Uncombable hair syndrome – spangled hair which is difficult to style

### *Pathogenesis*

- Microscopy of hairs: longitudinal grooving along the shaft or flattened surface with intact cuticle; areas discontinuous and change orientation many times along the shaft
- Cross-sectional microscopy: triangular, or other unusual shapes with longitudinal grooving

### *Diagnosis*

- Clinical diagnosis with characteristic microscopy of hair shaft

### *Differential diagnosis*

- Pili torti
- Loose anagen syndrome

### *Treatment*

- Gentle hair care
- Conditioners helpful
- Hair not particularly fragile

### *Prognosis*

- Good; tends to improve with age, but is always difficult to manage

### *References*

Ang P, Tay YK. What syndrome is this? Uncombable hair syndrome (Pili trianguli et canaliculi). *Pediatr Dermatol* 1998; 15: 475–6

Hicks J, Metry DW, Barrish J, Levy M. Uncombable hair (cheveux incoiffables, pili trianguli et canaliculi) syndrome: brief review and role of scanning electron microscopy in diagnosis. *Ultrastruct Pathol* 2001; 25: 99–103

Itin PH, Buhler U, Buchner SA, Guggenheim R. Pili trianguli et canaliculi: a distinctive hair shaft defect leading to uncombable hair. *Dermatology* 1993; 187: 296–8

## **Loose anagen syndrome**

### *Major points*

- Characterized by actively growing anagen hairs which are loosely anchored and can be easily and painlessly pulled from the scalp
- Mainly blond healthy girls aged 1–9 years
- Parents complain that hair will not grow and seldom needs cutting
- Subtle diffuse or patchy thinning with uneven length of hairs
- Hair appears limp and matted
- Sporadic inheritance; occasionally autosomal dominant

### *Pathogenesis*

- Normal tenacious bond between lower hair shaft and inner root sheath is weak, allowing trivial traction to cause disruption and extraction of hairs

### *Diagnosis*

- Hair pull test (diagnostic) – numerous hair shafts painlessly extracted from scalp
- Microscopy of proximal ends of hairs pulled: anagen hairs without outer root sheaths, with ruffling of hair shaft ('crumpled sock' appearance)

### *Differential diagnosis*

- Uncombable hair syndrome
- Pili torti
- Congenital hypotrichosis

### *Treatment*

- Gentle hair care
- Reassurance

### *Prognosis*

- Can improve with time

### *References*

Boyer JD, Cobb MW, Sperling LC, Rushin JM. Loose anagen hair syndrome mimicking the uncombable hair syndrome. *Cutis* 1996; 57: 111–12

Chapalain V, Winter H, Langbein L, et al. Is the loose anagen hair syndrome a keratin disorder? A clinical and molecular study. *Arch Dermatol* 2002; 138: 501–6

Olsen EA, Bettencourt MS, Cote NL. The presence of loose anagen hairs obtained by hair pull in the normal population. *Invest Dermatol Symp Proc* 1999; 4: 258–60

Tosti A, Piraccini BM. Loose anagen hair syndrome and loose anagen hair. *Arch Dermatol* 2002; 138: 521–2

## Trichothiodystrophy

Synonyms: BIDS, IBIDS, PIBIDS

### Major points

- Sulfur-deficient, brittle hair (scalp, eyebrows, eyelashes)
- Neuroectodermal disorder
- Intellectual impairment
- Short stature
- Decreased fertility
- Photosensitivity with impaired DNA repair
- Ichthyosis
- Autosomal recessive

### Pathogenesis

- Microscopy of hair shaft: flattened, twisted hair shaft, wavy, irregular, trichoschisis (clean, transverse fractures where there is localized absence of cuticle cells)
- Polarized microscopy: alternating bright and dark bands, resembling a tiger tail
- Sulfur content of hair reduced by 50%
- Gene locus/gene: chromosome 19q13/ mutation in at least two separate genes: ERCC2/XPD, and ERCC3/XPB, which encode the two helicase subunits of transcription/repair vector TFIIH

### Diagnosis

- Clinical features with characteristic microscopy of hair shaft

### Differential diagnosis

- Other hair shaft abnormalities

### Treatment

- Gentle hair care

### Prognosis

- Depends upon status of mental capabilities

### References

Bergmann E, Egly JM. Trichothiodystrophy, a transcription syndrome. *Trends Genet* 2001; 17: 279–86

Itin PH, Pittelkow MR. Trichothiodystrophy: review of sulfur-deficient brittle hair syndromes and association with the ectodermal dysplasias. *J Am Acad Dermatol* 1990; 22: 705–17

Itin PH, Sarasin A, Pittelkow MR. Trichothiodystrophy: update on the sulfur-deficient brittle hair syndromes. *J Am Acad Dermatol* 2001; 44: 891–920

McCuaig C, Marcoux D, Rasmussen JE, et al. Trichothiodystrophy associated with photosensitivity, gonadal failure, and striking osteosclerosis. *J Am Acad Dermatol* 1993; 28: 820–6

Sperling LC, DiGiovanna JJ. ‘Curly’ wood and tiger tails: an explanation for light and dark banding with polarization in trichothiodystrophy. *Arch Dermatol* 2003; 139: 1189–92

van Brabant AJ, Stan R, Ellis NA. DNA helicases, genomic instability, and human genetic disease. *Annu Rev Genomics Hum Genet* 2000; 1: 409–59

## ACQUIRED SCARRING ALOPECIA

### Major points

- End result of inflammatory process affecting pilosebaceous unit, resulting in destruction of tissue and permanent hair loss (See Table 18.4) (Figure 18.18–20)

### References

Tan E, Marinka M, Ball N, Shapiro J. Primary cicatricial alopecias: clinicopathology of 112 cases. *J Am Acad Dermatol* 2004; 50: 25–32

## ABNORMALITIES OF INCREASED HAIR

### Hypertrichosis

#### Major points

- Diffuse congenital hypertrichosis
  1. Hypertrichosis lanuginosa
    - a. Very rare

**Table 18.4 Causes of scarring alopecia****Developmental defects/syndrome**

Aplasia cutis congenita  
 Conradi–Hünermann chondrodysplasia punctata  
 Incontinentia pigmenti  
 Ankyloblepharon, ectodermal dysplasia, cleft lip or palate (AEC) syndrome  
 Epidermolysis bullosa  
 Hallermann–Streiff syndrome  
 KID syndrome  
 Goltz syndrome  
 Ichthyoses

**Infections**

Fungal, bacterial, viral (herpes zoster), syphilis

**Trauma**

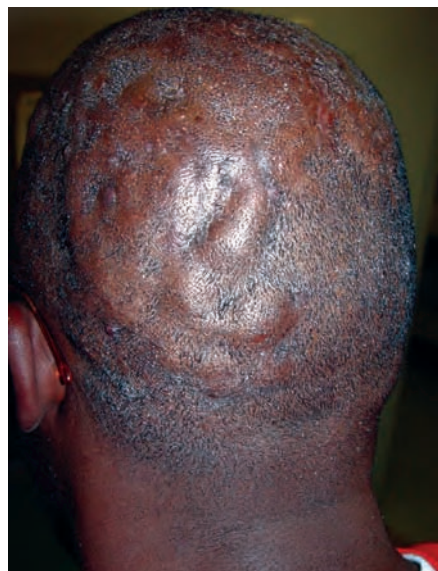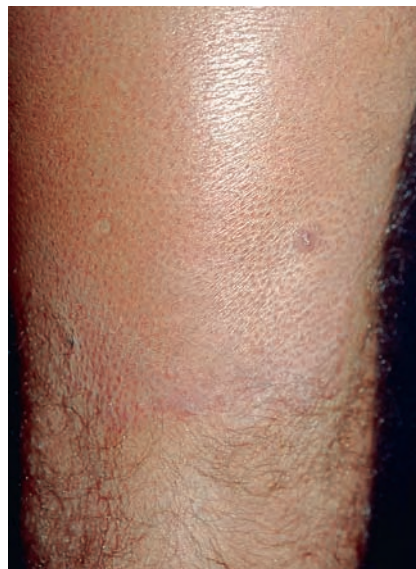Traction  
 Trichotillomania  
 Hot-comb alopecia  
 Radiation  
 Burns

**Inflammatory disorders**

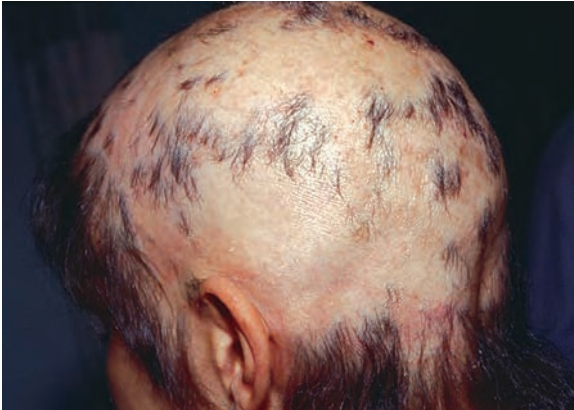Lichen planopilaris: lichen planus localized to follicles; progressive; mild itching; hyperkeratotic follicular papules with erythema and scaling; histology shows lichenoid infiltrate around follicle  
 Morphea: discrete nontender sclerotic patches with ivory-colored shiny center and violaceous border; can see en coup de sabre pattern on frontal scalp  
 Scleroderma: generalized progressive systemic sclerosis  
 Lupus erythematosus: patchy erythema with telangiectases, follicular plugging and central hypo- or depigmentation with peripheral hyperpigmentation; or diffuse  
 Keratosis pilaris atrophicans: follicular keratinous plugging with erythema  
 Folliculitis decalvans: recurrent patchy painful folliculitis, mainly of scalp, often associated with *Staphylococcus aureus*  
 Dissecting cellulitis of scalp: chronic inflammatory disease; painful fluctuant nodules and abscesses interconnected by deep sinus tracts (Figure 18.18)  
 Alopecia mucinosa: grouped follicular papules and plaques with hair loss: histology shows accumulation of mucin in sebaceous glands with dissolution of cellular attachments; perifollicular and perivascular inflammatory cell infiltrate of lymphocytes, histiocytes and a few eosinophils. (Figure 18.19)

**Neoplastic disorders**

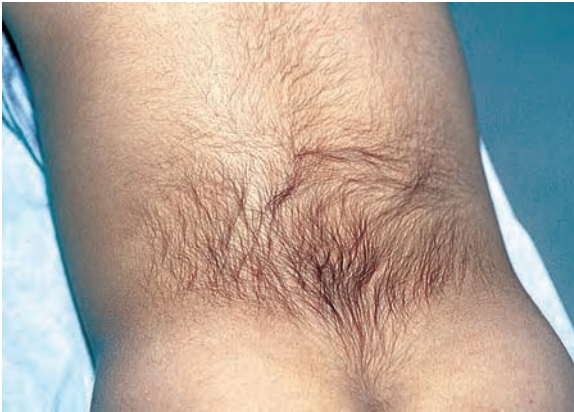Acne keloidalis: grouped, small papules typically on nape of neck: caused by shaving of hair and re-entry of curved hairs into skin causing inflammation and keloid formation  
 Benign tumors: adenexal tumors, hemangiomas  
 Malignant tumors: leukemias, lymphomas, sarcomas

**Figure 18.18** Dissecting folliculitis with cysts and tracts which are sterile abscesses**Figure 18.19** Alopecia mucinosa – benign type seen in a teenager

- b. Characterized by retention of lanugo hair
- c. At birth: coat of profuse silky hair up to 10 cm long with accentuation over the spine and ears
- d. Autosomal recessive or dominant
- Prepubertal hypertrichosis



**Figure 18.20** Acquired scarring alopecia – lichen planopilaris



**Figure 18.21** Hypertrichosis – familial type on lower back

1. Common
  2. Generalized; can present from birth
  3. Severity in early childhood varies
  4. Profuse terminal hair growth on back and limbs, and also temples, forehead and eyebrows (Figure 18.21)
  5. Not clear whether this represents an abnormality or normal range of hair growth seen in some racial groups (e.g. Mediterranean peoples, Indians)
- Drug-induced hypertrichosis (Table 18.5)
  - Localized hypertrichosis (see Table 18.5)
    1. Hypertrichosis with spinal fusion abnormalities
      - a. Tuft of long hair overlying defect (dimple, sinus tract, lipoma, spinal bifida, occult spinal dysraphism)
      - b. Lumbosacral area usually

**Table 18.5** Causes of hypertrichosis

*Types of congenital circumscribed hypertrichosis*

Congenital nevocellular nevus  
 Congenital Becker nevus  
 Smooth muscle hamartoma  
 Nevoid hypertrichosis  
 Underlying neurofibroma  
 Hypertrichosis cubiti  
 Hemihypertrophy  
 Spinal dysraphism  
 Anterior cervical hypertrichosis

*Congenital syndromes with secondary hypertrichosis*

Brachmann-de Lange syndrome  
 Fetal exposures  
   Fetal hydantoin syndrome  
   Fetal alcohol syndrome  
 Lipoatrophic diabetes  
 Mucopolysaccharidoses  
 Congenital porphyrias  
 Rubinstein–Taybi syndrome  
 Hypomelanosis of Ito

*Causes of acquired localized hypertrichosis*

Becker nevus  
 Orthopedic casts and splints  
 Friction  
   Lichen simplex chronicus  
   Habitual biting  
   Insect bites  
   Atopic eczema  
 Venous malformations, thrombosis  
 Trichomegaly  
   HIV  
   Systemic lupus erythematosus  
   Linear scleroderma

*Causes of acquired generalized hypertrichosis*

Infection  
 Malnutrition  
 Dermatomyositis  
 Thyroid abnormalities  
 Cerebral disturbances  
 Acrodynia

*Pharmacologic causes of hypertrichosis*

Phenytoin  
 Acetazolamide  
 Streptomycin  
 Cyclosporin A  
 Diazoxide  
 Minoxidil



2. Hypertrichosis with cranial abnormalities ('hair collar' sign)
  - a. Peripheral collar of thick dark tuft of hair with an underlying form fruste of a neural tube closure defect and heterotopic brain tissue

### *Pathogenesis*

- Increase in hair growth by conversion of vellus to terminal hairs, or changes in the hair-growth cycle

### *Diagnosis*

- Clinical diagnosis
- Rule out causes of hirsutism, if appropriate

### *Differential diagnosis*

(See Table 18.5)

### *Treatment*

- Depends upon cause of hypertrichosis
- Removal of excess hair: shaving, epilation, chemical depilatories, threading, waxing, electrolysis, laser hair removal

### *Prognosis*

- Depends upon cause of hypertrichosis; usually permanent

### *References*

Miller ML, Yeager JK. Hairy elbows. Arch Dermatol 1995; 131: 858–9

Wendelin DS, Pope DN, Mallory SB. Hypertrichosis. J Am Acad Dermatol 2003; 48: 161–79

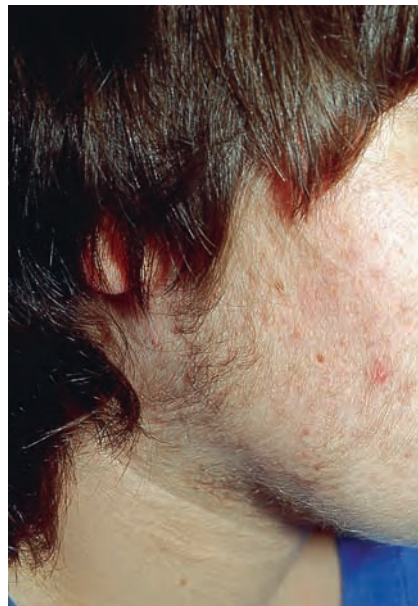## **Hirsutism**

### *Major points*

- Hair in masculine pattern in females on face, chest, upper back, abdomen
- Often associated with other signs of virilization or polycystic ovary syndrome in teens (Figure 18.22)

### *Pathogenesis*

- Abnormality of pituitary, adrenal glands or ovary with increase in male hormones



**Figure 18.22** Hirsutism caused by polycystic ovary disease in a teenage girl

### *Diagnosis*

- History
- Physical examination
- Laboratory tests: serum testosterone and free testosterone, dehydroepiandrosterone sulfate, cortisol levels, urinary 17-ketosteroids, luteinizing hormone, follicle stimulating hormone, prolactin levels and pelvic ultrasound examination

### *Differential diagnosis*

- Genetic predisposition in some ethnic groups
- Congenital adrenal hyperplasia
- Cushing syndrome
- Hyperprolactinemia
- Ovarian and adrenal tumors

### *Treatment*

- Removal of excess hair: shaving, epilation, chemical depilatories, threading, waxing, electrolysis, laser hair removal
- Oral contraceptives

### *Prognosis*

- Depends upon etiology of hirsutism, usually permanent



## References

- Shum KW, Cullen DR, Messenger AG. Hair loss in women with hyperandrogenism: four cases responding to finasteride. *J Am Acad Dermatol* 2002; 47: 733–9
- Sperling LC, Heimer WL. Androgen biology as a basis for the diagnosis and treatment of androgenic disorders in women. II. *J Am Acad Dermatol* 1993; 28: 901–16
- Whiting DA. Diagnostic and predictive value of horizontal sections of scalp biopsy specimens in male pattern androgenetic alopecia. *J Am Acad Dermatol* 1993; 28: 755–63

## ABNORMALITIES OF HAIR COLOR

See Table 18.6

### Menkes kinky hair syndrome

#### Major points

- Hair appears lightly pigmented, twisted, sparse
- Microscopic hair examination: pili torti, trichorrhexis nodosa
- General decrease in skin pigmentation
- Progressive severe mental retardation and neurologic defects
- Bony changes resembling scurvy
- Tortuosities of cerebral and systemic vasculature
- Diverticuli of the bladder

#### Pathogenesis

- Gene/gene locus: ATP7A (copper transporting ATPase enzyme)/Xp 13.3
- Abnormality of a copper binding protein important in cytoplasmic copper transport, causing an inappropriate copper distribution within the cells
- Copper accumulates in fibroblasts and macrophages
- Kinky hair results from a surplus of free sulfhydryl groups and a decrease in copper-dependent disulfide bonds
- Hypopigmentation results from a decrease in tyrosinase, a copper-containing enzyme

#### Diagnosis

- Clinical presentation
- Low serum copper and ceruloplasmin levels
- Genetic testing

**Table 18.6 Abnormalities of hair color**

#### *Disorders associated with primary reduction of hair color*

Oculocutaneous albinism  
Chediak–Higashi syndrome  
Elejalde syndrome  
Griscelli syndrome  
Pili torti  
Menkes syndrome  
Uncombable hair  
Phenylketonuria  
Homocystinuria  
Prader–Willi syndrome

#### *Disorders associated with premature canities (graying)*

Autoimmune disease  
Vitiligo  
Alopecia areata  
Pernicious anemia  
Addison disease  
Hypothyroidism  
Hyperthyroidism  
Syndromes  
Progeria  
Werner syndrome  
Rothmund–Thomson syndrome  
Dyskeratosis congenita  
Down syndrome  
Cri du chat syndrome  
Böök syndrome

#### *Localized hypopigmentation (poliosis)*

Piebaldism  
Waardenburg syndrome  
Vitiligo  
Vogt–Koyanagi–Harada syndrome  
Alezzandrini syndrome  
Alopecia areata  
Tuberous sclerosis  
Halo nevus

#### *Differential diagnosis*

- Child abuse
- Congenital lipodystrophic diabetes
- Trichothiodystrophy

#### *Treatment*

- No effective treatment is available

#### *Prognosis*

- Death usually before 1 year of age

- Mildly affected patients can survive to adolescence or adulthood

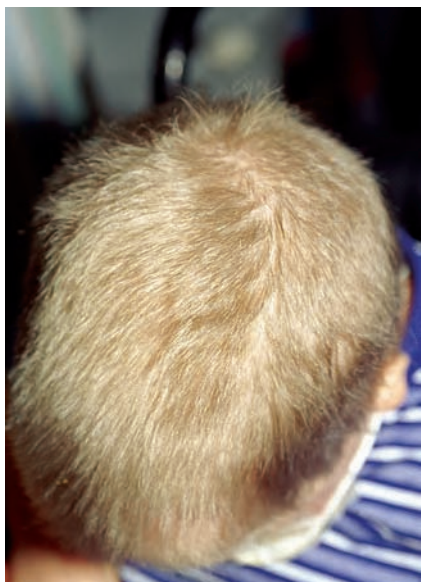### References

- Chelly J, Tumer Z, Tonnesen T, et al. Isolation of a candidate gene for Menkes disease that encodes a potential heavy metal binding protein. *Nature Genet* 1993; 3: 14–19
- Kodama H, Sato E, Yanagawa Y, et al. Biochemical indicator for evaluation of connective tissue abnormalities in Menkes' disease. *J Pediatr* 2003; 142: 726–8
- Menkes JH. Kinky hair disease; twenty five years later. *Brain Dev* 1988; 10: 77–9
- Poulsen L, Horn N, Heilstrup H, et al. X-linked recessive Menkes disease: identification of partial gene deletions in affected males. *Clin Genet* 2002; 62: 449–57
- Shim H, Harris ZL. Genetic defects in copper metabolism. *J Nutr* 2003; 133 (5 Suppl 1): 1527S–31S

## Chediak–Higashi syndrome

### Major points

- Hypopigmentation of skin and hair
  1. Hair has a silvery tint because of large melanosome granules in the hair (Figure 18.23)
  2. Loss of iris pigmentation with photophobia



**Figure 18.23** Chediak–Higashi syndrome with silvery hair, mental retardation and numerous infections

3. Visual acuity normal, but strabismus and nystagmus common
- Infections: children usually present with infection and fever in early childhood
    1. Infections of the skin, lungs, and upper respiratory tract with *Staphylococcus aureus*, *Streptococcus* species
    2. Natural killer cell function decreased
  - Neurological deterioration is progressive: clumsiness, abnormal gait, paresthesias and other findings
  - Accelerated phase: fever, hepatosplenomegaly, lymphadenopathy, pancytopenia; Epstein–Barr virus has been implicated
  - Autosomal recessive

### Pathogenesis

- Caused by a mutation in the *LYST* gene on chromosome 1q

### Diagnosis

- Clinical presentation
- Giant lysosomal granules are seen in polymorphnuclear leukocytes, melanosomes, and other cells
- Genetic testing

### Differential diagnosis

- Elejalde syndrome
- Griscelli syndrome
- Menkes kinky hair syndrome
- Other immunodeficiencies

### Treatment

- Supportive treatments with antibiotics
- Bone marrow transplantation early

### Prognosis

- Usually fatal before age 10 years, unless patient undergoes successful bone marrow transplant

### References

- Haddad E, Le Deist F, Blanche S, et al. Treatment of Chediak–Higashi syndrome by allogeneic bone marrow transplantation: report of ten cases. *Blood* 1995; 85: 3328–33
- Shiflett SL, Kaplan J, Ward DM. Chediak–Higashi syndrome: a rare disorder of lysosomes and lysosome related organelles. *Pigment Cell Res* 2002; 15: 251–7

Ward DM, Shiflett SL, Kaplan J. Chediak–Higashi syndrome: a clinical and molecular view of a rare lysosomal storage disorder. *Curr Mol Med* 2002; 2: 469–77

## Griscelli syndrome

### *Major points*

- Characterized by pigment dilution, hepatosplenomegaly, lymphohistiocytosis, and T and B cell immunodeficiencies
- Immunodeficiency with frequent pyogenic infections, fever, neutropenia, thrombocytopenia
- Hair has a silvery gray tint secondary to the dispersal and clumping of melanin in the hair shaft
- Skin is lighter in color than in siblings and parents
- Neurologic dysfunction with cerebellar and bulbar signs, encephalopathy, seizures, retardation
- Accelerated phase in childhood is usually fatal
- Autosomal recessive
- Gene locus: 15q 21
- Gene: Myosin VA (Type 1), RAB27A (Type 2)

### *References*

Griscelli C, Durandy A, Guy-Grand D, et al. A syndrome associating partial albinism and immunodeficiency. *Am J Med* 1978; 65: 691–702

Kumar M, Sackey K, Schmalstieg F, et al. Griscelli syndrome: rare neonatal syndrome of recurrent hemophagocytosis. *J Pediatr Hematol Oncol* 2001; 23: 464–8

Mancini AJ, Chan LS, Paller AS. Partial albinism with immunodeficiency: Griscelli syndrome: report of a case and

review of the literature. *J Am Acad Dermatol* 1998; 38: 295–300

## Elejalde syndrome

### *Major points*

- Characterized by silvery hair, severe CNS dysfunction, abnormal inclusions in cells of all tissues
- Neurologic abnormalities
- No immunologic dysfunctions
- Autosomal recessive
- Elejalde syndrome and Griscelli syndrome Type 1 may be the same entity

### *References*

Bahadoran P, Ortonne JP, Ballotti R, de Saint-Basile G. Comment on Elejalde syndrome and relationship with Griscelli syndrome. *Am J Med Genet* 2003; 116A: 408–9

Duran-McKinster C, Rodriguez-Jurado R, Ridaura C, et al. Elejalde syndrome – a melanolysosomal neurocutaneous syndrome: clinical and morphological findings in 7 patients. *Arch Dermatol* 1999; 135: 182–6

Elejalde BR, Holguin J, Valencia A, et al. Mutations affecting pigmentation in man: I. Neuroectodermal melanolysosomal disease. *Am J Med Genet* 1979; 3: 65–80

Ivanovich J, Mallory S, Storer T, et al. 12-year-old male with Elejalde syndrome (neuroectodermal melanolysosomal disease). *Am J Med Genet* 2001; 98: 313–16



# 19

## NAIL DISORDERS

---

### Agnail

- Hang nail; hard spicules at edge of nail

### Alopecia areata

- Shallow pits on surface of nail plate; geometric arrangement giving the appearance of a grid or screen; 60% of patients with alopecia areata have pitting which is reversible (Figure 19.1)

### Anonychia

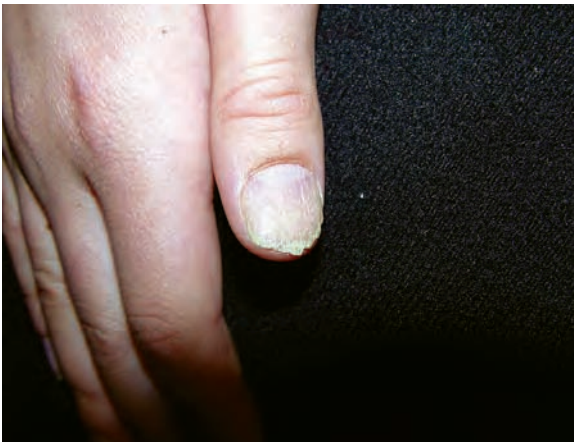- Absence of nail from birth; associated with nail patella syndrome, ectodermal dysplasias, maternal hydantoin ingestion, Coffin–Siris syndrome and others

### Beau's lines

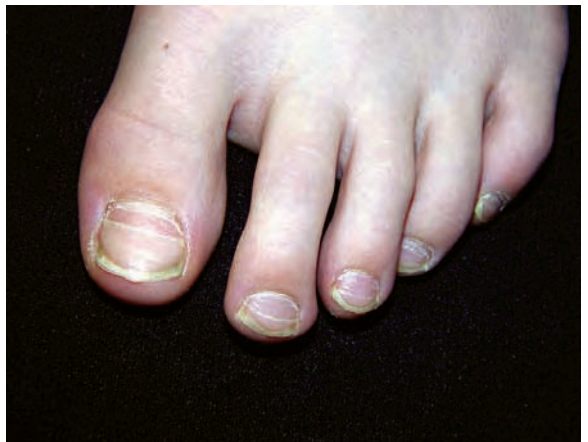- Uniform transverse grooves across the nail plate usually affecting all nails (Figure 19.2)
- Thumbnails and great toenails more prominent than others
- Grooves move distally with nail growth
- Caused by an arrest in nail plate formation by systemic illness or toxins
- No treatment is needed

### Blue nails

- Associated with antimalarial drugs, argyria, bleomycin, congenital pernicious anemia, minocycline and Wilson disease (Figure 19.3)

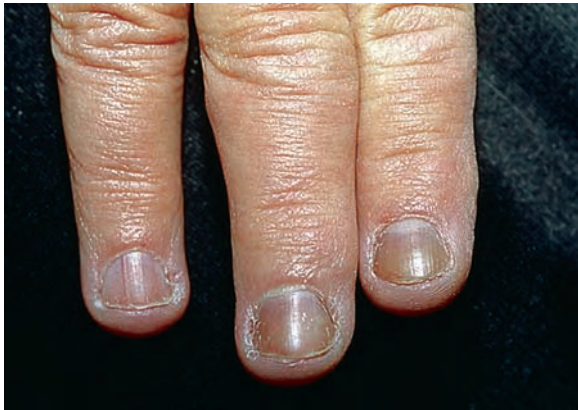

**Figure 19.1** Pitting – commonly occurs in alopecia areata and psoriasis



**Figure 19.2** Beau's lines – horizontal ridge of all 20 nails following a severe illness





**Figure 19.3** Nail pigmentation caused by minocycline

### Brachyonychia

- Short nails with width greater than length; associated with Rubinstein–Taybi syndrome, Down syndrome

### Clubbing

- Bulbous, fusiform enlargement of distal portion of fingers and toes
- Lovibond's angle  $>180^\circ$
- Associated with cystic fibrosis, cyanotic cardiovascular diseases

### Dystrophy

- General term describing nail changes. Examples: trauma, epidermal nevus, lichen striatus, psoriasis, twenty-nail dystrophy and others

### Half-and-half nails (Lindsay nails)

- Proximal nail is white (Figure 19.4)
- Distal 20–50% of nail is red, pink, or brown
- Seen in renal failure

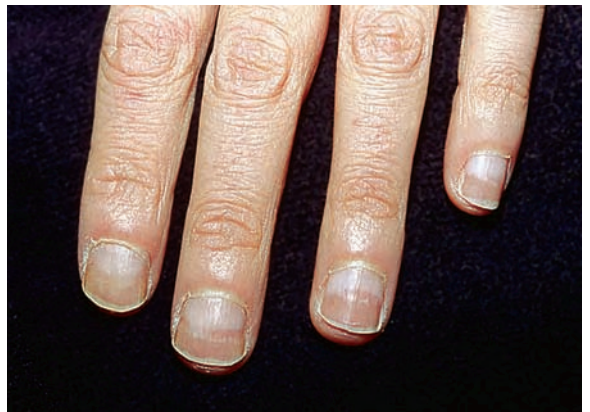### Hutchinson sign

- Periungual spread of pigmentation into the proximal and lateral nail folds
- An important indicator of subungual melanoma but not pathognomonic for it

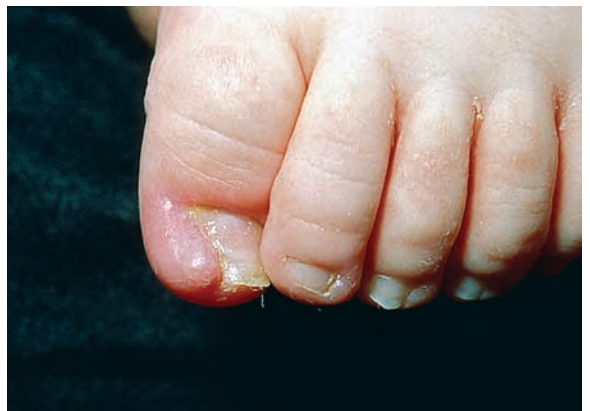### Ingrown nails

- Common problem in infancy, childhood and teens

- Clinical presentations
  1. Congenital hypertrophic lateral nail folds
    - a. Presents as a firm red swelling of lateral nail fold with tenderness (Figure 19.5)
    - b. Usually disappears spontaneously after several months, but may require surgical intervention
  2. Distal-lateral nail embedding
    - a. Caused by uneven cutting of the nail plate with subsequent growth of the plate into an injured lateral nail fold
    - b. Painful with exuberant granulation tissue around the edge of the embedded plate
    - c. Complications: secondary infection (often *Pseudomonas*) and paronychia



**Figure 19.4** Half-and-half nails – proximal nail is white and distal nail is pink; associated with renal disease



**Figure 19.5** Congenital ingrown toenails – erythema and swelling of the lateral nail folds, often bilateral

- d. Treatment: subungual packing with sterile cotton in uncomplicated cases with silver nitrate cauterization, oral antibiotics, topical steroid solutions. In complicated cases, surgical removal of the trapped nail plate
- e. Rarely, total ungual avulsion may be needed

### Koilonychia

- Spoon-shaped or flat nails (Figure 19.6)
- Associated with iron deficiency anemia
- Can be idiopathic or familial

### Leukonychia

- White nails (Figure 19.7)
- May be congenital or acquired
- May be totally white, or striped
- May be associated with multiple causes: alopecia areata, hypoalbuminemia, exfoliative dermatitis, Darier disease, pellagra, zinc deficiency

### Macronychia

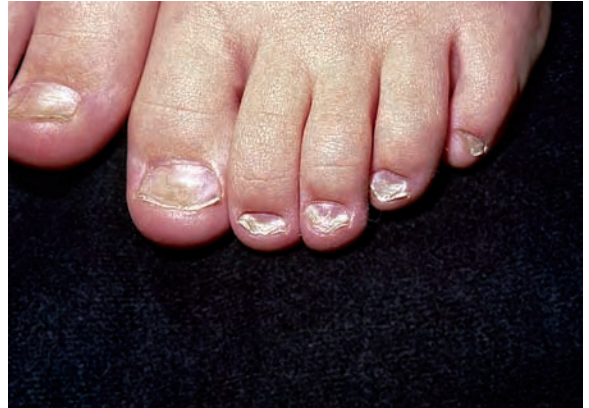- Large but otherwise normal nail
- Associated with neurofibromatosis, tuberous sclerosis

### Malalignment of the great toenails

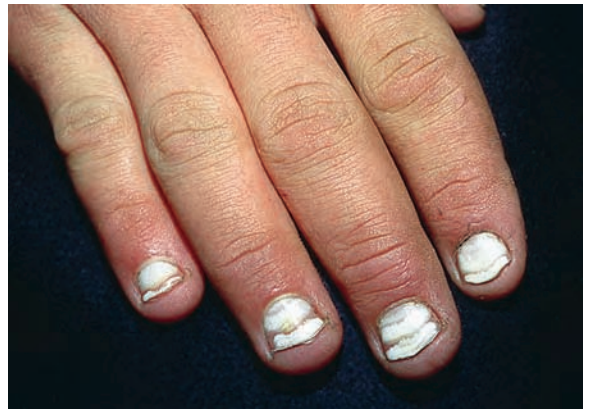- Characterized by lateral deviation of the nail plate relative to the axis of the hallux (Figure 19.8)
- Transverse ridging, thickening and gradual tapering towards the distal free edge with discoloration
- May be discolored from intermittent hemorrhage or microbes
- May be unilateral or bilateral
- Surgical correction may be needed
- Predisposes to paronychia and ingrown nails
- Spontaneous improvement can be seen
- Autosomal dominant

### Median nail dystrophy

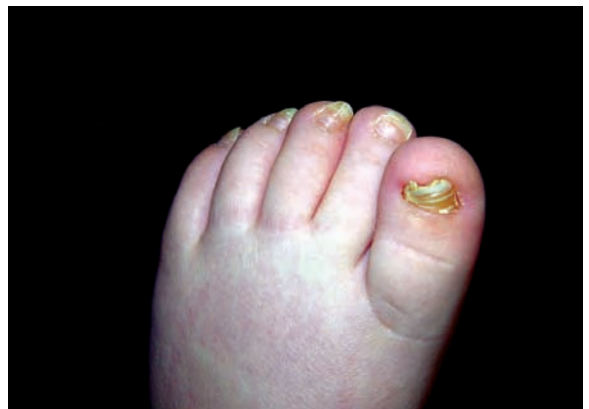- Split or canal in nail plate usually just off center from cuticle to free edge (Figure 19.9)



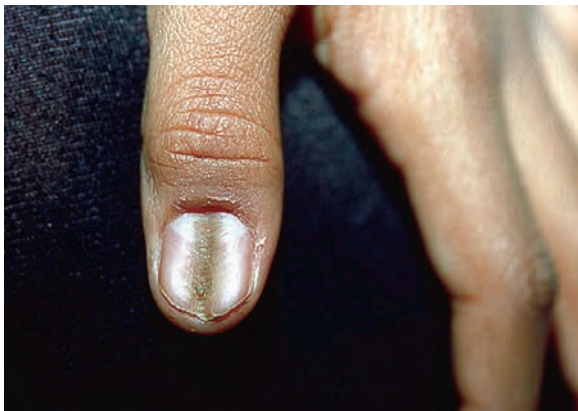**Figure 19.6** Koilonychia – congenital curving of toenails, a common finding in infants and young children



**Figure 19.7** Leukonychia – banded type of unknown etiology. This had been present for many years



**Figure 19.8** Malalignment of the great toenails, causing discomfort



**Figure 19.9** Median nail dystrophy – caused by a habit tic

- Caused by trauma or idiopathic; most common on thumb

### Mee's lines

- White bands in nail plate which move with plate as it grows
- Associated with arsenic ingestion, cardiac insufficiency, pellagra, renal failure, sickle cell anemia

### Micronychia

- Small but otherwise normal nail or nails
- Associated with ectodermal dysplasia, dyskeratosis congenita, nail–patella syndrome

### Muehrcke's nails

- Paired white parallel bands seen with hypoalbuminemia
- Bands do not move

### Nail–patella syndrome

Synonym: congenital iliac horns syndrome, hereditary osteo-onychodysplasia syndrome

- Onychodystrophy (medial thumbnails most involved) with hypoplasia and splitting with usual sparing of the toenails
- Triangular lunulae
- Absent or rudimentary patellae, with unstable knees

- Elbow dysplasia, subluxation of the radial heads
- Iliac horns (calcifications from the posterior aspect of the ilium)
- Other findings
  1. Renal abnormalities: glomerulonephritis, renal dysplasia, Goodpasture syndrome
  2. Hypoplasia of scapulae
  3. Scoliosis
  4. Cloverleaf pigmentation of irides (Lester iris)
  5. Laxity of skin
  6. Hyperhidrosis
  7. Autosomal dominant
- Gene: LMX1B (LIM-homeobox transcription factor 1 $\beta$ )
- Gene locus: 9q34.1

### References

- Bongers EM, Gubler MC, Knoers NV. Nail–patella syndrome. Overview on clinical and molecular findings. *Pediatr Nephrol* 2002; 17: 703–12
- Bongers EM, Van Bokhoven H, Van Thienen MN, et al. The small patella syndrome: description of five cases from three families and examination of possible allelism with familial patella aplasia–hypoplasia and nail–patella syndrome. *J Med Genet* 2001; 38: 209–14
- Dreyer SD, Zhou G, Baldini A, et al. Mutations in LMX1B cause abnormal skeletal patterning and renal dysplasia in nail patella syndrome. *Nature Genet* 1998; 19: 47–50
- Ogden JA, Cross GL, Guidera KJ, Ganey TM. Nail patella syndrome. A 55-year follow-up of the original description. *J Pediatr Orthop* 2002; 11: 333–8
- Stratigos AJ, Baden HP. Unraveling the molecular mechanisms of hair and nail genodermatoses. *Arch Dermatol* 2001; 137: 1465–71

### Nevi

- Characterized by longitudinal pigmented bands (Figure 19.10)
- Usually solitary

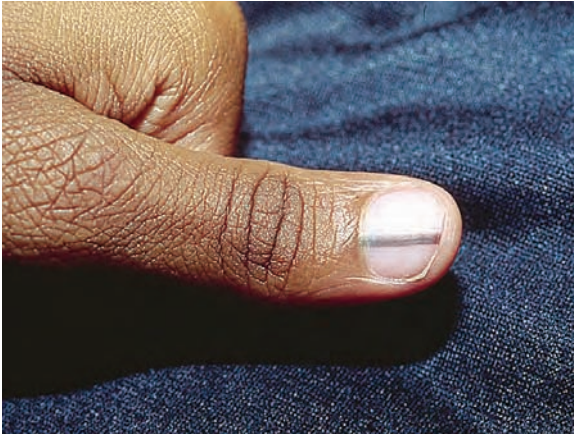### Onychogryphosis

- Acquired thickening (Figure 19.11)
- Caused by trauma, aging or unknown etiology

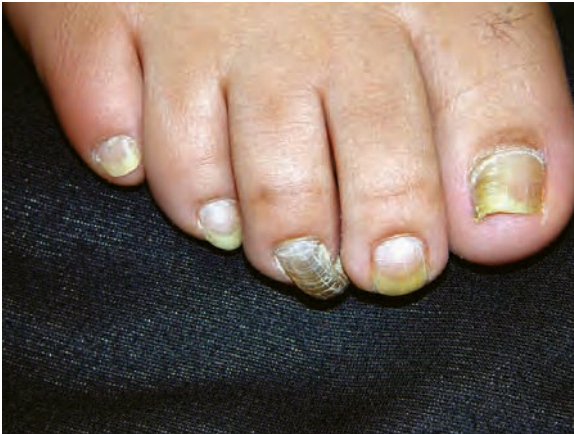### Onychoheteropia

- Misplaced nails





**Figure 19.10** Nevus of the nail matrix with linear dark band of pigmentation; because there is no pigment on the proximal nail fold, this is not Hutchinson sign; however, a biopsy of the nail matrix is suggested to rule out malignant melanoma



**Figure 19.11** Onychogryphosis of the third toenail with onychomycosis of the great toenail

### Onycholysis

- Separation of nail plate from nail bed at distal and lateral attachments (Figure 19.12)
- Caused by hypo- or hyperthyroidism, trauma, psoriasis, candidal infections, diabetes, phototoxic reactions to drugs (tetracycline, thiazine), or idiopathic

### Onychomadesis

- Separation of entire nail plate (Figure 19.13)

### Onychomycosis

- Fungal infection of the nail (See Chapter 9) (Figures 19.14 and 19.15)

### Onychophagia

- Nail biting

### Onychoschizia

- Splitting of nails into parallel layers, with a lamellar surface so that small pieces flake off

### Onychorrhexis

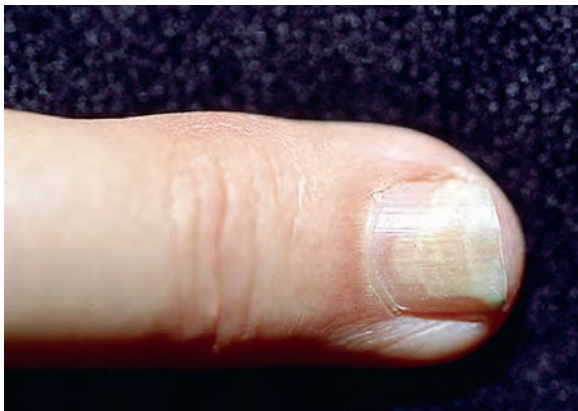- Excess longitudinal ridging

### Pachyonychia congenita

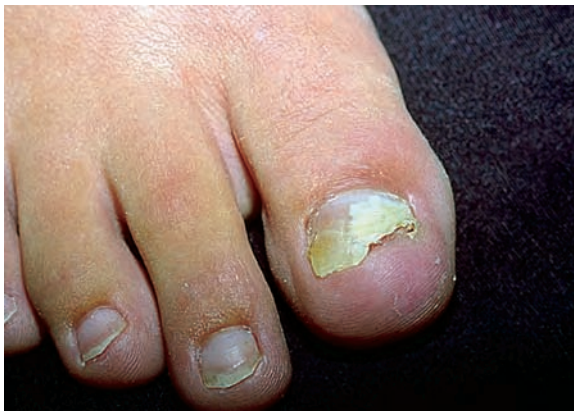- Type I: Jadassohn–Lewandowsky syndrome
  1. Marked thickening of nails (subungual hyperkeratosis) (Figure 19.16)
  2. Recurrent nail shedding
  3. Plantar and palmar keratoses
  4. Acral bullae
  5. Follicular keratoses on buttocks and extremities
  6. Hyperhidrosis of the palms and soles
  7. Leukoplakia that histologically resembles a white sponge nevus and shows no tendency toward malignant degeneration
  8. Mutation of keratin gene: KRT6A, KRT16 (keratin 6a, keratin 16), gene locus: 17q12-q21, 12q13
- Type II: Jackson–Lawler syndrome
  1. Clinical findings of Type I plus
  2. Bullae of palms and soles
  3. Palmar/plantar hyperhidrosis
  4. Steatocystoma multiplex
  5. Epidermal cysts
  6. Natal teeth
  7. No mucosal lesions
  8. Mutation of gene: KRT6B, KRT17 (keratin 6b, keratin 17)
  9. Gene locus: 17q17-q21, 12q13

### Differential diagnosis

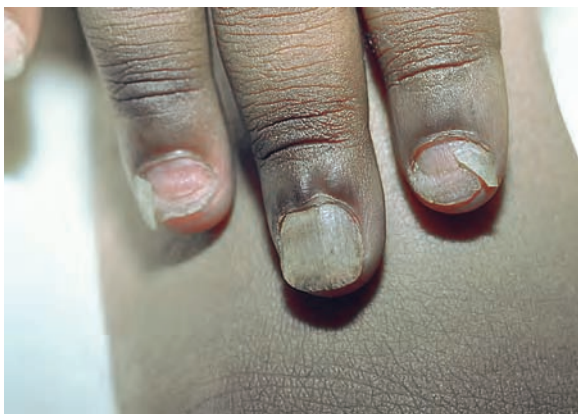- Mucocutaneous candidiasis
- Onychomycosis



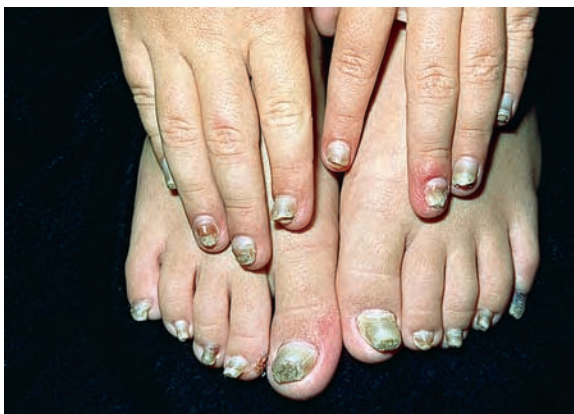**Figure 19.12** Onycholysis – lifting off of the nail plate from the nail bed



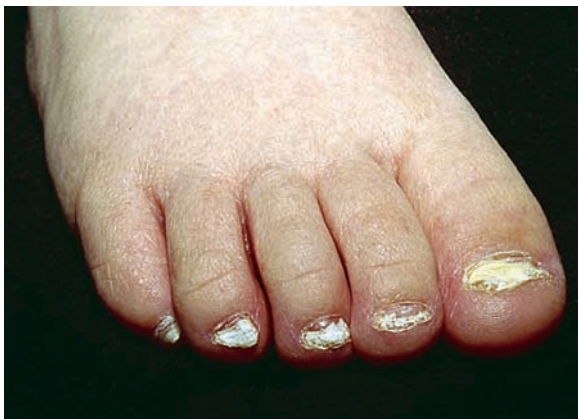**Figure 19.15** Onychomycosis – thickened distal nails with keratotic debris



**Figure 19.13** Onychomadesis – complete shedding of nails after a severe illness



**Figure 19.16** Pachyonychia congenita – markedly thick nails



**Figure 19.14** Onychomycosis – superficial white discoloration associated with *Trichophyton rubrum* in a child

### Treatment

- Surgical removal of nails if severe infections around the nails; keratolytic agents may be helpful

### Prognosis

- Chronic thickening of nails with chronic paronychia

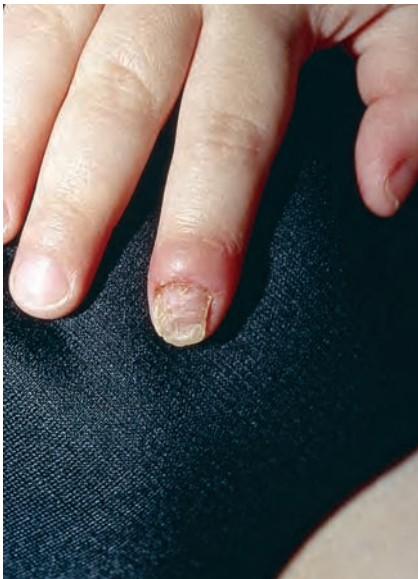
### References

- Feinstein A, Friedman J, Schewach-Millet M. Pachyonychia congenita. *J Am Acad Dermatol* 1988; 19: 705–11
- Paller AS, Moore JA, Scher R. Pachyonychia congenita tarda: a late-onset form of pachyonychia congenita. *Arch Dermatol* 1991; 127: 701–3
- Su WPD, Chun SI, Hammond DE, Gordon H. Pachyonychia congenita: clinical study of 12 cases and review of the literature. *Pediatr Dermatol* 1990; 7: 33–8



## Paronychia

- Infection of periungual tissues
- Common causes: sucking thumb or fingers
- Characterized by painful erythematous induration of proximal or lateral nail folds with fissuring (Figure 19.17)
- Cuticle is obliterated; nail folds round and replaced with granulation tissue
- Pus may be expressed
- Nail dystrophy with wavy undulation may result from inflammation in the proximal nail fold affecting the matrix
- Common organisms: *Staphylococcus*, *Streptococcus* and *Candida*
- Trauma to the proximal nail fold disrupts the cuticle, and in moist environment, organisms invade
- If multiple fingers and toes are involved, consider predisposing diseases: acrodermatitis enteropathica, mucocutaneous candidiasis, or immunodeficiency syndromes
- Treatment is difficult if predisposing factors are not addressed
  1. Topical combination of steroid and antifungal agents (Mycolog<sup>®</sup>) used two or three times per day for 4–6 months



**Figure 19.17** Paronychia – inflammation around the nail caused by *Candida albicans*

2. Topical clindamycin solution
3. Drying agents: 4% thymol in chloroform one or two times a day (should not be used in children who put their hands in their mouth)

## Pincer nail

- Overcurvature of the nails causing pain and partial strangulation dystrophy of the soft tissues (Figure 19.18)

## Polyonychia

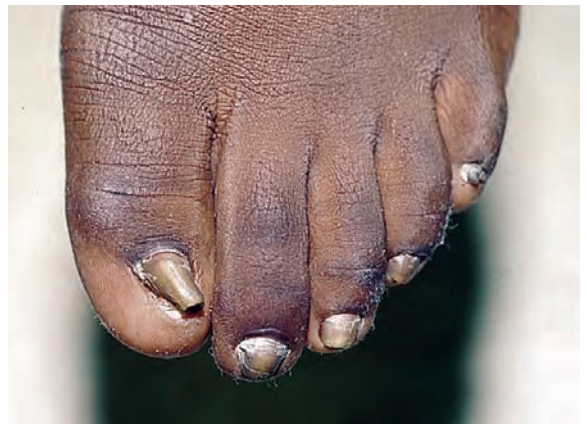- Two or more separate nails on one digit

## *Pseudomonas* nail

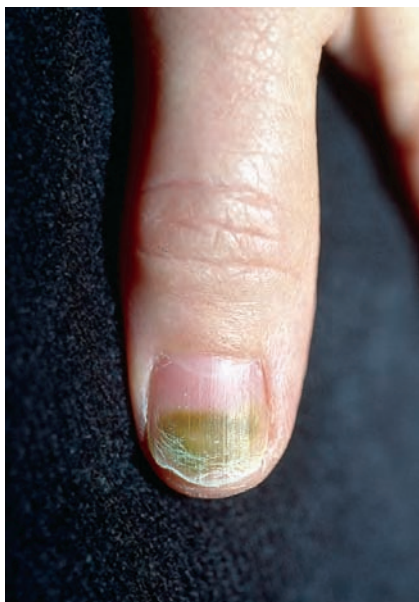- Greenish discoloration under the nail plate with onycholysis (Figure 19.19)

## Psoriasis

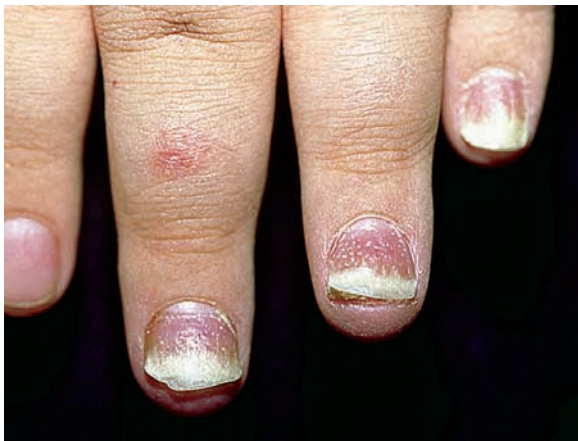- Occurs in 15–79% of children with cutaneous signs of psoriasis
- Pitting of the nail plate is most common; rarely can involve all 20 nails (Figure 19.20)
- Other findings: discoloration, onycholysis, distal subungual debris and oil spotting
- Periungual psoriasis can lead to marked nail dystrophy with hyperkeratosis and crumbling of the nail plate



**Figure 19.18** Pincer nail causing pain in this teenager



**Figure 19.19** *Pseudomonas* infection of the nail bed causing yellow-green discoloration of the nail and the nail bed



**Figure 19.20** Psoriasis – hyperkeratotic plaques under nails with pitting

### Pterygium

- Wing-shaped destruction of nail matrix
- Overgrowth of cuticle onto nail eventually destroying the nail, causing scarring
- Associated with dyskeratosis congenita, graft-versus-host disease, Raynaud disease, systemic sclerosis

### Racquet nail

- Congenital abnormality of the nail, causing the nail to be broader and shorter
- Most common on the thumb

### Red lunulae

- Seen in collagen vascular disease, alopecia areata, congestive heart failure

### Splinter hemorrhages

- Associated with subacute bacterial endocarditis, trauma, vasculitis, cirrhosis, trichinosis, scurvy, psoriasis, chronic glomerulonephritis, Darier disease

### Terry's nails

- Distal 1–2 mm pink, proximal nail white
- Seen with hypoalbuminemia or hepatic cirrhosis

### Trachyonychia

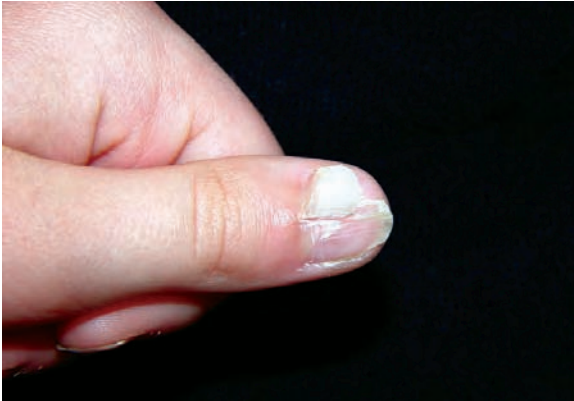- Uniform roughness of surface of nail plate
- Associated with ichthyosis vulgaris, ectodermal dysplasia, 20-nail dystrophy, others

### Traumatic nail injury

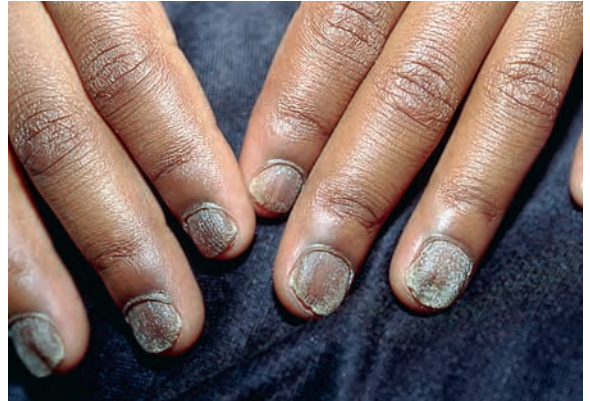- Injury to the nail, nail matrix, nail plate (Figures 19.21 and 19.22)
- Common in childhood
- Can cause permanent dystrophy

### Twenty-nail dystrophy

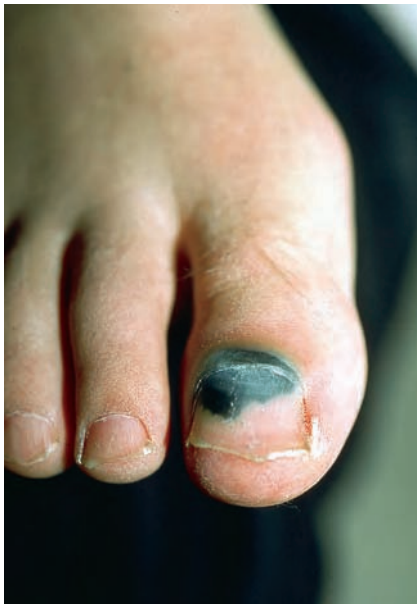- Acquired dystrophy involving all 20 nails
- Characterized by marked roughness of the nail plates (trachyonychia) with longitudinal grooves, striations, onychorrhexis, distal chipping (Figure 19.23)
- Nails can be either thin or thick
- May be associated with lichen planus
- Cause unknown
- Course variable with improvement in 6 months to 16 years
- Treatment:



**Figure 19.21** Trauma – residual damage to nail caused by slamming the finger in a car door



**Figure 19.23** Twenty-nail dystrophy – all nails simultaneously developed trachyonychia



**Figure 19.22** Trauma – hemorrhage under the nail from dropping a heavy object on the toe in a patient with hemophilia

1. Potent topical steroids may be of some benefit over 6 months
2. Clear nail lacquers

### Whitlow

- Caused by herpes inoculation into finger tip or around nail

- Painful recurrent vesicles around the distal finger or nails

### Yellow nails

- Thickened yellow nails
- Associated with chronic lymphedema, pleural effusion, bronchiectasis, chronic bronchitis, rheumatoid arthritis, sinusitis, thyroid disease, psoriasis, pachyonychia congenita, drugs (e.g. tetracycline, penicillamine)

### References

- Adams BB. Jogger's toenail. *J Am Acad Dermatol* 2003; 48: S58–9
- Carroll LA, Laumann AD. Doxycycline-induced photo-onycholysis. *J Drugs Dermatol* 2003; 2: 662–3
- Cohen PR. Red lunulae: case report and literature review. *J Am Acad Dermatol* 1992; 26: 292–4
- Daniel CR, Piraccini BM, Tosti A. The nail and hair in forensic science. *J Am Acad Dermatol* 2004; 50: 258–61
- Feldman SR, Gammon WR. Unilateral Muehrcke's lines following trauma. *Arch Dermatol* 1989; 125: 133–4
- Jerasutus S, Suvanprakorn P, Kitchawengkul O. Twenty nail dystrophy. *Arch Dermatol* 1990; 126: 1068–70
- Rich P, Scher RK. Nail psoriasis severity index: a useful tool for evaluation of nail psoriasis. *J Am Acad Dermatol* 2003; 49: 206–12
- Saray Y, Seckin D, Gulec AT, et al. Nail disorders in hemodialysis patients and renal transplant recipients: a case-control study. *J Am Acad Dermatol* 2004; 50: 197–202





# GENODERMATOSES AND SYNDROMES

---

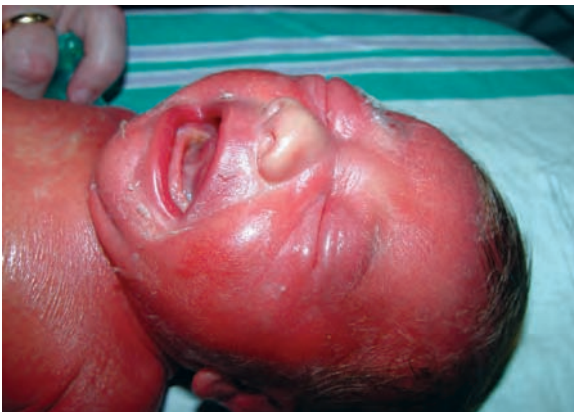## ICHTHYOSES

- Heterogeneous group of inherited disorders characterized by the accumulation of scale on the skin surface
- The word ichthyosis comes from the Greek word for fish, referring to the scaliness of the skin
- National organization: [www.scalyskin.org](http://www.scalyskin.org) (F.I.R.S.T.)

## Collodion baby

### Major points

- Not specific for any particular ichthyosis
- At birth: taut shiny membrane of skin that resembles plastic wrap (Figure 20.1)
- Membrane often becomes fissured and cracked
- Ectropion



**Figure 20.1** Collodion membrane in a neonate

- Eclabium
- Pinnae crumpled
- Tips of fingers often tapered
- Resolves with shedding of membrane
- Hair and nails usually normal

### Pathogenesis

- Seen in various types of ichthyosis:
  1. Lamellar ichthyosis
  2. Ichthyosis vulgaris
  3. Congenital ichthyosiform erythroderma (CIE)
  4. Netherton syndrome
  5. Conradi–Hünemann syndrome
  6. Ectodermal dysplasia
  7. Ankyloblepharon ectodermal dysplasia clefting (AEC) syndrome
  8. Gaucher disease type 2
- Caused by retention of or abnormal stratum corneum *in utero*

### Diagnosis

- Histology: stratum corneum thickened with orthokeratosis

### Differential diagnosis

- Postmaturity desquamation
- Staphylococcal scalded skin syndrome

### Treatment

- Emollients (e.g. ointments)
- Increase ambient humidity
- Maintain hygiene to prevent secondary infection
- Surveillance of skin cultures
- Artificial tears for ectropion
- Stabilization of temperature

### Prognosis

- Membrane usually shed in 7–10 days
- Outcome depends upon type of ichthyosis

### References

- Akcakus M, Gunes T, Kurtoglu S, Ozturk A. Collodion baby associated with asymmetric crying facies: a case report. *Pediatr Dermatol* 2003; 20: 134–6
- Buyse L, Graves C, Marks R, et al. Collodion baby dehydration: the danger of high transepidermal water loss. *Br J Dermatol* 1993; 129: 86–8
- DiGiovanna JJ, Robinson-Bostom L. Ichthyosis: etiology, diagnosis, and management. *Am J Clin Dermatol* 2003; 4: 81–95
- Matsumoto K, Muto M, Seki S, et al. Loricrin keratoderma: a cause of congenital ichthyosiform erythroderma and collodion baby. *Br J Dermatol* 2001; 145: 657–60
- Raghunath M, Hennies HC, Ahvazi B, et al. Self-healing collodion baby: a dynamic phenotype explained by a particular transglutaminase-1 mutation. *J Invest Dermatol* 2003; 120: 224–8
- Richard G, Ringpfeil F. Ichthyoses, erythrokeratodermas and related disorders. In *Dermatology*. Bologna JL, Jorizzo JL, Rapini RP, eds. Mosby: London, 2003: 775–808

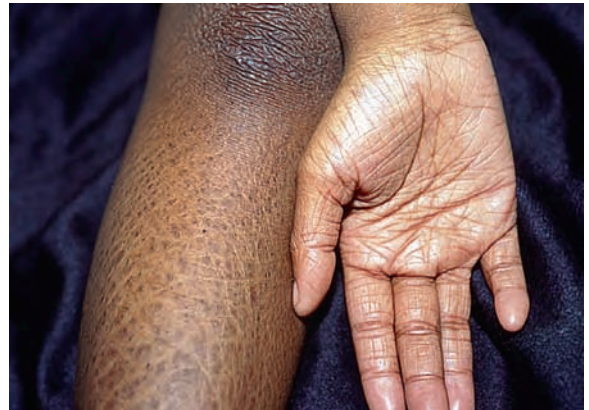## Ichthyosis vulgaris

### Major points

- Most common form of ichthyosis
- Incidence: 1 per 300–2000 persons
- Onset 3–12 months of age
- Personal or family history of dry skin or atopy
- Fine white scales, can be dark
- Location: extensor surfaces of the extremities and trunk, with extremities more severely affected (Figure 20.2)
- Margin of scale tends to turn up
- Flexural areas spared
- Hyperlinearity of the palms and keratosis pilaris is common
- Autosomal dominant

### Pathogenesis

- Increased adhesiveness of the stratum corneum cells and failure to separate
- Gene locus: 1q21
- Gene: profilaggrin, FLG (filaggrin)



**Figure 20.2** Ichthyosis vulgaris associated with hyperlinearity of the palms

### Diagnosis

- Clinical presentation
- Histology: absent granular layer and retention hyperkeratosis
- Electron microscopy: abnormally small and crumbly appearing keratohyaline granules

### Differential diagnosis

- X-linked ichthyosis in a male
- Sjögren–Larssen syndrome
- Xerosis

### Treatment

- Topical keratolytic agents
- $\alpha$ -hydroxyacids
- Moisturize skin with emollients immediately after bathing and frequently through the day

### Prognosis

- Life-long disorder with exacerbations in dry (winter) weather

### References

- Okulicz JF, Schwartz RA. Hereditary and acquired ichthyosis vulgaris. *Int J Dermatol* 2003; 42: 95–8
- Presland RB, Boggess D, Lewis SP, et al. Loss of normal profilaggrin and filaggrin in flaky tail (ft/ft) mice: an animal model for the filaggrin-deficient skin disease ichthyosis vulgaris. *J Invest Dermatol* 2000; 115: 1072–81
- Smack DP, Korge BP, James WD. Keratin and keratinization. *J Am Acad Dermatol* 1994; 30: 85–102

Williams ML, Elias PM. From basket weave to barrier. *Arch Dermatol* 1993; 129: 626–9

Zhong W, Cui B, Zhang Y, et al. Linkage analysis suggests a locus of ichthyosis vulgaris on 1q22. *J Hum Genet* 2003; 48: 390–2

## X-linked ichthyosis

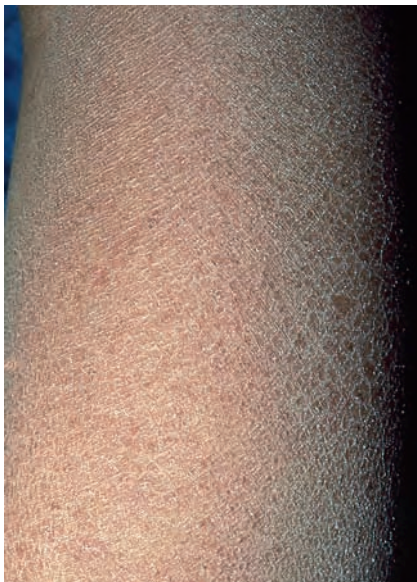Synonym: steroid sulfatase deficiency

### Major points

- Incidence: 1 per 2000–6000 males
- Placental steroid sulfatase deficiency syndrome with failure to initiate or progress in labor
- Begins in the first year of life
- Scales large, thick, adherent and dark (dirty appearance) (Figure 20.3)
- Generalized involvement, milder on face
- May involve flexures and neck
- Slightly thickened, scaly palms and soles
- Asymptomatic corneal opacities (50% adult males, some female carriers)
- Cryptorchidism (20%)
- X-linked recessive inheritance (males only)

### Pathogenesis

- Cholesterol sulfate in epidermis is built up



**Figure 20.3** X-linked ichthyosis – dark brown scaling on the arms

- Increased adhesiveness of the stratum corneum cells and failure of these cells to separate
- Gene locus: Xp22.32
- Gene: STS (steroid sulfatase)

### Diagnosis

- Clinical presentation in a male, often with a positive family history
- Enzyme assay of scale, cultured fibroblasts, keratinocytes or blood leukocytes
- Lipoprotein electrophoresis: rapid mobility of low-density lipoproteins
- Demonstration of gene mutation
- Histology: nondiagnostic; shows retention hyperkeratosis

### Differential diagnosis

- Ichthyosis vulgaris
- Sjögren–Larssen syndrome

### Treatment

- Topical keratolytic agents:  $\alpha$ -hydroxyacids
- Emollients immediately after bathing and frequently through the day
- Increase ambient humidity

### Prognosis

- Persistent; worsens in dry weather and may resolve in humid environments
- Risk for testicular carcinoma and hypogonadism

### References

- Cuevas-Covarrubias SA, Jimenez-Vaca AL, Gonzalez-Huerta LM, et al. Somatic and germinal mosaicism for the steroid sulfatase gene deletion in a steroid sulfatase deficiency carrier. *J Invest Dermatol* 2002; 119: 972–5
- Hernandez-Martin A, Gonzalez-Sarmiento R, De Unamuno P. X-linked ichthyosis: an update. *Br J Dermatol* 1999; 141: 617–27
- Kashork CD, Sutton VR, Fonda Allen JS, et al. Low or absent unconjugated estriol in pregnancy: an indicator for steroid sulfatase deficiency detectable by fluorescence *in situ* hybridization and biochemical analysis. *Prenat Diagn* 2002; 22: 1028–32
- Zettersten E, Man M-Q, Sato J, et al. Recessive X-linked ichthyosis: role of cholesterol-sulfate accumulation in the barrier abnormality. *J Invest Dermatol* 1998; 111: 784–90

## Lamellar ichthyosis

### Major points

- Incidence: 1 per 300 000 persons
- Collodion membrane at birth
- Large, dark, plate-like scales (generalized) with fissuring between scales (Figure 20.4)
- Mild erythroderma
- Ectropion
- Eclabium
- Dystrophic nails
- Alopecia
- No abnormality of mucosa or teeth
- Decreased sweating
- Autosomal recessive

### Pathogenesis

- Increased cell hyperplasia of the basal cells and increased transit rate through the epidermis
- Decreased transit time of epidermal cells with increased mitotic activity
- Alteration of scale lipids
- Gene defect in transglutaminase 1 (TGM1) that catalyzes cross-linking of proteins in the upper layers of the epidermis
- Gene locus: 14q11.2, 2q33-35, 19p12-q12



**Figure 20.4** Lamellar ichthyosis – thick, dark brown, plate-like scales in an adult

### Diagnosis

- Clinical diagnosis
- Histology: massive orthohyperkeratosis and mild/moderate acanthosis
- Genetic testing

### Differential diagnosis

- Congenital ichthyosiform erythroderma (nonbullous)
- Sjögren–Larssen syndrome
- Netherton syndrome
- Other ichthyoses

### Treatment

- Topical keratolytic agents
- Moisturize skin with emollients immediately after bathing and frequently through the day
- Oral retinoids (isotretinoin, acetrein)
- Increase ambient humidity

### Prognosis

- Persistent life-long hyperkeratosis and peeling
- Secondary infection common

### References

- Akiyama M, Sawamura D, Shimizu H. The clinical spectrum of nonbullous congenital ichthyosiform erythroderma and lamellar ichthyosis. *Clin Exp Dermatol* 2003; 28: 235–40
- Allen DM, Esterly NB. Significant systemic absorption of tacrolimus after topical application in a patient with lamellar ichthyosis. *Arch Dermatol* 2002; 138: 1259–60
- DiGiovanna JJ, Robinson-Bostom L. Ichthyosis: etiology, diagnosis, and management. *Am J Clin Dermatol* 2003; 4: 81–95
- Hennies HC, Kuster W, Wiebe V, et al. Genotype/phenotype correlation in autosomal recessive lamellar ichthyosis. *Am J Hum Genet* 1998; 62: 1052–61
- Huber M, Rettler I, Bernasconi K, et al. Mutations of keratinocyte transglutaminase in lamellar ichthyosis. *Science* 1995; 267: 525–8

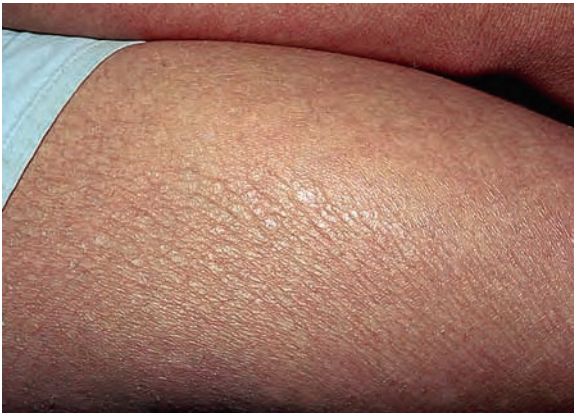## Congenital ichthyosiform erythroderma (nonbullous) (CIE)

### Major points

- Born with collodion membrane
- Generalized scaling and erythroderma, not as severe as lamellar ichthyosis (Figure 20.5)



- Scales fine and white on face, trunk and scalp
- Scales large, plate-like and dark on legs
- Ectropion
- Corneal dystrophy
- Sparse hair
- Nail dystrophy
- Small stature (occasional)
- Mental retardation (occasional)



**Figure 20.5** Congenital ichthyosiform erythroderma – with erythema and fine scales

### Pathogenesis

- Epidermal cell turnover markedly increased; decrease in transit time of epidermal cells
- Autosomal recessive or dominant
- Gene locus: 14q11.2
- Gene: TGM1 (transglutaminase-1)

### Diagnosis

- Clinical diagnosis
- Histology: nondiagnostic; focal or extensive parakeratosis and acanthosis

### Differential diagnosis

- Lamellar ichthyosis
- Other ichthyoses

### Treatment

- Topical keratolytic agents
- Moisturize skin with emollients immediately after bathing and frequently through the day
- Increase ambient humidity

### Prognosis

- Persistent, life-long scaling and erythema (can be mild to severe)

### References

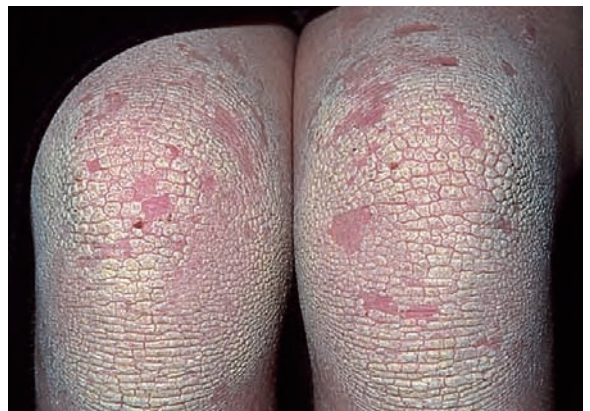- Akiyama M, Sawamura D, Shimizu H. The clinical spectrum of nonbullous congenital ichthyosiform erythroderma and lamellar ichthyosis. *Clin Exp Dermatol* 2003; 28: 235–40
- Laiho E, Ignatius J, Mikkola H, et al. Transglutaminase 1 mutations in autosomal recessive congenital ichthyosis: private and recurrent mutations in an isolated population. *Am J Hum Genet* 1997; 61: 529–38
- Porter RM, Lane EB. Phenotypes, genotypes and their contribution to understanding keratin function. *Trends Genet* 2003; 19: 278–85
- Williams ML, Elias PM. Enlightened therapy of the disorders of cornification. *Clin Dermatol* 2003; 21: 269–73

## Epidermolytic hyperkeratosis

Synonym: bullous congenital ichthyosiform erythroderma

### Major points

- Incidence is 1 per 300 000 births
- Blisters, erosions or erythema at birth
- Generalized scaling develops in later infancy
- Scales are warty, ridged and columnar (Figure 20.6)
- Spontaneous erosions throughout life where scales come off



**Figure 20.6** Epidermolytic hyperkeratosis with columnar thick odiferous scales



- Prominent keratoderma on the palms and soles
- No ectropion
- Heat intolerance
- Secondary infection common, resulting in malodor
- Autosomal dominant or sporadic

### Pathogenesis

- Chromosomes 12q and 17q
- Gene: keratin 1 and 10
- Increased germinative cell hyperplasia of the basal cells and increased transit rate through the epidermis
- Increased transepidermal water loss

### Diagnosis

- Clinical presentation
- Histology: characteristic intracellular vacuolar degeneration of upper spinous/granular cell layers and large clumped keratohyalin granules
- Prenatal diagnosis by fetal skin biopsy at 20–22 weeks' gestation

### Differential diagnosis

- Lamellar ichthyosis
- Congenital ichthyosiform erythroderma (nonbullous)
- Epidermolysis bullosa at birth
- Incontinentia pigmenti at birth
- Staphylococcal scalded skin syndrome
- Ichthyosis hystrix
- Conradi–Hünemann syndrome
- Other ichthyoses

### Treatment

- Increase ambient humidity
- Topical keratolytic agents
- Bathing, add antimicrobial agents to water (e.g. dilute sodium hypochlorite dilution to reduce odor) (See Chapter 21)
- Moisturize skin with emollients immediately after bathing
- Low-dose retinoids (e.g. isotretinoin)
- Support group

### Prognosis

- Persistent, life-long scaling
- Malodor is a persistent problem
- Secondary infection is common

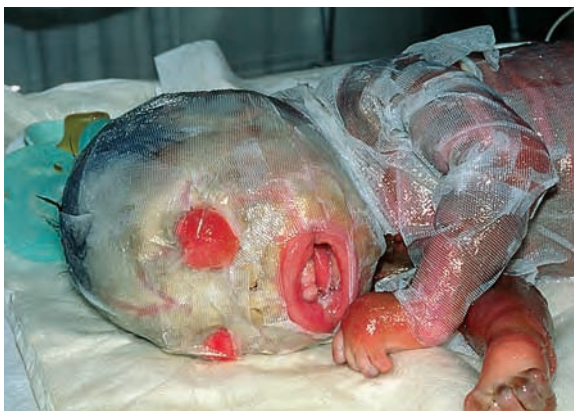### References

- Nazzaro V, Ermacora E, Santucci B, Caputo R. Epidermolytic hyperkeratosis: generalized form in children from parents with systematized linear form. *Br J Dermatol* 1990; 122: 417–22
- Porter RM, Lane EB. Phenotypes, genotypes and their contribution to understanding keratin function. *Trends Genet* 2003; 19: 278–85
- Schmuth M, Yosipovitch G, Williams ML, et al. Pathogenesis of the permeability barrier abnormality in epidermolytic hyperkeratosis. *J Invest Dermatol* 2001; 117: 837–47
- Siegel DH, Howard R. Molecular advances in genetic skin diseases. *Curr Opin Pediatr* 2002; 14: 419–25
- Smith F. The molecular genetics of keratin disorders. *Am J Clin Dermatol* 2003; 4: 347–64
- Virtanen M, Smith SK, Gedde-Dahl T Jr, et al. Splice site and deletion mutations in keratin (KRT1 and KRT10) genes: unusual phenotypic alterations in Scandinavian patients with epidermolytic hyperkeratosis. *J Invest Dermatol* 2003; 121: 1013–20

## Harlequin ichthyosis

### Major points

- Born with massive hyperkeratotic plates resembling the diamond pattern on a harlequin's costume (Figure 20.7)
- Distorted facial features with severe ectropion, eclabium, and rudimentary ears and nose
- Deformities of fingers/toes
- Premature delivery
- Autosomal recessive



**Figure 20.7** Harlequin fetus – massive plate-like scales

### Pathogenesis

- Gene locus: 18q21.3
- Genetic heterogeneity and division into three subtypes: in types 1 and 2 profilaggrin is expressed but not processed to filaggrin; type 3 lacks profilaggrin; types 2 and 3 both have keratins 6 and 16 in addition to normal keratins 5/14 and 1/10 seen in all three subtypes

### Diagnosis

- Clinical appearance
- Histology: compact orthohyperkeratosis
- Electron microscopy: absence of lamellar bodies
- Prenatal diagnosis by fetal skin biopsy at 20–22 weeks' gestation

### Differential diagnosis

- Collodion membrane

### Treatment

- Oral retinoids (e.g. isotretinoin, acetrelin) within a few days of birth has increased survival in a few patients
- Topical keratolytic agents
- Moisturize skin with emollients immediately after bathing and frequently through the day
- Ophthalmology consultation – important to open eyes to prevent blindness
- Management of fluid and electrolytes

### Prognosis

- Very poor, despite treatment
- Most die perinatally from sepsis or massive hyperkeratotic plaques interfering with respiration and feeding
- Survivors shed restrictive scale and develop severe congenital ichthyosiform erythroderma (CIE) phenotype

### References

- Chan Y-C, Tay Y-K, Tan L K-S, et al. Harlequin ichthyosis in association with hypothyroidism and juvenile rheumatoid arthritis. *Pediatr Dermatol* 2003; 20: 421–6
- Culican SM, Custer PL. Repair of cicatricial ectropion in an infant with harlequin ichthyosis using engineered human skin. *Am J Ophthalmol* 2002; 134: 442–3
- Fleckman P, Hager B, Dale BA. Harlequin ichthyosis keratinocytes in lifted culture differentiate poorly by morphologic and biochemical criteria. *J Invest Dermatol* 1997; 109: 36–8

Gunes T, Akcakus M, Kurtoglu S, et al. Harlequin baby with ecthyma gangrenosum. *Pediatr Dermatol* 2003; 20: 529–30

Prasad RS, Pejaver RK, Hassan A, et al. Management and follow-up of harlequin siblings. *Br J Derm* 1994; 130: 650–3

Singh S, Bhura M, Maheshwari A, et al. Successful treatment of harlequin ichthyosis with acetrelin. *Int J Dermatol* 2001; 40: 472–3

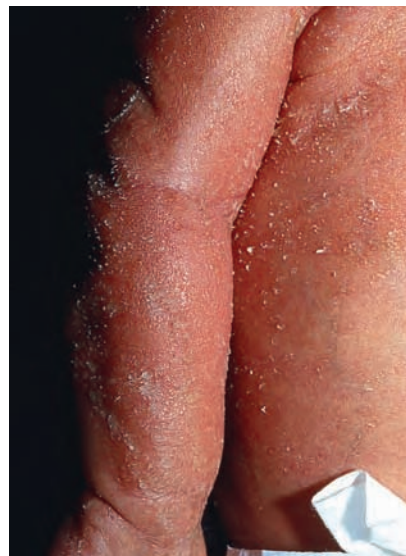Zeeuwen PL, Dale BA, de Jongh GJ, et al. The human cystatin M/E gene (CST6): exclusion candidate gene for harlequin ichthyosis. *J Invest Dermatol* 2003; 121: 65–8

## Conradi–Hünemann–Happle syndrome

Synonym: X-linked dominant chondrodysplasia punctata

### Major points

- Thick scaling in whorl-like pattern (early) following Blaschko lines which clears in 3–6 months, followed by follicular atrophoderma (Figure 20.8)
- Asymmetrical, calcific, epiphyseal stippling by X-ray in newborn
- Unusual facies: flat facies with depressed nasal bridge
- Joint contractures
- Kyphoscoliosis
- Patchy, scarring alopecia
- Dry, lusterless hair



**Figure 20.8** Conradi–Hünemann–Happle syndrome – hyperkeratotic streaks following Blaschko lines

- Shortening of humeri and femurs
- Asymmetrical skeletal deformities
- Lens opacities, other eye problems
- Normal mentation
- X-linked dominant (seen in girls), or autosomal dominant

### *Pathogenesis*

- Gene locus: Xp11.22-p11.23
- Gene: delta (8)–delta (7) sterol isomerase (emopamil-binding protein)
- Mosaic disorder

### *Diagnosis*

- Clinical presentation
- Genetic testing

### *Differential diagnosis*

- Epidermolytic hyperkeratosis
- Goltz syndrome
- Other ichthyoses

### *Treatment*

- Topical keratolytic agents
- Moisturize skin with emollients immediately after bathing and frequently through the day
- Increase ambient humidity

### *Prognosis*

- Scaling resolves by 12 months, but other features persist

### *References*

Braverman N, Lin P, Moebius FF, et al. Mutations in the gene encoding 3-beta-hydroxysteroid-delta(8),delta(7)-isomerase cause X-linked dominant Conradi–Hunermann syndrome. *Nature Genet* 1999; 22: 291–4

Bruch D, Megahed M, Majewski F, Ruzicka T. Ichthyotic and psoriasiform skin lesions along Blaschko's lines in a woman with X-linked dominant chondrodysplasia punctata. *J Am Acad Dermatol* 1995; 33: 356–60

Corbí MR, Conejo-Mir JS, Linares M, et al. Conradi–Hünemann syndrome with unilateral distribution. *Pediatr Dermatol* 1998; 15: 299–303

Milunsky JM, Maher TA, Metzenberg AB. Molecular, biochemical, and phenotypic analysis of a hemizygous male with a severe atypical phenotype for X-linked dominant Conradi–Hünemann–Happle syndrome and a mutation in EBP. *Am J Med Genet* 2003; 116A: 249–54

Offiah AC, Mansour S, Jeffrey I, et al. Greenberg dysplasia (HEM) and lethal X linked dominant Conradi–Hünemann chondrodysplasia punctata (CDPX2): presentation of two cases with overlapping phenotype. *J Med Genet* 2003; 40: 129

Wessels MW, Den Hollander NJ, De Krijger RR, et al. Fetus with an unusual form of nonrhizomelic chondrodysplasia punctata: case report and review. *Am J Med Genet* 2003; 120A: 97–104

Yanagihara M, Ueda K, Asano N, et al. Usefulness of histopathologic examination of thick scales in the diagnosis of X-linked dominant chondrodysplasia punctata (Happle). *Pediatr Dermatol* 1996; 13: 1–4

## **PALMOPLANTAR KERATODERMAS**

### *Major points*

- Characteristic thickening of the palms and soles (Figure 20.9)
- Three major patterns: diffuse, focal or punctuate (Figure 20.10)
- Can be inherited (autosomal or recessive) or acquired
- Can be associated with ichthyoses or other abnormalities
- Associated syndromes: Unna–Thost syndrome, Vohwinkel syndrome, pachyonychia congenita, tyrosinemia type II, epidermolytic hyperkeratosis, hidrotic ectodermal dysplasia, and other dermatoses such as psoriasis, atopic dermatitis, etc.

### *Pathogenesis*

- Abnormalities of keratin 1, 9, 16, connexin 26, loricrin, desmoplakin, others

### *Diagnosis*

- Clinical features

### *Treatment*

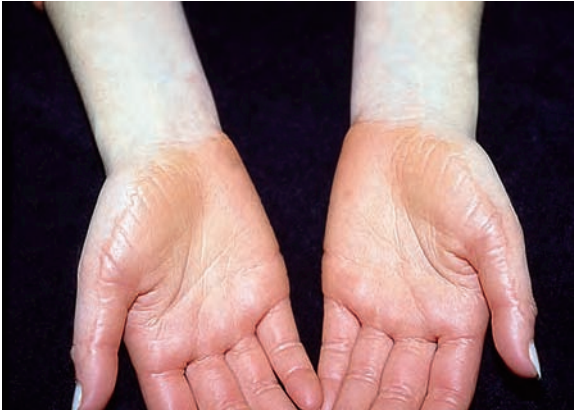- Salicylic acid 4–6% in petrolatum (watch for salicylism)
- Mechanical debridement
- Oral retinoids have variable effect

### *Prognosis*

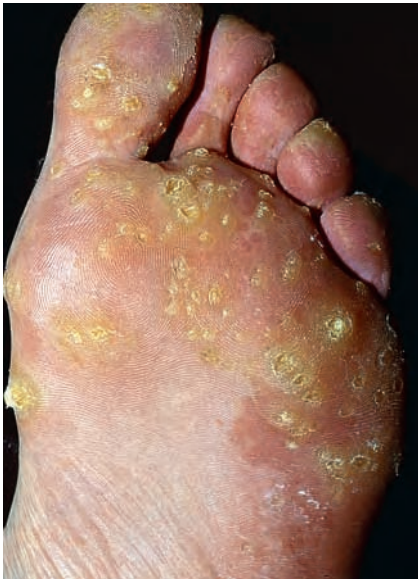- Persistent, can be progressive

### *References*

Kimyai-Asadi A, Kotcher LB, Jih MH. The molecular basis of hereditary palmoplantar keratodermas. *J Am Acad Dermatol* 2002; 47: 327–43



**Figure 20.9** Palmoplantar keratoderma with yellow thickened plaques



**Figure 20.10** Punctate palmoplantar keratoderma

McGrath JA, Eady RA. Recent advances in the molecular basis of inherited skin diseases. *Adv Genet* 2001; 43: 1–32

McLean WH. Epithelial Genetics Group. Genetic disorders of palm skin and nail. *J Anat* 2003; 202: 133–41

Paller AS. The molecular basis for the palmoplantar keratodermas. *Pediatr Dermatol* 1999; 16: 483–5

Richard G. Connexin disorders of the skin. *Adv Dermatol* 2001; 17: 243–77

Smith F. The molecular genetics of keratin disorders. *Am J Clin Dermatol* 2003; 4: 347–64

Whittock NV, Ashton GHS, Dopping-Hepenstal PJC, Gratian MJ. Striate palmoplantar keratoderma resulting from desmoplakin haploinsufficiency. *J Invest Dermatol* 1999; 113: 940–6

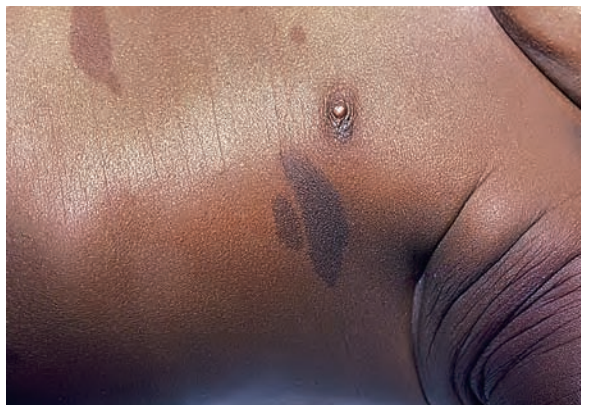Yan AC, Aasi SZ, Alms WJ, et al. Aquagenic palmoplantar keratoderma. *J Am Acad Dermatol* 2001; 44: 696–9

## OTHER GENODERMATOSES

### Neurofibromatosis

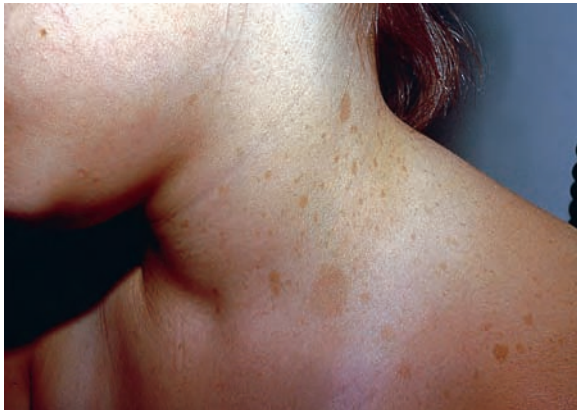#### Major points

- Neurofibromatosis type 1 (von Recklinghausen disease)
  1. Incidence 1 : 3500 of the general population
  2. Characterized by multiple café au lait macules and neurofibromas in the skin, CNS, bones, muscles and endocrine system
  3. Diagnostic criteria (must have two for diagnosis)
    - a.  $\geq 6$  café au lait macules which are  $>5$  mm (before puberty) and  $>1.5$  cm (after puberty) (Figure 20.11)
    - b. Axillary freckling (Crowe sign) (Figure 20.12)
    - c.  $\geq 2$  Lisch nodules (iris hamartomas)
    - d. Distinctive osseous lesion such as sphenoid dysplasia or thinning of long bone cortex with or without pseudarthrosis
    - e. Optic glioma
    - f.  $\geq 2$  neurofibromas or a plexiform neurofibroma (large doughy mass with or without underlying limb hypertrophy which may be present at birth) (Figures 20.13 and 20.14)



**Figure 20.11** Neurofibromatosis – café au lait macules



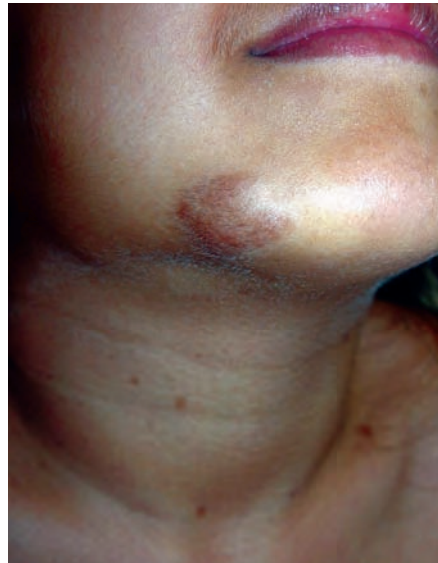

**Figure 20.12** Neurofibromatosis – Crowe sign with freckling on neck or axillae

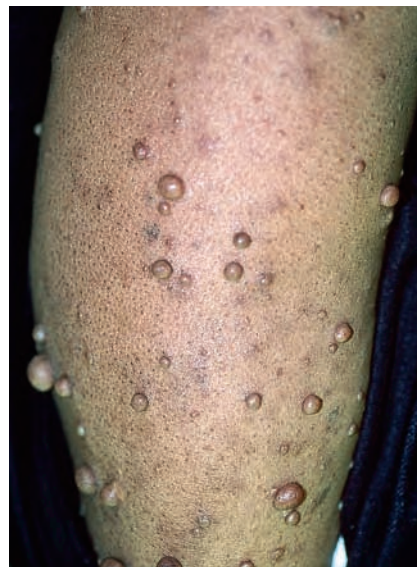- g. First-degree relative with neurofibromatosis type 1
- 4. Neurologic: learning disorders, mental retardation, seizures, intracranial tumors
- 5. Ophthalmic: Lisch nodules, proptosis, ptosis, optic gliomas, congenital glaucoma
- 6. Skeletal: scoliosis, kyphosis, pseudarthrosis, macrocephaly, scalloping of vertebrae, short stature
- 7. Endocrine abnormalities: sexual precocity
- 8. Other associations: pheochromocytoma, Wilms tumor, leukemia and other malignancies
- 9. Autosomal dominant with 50% spontaneous mutations
- Neurofibromatosis type 2
  - 1. Acoustic neuromas of the eighth cranial nerve (90% bilateral)
  - 2. Multiple CNS tumors (various types)
  - 3. Few café au lait macules or neurofibromas
  - 4. No axillary freckling
  - 5. No iris hamartomas (Lisch nodules)
  - 6. Autosomal dominant

### Pathogenesis

- Neurofibromas are caused by loss of a tumor suppressor gene with uncontrolled growth of tissues
- Neurofibromatosis type 1
  - 1. Gene locus: chromosome 17q11.2
  - 2. Gene: neurofibromin, a protein that acts as a negative feedback control for the ras proto-oncogene (tumor suppressor gene)
- Neurofibromatosis type 2
  - 1. Gene locus: 22q12.2



**Figure 20.13** Neurofibromatosis – plexiform neurofibroma on chin; also note the café au lait macules on the neck



**Figure 20.14** Neurofibromatosis – numerous neurofibromas in an adult

- 2. Gene: NF2, merlin (Moesin, Ezrin, Radixin-Like protein)

### Diagnosis

- See Major points

### Differential diagnosis

- Neurofibromas:
  1. Lipomas
  2. Epidermal cysts
  3. Intradermal nevi
  4. Anetoderma
- Café au lait macules:
  1. McCune–Albright syndrome
  2. Watson syndrome
  3. Bannayan–Riley–Ruvalcaba syndrome
  4. Epidermal nevus syndrome
  5. Proteus syndrome

### Treatment

- Annual visits (more frequent, as indicated) with a clinician familiar with neurofibromatosis type 1
- Patients should be followed for complications: optic glioma, neural tumors, developmental disabilities, vascular problems, elevated blood pressure, orthopedic problems, malignancy, psychological problems
- Surgical excision of neurofibromas that are rapidly growing or painful
- Genetic testing is not routine or necessary in the majority of patients
- Specific treatment geared to specific complications

### Prognosis

- Type 1: progressive and variable; may be an increase in complications around puberty or pregnancy
- Type 2: deafness usually in adulthood

### References

- Ablon J. Parents' responses to their child's diagnosis of neurofibromatosis 1. *Am J Med Genet* 2000; 93: 136–42
- Dasgupta B, Gutmann DH. Neurofibromatosis 1: closing the GAP between mice and men. *Curr Opin Genet Dev* 2003; 13: 20–7
- DeBella K, Szudek J, Friedman JM. Use of the National Institutes of Health criteria for diagnosis of neurofibromatosis 1 in children. *Pediatrics* 2000; 105: 608–14
- Dugoff L, Sujansky E. Neurofibromatosis type 1 and pregnancy. *Am J Med Genet* 1996; 66: 7–10
- Drappier J-C, Khosrotehrani K, Zeller J, et al. Medical management of neurofibromatosis 1: a cross-sectional study of 383 patients. *J Am Acad Dermatol* 2003; 49: 440–4

Gutmann D, Aylsworth A, Carley J, et al. The diagnostic evaluation and multidisciplinary management of neurofibromatosis 1 and neurofibromatosis 2. *J Am Med Assoc* 1997; 278: 51–7

Evans DGR, Trueman L, Wallace A, et al. Genotype/phenotype correlations in type 2 neurofibromatosis (NF2): evidence for more severe disease associated with truncating mutations. *J Med Genet* 1998; 35: 450–5

Goldberg Y, Dibbern K, Klein J, et al. Neurofibromatosis type 1 – an update and review for the primary pediatrician. *Clin Pediatr* 1996; 35: 545–61

Johnson NS, Saal HM, Lovell AM, Schorry EK. Social and emotional problems in children with neurofibromatosis type 1: evidence and proposed interventions. *J Pediatr* 1999; 134: 767–72

Kandt RS. Tuberous sclerosis complex and neurofibromatosis type 1: the two most common neurocutaneous diseases. *Neurol Clin* 2003; 21: 983–1004

McLaughlin ME, Jacks T. Neurofibromatosis type 1. *Methods Mol Biol* 2003; 222: 223–37

Task Force: Eichenfield LF, Levy ML, Paller AS, Riccardi VM. Guidelines of care for neurofibromatosis type 1. Academy guidelines. *J Am Acad Dermatol* 1997; 37: 625–30

Van Es S, North KN, McHugh K, De Silva M. MRI findings in children with neurofibromatosis type 1: a prospective study. *Pediatr Radiol* 1996; 26: 478–87

### Tuberous sclerosis complex

Synonym: Bourneville disease

### Major points

- Incidence: 5 per 100 000
- Characterized by a triad of features (commonly, only one or two of these classic features is present):
  1. Adenoma sebaceum (angiofibromas) (>50%)
    - a. Begins at ages 2–5 years as pink/red small papules on the cheeks and nasolabial folds and they enlarge slowly over time
  2. Mental retardation in 30–65%; ranges from mild to severe
  3. Seizures or infantile spasms (80%)

### Pathogenesis

- Gene locus/gene:
  1. TSC-1, 9q34/ hamartin (tumor suppressor gene)

- 2. TSC-2, 16p.13.3/ tuberlin (GAP protein)
- 50–75% of cases are sporadic

### Diagnosis

- Diagnostic criteria (see Table 20.1)
- Examination with a Wood's light can aid in the visualization of the hypopigmented macules in light-skinned individuals
- Examination of family members
- Histology (angiofibroma): dermal fibrosis and vasodilatation
- Histology (shagreen patch): increased collagen and elastin
- MRI can demonstrate CNS hamartomas

### Differential diagnosis

- Facial lesions
  1. Acne
  2. Milia
  3. Trichoepitheliomas
  4. Molluscum contagiosum
  5. Seborrheic dermatitis
- Hypopigmented macules
  1. Vitiligo
  2. Nevus depigmentosus
  3. Pityriasis alba
  4. Hypomelanosis of Ito
  5. Nevus anemicus
  6. Postinflammatory hypopigmentation
  7. Tinea versicolor
- Periungual fibromas
  1. Warts
  2. Infantile digital fibromatosis

### Treatment

- Hypopigmented macules – none needed
- Adenoma sebaceum: CO<sub>2</sub> laser or other destructive therapy
- Close follow-up by pediatrician and specialists as indicated

### Prognosis

- Variable
- Some patients have severe CNS difficulties, some have severe development of angiofibromas, others have only minor stigmata of the disease and are only diagnosed when a family member is diagnosed
- Hypopigmented lesions are static, or become less obvious with time

**Table 20.1 Diagnostic criteria for tuberous sclerosis (TSC)**

**Definite TSC:** either one primary feature, two secondary features or one secondary plus two tertiary features

**Probable TSC:** either one secondary plus one tertiary feature or three tertiary features

**Suspect TSC:** either one secondary feature or two tertiary features

#### Primary features

Facial angiofibromas (adenoma sebaceum)  
Multiple ungual fibromas  
Cortical tuber (histologically confirmed)  
Subependymal nodule or giant cell astrocytoma (histologically confirmed)  
Multiple calcified subependymal nodules protruding into the ventricle (radiographic evidence)  
Multiple retinal astrocytomas

#### Secondary features

Affected first-degree relative  
Cardiac rhabdomyomas (histologic or radiographic confirmation), often multiple  
Retinal hamartoma or achromic patch  
Cerebral tubers (radiographic confirmation)  
Noncalcified subependymal nodules (radiographic confirmation)  
Shagreen patch (connective tissue nevus) – most common in lumbar area (Figure 20.15)  
Forehead plaque (angiofibromas)  
Renal angiomyolipoma (radiographic or histologic confirmation)  
Renal cysts (histologic confirmation)  
Pulmonary lymphangioleiomyomatosis (histology required)

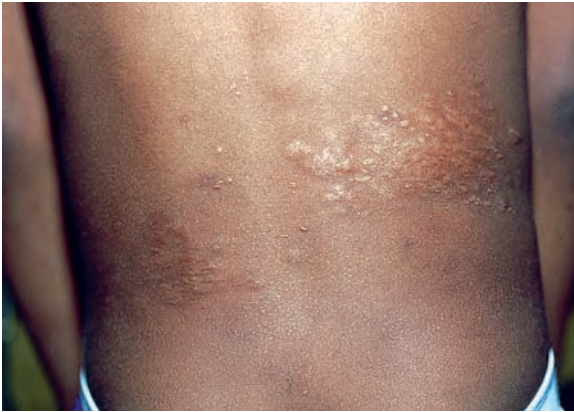#### Tertiary features

Hypomelanotic macules/poliosis (white patches of hair) (Figure 20.16)  
Confetti skin lesions  
Renal cysts (radiographic evidence)  
Randomly distributed enamel pits in teeth  
Hamartomatous rectal polyps (histologic confirmation)  
Bone cysts (radiographic evidence)  
Pulmonary lymphangioleiomyomatosis (radiographic evidence)  
Cerebral white matter 'migration tracts' or heterotopias (radiographic evidence)  
Gingival fibroma  
Hamartoma of the other organs (histologic confirmation)  
Infantile spasms

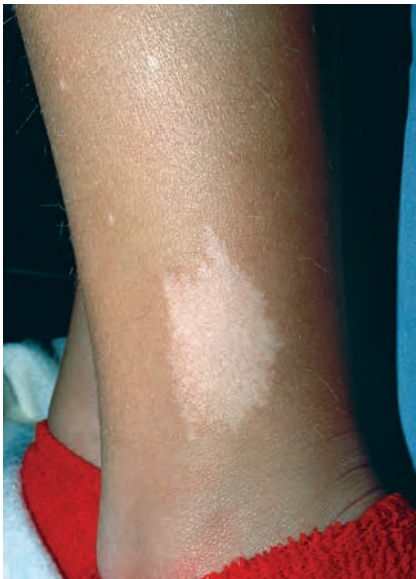Continued...

**Table 20.1 Continued****Other findings**

Pneumothorax  
 Diffuse bronzing  
 Retinal gliomas  
 Optic atrophy  
 Mental retardation  
 Seizures



**Figure 20.15** Tuberous sclerosis – shagreen patch on lower back



**Figure 20.16** Tuberous sclerosis – hypopigmented macules

**References**

- Dahan D, Fenichel GM, El-Said R. Neurocutaneous syndromes. *Adolesc Med State Art Rev* 2002; 13: 495–509
- Kandt RS. Tuberous sclerosis complex and neurofibromatosis type 1: the two most common neurocutaneous diseases. *Neurol Clin* 2002; 20: 941–64
- Kwiatkowski DJ. Tuberous sclerosis: from tubers to mTOR. *Ann Hum Genet* 2003; 67: 87–96
- Narayanan V. Tuberous sclerosis complex: genetics to pathogenesis. *Pediatr Neurol* 2003; 29: 404–9
- Tsao H. Update on familial cancer syndromes and the skin. *J Am Acad Dermatol* 2000; 42: 939–69
- Vanderhooft SL, Francis JS, Pagon RA, et al. Prevalence of hypopigmented macules in a healthy population. *J Pediatr* 1996; 129: 355–61
- Zuvulunov A, Esterly NB. Neurocutaneous syndromes associated with pigmentary skin lesions. *J Am Acad Dermatol* 1995; 32: 915–35

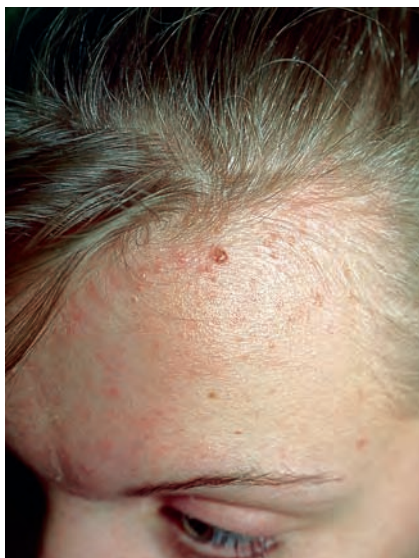**Basal cell nevus syndrome**

Synonyms: nevoid basal cell carcinoma syndrome, Gorlin syndrome

**Major points**

- Multiple basal cell carcinomas at an early age (Figure 20.17)
- Palmoplantar pits
- Multiple jaw cysts (odontogenic keratocysts) with malignant potential
- Skeletal abnormalities
  1. Spina bifida occulta
  2. Rib anomalies (splayed, bifid, fused, missing, etc.)
  3. Scoliosis
  4. Short fourth metacarpals
  5. Mandibular prognathism
  6. Vertebral anomalies
  7. Pectus excavatum
- Hypertelorism
- Medulloblastoma
- Mental retardation
- Calcification of the falx cerebri
- Agenesis of the corpus callosum
- Frontal bossing
- Autosomal dominant





**Figure 20.17** Basal cell nevus syndrome – with basal cell carcinoma resembling a nevus

### Pathogenesis

- Gene locus: 9q22.3, 9q31
- Gene: PTC1 (patched gene) (PTC protein binds and inhibits transmembrane protein SMOOTHENED (SMO))
- Histology: similar to ordinary basal cell carcinomas

### Diagnosis

- Clinical features
- X-rays looking for skeletal abnormalities and odontogenic keratocysts
- Biopsy of suspicious lesion

### Differential diagnosis

- Melanocytic nevus
- See Table 17.2

### Therapy

- Careful periodic evaluation to assess development of basal cell carcinoma and other abnormalities
- Radiotherapy should be avoided
- Removal of growing lesions
- Sun avoidance, sunscreens
- Genetic counseling

### Prognosis

- Slow progression of basal cell carcinomas, jaw cysts
- Depends upon behavior of tumors

### References

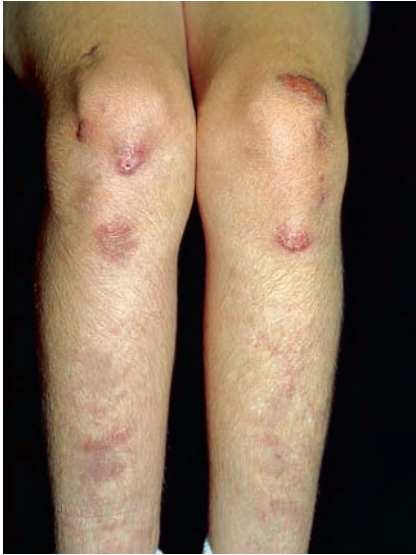- Barbagallo JS, Kolodzieh MS, Silverberg NB, Weinberg JM. Neurocutaneous disorders. *Dermatol Clin* 2002; 20: 547–60, viii
- Boutet N, Bignon Y-J, Drouin-Garraud V, et al. Spectrum of PTC1 mutations in French patients with Gorlin syndrome. *J Invest Dermatol* 2003; 121: 478–81
- Kulkarni P, Brashear R, Chuang TY. Nevroid basal cell carcinoma syndrome in a person with dark skin. *J Am Acad Dermatol* 2003; 49: 332–5
- LeSueur BW, Silvis NG, Hansen RC. Basal cell carcinoma in children: report of 3 cases. *Arch Dermatol* 2000; 136: 370–2
- Turner MB, Mallory SB. Nevroid basal cell carcinoma syndrome. *Curr Opin Dermatol* 1997; 4: 162–7

## EHLERS-DANLOS SYNDROME

Synonym: cutis hyperelastica

### Major points

- Ehlers–Danlos syndrome I. Gravis type (classic, severe): skin fragility and hyperextensibility; soft, velvety skin; joint hypermobility; easily bruised skin; atrophic scars; varicose veins (Figure 20.18)
  1. Autosomal dominant
  2. Biochemical defect: COL5A1, or COL5A2, or COL1A1
  3. Gene locus: 2q31, 17q21.31-q22, 9q34.2-q34.3
- Ehlers–Danlos syndrome II. Mitis type (classic, mild): similar to type I, but less severe; easily bruised skin; floppy mitral valve; absence of inferior labial frenulum and lingual frenulum
  1. Autosomal dominant
  2. Biochemical defect: COL5A1, COL5A2
  3. Gene locus: 9q34.2-q34.3
- Ehlers–Danlos syndrome III. Hypermobile type: large and small joint hypermobility (marked) and dislocations; soft skin
  1. Autosomal dominant
  2. Biochemical defect: COL3A1 and tenascin-XB
  3. Gene locus: 2q31
- Ehlers–Danlos syndrome IV. Vascular type: arterial, bowel and uterine rupture; marked skin fragility with thin, translucent skin; easily bruised skin; absence of skin and joint extensibility; tendency to form keloids; characteristic facial



**Figure 20.18** Ehlers–Danlos syndrome – pseudotumors from scars

appearance with parchment-like skin and very thin nose; reduced life expectancy

1. Autosomal dominant or autosomal recessive
2. Biochemical defect: abnormal type III collagen (COL 3A1)
3. Gene locus: 2q31
- Ehlers–Danlos syndrome V. X-linked type: similar to EDS type II
  1. X-linked recessive
  2. Biochemical defect unknown
- Ehlers–Danlos syndrome VI. Ocular-sclerotic type: marked joint and skin involvement; scleral and corneal fragility; keratoconus; intraocular hemorrhage; scoliosis; hypotonia; arterial rupture
  1. Autosomal recessive
  2. Biochemical defect: lysyl hydroxylase
  3. Gene locus: 1p36.3-p36.2
- Ehlers–Danlos syndrome VII. Arthrochalis multiplex congenita type: extreme joint hypermobility with congenital hip dislocation; short stature; excessive, soft skin particularly on the limbs; normal scarring; micrognathia
  1. Autosomal recessive
  2. Biochemical defect: COL1A1, COL1A2
  3. Gene locus: 17q21.31-q22, 7q22.1
- Ehlers–Danlos syndrome VIII. Periodontal type: moderate joint and skin involvement; periodontitis, gingival regression, tooth loss

1. Autosomal dominant
2. Biochemical defect unknown
- Ehlers–Danlos syndrome X. Fibronectin type: similar to EDS type II; striae distensae; prominent bruising; abnormal clotting studies; normal skin texture
  1. Autosomal recessive
  2. Biochemical defect: fibronectin-1
  3. Gene locus: 2q34

### Diagnosis

- Clinical presentation
- Genetic testing
- Histology: large, irregular collagen fibrils in Ehlers–Danlos syndrome types I, II, III

### Differential diagnosis

- Cutis laxa
- Normal hypermobility

### Treatment

- Protection against injury to skin and joints
- Orthopedic management with physical therapy and braces if needed

### Prognosis

- Depends upon type
- Stable or worsens with injury
- Vascular type (Ehlers–Danlos syndrome type IV) has a guarded prognosis, because of vascular or bowel rupture

### References

- Beighton P. The Ehlers–Danlos syndrome. McKusick's Heritable Disorders of Connective Tissue. Mosby–Year Book: St Louis. MO 1993: 189–251
- Byers PH. Ehlers–Danlos syndrome: recent advances and current understanding of the clinical and genetic heterogeneity. J Invest Dermatol 1994; 103: 47S–52S
- Byers PH. Ehlers–Danlos syndrome type IV: a genetic disorder in many guises. J Invest Dermatol 1995; 105: 311–13
- Dahan D, Fenichel GM, El-Said R. Neurocutaneous syndromes. Adolesc Med State Art Rev 2002; 13: 495–509
- Germain DP. Clinical and genetic features of vascular Ehlers–Danlos syndrome. Ann Vasc Surg 2002; 16: 391–7
- Henry F, Goffin V, Piérard-Franchimont C, Piérard GE. Mechanical properties of skin in Ehlers–Danlos syndrome, types I, II, and III. Pediatr Dermatol 1996; 13: 464–7
- Mao JR, Bristow J. The Ehlers–Danlos syndrome: on beyond collagens. J Clin Invest 2001; 107: 1063–9

Myllyharju J, Kivirikko KI. Collagens and collagen-related diseases. *Ann Med* 2001; 33: 7–21

Sidhu-Malik NK, Wenstrup RJ. The Ehlers–Danlos syndromes and Marfan syndrome: inherited diseases of connective tissue with overlapping clinical features. *Semin Dermatol* 1995; 14: 40–6

## Cutis laxa

### Major points

- Skin hangs in loose folds from birth or may develop during childhood or adolescence and becomes inelastic giving a ‘hound dog’ appearance
- Generalized elastic tissue abnormality predisposing to:
  1. Inguinal hernias
  2. Lax joints
  3. Bronchiectasis with pulmonary emphysema
  4. Mitral valve prolapse
  5. Aortic aneurysm
  6. Gastrointestinal diverticula
  7. Prolapse of the rectum or uterus
  8. Bladder or urinary tract diverticula

### Pathogenesis

- Autosomal dominant (milder) – usually involves skin only
- Mutations in elastin (ELN) or fibulin-5 (FBLN5)
- Gene 14q32.1, 5q23.3-q31.2
- Autosomal recessive (severe): mutation in fibulin-5 (FBLN5) gene

### Diagnosis

- Clinical presentation
- Histology: marked fragmentation or diminution of elastic fibers

### Differential diagnosis

- Ehlers–Danlos syndrome
- Beare–Stevenson syndrome
- Costello syndrome
- Michelin tire baby syndrome
- Marfan syndrome
- Menkes kinky hair syndrome

### Treatment

- None specific
- Surgery for cosmesis

## Prognosis

- Slowly progressive

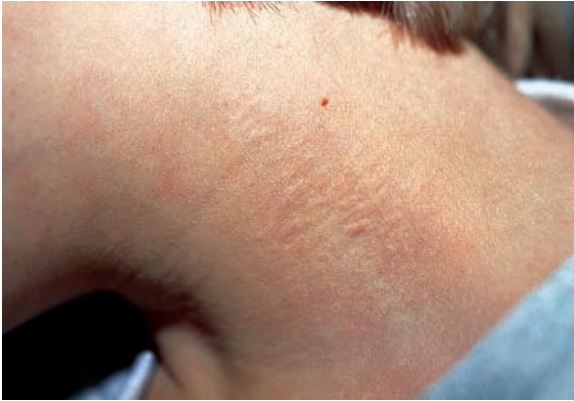## References

- Andiran N, Sarikayalar F, Saraclar M, Caglar M. Autosomal recessive form of congenital cutis laxa: more than the clinical appearance. *Pediatr Dermatol* 2002; 19: 412–14
- Baldwin L, Kumrah L, Thoppuram P, Bhattacharji S. Congenital cutis laxa (dermatochalasia) with cardiac valvular disease. *Pediatr Dermatol* 2001; 18: 365–6
- Banks ND, Redett RJ, Mofid MZ, Manson PN. Cutis laxa: clinical experience and outcomes. *Plast Reconstruct Surg* 2003; 111: 2434–42
- Hwang ST, Williams ML, McCalmont TH, Frieden IJ. Sweet’s syndrome leading to acquired cutis laxa (Marshall’s syndrome) in an infant with  $\alpha_1$ -antitrypsin deficiency. *Arch Dermatol* 1995; 131: 1175–7
- Orlow SJ. Cutaneous findings in craniofacial malformation syndromes. *Arch Dermatol* 1992; 128: 1379–86
- Sarkar R, Kaur C, Kanwar AJ, Basu S. Cutis laxa in seven members of a north-Indian family. *Pediatr Dermatol* 2002; 19: 229–31

## Pseudoxanthoma elasticum

### Major points

- Xanthoma-like papules (‘plucked chicken’ appearance) found in flexural areas and neck which thicken with age; other areas periumbilical, antecubital fossae, wrists, popliteal fossae
- Small (1–3 mm) yellowish papules in a linear or reticular pattern, may be in confluent plaques (Figure 20.19)
- Perforating lesions with hyperkeratosis (e.g. elastosis perforans serpiginosa)
- Abnormal elastic tissue in arteries
- Hyperextensible skin and joints
- Marfanoid features
- Hypertension
- Cerebrovascular accidents
- Gastrointestinal hemorrhages caused by cracking of calcified vessels
- Cardiovascular disease
- Arteriosclerosis
- Myocardial infarction (can be seen in teenagers)
- Ocular abnormalities:
  1. Angioid streaks in retina (breaks in Bruch membrane)



**Figure 20.19** Pseudoxanthoma elasticum – firm, yellow papules on the sides of the neck as a presenting sign

- 2. Loss of vision, drusen, peau d'orange or maculopathy
- Autosomal dominant or recessive

#### *Pathogenesis*

- Aberrant calcification of elastic fibers
- Gene locus: 16p13.1
- Gene: ABCC6 (ATP-binding cassette)

#### *Diagnosis*

- Major criteria
  1. Characteristic skin involvement
  2. Histology: fragmented elastic tissue, clumped with calcium deposits demonstrated by von Kossa stain; calcification in vessels involving elastic media and intima
  3. Characteristic ocular disease
- Minor criteria
  1. Characteristic histologic features of nonlesional skin
  2. Family history of pseudoxanthoma elasticum in first-degree relative

#### *Differential diagnosis*

- Xanthomas
- Connective tissue nevus
- D-Penicillamine-induced skin lesions

#### *Treatment*

- Close observation for gastrointestinal hemorrhage and cardiovascular abnormalities
- Surgical excision of abnormal skin rarely indicated
- Possible restriction of calcium in childhood and adolescence

#### *Prognosis*

- Depends upon type of pseudoxanthoma elasticum; some have more severe internal involvement than others

#### *References*

- Balus L, Amantea A, Donati P, et al. Fibroelastolytic papulosis of the neck: a report of 20 cases. *Br J Dermatol* 1997; 137: 461–6
- Hacker SM, Ramos-Caro FA, Beers BB, Flowers FP. Juvenile pseudoxanthoma elasticum: recognition and management. *Pediatr Dermatol* 1993; 10: 19–25
- Lebwohl M, Halperin J, Phelps RG. Brief report: occult pseudoxanthoma elasticum in patients with premature cardiovascular disease. *N Engl J Med* 1993; 329: 1237–9
- Lebwohl M, Neldner K, Pope M, et al. Classification of pseudoxanthoma elasticum: report of a consensus conference. *J Am Acad Dermatol* 1994; 30: 103–7
- Le Saux O, Urban Z, Tschuch C, et al. Mutations in a gene encoding an ABC transporter cause pseudoxanthoma elasticum. *Nature Genet* 2000; 25: 223–7
- Ohtani T, Furukawa F. Pseudoxanthoma elasticum. *J Dermatol* 2002; 29: 615–20
- Uitto J, Pulkkinen L, Ringpfeil F. Progress in molecular genetics of heritable skin diseases: the paradigms of epidermolysis bullosa and pseudoxanthoma elasticum. *J Invest Dermatol Symp Proc* 2002; 7: 6–16

### **Gardner syndrome**

#### *Major points*

- Multiple gastrointestinal polyps (mainly colon) with 100% risk for adenocarcinoma (adolescence to adulthood)
- Osteomas - especially of mandible, maxilla and facial bones
- Epidermal cysts – typical, multiple or large
- Desmoid tumors – most often occur at sites of scars (25%)
- Fibromas (skin, subcutaneous tissues, mesentery)
- Congenital hypertrophy of retinal pigment epithelium – bilateral dark brown patches on funduscopy
- Autosomal dominant with 100% penetrance

#### *Pathogenesis*

- Gene locus: chromosome 5q21-q22
- Gene: APC gene (adenomatous polyposis coli) – a tumor suppressor gene



### Diagnosis

- Histology of polyps – adenomatous type
- Histology of epithelial cysts: lined with epithelial cells

### Differential diagnosis

- Familial polyposis
- Peutz–Jeghers syndrome
- Cowden syndrome
- Common epidermal cysts
- Bannayan–Riley–Ruvalcaba syndrome

### Treatment

- Screening should begin at age 5 years for polyps in family members
- Prophylactic colectomy in teens is recommended
- Surveillance for secondary findings by physician familiar with the disorder
- Desmoid tumors – suggest excision; 50% recurrence rate; sulindac has been reported to result in regression in some patients

### Prognosis

1. Poor if colon not removed before cancer begins

### References

- Armstrong JG, Davies DR, Guy SP, et al. APC mutations in familial adenomatous polyposis families in the northwest of England. *Hum Mutat* 1997; 10: 376–80
- Gregory B, Ho VC. Cutaneous manifestations of gastrointestinal disorders. Part I. *J Am Acad Dermatol* 1992; 26: 153–66
- Herrmann SM, Adler YD, Schmidt-Petersen K, et al. The concomitant occurrence of multiple epidermal cysts, osteomas and thyroid gland nodules is not diagnostic for Gardner syndrome in the absence of intestinal polyposis: a clinical and genetic report. *Br J Dermatol* 2003; 149: 877–83
- Parks ET, Caldemeyer KS, Mirowski GW. Gardner syndrome. *J Am Acad Dermatol* 2001; 45: 940–2
- Quesnel S, Malkin D. Genetic predisposition to cancer and familial cancer syndromes. *Pediatr Clin N Amer* 1997; 44: 791–808
- Rustigi AK. Hereditary gastrointestinal polyposis and nonpolyposis syndromes. *N Engl J Med* 1994; 331: 1694–702

### Cowden disease

Synonym: multiple hamartoma syndrome

### Major points

- Can present in childhood with craniomegaly
- Multiple hamartomas of ectodermal, endodermal, and mesodermal origin
- Trichilemmomas (especially facial)
- Facial papules, often grouped around the mouth, nose or ears, usually evident by age 20 years
- Oral papillomatosis (cobblestoning); can be seen in esophagus and duodenum
- Palmoplantar keratoses
- Other findings (seen in teens/adults)
  1. Strong association with malignancy of breast (33%) and thyroid (5%)
  2. Fibrocystic disease of the breast and follicular adenocarcinoma of the breast in women (75%)
  3. Thyroid adenoma or goiter (65%)
  4. Gastrointestinal polyps in both large and small bowel
  5. Ovarian, cervical and uterine cancer
- Autosomal dominant

### Pathogenesis

- Gene locus: 10q23.3
- Gene: PTEN – a tumor suppressor gene

### Diagnosis

- Clinical findings
- Histology: trichilemmomas which arise from outer root sheath; multiple biopsies may be necessary; keratoses show hyperkeratotic papillomas

### Differential diagnosis

- Basal cell nevus syndrome
- Neurofibromatosis
- Gardner syndrome
- Tuberous sclerosis

### Treatment

- Close observation for thyroid, breast and gynecologic cancer in females; bladder cancer in males
- Surgical removal of facial papules
- Close follow-up with physician familiar with disorder

### Prognosis

- Depends upon complications

## References

- Eng C. PTEN: one gene, many syndromes. *Hum Mutat* 2003; 22: 183–98
- Hanssen AMN, Fryns JP. Cowden syndrome. *J Med Genet* 1995; 32: 117–19
- Hanssen AMN, Werquin H, Suys E, Fryns JP. Cowden syndrome: report of a large family with macrocephaly and increased severity of signs in subsequent generations. *Clin Genet* 1993; 44: 281–6
- Lynch ED, Ostermeyer EA, Lee MK, et al. Inherited mutations in PTEN that are associated with breast cancer, Cowden disease, and juvenile polyposis. *Am J Hum Genet* 1997; 61: 1254–60
- Marsh DJ, Kum JB, Lunetta KL, et al. PTEN mutation spectrum and genotype-phenotype correlations in Bannayan–Riley–Ruvalcaba syndrome suggest a single entity with Cowden syndrome. *Hum Mol Genet* 1999; 8: 1461–72
- Marsh D, Zori R. Genetic insights into familial cancers—update and recent discoveries. *Cancer Lett* 2002; 181: 125–64
- Tsao H. Update on familial cancer syndromes and the skin. *J Am Acad Dermatol* 2000; 42: 939–69
- Waite KA, Eng C. From developmental disorder to heritable cancer: it's all in the BMP/TGF-beta family. *Nature Rev Genet* 2003; 4: 763–73
- Waite KA, Eng C. Protean PTEN: form and function. *Am J Hum Genet* 2002; 70: 829–44

## Ataxia–telangiectasia

Synonym: Louis–Bar syndrome

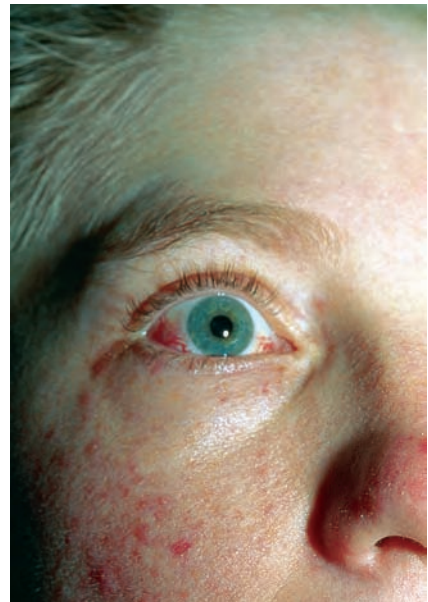### Major points

- Progressive cerebellar ataxia beginning at age ~2 years
- Skin findings
  1. Telangiectasias begin on ears, conjunctiva and flexural folds of extremities usually at about 3–5 years, and progress to malar areas and the V of the chest (Figure 20.20)
  2. Granulomatous plaques (sterile)
  3. Vitiligo
  4. Poliosis
  5. Premature graying of hair
  6. Hypo- or hyperpigmentation
  7. Atrophy of the skin
  8. Chronic skin infections
  9. Acanthosis nigricans

- Frequent sinopulmonary infections: bronchitis, rhinitis, pneumonia, bronchiectasis
  1. Defective cell-mediated: lymphopenia, impaired lymphocyte transformation
  2. Humoral immunity: IgA and IgE deficiency
- Ocular findings
  1. Telangiectasias beginning about age 2–6 years on bulbar conjunctiva
  2. Nystagmus
  3. Strabismus
  4. Blepharitis
- Structural anomalies of thymus and lymph nodes
- Elevated  $\alpha$ -fetoprotein
- Progressive mental and neurological deterioration
- Breaks and rearrangements of chromosomes particularly 7, 14
- High incidence of neoplastic disorders (e.g. lymphoma, leukemia, breast carcinomas, etc.) in patients and carriers
- Autosomal recessive; male/female ratio = 1

### Pathogenesis

- Caused by a mutation in ATM gene which repairs chromosomal strand breakage
- Gene locus: 11q22
- Gene: ATM



**Figure 20.20** Ataxia–telangiectasia – telangiectasias on the conjunctivae

### Diagnosis

- Clinical diagnosis with gene verification
- Histology: nonspecific; dilated blood vessels of subpapillary plexus

### Differential diagnosis

- Hereditary hemorrhagic telangiectasia
- Angioma serpiginosum
- Generalized essential telangiectasia

### Treatment

- Supportive, with antibiotics, respiratory therapy, physical therapy
- Genetic counseling

### Prognosis

- Usually fatal in second decade from secondary infections, respiratory failure, or malignancies

### References

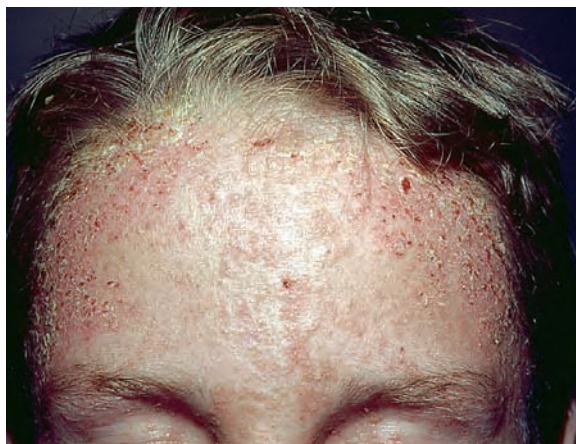- Barbagallo JS, Kolodzieh MS, Silverberg NB, Weinberg JM. Neurocutaneous disorders. *Dermatol Clin* 2002; 20: 547–60, viii
- De la Torre C, Pincheira J, Lopez-Saez JF. Human syndromes with genomic instability and multiprotein machines that repair DNA double-strand breaks. *Histol Histopathol* 2003; 18: 225–43
- Koenig M. Rare forms of autosomal recessive neurodegenerative ataxia. *Semin Pediatr Neurol* 2003; 10: 183–92
- Perlman S, Becker-Catania S, Gatti RA. Ataxia–telangiectasia: diagnosis and treatment. *Semin Pediatr Neurol* 2003; 10: 173–82
- Swift M, Morrell D, Massey RB, Chase CL. Incidence of cancer in 161 families affected by ataxia – telangiectasia. *N Engl J Med* 1991; 325:1831–6

## Darier disease

Synonymy: keratosis follicularis, Darier–White disease

### Major points

- Firm greasy, yellow-brown, crusted papules which coalesce into plaques (Figure 20.21)
- Distribution: scalp, face, seborrheic and flexural areas, dorsa of hands and feet
- Palm and sole keratoses or minute pits
- Malodorous
- Onset usually between 8 and 15 years



**Figure 20.21** Darier disease – scaling on the face resembling seborrheic dermatitis

- Mucous membranes: white cobblestoning which coalesces into plaques; oropharynx, larynx and anorectal mucosa may be involved
- Nail changes: white or red longitudinal bands, V-shaped nicks at distal margin, subungual hyperkeratoses
- T-cell abnormalities in some patients
- Increased susceptibility to infections
- Mental disturbances or mild retardation
- Autosomal dominant, with male/female ratio >1

### Pathogenesis

- Gene locus: 12q23–24.1
- Gene: SERCA 2 (ATP 2A2) – plays a role in cell adhesion

### Diagnosis

- Clinical findings with classic histology of skin
- Histology: suprabasal acantholysis and dyskeratosis; characteristic corps ronds and corps grains in stratum corneum

### Differential diagnosis

- Seborrhea
- Transient acantholytic dermatosis
- Pemphigus foliaceus
- Hailey–Hailey disease

### Treatment

- Emollients
- Keratolytic agents

- Intermittent topical steroids for erythema or irritation
- Topical retinoids
- Systemic retinoids
- Antibiotics for secondary infection

### *Prognosis*

- Persistent, chronic dermatosis with exacerbations and partial remissions
- Aggravated by sunlight and heat
- Responds to oral retinoids

### *References*

- Burge SM, Wilkinson JD. Darier–White disease: a review of the clinical features in 163 patients. *J Am Acad Dermatol* 1992; 27: 40–50
- Cooper SM, Burge SM. Darier's disease: epidemiology, pathophysiology, and management. *Am J Clin Dermatol* 2003; 4: 97–105
- Devries DT, Warren SJ. Recent advances in intraepidermal blistering diseases. *Adv Dermatol* 2002; 18: 203–45
- Kennedy JL, Berg D, Bassett AS, et al. Genetic linkage for Darier disease (keratosis follicularis). *Am J Med Genet* 1995; 55: 307–10
- Munro CS. The phenotype of Darier's disease: penetrance and expressivity in adults and children. *Br J Dermatol* 1992; 127: 126–30
- O'Malley MP, Haake A, Goldsmith L, Berg D. Localized Darier disease. Implications for genetic studies. *Arch Dermatol* 1997; 133: 1134–8
- Peacocke M, Christiano AM. Bumps and pumps, SERCA 1999. *Nature Genet* 1999; 21: 252–3





# THERAPY

## TOPICAL THERAPY

### Major points

- Treatment should be simple
- Teach patients how to apply medications
- Write prescriptions for steroids in sizes of tubes (e.g. 15, 30, 45, 60, 90, 120 g), not just 'trade size'
  1. Patient may receive too little or too much medicine if not written correctly
  2. Include the diagnosis in addition to instructions so that there is no confusion (e.g. 'Apply at bedtime for acne')
- Thin application is desirable for most medicines except emollients, where thick application is preferred
- Apply moisturizers to damp skin to retain hydration
- Estimates of coverage of the skin can be made by using the 'Rule of Nines', in which the body surface is divided into 11 equal parts, each constituting ~9% of the total body surface area
  1. Head
  2. Arm (one)
  3. Chest (anterior)
  4. Back
  5. Abdomen
  6. Buttocks, lumbar area
  7. Leg (half each)
- Each area can be covered by ~2 g of cream or ointment (See Table 21.1)
- Factors which increase percutaneous absorption of a medication:
  1. Inflammation
  2. Hydration (after a bath)

3. Occlusion with plastic wraps, or diapers
  4. Epidermal breakage or injury
  5. Heat
  6. Type of vehicle
- Topical agents are composed of: active medication and vehicle

## VEHICLES

- Vehicles have a profound impact on the medication's delivery and stability

**Table 21.1 Amount of medicine to dispense**

Area	One application in grams	BID application for 2 weeks in grams
Face	2	60
Hands	2	60
Head	2	60
Groin	2	60
One arm	3	80
Anterior chest	3	80
Back	3	80
One leg	4	120
Whole body	30–60	840–1680

Adapted from Weston WL, Lane AT, Morelli JG. Color Textbook of Pediatric Dermatology. Mosby: St Louis, 1996: 358

## Ointments

- Simplest lubricating vehicle
- Ointments are oleaginous pure greases (e.g. petrolatum, lanolin) or greases with a small amount of water suspended in them
- Leave a greasy film on the skin, causing heat retention and water retention
- Indications:
  1. Dry, cracked skin (atopic dermatitis)
  2. Scaling (psoriasis)
  3. Lubrication
- Do not use (as a general rule of thumb):
  1. Moist skin areas (axillae, groin)
  2. Hot humid environments
- Disadvantages: messy, stains clothing (e.g. petrolatum)
- Advantages: fewest inactive ingredients (i.e. fewer sensitizing agents)

## Creams

- Emulsion of water and oil plus chemical emulsifiers, preservatives and fragrances
- Creams require preservatives and stabilizers because of the addition of water
- Easier to use than ointments and cosmetically more acceptable
- Less occlusive than an ointment
- Indications:
  1. Dry skin in humid climates
  2. Semifold areas (antecubital area and neck)
  3. Face
- Do not use:
  1. Hairy scalp (in general)
  2. If allergic or sensitive to preservatives in a specific product

## Emollient creams

- Generally more oily than nonemollient types
- Smooth application
- More moisturizing than creams

## Solutions

- Solutions contain alcohol and propylene glycol with the active ingredient
- Completely evaporate, leaving the active medication on the skin

- Indications:
  1. Scalp
  2. Hairy areas
  3. Moist areas (toewebs)
- Do not use:
  1. Broken skin (causes stinging)
  2. Very dry skin

## Lotions

- Lotions are mainly water with some lipids added
- Indications:
  1. Mild dry skin
  2. Moist folds
- Examples: Keri Lotion, Lubriderm, Eucerin Lotion, numerous others

## Aerosols, sprays, and foams

- These products are solutions with a propellant system
- Indications:
  1. Scalp: with a small tubular applicator nozzle, aerosols are easy to use on the scalp
  2. Body: can cover large areas with a very fine coat of medication (e.g. insect repellents)
- Advantages
  1. Cosmetically elegant
  2. Convenient, easy to use
- Disadvantages: may be drying and irritating

## Gels

- Gelled propylene glycol solutions which liquify on contact with skin
- Advantages:
  1. Permit good penetration of medications
  2. Leave little residue
- Disadvantage: very drying
- Indications:
  1. Facial dermatoses
  2. Scalp dermatoses
- Do not use on irritated or broken skin (causes stinging)
- Examples: tretinoin gel, steroid gels

## Tape/plasters

- Tape impregnated with medicament
- Advantage

- 1. Stays in place
- Indications:
  1. Thickened, pruritic plaques of lichen simplex chronicus
  2. Warts
- Examples: Cordran tape, salicylic acid plasters

## Shake lotions

- Liquid preparation to which powder has been added
- Must be shaken to suspend the powder in solution
- Antipruritics (menthol, camphor) often added
- Examples: calamine lotion
- Indications:
  1. Mild cooling and soothing effect
  2. Weeping, oozing dermatitis (e.g. poison ivy dermatitis)

## Pastes

- Creams or ointments with powder added
- Disadvantages: thick and stiff in consistency
- Indications: barrier cream
- Example: zinc oxide paste

## Powders

- Consist of fine particles of talc
- Indications:
  1. Increased surface area with a drying effect
  2. Moist sweaty areas (axillae, groin, feet)
  3. Reduce friction
- Examples: nystatin powder, Zeasorb AF
- Disadvantage: delivery of medication relatively poor

## Oils

- Oily monophasic solution
- Examples: mineral oil, Dermasmoothe Oil

## Oil-free products

- All avoid ingredients with the word 'oil'; however, may contain oils or fats which do not contain the word 'oil' (e.g. lanolin)
- May contain waxes or oily hydrocarbons
- Disadvantage: can be drying

- Borderline oil-free products, although not technically oils or fats, can contain oil-like emollient esters which may be comedogenic

## PRODUCTS AND TREATMENT

### Wet dressings

- Indications
  1. Useful for first 24–72 hours of an acute weeping dermatitis
  2. Evaporation of water is cooling, causing vasoconstriction
  3. Relief of pruritus by increasing humidity
  4. Helps remove crusts
- Examples: water, saline
- Examples:
  1. Burow's solution (aluminum acetate) for a more drying effect (e.g. Bluboro powder, Boropak powder, Domeboro powder or tablets)
  2. Dakin's solution (sodium hypochlorite) for antisepsis (strengths: 0.25%, 0.5%)
  3. Oatmeal bathing products (e.g. Aveeno)

### Topical corticosteroids

- Potency of topical steroids (Table 21.2) based on vasoconstriction assay, roughly corresponds to anti-inflammatory properties
- Indications: inflammatory skin disorders (steroids cause vasoconstriction and prevent inflammation)
  1. Low potency
    - a. Ideal in infants
    - b. Adults/teens – face, intertriginous, genitals
  2. Mid-potency
    - a. Atopic dermatitis
    - b. Psoriasis
  3. High potency/ultrapotency
    - a. Palms and soles
    - b. Psoriasis if thickened plaques
    - c. Lichen simplex chronicus
    - d. Acute contact dermatitis (e.g. poison ivy dermatitis)
  4. High-potency and ultrapotency topical steroids should not be used in children except in short courses for specific conditions
- Dose:
  1. Use a mid-strength steroid twice daily for 3–10 days until symptoms have subsided, then



**Table 21.2 Potency of topical steroids**

<i>Brand name</i>	<i>Generic name</i>
<b>Group I (ultrapotent)</b>	
Cormax Ointment 0.05%	Clobetasol propionate
Cormax Scalp Solution 0.05%	Clobetasol propionate
Cordran Tape 4 µg/cm <sup>2</sup>	Flurandrenolide
Diprolene Cream, Ointment, Gel 0.05%	Betamethasone dipropionate
Olux Foam 0.05%	Clobetasol propionate
Psorcon Ointment 0.05%	Diflorasone diacetate
Temovate Cream, Ointment, Gel, E Emollient Cream 0.05%	Clobetasol propionate
Ultravate Cream, Ointment 0.05%	Halobetasol propionate
<b>Group II (potent)</b>	
Cyclocort Ointment 0.1%	Amcinonide
Diprolene AF Cream 0.05%	Betamethasone dipropionate
Diprosone Ointment 0.05%	Betamethasone dipropionate
Elocon Ointment 0.1%	Mometasone furoate
Florone Ointment 0.05%	Diflorasone diacetate
Halog Cream, Oint., Sol., Emollient Cream 0.1%	Halcinonide
Kenalog Ointment 0.5%	Triamcinolone acetonide
Lidex Cream, Gel, Ointment, Gel 0.05%	Fluocinonide
Topicort Ointment, Cream 0.25%	Desoximetasone
Topicort Gel 0.05%	Desoximetasone
<b>Group III (high mid-strength)</b>	
Aristocort A Ointment 0.1%	Triamcinolone acetonide
Aristocort-HP Ointment	Triamcinolone acetonide
Cutivate Ointment 0.05%	Fluticasone propionate
Cyclocort Cream and Lotion 0.1%	Amcinonide
Florone Cream 0.05%	Diflorasone diacetate
Halog Ointment 0.1%	Halcinonide
Lidex E Cream 0.05%	Fluocinonide
Topicort LP Cream 0.05%	Desoximetasone
Valisone Ointment 0.1%	Betamethasone valerate
<b>Group IV (middle mid-strength)</b>	
Aristocort 0.1% Cream	Triamcinolone acetonide
Cordran Ointment 0.05%	Flurandrenolide
Dermatop Ointment 0.1%	Prednicarbate
Elocon Cream, Lotion 0.1%	Mometasone furoate
Kenalog Cream, Ointment 0.1%	Triamcinolone acetonide
Luxiq Foam 0.12%	Betamethasone valerate
Synalar Ointment 0.025%	Fluocinolone acetonide
Westcort Ointment 0.2%	Hydrocortisone valerate

Continued...

- reduce to once daily, eventually weaning off medication; emollients are often helpful
2. Face and groin:
    - a. Only use low-potency steroids, class VI, VII (e.g. hydrocortisone 1–2.5%)

- b. Prone to atrophy, striae and telangiectasias
3. Tachyphylaxis can occur with high-potency/ultrapotent steroids
  - a. Caused by intense vasoconstriction, followed by rebound vasodilatation

Table 21.2 Continued

<i>Brand name</i>	<i>Generic name</i>
<b>Group V (low mid-strength)</b>	
Aclovate Cream, Ointment 0.05%	Alclometasone dipropionate
Cordran Cream, Lotion 0.05%	Flurandrenolide
Cutivate Cream 0.05%	Fluticasone propionate
Dermatop Cream 0.1%	Prednicarbate
Kenolog Cream, Lotion 0.1%	Triamcinolone acetonide
Locoid Cream, Ointment, Solution 0.1%	Hydrocortisone butyrate
Synalar Cream 0.025%	Fluocinolone acetonide
Westcort Cream 0.2%	Hydrocortisone valerate
Dermatop Cream 0.1%	Prednicarbate
<b>Group VI (low strength)</b>	
Aclovate Cream, Ointment 0.05%	Alclometasone dipropionate
DesOwen Cream, Lotion, Ointment 0.05%	Desonide
Synalar Cream, Solution 0.01%	Fluocinolone acetonide
Tridesilon Cream 0.05%	Desonide
<b>Group VII (lowest strength)</b>	
Hytone 0.5%, 1%, 2.5%, dexamethasone	Hydrocortisone 0.5%, 1%, 2.5%

- b. Most commonly occurs on the face (causing perioral dermatitis or steroid rosacea)
- Monitor:
  1. Adrenal axis suppression can occur with long-term or overuse of mid- or high-potency, or ultrapotent topical steroids
  2. Limit total dosage to <50 g/week in adult/teen
  3. Steroid addiction
    - a. Results from prolonged use of mid-strength or high-potency steroids, particularly on the face
    - b. With discontinuation, rebound vasodilatation occurs, resulting in patients' continuing to apply steroid for relief
    - c. With prolonged use, permanent redness, thinning and fine wrinkling, and acne can result
    - d. Treatment – substitute a bland ointment and wean down to lower-potency steroids with eventual discontinuance
- Disadvantages/side-effects – accentuated with higher concentrations
  1. Atrophy manifestations
    - a. Thinning of skin/wrinkling
    - b. Translucency of skin
    - c. Telangiectasias
    - d. Striae
    - e. Hypopigmentation
    - f. Glaucoma when used on eyelids
  2. Occlusion increases penetration and increases potency

### Oral corticosteroids

- Indications: inflammatory dermatoses, bullous dermatoses, urticaria, immunosuppressive therapy
- Types of oral corticosteroids:
  1. Prednisolone (Delta-Cortef, Prelone, Pediapred, others)
    - a. Supplied: Prelone 15 mg/5 ml; Pediapred 5 mg/5 ml; tabs: 5 mg
  2. Dexamethasone
    - a. Supplied: tabs: 0.25, 0.5, 0.75, 1, 1.5, 2, 4, 6 mg; liquid: 0.5 mg/5 ml; 0.1 mg/ml; 1 mg/ml
    - b. Dose: child: 0.08–0.3 mg/kg/24 hours given every 6–12 hours; adults: 0.75–9 mg/24 hours
  3. Prednisone
    - a. Supplied: Tabs: 1, 2.5, 5, 10, 20, 50 mg; liquid: 1 mg/ml, 5 mg/ml

- b. Dose: 0.5–2 mg/kg per 24 hours given once daily to four times a day
- 4. Equivalents:
  - a. Prednisone 5 mg = 0.75 mg dexamethasone
- 5. Stress dose (prednisolone/prednisone): 8–24 mg/m<sup>2</sup>/24 hours (approximately 3 mg/day in a 6-month-old) divided BID, given during stressful event, fever, surgery

### Intralesional corticosteroids

- Indications: keloids, alopecia areata
- Dose
  - 1. Keloids: 10–40 mg/ml
  - 2. Alopecia areata 2.5–5 mg/ml
- Supplied: triamcinolone 3 mg/ml, 10 mg/ml, 25 mg/ml, 40 mg/ml
- Monitor: atrophy, hypopigmentation (usually not permanent)

### Anthralin

- Consists of tricyclic hydrocarbons made from the reduction of anthraquinone
- Indications:
  - 1. Antimitotic effect on epidermis
  - 2. Psoriasis
- Supplied: 0.1%, 0.25%, 0.5%, 1% cream (Drithocrema)
- Dose:
  - 1. Apply 1–2 times/day
  - 2. Short contact therapy
    - a. Apply to affected area for 5–10 minutes once daily
    - b. Wash off with a pH-neutral soap (e.g. Dove)
    - c. Start with mid-strength cream and advance in strength and time of exposure as tolerated
- Disadvantages:
  - 1. Stains clothing and skin
  - 2. Difficult to use, especially over large areas
  - 3. Irritating
  - 4. Avoid mucosal contact

### Tar

- Derived from distillation of coal
- Indications: anti-inflammatory, keratolytic, antipruritic, antimitotic

- 1. Psoriasis
- 2. Eczema
- Dose: apply BID, in direction of hair growth (not against, in order to avoid tar folliculitis)
- Supplied:
  - 1. Crude coal tar (CCT) 1–10% USP, compound in petrolatum or other base
  - 2. Tar gels (e.g. Estar 5%, Psorigel 17.5%)
    - a. Clear and light brown
    - b. Equivalent to CCT 5%
    - c. Should be covered with an emollient (e.g. petrolatum) afterwards, as these products by themselves are drying
  - 3. Liquor carbonis detergens (LCD): an alcoholic extract of coal tar
    - a. LCD 5%–10% equivalent to CCT 1%–2%
    - b. Must be compounded
  - 4. Tar shampoos: apply to wet hair and leave on for 5–10 minutes; then rinse
  - 5. Tar oils
    - a. Apply to skin 1–2 times/day
    - b. Supplied (over the counter OTC): Cutar Emulsion 1.5%, Doak Tar Oil 2%
  - 6. Tar bath oils
    - a. Add to bath water, soak for 10–20 minutes
    - b. Supplied: Balnetar (2.5% coal tar)
- Disadvantages: stains skin and clothing, malodorous

### Calcipotriene

- Calcipotriene is a synthetic analog of vitamin D<sub>3</sub>
- Indications: psoriasis, morphea
- Dose: apply BID, thin application; do not use on face
- Examples: Dovonex 0.005% ointment, cream (30 g, 60 g, 100 g), scalp solution (60 ml)
- Disadvantages: burning and itching, expensive

### Moisturizers with or without keratolytics

- Indications: dry skin (xerosis)
- Dose: apply 2–4 times/day as needed
- Disadvantages:
  - 1. Frequent application necessary
  - 2. Moisturizers contain water; preservatives are necessary to avoid contamination and contact dermatitis may occur
  - 3. Stinging

- Examples:
  1. Urea cream and lotions: cream 10% (AquaCare, Nutraplus), cream 20% (Carmol 20), lotion 10% (Nutraplus, AquaCare, Carmol 10)
  2. Lactic acid-containing lotions: 5% (Lacticare), 12% ammonium lactate (Lac-Hydrin – Rx), 6 % ammonium lactate (Lac-Hydrin – OTC)
  3. Lactic acid plus urea: Eucerin Plus Creme and Lotion (2.5% lactic acid plus 10% urea)
  4.  $\alpha$ -Hydroxyacids (glycolic acid): Alpha Hydrox (7% glycolic acid), Curel Alpha Hydroxy Dry Skin Lotion, Aqua Glycolic (6% glycolic acid)
  5. Bath oils: RoBathol, Lubriderm Bath Oil, Alpha Keri Bath Oil, Neutrogena Sesame Seed Body Oil

## Keratolytic agents

- Indications:
  1. Enhance stratum corneum desquamation
  2. Used to remove the superficial or thick scale in psoriasis, ichthyosis, keratosis pilaris or warts
- Disadvantages:
  1. Irritating; care should be used when applying them to the skin or scalp
  2. Systemic absorption of potentially toxic products may occur. Limit to <10% of skin surface area
- Examples:
  1. Scalp preparations:
    - a. Massage into scalp and leave on overnight under a shower cap. As an alternative, leave on scalp for several hours before shampooing it out
    - b. DermaSmothe/FS (fluocinolone acetonide 0.01% in peanut oil, mineral oil)
    - c. P&S Oil (< 1% phenol and saline solution)
    - d. Mineral oil plus salicylic acid
  2. Topical keratolytic agents:
    - a. Salicylic acid 0.5–6%. Can be compounded to preparations with creams or emollients. Keralyt Gel (salicylic acid 6%)
    - b. Whitfield's Ointment USP (salicylic acid 3%, benzoic acid 6% in polyethylene glycol ointment) – OTC
    - c. MG 217 Sal-Acid Ointment (3% salicylic acid) – OTC

- d. Salicylic acid preparations for warts: liquid or plasters: 14–40%, Mediplast 40%, Doctor Scholl's
- e. Acne washes 1–2% for acne preparations: Neutrogena Acne Wash
- f. Kerasal
3. Lactic acid: see Moisturizers
4.  $\alpha$ -Hydroxyacids: see Moisturizers

## Cleansers/soaps

- Indications:
  1. Help remove oil and dirt from skin
  2. Antibacterial or deodorant soaps help reduce bacteria concentrations on the skin
- Disadvantages:
  1. All soaps are irritating to broken skin
  2. Most soaps are drying and irritating
- Doses:
  1. In sensitive skin, neutral pH is preferred
  2. Examples of soap substitutes or mild soaps: Dove (unscented), Oil of Olay Bar, cetyl alcohol cleanser (Cetaphil, Aquanil), Purpose Gentle Cleansing Wash, Moisturel Sensitive Skin Cleanser, Cetaphil cleansing bar, Aveeno products (colloidal oatmeal)

## Shampoos

- Shampoos contain water, sodium lauryl sulfate (emulsifier), dispersing agents and fragrance
- Indications:
  1. Helps remove oil, dirt and scale from the scalp
  2. Dandruff shampoos can be keratolytic and suppress inflammation and epidermal turnover
- Dose:
  1. Medicated shampoos: apply to scalp, leave on for 5–10 minutes, then rinse
- Disadvantages: all shampoos are irritating and drying
- Supplied:
  1. Examples of less irritating shampoos are: Free and Clear
  2. Medicated shampoos
    - a. Selenium sulfide 1% (Selsun Blue - OTC), 2.5% (Selsun, Exsel- Rx)
    - b. Zinc pyrithione (Head & Shoulders, Zincon, Denorex, DHS Zinc)

- c. Ketoconazole (Nizoral 2% – Rx, 1% – OTC)
- d. Tar shampoos 0.5–2% tar (Sebutone, TGel, DHS-T, Zetar, Ionil-T, Pentrax, Tegrin, Vanseb-T, X-SebT)
- e. Keratolytic shampoos – help soften scales
  - i Salicylic acid 2% plus sulfur 2% (Sebulex, Ionil, Vanseb)
  - ii P&S Shampoo
  - iii TSal shampoo
- f. Steroid shampoo (Rx) – Capex Shampoo

### Antiperspirants

- Antiperspirants are liquid aluminum chloride hexahydrate in alcohol
- Indications: decrease sweating and odor; works by plugging sweat ducts
- Dose: apply at night; can cover with plastic wrap on hands and feet
- Examples: Drysol 20%, Xerac AC 6.25%

### Sunscreens

- Important factors
  1. Sun protection factor (SPF) is the ratio of time it takes to develop erythema with the sunscreen applied compared to the time it takes to develop erythema without the sunscreen. For example, SPF 10 means a person can theoretically spend 10 times longer in the sun without developing a sunburn. People with skin that burns easily (type I) should use the most protection, SPF >15. For heavy sun exposure, SPF >30 is advised
  2. Vehicle: determines whether sunscreen is waterproof, or water resistant
  3. Reapply sunscreen especially after swimming or sweating
  4. With the regular use of an SPF 15 sunscreen during the first 18 years of life, the lifetime incidence of nonmelanoma skin cancers has been estimated to be reduced by 78%
  5. Contact dermatitis to sunscreens can be caused by either the chemical or the vehicle. Treat with topical steroids, or if severe, a short course of oral steroids (5–7 days)
- Ingredients in sunscreens:
  1. Para-aminobenzoic acid (PABA) and PABA esters – partial UVB and no UVA protection

2. Cinnamates – full UVB protection
  3. Benzophenones – UVB and partial UVA protection
  4. Salicylates – full UVB, and no UVA
  5. Avobenzone (Parsol 1789) – UVA, no UVB
  6. Titanium dioxide and zinc oxide – physical sunblocks: entire UVB, UVA, visible light protection
- Types of sunscreen
    1. Physical barriers reflect and scatter UVB (e.g. titanium dioxide, zinc oxide; recommended especially for extremely sun-sensitive individuals)
    2. UVB blockers (e.g. para-aminobenzoic acid (PABA) and its derivatives)
    3. UVA blockers (e.g. benzophenone)

## COMMONLY USED DRUGS IN DERMATOLOGY

(Some of the indications are off-label – refer to Physician Desk Reference for indications)

### Antihistamines

- Cetirizine (Zyrtec)
  1. Dose: 2–6 years: 2.5 mg daily; maximum 5 mg daily; >6 years: 5–10 mg daily
  2. Supplied: 5 mg/5 ml; 5 mg, 10 mg
- Clemastine (Tavist-1)
  1. Dose: >6 years: 1–3 tsp BID
  2. Supplied: 0.67 mg/5 ml, 1.34 mg (OTC), 2.68 mg (Rx)
- Cyproheptadine (Periactin)
  1. Dose: 2–5 years: 2 mg BID–TID; 6–12 years: 4 mg BID–TID
  2. Supplied: 4 mg, 2 mg/5 ml
- Desloratadine (Clarinex)
  1. Dose: ≥12 years: 5 mg daily
  2. Supplied: 5 mg
- Diphenhydramine (Benadryl)
  1. Dose: 5 mg/kg per 24 hours PO, IV, IM given every 6–8 hours maximum 300 mg/24 hours
  2. Supplied: 12.5 mg/5 ml, 25 mg, 50 mg
- Fexofenadine (Allegra)
  1. Dose: 6–11 years: 30 mg BID; >12 years: 60 mg BID or 180 mg daily
  2. Supplied: 30 mg, 60 mg, 180 mg
- Hydroxyzine (Atarax, Vistaril)



1. Dose: <6 years, 2 mg/kg/24 hours divided every 6–8 hours >6 years 10–100 mg every 6 hours
2. Supplied: 10 mg/5 ml, 10 mg, 25 mg, 50 mg
- Loratadine (Claritin)
  1. Dose: >5 years: 5–10 mg daily
  2. Supplied: 5 mg/5 ml, 10 mg

## Antibiotics

- Amoxicillin (Amoxil)
  1. Dose: child: 20–40 mg/kg per 24 hours divided TID; Adult 250 mg TID
  2. Supplied: 125 mg/5 ml, 250 mg/5 ml, 250 mg, 500 mg, 875 mg
- Ampicillin (Omnipen, Principen, Totacillin)
  1. Dose: child: 50–100 mg/kg per 24 hours, given every 6 hours; adult 250–500 mg PO, IM, IV given every 6 hours
  2. Supplied: 125 mg/5 ml, 250 mg/5 ml
- Augmentin (amoxicillin plus clavulanic acid)
  1. Dose: child: 20–40 mg/kg per 24 hours, divided TID; adult: 250–500 mg BID–TID
  2. Supplied: 200 mg/5 ml, 400 mg/5 ml, 250 mg, 500 mg
- Azithromycin (Zithromax)
  1. Dose: child (6 months–12 years) 5–12 mg/kg per 24 hours; adult 500 mg daily once; then 250 mg daily for 4 days
  2. Supplied: 100 mg/5 ml, 200 mg/5 ml, 100 mg, 250 mg; Z–Pak: 500 mg for 1 day, then 250 mg daily for 4 days; Tri-Pak: 500 mg daily for 3 days
  3. Comments: take on empty stomach; hepatic excretion
- Cefaclor (Ceclor)
  1. Dose: 20–40 mg/kg per 24 hours given TID, adult: 250–500 mg TID
  2. Supplied: 125 mg/5 ml, 250 mg/5 ml, 250 mg, 500 mg
- Cefadroxil (Duricef)
  1. Dose: child: 30 mg/kg per 24 hours; give BID; adult: 500 mg BID
  2. Supplied: 125 mg/5 ml, 250 mg/5 ml, 500 mg/5 ml, 500 mg, 1000 mg
- Cephalexin (Keflex)
  1. Dose: child: 25–50 mg/kg per 24 hours; adult: 250–500 mg every 6 hours or QID
  2. Supplied: 125 mg/5 ml, 250 mg/5 ml, 250 mg, 500 mg
- Ciprofloxacin (Cipro)
  1. Dose: <6 years, 2 mg/kg/24 hours divided every 6–8 hours >6 years 10–100 mg every 6 hours
  2. Supplied: 10 mg/5 ml, 10 mg, 25 mg, 50 mg
- Clarithromycin (Biaxin)
  1. Dose: child: 7.5–15 mg/kg every 12 hours; adult: 250–500 mg BID
  2. Supplied: 125 mg/5 ml, 250 mg/5 ml, 250 mg, 500 mg
- Clindamycin
  1. Dose: child: 8–25 mg/kg per 24 hours divided TID–QID; adult: 150–450 mg QID
  2. Supplied: 75 mg, 150 mg, 300 mg, 75 mg/5 ml
- Cloxacillin (Cloxapen)
  1. Dose: 50 mg/kg per 24 hours (given every 6 hours); adult: 250–500 mg every 6 hours
  2. Supplied: 125 mg/5 ml, 250 mg, 500 mg
- Diaminodiphenylsulfone (Dapsone)
  1. Dose: child: 1–2 mg/kg per 24 hours given 1–2 times a day; adult: 25–150 mg per 24 hours
  2. Supplied: 25 mg, 100 mg
  3. Side-effects: methemoglobinemia, peripheral neuropathy, drug interactions, agranulocytosis
  4. Monitor:
    - a. Baseline CBC, glucose-6-phosphate dehydrogenase (G6PD), complete metabolic panel, neurologic evaluation;
    - b. CBC every week for 4 weeks, then once a month for 6 months, then every 6 months
    - c. Complete metabolic panel and neurologic examination every 3–4 months
- Dicloxacillin (Dynapen)
  1. Dose: child: 12.5–50 mg/kg per 24 hours, given QID; adult: 125–500 mg QID
  2. Supplied: 62.5 mg/5 ml, 250 mg, 500 mg
- Doxycycline (Doryx, Monodox, Vibramycin, Vibr-Tabs)
  1. Dose: child: 3–5 mg/kg per 24 hours; given BID; adult: 50–200 mg/24 hours, given BID
  2. Supplied: 25 mg/5 ml, 50 mg/5 ml, 50 mg, 100 mg
  3. Side-effects: phototoxicity, dizziness, esophagitis
- Erythromycin
  1. Dose: child: 50 mg/kg per 24 hours divided QID; adult: 250–500 mg QID
  2. Supplied: Eryped (EES) 200 mg/5 ml, 400 mg/5 ml, 400 mg; E-mycin 250 mg, 333 mg, 500 mg

3. Side-effects: nausea
- Minocycline (Dynacin, Minocin, Vectrin)
  1. Dose: 2–4 mg/kg per 24 hours; 50–100 mg BID
  2. Supplied: 50 mg/5 ml, 50 mg, 100 mg
  3. Side-effects: discoloration of skin, teeth, pseudotumor cerebri
- Nafcillin (Unipen)
  1. Dose: 250–1000 mg every 4–6 hours IV or IM
  2. Supplied: 500 mg, 1000 mg powder for injection
  3. Side-effects: nephrotoxicity
- Oxacillin (Bactocill)
  1. Dose: child: 50–100 mg/kg per 24 hours divided 4–6 hours; adult: 500 mg every 4–6 hours
  2. Supplied: 250 mg/5 ml, 250 mg, 500 mg
- Penicillin V
  1. Dose: child: 25–50 mg/kg per 24 hours given every 6–8 hours; adult: 250–500 mg PO QID
  2. Supplied: 125 mg/5 ml, 250 mg/5 ml, 250 mg, 500 mg
- Rifampin
  1. Dose: 10–20 mg/kg per 24 hours, max 600 mg
  2. Supplied: 150 mg, 300 mg
  3. Warnings: interacts with antacids, Ca channel blockers, steroids, cyclosporine, digoxin, dapsone, quinolones, warfarin, L-thyroxine
- Sulfasalazine (Azulfidine)
  1. Dose: child: 30–60 mg/kg per 24 hours given every 4–6 hours; adult: 500 mg/24 hours for 1 week, then increase by 500 mg/24 hours for 1 week
  2. Max: 1–4 g/24 hours given QID
  3. Supplied: 500 mg/5 ml, 500 mg
  4. Monitor: CBC, liver enzymes every 2 weeks, monthly for 3 months, then every 3–6 months
  5. Warning: take with food
- Tetracycline (Panmycin, Sumycin)
  1. Dose: child: 25–50 mg/kg per 24 hours given QID; adult: 250–500 mg BID–QID, maximum 3 g/24 hours
  2. Supplied: 250 mg, 500 mg
  3. Warning: do not use <8 years
- Trimethoprim–sulfamethoxazole (Septra, Bactrim)
  1. Dose: child: 0.5 mg/kg/dose, give BID; For child 10 kg – give 1 tsp BID; For child 20 kg – give 2 tsp BID; For child 30 kg – give 3 tsp BID; For child ≥40 kg – give 4 tsp BID or 1 double strength tab BID; for adult 1 tab (double strength) BID–QID

2. Supplied: liquid: 200 mg/5 ml of sulfa, 40 mg/5 ml of TMP; tablet: 400 mg of sulfa, 80 mg of TMP; double strength: 800 mg of sulfa, 160 mg of TMP
3. Warnings: white blood cell suppression, allergy

### Preoperative endocarditis prophylaxis

- Amoxicillin: adults: 2 g, children 50 mg/kg; given orally 1 hour before procedure
- Allergic to penicillin:
  1. Clindamycin: adults: 600 mg, children 20 mg/kg; given orally 1 hour before procedure OR
  2. Cephalexin: adults: 2 g, children 50 mg/kg; given orally 1 hour before procedure OR
  3. Azithromycin or clarithromycin: adults: 500 mg, children 15 mg/kg; given orally 1 hour before procedure

### Antibiotic agents (topical)

Indications: superficial folliculitis, impetigo

- See Table 21.3

#### *Dakon solution*

- Indications: antibiotic solution
- Dose: full strength (0.5%) 10 ml bleach, 20 ml NaHCO<sub>3</sub> in 1 liter of water; half strength (0.25%); quarter strength (0.125%)

### Antifungal agents

#### *Topicals*

- Creams are best for dry areas
- Solutions are best for intertriginous areas
- Medicated powders help to dry the skin but are not very effective in treating fungus; helpful in prophylaxis
- Combination products with topical steroids can mask infections and are not recommended for most tinea or candidal infections
- See Table 21.4

#### *Oral*

- Griseofulvin (Grifulvin, Grisactin, Fulvicin)

**Table 21.3 Topical antibiotic agents**

<i>Brand name</i>	<i>Generic name</i>	<i>Prescription/ OTC</i>
Bactroban cream, ointment	mupirocin 2%	Rx
Bactitracin ointment	bacitracin (generic)	OTC
Betadine ointment	povidone 5–10%	OTC
Cortisporin ointment	polymyxin, neomycin, bacitracin, hydrocortisone (HC) 1%	Rx
Furacin cream, ointment	nitrofurazone 0.2%	Rx
Garamycin ointment, cream	gentamicin 0.1%	Rx
Mycitracin ointment	polymyxin, neomycin, bacitracin	OTC
Neosporin ointment	polymyxin, neomycin, bacitracin	OTC
Polysporin ointment	polymyxin, bacitracin	OTC
Silvadene cream	silver sulfadiazine 1%	Rx
Vioform-HC	clinoquinol 3% + 1% HC	Rx
Vytone cream	iodoquinol 1% + 1% HC	Rx

**Table 21.4 Topical antifungal agents**

<i>Brand name</i>	<i>Generic name</i>	<i>Prescription or OTC</i>
Exelderm	1% sulconazole	Rx
Lamisil (cream, solution, spray)	1% terbinafine	OTC
Lotrisone	1% clotrimazole + diprosone 0.05%	Rx
Loprox (cream, lotion)	1% ciclopirox	Rx
Lotrimin (cream, solution, lotion)	1% clotrimazole	OTC
Mentax	1% butenafine	Rx
Micatin	2% miconazole	OTC
Mycelex (cream, solution)	1% clotrimazole	OTC
Naftin (gel, cream)	1% naftifine	Rx
Nizoral (cream, shampoo)	1% ketoconazole	OTC
	2% ketoconazole	Rx
Oxistat (cream)	1% oxiconazole	Rx
Spectazole	1% econazole	Rx

1. Dose (Microsize): child: 10–25 mg/kg per 24 hours; adult: 500–1000 mg/24 hours; max dose: 1 g/24 hours
  2. Dose (Ultra Micro): child: 5–10 mg/kg per 24 hours given once daily or BID; adult: 375–750 mg/24 hours given once daily or BID; max dose 750 mg/24 hours
  3. Supplied: (equivalency: 250 mg Ultra Micro equals ~500 mg Micro). Micro (UF): 250, 500 mg tabs, 125 mg/5 ml syrup; Ultra Micro (PG): 125, 250, 330 tabs
  4. Warning: take with food, drug interactions
  5. Contraindications: pregnancy, liver failure, porphyria
- Fluconazole (Diflucan)
    1. Dose: child: 3–6 mg/kg per 24 hours; adult: 150–300 mg once weekly for nails for 3–12 months
    2. Supplied: 10 mg/ml, 40 mg/ml, 50 mg, 100 mg, 150 mg, 200 mg
    3. Monitor: liver enzymes, drug interactions
  - Itraconazole (Sporanox)
    1. Dose: adult: 200–400 mg/24 hours; max dose: 400 mg/24 hours
    2. Dose: child:
      - a Nails (pulse 1 week out of month): 10–20 kg: 1 cap every other day; 20–30 kg: 1 cap daily; 30–40 kg: 1 cap every other day

- alternating with 2 caps every other day;  
40–50 kg: 2 caps daily; >50 kg: 2 caps BID
- b. Hair (tinea capitis): 3–5 mg/kg per 24 hours for 30 days, given once daily or BID; >60 lb: 100 mg/24 hours for 1 month; 2-year-old: 100 mg every other day in apple sauce or Jello for 1 month
- c. Tinea versicolor: 200 mg once, repeat in 1 week
- 3. Supplied: 10 mg/ml, 100 mg
- 4. Monitor: liver enzymes, drug interactions
- Ketoconazole (Nizoral)
  1. Dose: child  $\geq$  2 years: 3.3–6.6 mg/kg per 24 hours given once daily; adult: 200–400 mg/24 hours given once daily; max dose: 800 mg/24 hours given BID
  2. Tinea versicolor: 400 mg once a week twice, week apart; or 200 mg daily for 5–10 days
  3. Supplied: 100 mg/5 ml compounded, 200 mg
  4. Monitor: liver enzymes in long-term use, drug interactions
- Nystatin
  1. Dose: child/adult: 4–6 ml swish and swallow QID
  2. Supplied: suspension 100 000 units/ml
- Terbinafine (Lamisil)
  1. Dose:
    - a. Hair: 3–6 mg/kg per 24 hours for one month; <20 kg: one quarter tab/24 hours; 20–40 kg: one half tab/24 hours; >40 kg: 1 tab/24 hours
    - b. Nails: 250 mg daily for 3 months or pulsed: 250 mg BID for 1 week each month for 3 months
    - c. Adult: 250–500 mg/24 hours
  2. Supplied: 250 mg
  3. Monitor: CBC and liver enzymes before and monthly during continuous therapy, drug interactions

## Antiparasitic agents

- Elimite cream (permethrin 5%)
  1. Apply for 8–14 hours (overnight); repeat in 1 week
- Kwell (lotion, cream, shampoo) (lindane 1%)
  1. Apply for 8–14 hours; repeat in 1 week
- Nix Cream Rinse (permethrin 1%)
  1. Apply for 10 minutes to dry hair then wash out

- RID (pyrethrin 0.3% plus pipermylbutoxide)
  1. Apply for 10 minutes to dry hair then wash out
- Sulfur (precipitated) (5–10% ointment)
  1. Must compound in cream or petrolatum; apply daily for 3 days
- Ivermectin (0.2 mg/kg given in a single dose).  
15–24 kg: half tab (3 mg); 25–35 kg: 1 tab (6 mg); 36–50 kg: 1 half tab (9 mg); 51–65 kg: 2 tab (12 mg); 66–79 kg: 2 half tab (15 mg);  $\geq$ 80 kg: 0.2 mg/kg
  1. Supplied: 6 mg tab

## Acne medicines (topicals)

### *Benzoyl peroxide (BP)*

- Antibacterial/keratolytic
- Do not apply at same time with topical retinoid
- Water-based gels less irritating and less drying than acetone- or alcohol-based gels
- Concentrations of 2.5–5% are as effective as 10% gels and less irritating
- See Table 21.5

### *Topical antibiotics for acne*

- Come as solutions, lotions, gels, creams and pads
- Kill *Propionibacterium acnes*
- Anti-inflammatory effects
- See Table 21.6

### *Keratolytics for acne*

- See Table 21.7

### *Topical retinoids*

- Available by prescription only
- Creams are less irritating than gels or solutions
- See Table 21.8

### *Sulfur products*

- Broad-spectrum antimicrobial, keratolytic
- Treat: acne, rosacea, seborrheic dermatitis
- Do not use in sulfa-sensitive patients
- See Table 21.9

### *Other*

- See Table 21.10

**Table 21.5 Topical acne medicines**

<i>Medication</i>	<i>Prescription/OTC</i>
Benzac AC (water emollient base) 2.5%, 5%, 10%	Rx
Benzac W (water) 2.5%, 5%, 10%	Rx
BenzaClin (BP 5% + 1% clindamycin)	Rx
Brevoxyl (water) 4%, 8%	Rx
Clear By Design 2.5%	OTC
Duac gel (clindamycin 1% + BP 5%)	Rx
Neutrogena Acne Mask 5%	OTC
Oxy 10% gel	OTC
Pan Oxyl 5%, 10% gel	Rx
Sulfoxyl (regular) 5% BP + 2% sulfur lotion	Rx
Sulfoxyl (strong) 10% BP + 2% sulfur lotion	Rx
Triaz 3%, 6%, 10% gel	Rx
Benzagel 5%, 10%	Rx
Desquam X 2.5%, 5%, 10% gel	Rx
<b><i>Benzoyl peroxide wash</i></b>	
Benzac AC Wash 2.5%, 5%, 10%	Rx
Brevoxyl Cleanser 4%, 8%	Rx
Brevoxyl Creamy Wash 4%, 8%	Rx

**Table 21.6 Topical antibiotics for acne**

<i>Medication</i>	<i>Generic</i>
Akne-Mycin (ointment or solution)	2% erythromycin
A/T/S (gel, solution)	2% erythromycin
Benzamycin	3% erythromycin + BP 5%
BenzaClin (gel)	1% clindamycin + BP 5%
Cleocin T (solution, gel, lotion, pledgets)	1% clindamycin
Clindets (pads)	1% clindamycin
Duac	1% clindamycin + BP 5%
Emgel (gel)	2% erythromycin
Erycette (swabs)	2% erythromycin
EryDerm (solution)	2% erythromycin
Erygel (gel)	2% erythromycin
Staticin solution	1.5% erythromycin
Theramycin Z (solution)	2% erythromycin + zinc acetate
Topicycline (solution)	tetracycline 2.2 mg/ml
T-Stat (solution, pads)	2% erythromycin



**Table 21.7 Keratolytics for acne**

<i>Medication</i>	<i>Generic</i>	<i>Supplied</i>
Clean & Clear	salicylic acid 0.5% or 2%	OTC
Oxy Night Watch	salicylic acid 1% or 2%	OTC
Stridex Clear Gel	salicylic gel 2%	OTC

**Table 21.8 Topical retinoids for acne**

<i>Medication</i>	<i>Generic</i>
Avita 0.025% cream, gel	tretinoin
Differin 0.1% cream, gel	adapalene
Retin-A Micro 0.1% gel	tretinoin
Retin A 0.025%, 0.05%, 0.1% cream	tretinoin
Retin A 0.01%, 0.025% gel	tretinoin
Tazorac 0.05%, 0.1% (cream, gel)	tazarotene

**Table 21.9 Sulfur products for acne**

<i>Medication</i>	<i>Generic</i>	<i>Supplied</i>
Clearasil	8% sulfur + 1% resorcinol	OTC
Fostril	2% sulfur	OTC
Klaron	10 % sodium sulfacetamide	Rx
Liquimat	5% sulfur	OTC
Novacet	5% sulfur + 10% sodium sulfacetamide	Rx
Sulfacet-R	5% sulfur +10% sodium sulfacetamide	Rx
Sulfoxyl (regular)	5% BP + 2% sulfur lotion	Rx
Sulfoxyl (strong)	10% BP + 2% sulfur lotion	Rx

**Table 21.10 Other products for acne**

<i>Medication</i>	<i>Generic</i>	<i>Supplied</i>
Azelex cream	20% azelaic acid	Rx
Finacea gel	15% azelaic acid	Rx

## Rosacea medicines

- Anti-inflammatory
- Prescription only
- See Table 21.11

## Antiviral agents

### Topical

- Suppressive, not for primary treatment
- Prescription only
- See Table 21.12

**Table 21.11 Rosacea medicines**

<i>Medication</i>	<i>Generic</i>
Noritate (cream)	metronidazole 1%
MetroGel	metronidazole 0.75%
MetroCream	metronidazole 0.75%
MetroLotion	metronidazole 0.75%
Klaron (lotion)	sodium sulfacetamide 10%
Novacet Lotion	sulfacetamide 10%/5%
sodium	sulfur
Sulfacet-R sodium	sulfacetamide 10%/5%
	sulfur

**Table 21.12 Antiviral agents**

<i>Medication</i>	<i>Generic</i>
Zovirax ointment	acyclovir 5%
Viroptic solution	trifluridine 1%
Cidofovir gel	0.3, 1, 3% gel
Denavir cream	peniclovir 1% cream

## Topical genital wart treatment

- Podocon-25 (podophyllin 25%)
  1. Apply in office; leave on 1–6 hours; then wash off
- Condylox (podofilox 0.5%)
  1. Dose: use BID for 3 days each week; reassess at 4 weeks
- Aldara (imiquimod 5%)
  1. Apply once daily 3 times per week at bedtime; wash in morning

## Opioid analgesics

- Codeine
  1. Starting oral doses and intervals
    - a. Child (<50 kg) 0.5–1.0 mg/kg per dose every 4–6 hours
    - b. Max dose: 60 mg/dose
    - c. Adult (>50 kg) 15–60 mg every 4–6 hours
  2. Supplied: 15 mg, 30 mg, 60 mg; 15 mg/ml, 60 mg/5 ml
    - a. Acetaminophen with codeine: no. 2: 300 mg acetaminophen + 15 mg codeine; no. 3: 300 mg acetaminophen + 30 mg codeine; no. 4: 300 mg acetaminophen + 60 mg codeine
- Diazepam (Valium)
  1. Dose: child: 0.1–0.8 mg/kg per 24 hours given every 6–8 hours; adult: 2–10 mg/24 hours given every 6–12 hours
  2. Supplied: 5 mg/ml, 5 mg/5 ml, 1 mg, 2 mg, 5 mg, 10 mg
- Oxycodone (Oxycontin, Roxicodone)
  1. Starting oral doses and intervals
    - a. Child (<50 kg) 0.05–0.15 mg/kg per dose every 4–6 hours
    - b. Max dose: 10 mg/dose
    - c. Adult (>50 kg) 5–10 mg every 4–6 hours
  2. Supplied: 1 mg/ml, 20 mg/ml, 5 mg
    - a. Oxycontin controlled-release tabs: 10 mg, 20 mg, 40 mg; adults: 10–40 mg PO every 12 hours
    - b. Percocet (oxycodone + acetaminophen); adult 1–2 tab every 4–6 hours
    - c. Supplied: 500 mg acetaminophen + oxycodone 5 mg; 325 mg acetaminophen + oxycodone 5 mg; 325 mg acetaminophen + oxycodone 5 mg/5 ml
- Morphine
  1. Starting oral doses and intervals:
    - a. Child (<50 kg) 0.2–0.5 mg/kg per dose every 3–4 hours
    - b. Max dose: 15 mg/dose
    - c. Adult (>50 kg) 10–30 mg every 4–6 hours
  2. Supplied: 10 mg/5 ml, 20 mg/5 ml, 100 mg/5 ml; 15 mg, 30 mg
  3. Controlled release tabs (given every 12 hours): 30 mg, 60 mg, 100 mg
- Midazolam (Versed)
  1. Dose (sedation/anxiolysis)

- a. Child (6 months to 5 years): 0.05–0.1 mg/kg per dose; can repeat in 2–3 minute intervals; max: 6 mg; 6–12 years: 0.025–0.05 mg/kg per dose; max: 10 mg; 12–16 years: 0.5–2 mg/dose; max: 10 mg; can repeat
  - b. Adult: 5 mg or 0.07 mg/kg IM or 1 mg IV or 0.15 mg/kg IM
2. Supplied: 2 mg/ml, 3 mg/ml

## Nonopioid analgesics

- Acetaminophen (Tylenol)
  1. Dose:
    - a. Child: 10–15 mg/kg per dose every 4–6 hours; 6 months to 5 years: 0.25–1 mg/kg per dose; 6–12 years: 0.25–0.5 mg/kg per dose
    - b. Max daily dose: 75 mg/kg per 24 hours (not to exceed 4 g/24 hours)
    - c. Adult: 325–650 mg every 4–6 hours
    - d. Max daily dose (adults): 4 g/24 hours
  2. Supplied: 160, 325, 500, 650 mg
    - a. Chewable tabs: 80, 160 mg
    - b. Infant drops: 80 mg/ 0.8 ml
    - c. Liquid: 80 mg/5 ml, 120 mg/5 ml, 160 mg/5 ml, 325 mg/5 ml
- Aspirin
  1. Dose:
    - a. Child: 10–15 mg/kg per dose every 4–6 hours
    - b. Adult dose 650–1000 mg every 4–6 hours
    - c. Max daily dose: 4 g/24 hours
  2. Supplied: 325, 500 mg, others
    - a. Chewable tabs: 81 mg
- Ibuprofen (Advil, Motrin)
  1. Dose:
    - a. Child: 5–10 mg/kg per dose every 6–8 hours
    - b. Max dose (child): 40 mg/kg per 24 hours
    - c. Adult: 400–800 mg every 6–8 hours
    - d. Max daily dose (adult): 3200 mg/24 hours
  2. Supplied: 100 mg/5 ml, 40 mg/ml
    - a. Chewable tabs: 50 mg, 100 mg
    - b. Tabs: 100, 200, 300, 400, 600, 800 mg
- Naproxen (Naprosyn, Aleve)
  1. Dose:
    - a. Child >2 years: 5–7 mg/kg per dose every 8–12 hours
    - b. Adult dose 250–500 mg every 12 hours
    - c. Max daily dose (adult): 1000 mg

2. Supplied: 125 mg/5 ml, 220 mg, 250 mg, 375 mg, 500 mg

## Topical anesthetics

- See Table 21.13

**Table 21.13 Topical anesthetics**

Medication	Generic
EMLA	2.5% lidocaine + 2.5% prilocaine
ELA-MAX	4% lidocaine
LMX	4% lidocaine
Pramosone	Pramoxine + 1% or 2.5% hydrocortisone
Lida-Mantle	3% Lidocaine + 0.13% benzalkonium Cl + 0.5% hydrocortisone

## Local anesthetics

- Lidocaine (Xylocaine)
  1. Dose:
    - a. Adults: max 4.5 mg/kg per dose without epinephrine; max 7 mg/kg per dose with epinephrine; max topical 3 mg/kg per dose, no more frequently than every 2 hours
  2. Supplied:
    - a. Injection: 0.5%, 1%, 1.5%, 2%, 4%, 10%, 20%
    - b. Injection with 1 : 50 000 epinephrine – 2% lidocaine
    - c. Injection with 1 : 100 000 epinephrine – 1%, 2% lidocaine
    - d. Injection with 1 : 200 000 epinephrine – 0.5%, 1%, 1.5%, 2% lidocaine; jelly: 2% lidocaine ; liquid (viscous): 2% lidocaine; solution: 2% lidocaine

## Other medicines

- Acitretin (Soriatane)
  1. Indications: psoriasis, ichthyosis (off label)
  2. Dose: 0.5 mg/kg per 24 hours; adult: 25–50 mg/24 hours
  3. Supplied: 10 mg, 25 mg
  4. Monitor: CBC, electrolytes, blood urea nitrogen (BUN), creatinine, liver enzymes,

lipids, urinalysis, fasting glucose, albumin, pregnancy tests

- a. Check baseline, then every 2 weeks for 2 weeks, then every month for 6 months, then every 3 months
5. Contraindications: pregnancy, alcohol ingestion
6. Warnings: see Physician's Desk Reference, avoid pregnancy for >3 years after cessation
7. Side-effects: fetal abnormalities, pseudotumor cerebri, hepatotoxicity, decreased night vision, hyperostosis, lipid abnormalities
- Acyclovir (Zovirax)
  1. Dose:
    - a. Primary herpes: child: 15–30 mg/kg per 24 hours every 8 hours; max dose in child: 80 mg/kg per 24 hours; adult: 400 mg TID or 200 mg 5 times daily for 7–10 days
    - b. Recurrence: adult: 400 mg TID for 5 days, or 200 mg 5 times a day for 5 days
    - c. Chronic suppression: adult: 800–1000 mg/24 hours given 2–5 times a day
    - d. Varicella: child: 80 mg/kg per 24 hours given QID for 5 days; max dose: 3200 mg/24 hours
    - e. Herpes zoster: 800 mg 5 times a day for 5–7 days
  2. Supplied: 200 mg/5 ml, 200 mg, 400 mg, 800 mg
- Chloral hydrate
  1. Indications: sedation for procedures, sedative
  2. Dose:
    - a. Child: for anxiety: 5–15 mg/kg per dose (maximum 500 mg); for conscious sedation: 50–75 mg/kg per dose given every 6–8 hours; max: 1 g/dose
    - b. Adult: 250–1000 mg/dose given TID; max: 2 g/24 hours
  3. Supplied: 250 mg/5 ml, 500 mg/5 ml, 250 mg, 500 mg
  4. Contraindications: hepatic or renal disease
- Cimetidine (Tagamet)
  1. Indications: histamine-2-antagonist
  2. Dose:
    - a. Child: 20–40 mg/kg per 24 hours, given 3–4 times per day
    - b. Adult 300 mg QID
    - c. Max: 2400 mg/24 hours

3. Supplied: 100 mg (OTC), 200 mg tabs, 300 mg/5 ml, 300 mg, 400 mg, 800 mg
4. Warning: drug interactions
- Cyclosporine (Neoral)
  1. Indications: immunosuppressant, potent T-cell inhibitor, psoriasis
  2. Dose: 2.5–4 mg/kg per 24 hours divided BID for 4 weeks; increase every 2 weeks by 0.5 mg/kg per 24 hours
    - a. Max: 5 mg/kg per 24 hours
  3. Monitor: CBC, liver enzymes, BUN, creatinine, Mg, K, uric acid, lipids, cyclosporine trough levels if >5 mg/kg per day
    - a. Check blood pressure every 2 weeks for 3 months, decrease dose if creatinine is elevated >30%
    - b. Check creatinine clearance every 6 months
  4. Contraindications: renal insufficiency, hypertension, infection
  5. Relative contraindications: malignancy, immunodeficiency, nephrotoxic drugs, hepatic disease, gout
  6. Side-effects: nephrotoxicity, hepatotoxicity, hypertension, tremor, gingival hyperplasia, long-term malignancy, hyperlipidemia, hypertrichosis, hyperkalemia, uricemia, hypomagnesemia
  7. Supplied: 100 mg/ml, 25 mg, 100 mg
- Doxepin
  1. Dose:
    - a. Child: 1–3 mg/kg per 24 hours, given in single dose at bedtime
    - b. Adult 25–100 mg PO at bedtime; start low and increase slowly; max 300 mg/24 hours
  2. Supplied: 10 mg/ml; 10 mg, 25 mg
  3. Topical - use in teens and adults only; use only in small areas; consider toxicity (drowsiness) if overused
- Epinephrine
  1. Indications: sympathomimetic, hypersensitivity reactions
  2. Dose:
    - a. Child: 0.01 mg/kg per dose (maximum 0.3 mg)
    - b. Adult: usually 0.1–0.25 mg of 1 : 1,000 solution subcutaneously
  3. Supplied: Epi Pen Jr 0.15 mg dose, Epi Pen 0.3 mg autoinjection
    - a. For injection: 1 mg/ml, 5 mg/ml, 0.1 mg/ml, 0.01 mg/ml
  4. Warning: may produce arrhythmia, hypertension, nervousness, vomiting
- Famciclovir (Famvir)
  1. Dose: ages >18 years
    - a. Primary herpes: 250 mg TID for 7–10 days
    - b. Recurrence: 125–250 mg BID for 5 days
    - c. Suppression: 250 mg BID
    - d. Herpes zoster: 500 mg TID for 7 days
    - e. Supplied: 125 mg, 250 mg, 500 mg
    - f. Warning: do not give to HIV patients
- Folic acid
  1. Dose:
    - a. Initial: child (1–10 years): 1 mg/24 hours or 5 mg per week; >11 years: 1–3 mg/dose divided daily to TID
    - b. Maintenance: 0.1–0.5 mg/24 hours given QD; pregnant women 0.8 mg/24 hours
  2. Supplied: 0.4 mg, 0.8 mg, 1 mg; 1 mg/ml compounded
- Hydroquinone (HQ)
  1. Indications: bleaching agent
  2. Supplied: 1.5–2% OTC
    - a. 4% by prescription
    - b. Lustra (HQ, glycolic acid, no sunscreen)
    - c. Lustra AF (HQ, sunscreen)
    - d. Alustra (HQ, retinal, sunscreen)
  3. Warnings: do not use for prolonged periods (>3 months) because of risk of hyperpigmentation
- Hydroxychloroquine (Plaquenil)
  1. Dose: 200–400 mg/24 hours, given BID–TID
  2. Supplied: 200 mg
  3. Monitor:
    - a. Initial G6PD (avoid if deficient), CBC, liver enzymes, eye examination
    - b. Every 3 months: CBC, liver enzymes
    - c. Every 6 months: eye examination
  4. Side-effects: retinal damage, myopathy, liver abnormalities, hemolysis, cutaneous eruptions or discoloration
- Isotretinoin (Accutane)
  1. Indications: severe recalcitrant or cystic acne, ichthyosis (off label)
  2. Dosage:
    - a. Initial 0.5–2 mg/kg per 24 hours given BID for 15–20 weeks
    - b. Max dose: 2 mg/kg per 24 hours

- c. Adjust for side-effects and disease response
  - d. Repeat only if necessary after 2 months off drug
  - e. Take with food
  3. Supplied: 10 mg, 20 mg, 30 mg, 40 mg
  4. Contraindications: pregnancy, paraben sensitivity, concomitant vitamin A
  5. Monitor: initial CBC; baseline and every month: liver enzymes, lipids, pregnancy tests
  6. Warnings: see PDR; need special labels to prescribe
- Methotrexate (Rheumatrex)
    1. Indications: psoriasis, morphea, cutaneous T-cell lymphoma
    2. Dose: 2.5–25 mg given once a week either PO or IM
    3. Supplied: 2.5 mg
    4. Monitor: liver enzymes, creatinine, CBC, urinalysis every week for 4 weeks then once a month; chest X-ray as indicated; liver biopsy after 1–1.5 g total dose
    5. Contraindications: pregnancy, liver disease, alcohol ingestion, significant hematological abnormalities, active infectious disease, immunodeficiency
    6. Warning: multiple drug interactions, hepatotoxicity, bone marrow depression, carcinogenesis, pulmonary fibrosis
  - Minoxidil (Rogaine)
    1. Indications: androgenetic alopecia
    2. Dose: 2%, 5% solution, apply 1 ml to dry scalp BID
    3. Side-effects: hypertrichosis
  - Mycophenolate mofetil (CellCept)
    1. Indications: immunosuppressive agent
    2. Dose: 2–4 g/24 hours given BID
      - i. Child: 600 mg/m<sup>2</sup> per dose PO, BID
    3. Supplied: 250 mg, 500 mg
    4. Monitor: CBC (neutrophils) and liver enzymes once a week for 1 month, then once monthly
    5. Warning: drug interactions
  - Oral contraceptive pills (with low androgenetic activity)
    1. Indications: acne, hirsutism
    2. Supplied: Ortho-Tricyclen (ethinyl estradiol–norgestimate), OrthoCyclen, Desogestrel, Ovulen, Demulen, Enovid, Orthocept, Desogen, OrthoCyclen, Desogen, Orthocept
  - 3. Contraindications: pregnancy
  - Pimecrolimus (Elidel)
    1. Ages >2 years: 1% pimecrolimus cream BID
    2. Supplied: 15 g, 30 g, 100 g
    3. Warnings: burning, stinging
  - Robinul (glycopyrrolate)
    1. Indications: hyperhidrosis (anticholinergic)
    2. Dose:
      - a. Child: 0.04–0.1 mg/kg per dose every 4–8 hours
      - b. Adult: 1–2 mg BID–TID
    3. Supplied: 1 mg, 2 mg
    4. Warning: caution in liver or kidney disease; atropine-like side-effects
  - SSKI (potassium iodide)
    1. Indications: larva migrans, erythema nodosum (off label), sporotrichosis
    2. Dose: 3–10 drops TID
      - a. Adult: 300–650 mg TID–QID
      - b. Child: 60–250 mg TID–QID
      - c. Max: 4.5–9 g/24 hours
    3. Supplied: 1000 mg/ml, 325 mg/5 ml, 65 mg, 130 mg
    4. Monitor: thyroid tests
    5. Contraindications: pregnancy
    6. Warning: metallic taste, give with milk or meals
  - Tacrolimus (Protopic)
    1. Ages 2–15 years: 0.03% tacrolimus ointment BID
    2. Ages >15 years: 0.1% tacrolimus ointment BID
    3. Supplied: 30 g, 60 g
    4. Warnings: burning, stinging
  - Thalidomide
    1. Dose:
      - a. Adult: 50–300 mg/24 hours given at night
    2. Supplied: 50 mg
    3. Side-effects: birth defects, peripheral neuropathy (sensory), sedation
    4. Monitor:
      - a. Baseline human chorionic gonadotropin (hCG), neurological examination, sensory nerve action potential (SNAP)
      - b. hCG every week for 4 weeks, then every 4 weeks
      - c. Neurological examination every 3 months, and SNAP as indicated
  - Valacyclovir (Valtrex)



1. Dose: ages: >18 years
  - a. Primary herpes: 1–2 g BID for 7–10 days
  - b. Recurrence: 500 mg BID for 5 days
  - c. Suppression: 500 mg once daily
  - d. Herpes zoster: 1 g TID for 7 days
2. Supplied: 500 mg, 1000 mg
3. Warning: do not prescribe to HIV patients
- Zinc
  1. Indications: zinc deficiency
  2. Dose:
    - a. Child: 0.5–1 mg elemental zinc/kg per 24 hours, given daily to TID
    - b. Adult: 25–50 mg elemental zinc/dose TID
  3. Supplied: 2 mg/ml
    - a. Children >4 years: Centrum Jr + Fe (15 mg), Polyvisol + Fe Zn
    - b. Tabs as sulfate with 23% elemental Zn: 110 mg (25 mg elemental Zn), 220 mg (50 mg elemental Zn)
    - c. Tabs as gluconate with 14.3% elemental Zn
    - d. Liquid as acetate: 5 mg, 10 mg elemental Zn/ml (compounded)
  4. Warning: GI upset

## References

- Archer JSM, Archer DF. Oral contraceptive efficacy and antibiotic interaction: a myth debunked. *J Am Acad Dermatol* 2002; 46: 917–23
- Berde CB, Sethna NF. Analgesics for the treatment of pain in children. *N Engl J Med* 2002; 347: 1094–103
- Brecher AR, Orlow SJ. Oral retinoid therapy for dermatologic conditions in children and adolescents. *J Am Acad Dermatol* 2003; 49: 171–82
- Drake LA, Dinehart SM, Farmer ER, et al. Guidelines of care for the use of topical glucocorticosteroids. *J Am Acad Dermatol* 1996; 35: 615–19
- Litt JZ. *Pocketbook of Drug Eruptions*. Parthenon Publishing: New York, 2001
- Parker JF, Vats A, Bauer G. EMLA toxicity after application for allergy skin testing. *Pediatrics* 2004; 113: 410–11
- Shapiro LE, Shear NH. Drug interactions: proteins, pumps, and P-450s. *J Am Acad Dermatol* 2002; 47: 467–84
- Scheman AJ, Severson DL. *Pocket Guide to Medication Used in Dermatology*, 6th edn. Williams & Wilkins: Baltimore, 1999



# INDEX

---

- abuse 211–16
  - acanthosis nigricans 246–8
  - acetaminophen 405
  - acitretin 406
  - acne 71–80
    - acne vulgaris 72–74
    - drug-induced acne 74–75, 223
    - early-onset 71–72
    - infantile 71
    - keloidalis nuchae 312
    - neonatal 71
    - prepubertal 71
  - acne medications 402–4
    - keratolytics 404
    - retinoids 404
    - sulfur products 404
    - topical antibiotics 401, 403
  - acneiform disorders
    - drug-induced 74–75, 223
    - hidradenitis suppurativa 77
    - hyperhidrosis 79–80
    - miliaria 78–79
    - perioral dermatitis 75–76
    - rosacea 76–77
  - acquired lesions 291–5
  - acrodermatitis enteropathica 197–8, 337
  - acropustulosis of infancy 68–69
  - actinic porokeratosis, disseminated superficial (DSAP) 46–7
  - actinic prurigo 203
  - acute febrile neutropenic dermatosis 191–3
  - acyclovir 406
  - Adams–Oliver syndrome 18
  - adapalene 55
  - Addison disease, hyperpigmentation 230
  - adhesives, contact dermatitis 59
  - aerosols 392
  - AIDS and HIV infection 142–4
  - albinism 251–2
  - Albright hereditary osteodystrophy 323
  - Alezzandrini syndrome 249
  - allergens, skin patch tests 61–62
  - allergic contact dermatitis 58–63
  - alopecia 335–7
    - acquired non-scarring 340–6
      - alopecia areata 340–2
      - alopecia areata, nail disorders 359
      - alopecia mucinosa 352
    - anagen effluvium 343
    - androgenetic alopecia 343–4
    - syndromes with late-onset hypotrichosis 346
    - telogen effluvium 342–3
    - traction alopecia 346
    - traumatic alopecia 346
    - triangular alopecia 337
    - trichotillomania 344–5
  - acquired scarring 351–353
  - congenital, diffuse 337–40
    - early-onset 337–8
    - ectodermal dysplasia (hidrotic) 339–40
    - ectodermal dysplasia (hypohidrotic/anhidrotic) 338–9
  - congenital, localized 336–7
    - occipital alopecia 336
    - patchy alopecia 337
  - drug-induced 223
- Amblyomma americanum* 171
- anagen effluvium 343
- analgesics 405
- anaphylaxis 177–178
- Ancylostoma braziliensis* 172–3
- Ancylostoma caninum* 172–3
- androgenetic alopecia 343–4
- anesthetics, local 406
- anetoderma 306–7
- angiokeratoma 287–8
- anhidrotic ectodermal dysplasia 338–9
- animal bites 169–74
- annular, defined 4
- annular erythema 183–5
- anogenital warts 137–9
- anonychia 359
- anorexia nervosa-associated skin disorders 194–5
- ant bites 168
- anthralin 396
- antibiotics 399–400
  - endocarditis prophylaxis 400
  - topical 401
  - topical, for acne 403
- antiepileptics, drug reactions 224
- antifungals 400–1
- antihistamines 398–9
- antimalarials, drug reactions 225
- antimetabolites (chemotherapy), drug reactions 225
- antiparasitic agents 402
- antiperspirants 398
- antipruritics 54, 62
- antiviral agents 404
- aplasia cutis congenita, 17–19
- arciform, defined 4

- artefactual dermatitis 214–16  
 ashy dermatosis 246  
 aspirin 405  
 asteatotic (winter) eczema 56  
 ataxia–telangiectasia 387–8  
 athlete's foot fungus 153  
 atopic dermatitis 49–55  
 atrophy, defined 3  
 Auspitz sign 33  
 avobenzone 398
- bacterial culture 7  
 bacterial diseases 95–115  
 baldness *see* alopecia  
 bamboo hair 347  
*Bartonella henselae* 109  
 basal cell carcinoma 327–8  
 basal cell nevus syndrome 381–2  
 Bazex syndrome 327  
 Bazin disease 113  
 beaded hair (monilethrix) 349  
 Beau's lines 359  
 bee/wasp/hornet stings 168  
 benzoyl peroxide 402  
 BIDS 351  
 biopsy 7  
 bites 169–74  
 Blaschko lines 46–7, 229, 297–301  
   Conradi–Hunermann syndrome 375–6  
   definition 229  
   disorders following 297  
   epidermal nevus 297–9  
   hypomelanosis of Ito 254  
   nevus comedonicus 300–1  
   nevus sebaceus 299–300  
 blastomycosis 159, 160–1  
 blepharitis 66  
 blistering distal dactylitis 103–4  
 Block–Sulzberger syndrome 244  
 Bloom syndrome 209  
 blue nails 359–60  
 blue rubber bleb syndrome 281  
 blueberry muffin baby 21  
 body lice 165–7  
 borreliosis 146, 170–2  
 Bourneville disease 379  
 brachyonychia 360  
 branchial cleft cyst/sinus 29  
 bromides, drug reactions 225  
 bulimia nervosa-associated skin disorders 194–5  
 bulla, defined 3  
 bullous congenital ichthyosiform
- erythroderma 373  
 bullous disorders 81–94  
   bullous impetigo 96  
   bullous pemphigoid 85–86  
   chronic bullous disease of childhood 84, 87–89  
   drug-induced erythema multiforme 219  
   epidermolysis bullosa 89–94  
   immunobullous disorders 81–89  
   *see also* pemphigus  
 Burow's solution 393
- café au lait macules 240–1, 377  
 calcifying epithelioma of Malherbe 303–4  
 calcinosis cutis 257, 322–3  
   metastatic 323  
 calcipotriene 396  
 calluses 315–16  
 candidal diaper dermatitis 65, 149  
 candidiasis 149–51  
   neonatal infections 24–6  
 capillaritis, primary 272  
 capillary malformations 280–2  
 Caspary–Joseph spaces 44  
 cat hookworm 172–3  
 cat scratch disease 109–10  
 caterpillar dermatitis (lepidopterism) 169  
 cellulitis 99–101  
 cephalic pustulosis, neonates 13–14  
 cephalosporins, drug reactions 224  
 cercarial dermatitis (swimmer's itch) 174–5  
 cetirizine 398  
 Chediak–Higashi syndrome 356–7  
 chemotherapy, drug reactions 225  
 chickenpox 132–5  
 chiggers 167  
 chilblains 210  
 child abuse 211–16  
 CHILD syndrome 337  
 chloral hydrate 406  
 chondrodysplasia punctata, X-linked 375  
 Christian–Siemens–Touraine syndrome 338  
 cimetidine 406  
 Civatte bodies 44  
 clavus/i 315  
 cleansers 54, 397  
 clemastine 398  
 clinical diagnosis 1–7
- configuration of lesions 4  
 dermatoses, common 8  
 diagnostic tests 4–7  
 history 1–2  
 primary lesions 3  
 reaction patterns 6  
 regional patterns 5  
 secondary lesions 3  
 terminology 2–4  
 Clouston syndrome 339  
 Cockayne syndrome 208–9  
 Cockayne–Touraine epidermolysis bullosa 92  
 codeine 405  
 cold injuries 210–11  
 collagen type-7 84  
 collagen vascular diseases 257–74  
 collodion baby 369–70  
 coloration 4  
 comedonal nevi 300–1  
 comedones 3, 72  
 condylomata acuminata 137, 139  
 configuration of lesions 4  
 confluent and reticulated papillomatosis 248  
 congenital dermal sinus 28–9  
 congenital ichthyosiform erythroderma (CIE) 372–3  
 congenital lymphedema 290–1  
 congenital nevocellular nevi 231–2  
 connective tissue 309–17  
   nevus 316  
 Conradi–Hunermann–Happle syndrome 337, 375–6  
 contact dermatitis 58–63  
   allergic 58–63  
   history 59  
   irritant 63  
 corns 315–16  
 corticosteroids  
   drug reactions 224  
   mid-strength and high-potency 54  
   systemic/oral 54, 62, 395–6  
   topical 54, 62, 393–5  
   types and strengths 394  
*Corynebacterium minutissimum*,  
   Wood's lamp examination 7  
 cosmetics, contact dermatitis 59  
 coumadin, drug reactions 225  
 coup de sabre 264  
 Cowden disease 386–7  
 coxsackieviruses 136–7  
 crab lice 165–7  
 creams 392

- creeping eruption 172–3  
 Crowe sign 378  
 crust, defined 3  
 cutaneous larva migrans 172–3  
 cutaneous T-cell lymphoma 41–3  
 cutis hyperelastica 382  
 cutis laxa 384  
 cutis marmorata 9–10  
     telangiectatica congenita 284–5  
 cyclosporine 407  
 cyproheptadine 398  
 Cyrano nose 277  
 cystic fibrosis 197–8  
 cystic hygroma 290  
 cysts 301–5  
     benign 302  
     branchial cleft cyst/sinus 29  
     defined 3  
     dermoid cyst 303  
     epidermal cyst 301–2  
     eruptive vellus hair cysts 304–5  
     macrocytic malformations 289–90  
     preauricular cyst/sinus 29–30  
     steatocystoma multiplex 325  
  
 dactylitis, blistering distal 103–4  
 Dakin's solution 393, 400  
 Dandy–Walker syndrome 277–8  
 Darier disease 388–9  
 Darier sign 320  
 definitions 3–4  
 delayed-type hypersensitivity reactions 60  
 Dennie's lines 64  
*Demacenter variabilis* 171  
 dermal erythropoiesis, neonates 21  
 dermal sinus, congenital 28–9  
 dermatitis  
     allergic contact 58–63  
     artefactual 214–16  
     caterpillar 169  
     cercarial 174–5  
     defined 49  
     diaper 63–65  
     eczematous, with  
         immunodeficiencies 57–58  
     factitial 214–16  
     frictional lichenoid 51–52  
     irritant contact 63  
     juvenile plantar 51–52  
     marine 175–6  
     perianal streptococcal 102–3  
     perioral 75–76  
     photoallergic 201–2  
     photodermatoses 201–2  
     phytophotodermatitis 202  
     seborrheic 66–67  
 dermatitis herpetiformis 84, 86–87  
 dermatofibroma 314–15  
 dermatographism 52, 177  
 dermatomyositis 257–8  
 dermatoses  
     acute febrile neutropenic 191–3  
     common 8  
     eczematous 49–69  
     genodermatoses 205–10  
     IgA 87–89  
     neutropenic 191–3  
     photodermatoses 199–205  
 dermoid cyst 303  
 DeSanctis–Cacchione syndrome 207  
 desloratadine 398  
 desmoglein 84  
 desmoplakin 84  
 diabetes, necrobiosis lipoidica 186–7  
 diagnosis *see* clinical diagnosis  
 diagnostic tests 4–7  
 diaper candidiasis 65, 149  
 diaper dermatitis 63–65  
 diaper psoriasis 33–6  
 diascopy 7  
 diazepam 405  
 diffuse cutaneous mastocytosis 319–20  
 diphenhydramine 398  
 discoid lupus erythematosus 260–1  
 dispensing  
     topical therapy 391  
     *see also* therapies  
 disseminated superficial actinic porokeratosis 46–7  
 dog bites 173  
 dog hookworm 172–3  
 Dowling–Meara epidermolysis bullosa 89, 90, 91  
 Down syndrome 360  
 doxepin 407  
 doxycycline, phototoxicity 199–201  
 drug eruptions 217–27  
     acne 74–75  
     acneiform eruptions 223  
     alopecia 223  
     common causative drugs 218  
     diagnosis 226  
     drugs with low incidence 217  
     environmental factors 225  
     erythema multiforme 219  
     erythema nodosum 221  
     fixed 222–3, 226  
     hypersensitivity 219–21  
     immunologic reactions (types 1–4) 225–6  
     lichenoid 222  
     lupus-like reactions 223  
     maculopapular/morbilliform 217–18  
     pathogenesis 225–7  
     photosensitivity eruptions 221–2  
     pigmentary changes 223  
     reaction types 217–27  
     serum sickness 220–1  
     serum sickness-like reactions 221  
     toxic epidermal necrolysis 219  
     treatment 227  
     urticaria 218–19  
     vasculitis 223  
 drug eruptions, specific drugs 224–7  
     antiepileptics 224  
     antimalarials 225  
     antimetabolites (chemotherapy) 225  
     bromides 225  
     cephalosporins 224  
     corticosteroids 224  
     coumadin 225–7  
     gold 224–5  
     iodides 225  
     lithium 225  
     nonsteroidal anti-inflammatory agents 225  
     penicillin 224  
     sulfonamides 225  
     tetracyclines 224  
     thiazides 225  
 drug-induced hypersensitivity 219–21  
  
 echovirus 126–7  
 ecthyma 98–99  
 ecthyma contagiosum 141  
 ectodermal dysplasia  
     hidrotic 339–40  
     hypohidrotic/anhidrotic 338–9  
 eczema  
     defined 49  
     dermatitis with  
         immunodeficiencies 57–58  
     infantile eczema 49–69  
 Ehlers–Danlos syndrome 382–4  
*Ehrlichia* 171  
 elastosis perforans serpiginosa 45–6  
 Elejalde syndrome 357



- elicitation reactions 60
- EMLA 406
- emollients 392
- en coup de sabre 264
- enanths 119
- encephalocele 28
- endocarditis, prophylaxis 400
- envoplakin 84
- ephelides 239–40
- epidermal cyst 301–2
- epidermal growths 325–7
  - steatocystoma multiplex 325
  - syringomas 325–6
  - trichoepithelioma 326–7
- epidermal nevus 297–9
- epidermolysis bullosa 89–94
  - acquisita 84
  - Cockayne–Touraine type 92
  - Dowling–Meara type 89, 90, 91
  - dystrophica 19, 92
  - Herlitz type 89, 91
  - junctional 91
  - of Pasini 92
  - simplex 90–91
  - Weber–Cockayne type 89, 90
- epidermolytic hyperkeratosis 373–4
- Epidermophyton floccosum* 153
- epinephrine 407
- epithelioma of Malherbe 303–4
- Epstein–Barr virus disease 127
- erosion, defined 3
- eruptive vellus hair cysts 304–5
- eruptive xanthoma 319
- erysipelas 101–2
- erythema annulare 183–5
- erythema chronicum migrans 145, 170–1
- erythema craquele 56
- erythema dyschromicum perstans 246
- erythema induratum 113
- erythema infectiosum (fifth disease) 123–4
- erythema multiforme
  - drug-induced 219
  - major 180–2
  - minor 179–80
- erythema nodosum 182–3
  - drug-induced 221
  - etiologies 309
- erythema toxicum neonatorum 11–12
- erythematous psoriasis 34
- erythroderma, congenital
  - ichthyosiform (CIE) 372–3
- eschar, defined 3
- exanthems 119
  - asymmetric periflexural 125
  - subitum (roseola) 122–3
  - unilateral laterothoracic 125–6
- excoriation, defined 3
- exostoses 324
- exudate, defined 3
- Fabry disease 288
- famciclovir 407
- fat, associated disorders 305–9
  - subcutaneous necrosis 16–17
- favus 154
- fetus papyraceus 18
- fexofenadine 398
- fibromatoses 309–11
  - dermatofibroma 314–15
- fibrous histiocytoma 314–15
- fifth disease 123–4
- finger clubbing 360
- fish tank granuloma 111–12
- fissure, defined 3
- fluconazole 401
- foams 392
- fogo selvagem 82
- folic acid 407
- folic acid deficiency 196
- folliculitis 96–98
  - dissecting 352
  - keratotic 388
  - Pityrosporum* 97
  - pseudomonal 97–98
- Fordyce, angiokeratoma 288
- Forschheimer spots 104
- freckles (ephelides) 239–40
- frictional lichenoid dermatitis 51–52
- frostbite 210–11
- fungal cultures 6
- fungal infections 149–62
  - deep 159–62
    - blastomycosis 160–1
    - mucormycosis 161–2
    - sporotrichosis 159–60
  - superficial 149–59
    - candida 149–51
    - onychomycosis 156–7, 363–4
    - potassium hydroxide examination 4–5
    - tinea capitis 154–6
    - tinea corporis 151–3
    - tinea pedis 153–4
    - tinea versicolor 157–9
- furunculosis 97
- Gardner syndrome 301, 385–6
- gels 392
- generalized hyperpigmentation 230
- genital warts 137–9
  - topical treatment 404
- genodermatoses
  - sun sensitivity 205–10
  - syndromes 369–89
- Gianotti–Crosti syndrome 124–5
- Gilchrist disease 160
- gliadin 84
- glioma 27–8
- glomovenous malformations 285–6
- glycopyrrolate 408
- gold, drug reactions 224–5
- Goltz syndrome 337
- Gorlin syndrome 381
- Gottron papules 257
- Gougerot and Carteaud syndrome 248
- Gower sign 257
- granulomas
  - annulare 185–6
  - fish tank 111–12
  - juvenile xanthogranuloma 317–19
  - Majocchi 152
  - pyogenic granuloma 291–2
  - sarcoidosis 193–4
  - umbilical granuloma 14
- granulomatosis, Wegener 267
- Griscelli syndrome 357
- griseofulvin 400–1
- gyrate, defined 4
- Haemophilus influenzae* 270
- hair disorders 335–57
  - abnormalities of hair color 355–7
  - abnormalities of increased hair 351–5
  - acquired non-scarring alopecia 340–6
  - acquired scarring alopecia 351, 352, 353
  - congenital alopecia, diffuse 337–40
  - congenital alopecia, localized 336–7
  - see also* alopecia
  - hair growth, normal cycle 335
  - hair shaft abnormalities 347–51
    - loose anagen syndrome 350–1
    - monilethrix 349
    - pili torti 348–9

- trichorrhexis invaginata 347–8  
trichorrhexis nodosa 347  
trichothiodystrophy 351  
uncombable hair syndrome 349–50
- Hallopeau, continua 34
- hamartoma  
connective tissue nevi 316  
fibrous of infancy 310  
multiple hamartoma syndrome 386  
smooth muscle hamartoma 317
- hand, foot and mouth disease 136–7
- Hansen disease 113–14
- harlequin ichthyosis 374–5
- harvest mites 167
- head lice 165–7
- heliotrope rash 257
- hemangioma of infancy 275–80
- hematopoiesis, extramedullary 21
- Henoch–Schönlein purpura 268–70
- hepatitis 128–9
- Herlitz type junctional epidermolysis bullosa 89
- Hermansky–Pudlak syndrome 253
- herpes simplex 130–2  
erythema multiforme 179–80  
infantile 23–4, 130–2  
neonates 21–3, 130–2  
Tzanck smear 6  
whitlow 131, 367
- herpes zoster 135–6  
infantile 23–4
- herpetiform, defined 4
- hidradenitis suppurativa 77
- hidrotic ectodermal dysplasia 339–40
- hirsutism 354–5
- histiocytoma 314–15
- histiocytosis 330–1
- HIV infection 142–4
- hookworm 172–3
- hot tub (pseudomonal) folliculitis 97–98
- human immunodeficiency virus (HIV) 142–4
- Hutchinson sign, nail disorders 360
- Hutchinson summer prurigo 203
- Hutchinson triad 26
- hydroa aestivale 203
- hydroa vacciniforme 203
- hydroquinone 407
- hydroxychloroquine 407
- hydroxyzine 398
- hymenoptera stings 168–9
- hypercalcaemia, subcutaneous fat necrosis 16–17
- hyperhidrosis 79–80
- hyperimmunoglobulin E syndrome 57–58
- hyperkeratosis, epidermolytic 373–4
- hyperpigmentation disorders 229–48
- hypersensitivity disorders 177–94  
annular erythemas 183–5  
drug-induced 219–20  
erythema multiforme 179–80  
erythema nodosum 182–3  
granuloma annulare 185–6  
Kawasaki disease 187–9  
necrobiosis lipoidica diabetorum 186–7  
pyoderma gangrenosum 189–91  
rheumatoid nodules 186  
sarcoidosis 193–4  
Stevens–Johnson syndrome (SJS) 180–2  
Sweet syndrome 191–3  
toxic epidermal necrolysis (TEN) 180–2  
urticaria 177–79
- hypersensitivity reactions  
acute 58–60  
delayed-type 60
- hypertrichosis 351–4  
causes 353
- hypertrophic scars 313
- hypohidrotic ectodermal dysplasia 338–9
- hypomelanosis of Ito 254–5
- hypopigmented disorders 249–56
- hypotrichosis 339, 346  
late-onset 346
- IBIDS 351
- ibuprofen 405
- ichthyosiform erythroderma, congenital (CIE) 372–3
- ichthyosis 369–76  
collodion baby 369–70  
congenital ichthyosiform erythroderma (CIE) 372–3  
Conradi–Hünemann–Happle syndrome 375–6  
epidermolytic hyperkeratosis 373–4  
harlequin 374–5  
ichthyosis vulgaris 370–1  
lamellar 372  
steroid sulfatase deficiency 371
- X-linked 371
- id reaction 60, 152
- IgA dermatosis 87–89
- imiquimod 404
- immunobullous disorders 81–89  
bullous pemphigoid 85–86  
dermatitis herpetiformis 86–87  
pemphigus 81–84
- immunodeficiencies  
with eczematous dermatitis 57–58  
HIV infection 142–4  
severe combined syndrome 57–58
- immunologic reactions (types 1–4) 225–6
- impetigo 95–96
- incontinentia pigmenti 244–6
- infantile eczema 49–69
- infantile fibromatoses 309–11
- infectious mononucleosis 127–8
- infestations 163–76
- infiltrations 317–25  
calcinosis cutis 322–3  
juvenile xanthogranuloma 317–19  
mastocytosis 319–22  
osteoma cutis 323–5
- inflammatory linear verrucous epidermal nevus (ILVEN) 298
- insect bites, urticarial reactions 167–8
- insect stings 168–9
- intertrigo 66–67
- iodides, drug reactions 225
- isotretinoin 407
- Ito  
hypomelanosis 254–5  
nevus 243–4
- itraconazole 401
- ivermectin 165, 402
- Ixodes* spp. 171
- Jackson–Lawler syndrome 364
- Jacquet ulcers 64
- Jadassohn–Lewandowsky syndrome 364
- Job syndrome 57–58
- juvenile plantar dermatitis 51–52
- juvenile rheumatoid arthritis 186
- juvenile spring eruption 203
- juvenile xanthogranuloma 317–19
- Kasabach–Merritt syndrome 277
- Kawasaki disease 187–9
- keloids 311–12
- keratodermas, palmoplantar 376–82
- keratolysis, pitted 108–9

- keratolysis exfoliativa 47–8  
 keratolytics 55, 397  
     with moisturizers 396–7  
 keratosis follicularis 388  
 keratosis pilaris 55–56  
 kerion 154  
 ketoconazole 402  
 KID syndrome 338  
 kinky hair syndrome 355–6  
 Klein–Waardenburg syndrome 252  
 Klippel–Trenaunay syndrome 283–4  
 knuckle pads 310  
 Koebner epidermolysis bullosa 89  
 Koebner phenomenon 33, 44  
 koilonychia 361  
 Koplik spots 119  
 kwashiorkor 195
- Lactrodictus mactans* 169–70  
 Langerhans cell histiocytosis 330–1  
 laser therapy 279  
 lentiginous nevus 236  
 lentigo simplex 240  
 Leopard syndrome 208  
 lepidopterism 169  
 leprosy 113–15  
 Letterer–Siwe disease 330  
 leukemia cutis 328–9  
 leukoderma acquisitum centrifugum 235  
 leukonychia 361  
 lichen aureus 273–4  
 lichen nitidus 44–5  
 lichen planus 43–4  
 lichen purpuricus 273–4  
 lichen sclerosus 265–6  
 lichen scrofulosorum 113  
 lichen simplex chronicus 51  
 lichen striatus 67–68  
 lichenification, defined 3  
 lichenoid dermatitis 51–52  
     drug-induced 222  
 lidocaine 406  
 Lindsay nails 360  
 linear IgA dermatosis 87–89  
 lipoma 305–6  
 lithium, drug reactions 225  
 livedo reticularis 292–3  
 local anesthetics 406  
 loose anagen syndrome 350–1  
 loratadine 399  
 lotions 392  
 Louis–Bar syndrome 387  
 louse infestations 165–7
- Loxosceles reclusa* 169–70  
 lues 115–17  
 lupus erythematosus  
     discoid 260–1  
     neonatal 14–16  
     systemic lupus erythematosus 258–60  
 lupus vulgaris 112  
 lupus-like drug-induced reactions 223  
 Lyme disease 145–7, 171  
 lymphangioma circumscriptum 289  
 lymphatic malformations 288–91  
 lymphedema 290–91  
 lymphoma 329–30
- McCune–Albright syndrome 241–2  
 macrocystic (lymphatic)  
     malformations 289–90  
 macronychia 361  
 macular atrophy 306  
 macule, defined 3  
 Mafucci syndrome 281  
 Majocchi granuloma 152  
 malar rash 257  
 malignancies/tumors 327–33  
     basal cell carcinoma 327–8  
     defined 3  
     glomus tumor 285–6  
     histiocytosis 330–1  
     leukemia cutis 328–9  
     lymphoma 329–30  
     mast cell disease 320  
     melanoma 236–8  
     neuroblastoma 332–3  
     neurofibroma 315  
     neurofibromatosis 377–9  
     rhabdomyosarcoma 331–2  
 marasmus 195  
 marine dermatitis 175–6  
 mast cells 321  
     degranulators 320  
     malignant disease 320  
 mastocytoma, solitary 319–22  
 mastocytosis 319–22  
     syndrome 320  
     systemic 320  
 measles (rubeola) 119–20  
 Mee's lines, nail disorders 362  
 melanocytic nevi 231–3, 243–4  
     congenital/acquired 231–3  
 melanoma 236–8  
     benign juvenile 233  
 melanosis, transient neonatal pustular 12–13
- melanosis of Ito/Ota 243–4  
 melasma 242–3  
 meningococcemia 107–8  
 Menkes kinky hair syndrome 355–6  
 methotrexate 408  
 Mibelli  
     angiokeratoma 288  
     porokeratosis 46–7  
 micronychia 362  
*Microsporum* spp. 155–6  
     Wood's lamp examination 7  
 midazolam 405  
 milia 11, 302–3  
 miliaria 78–79  
 minoxidil 408  
 moisturizers, with/without keratolytics 396–7  
 molluscum contagiosum 139–41  
 Mongolian spot 243  
 monilethrix 349  
 morbilliform eruptions  
     drug-induced 217–18  
     viral 121  
 morphea 263–5  
 morphine 405  
 Mucha–Habermann disease 39  
 mucocutaneous candidiasis 149–50  
 mucormycosis 161–2  
 Muehrcke's nails 362  
 multiple hamartoma syndrome 386  
 Munchausen syndrome by proxy 214  
 mycobacterial disease  
     atypical 110–12  
     classification 110  
     leprosy 113–15  
     tuberculosis 112–13  
 mycophenolate mofetil 408  
*Mycoplasma pneumoniae* 180  
 mycosis fungoides 41–3
- nail disorders 359–68  
     alopecia areata 359  
     anonychia 359  
     Beau's lines 359  
     blue nails 359–60  
     brachyonychia 360  
     clubbing 360  
     dystrophy 360  
     ectodermal dysplasia (hidrotic) 339  
     half-and-half (Lindsay) nails 360  
     hangnail 359  
     Hutchinson sign 360  
     ingrown toenails 360

- koilonychia 361
- leukonychia 361
- macronychia 361
- malalignment of great toenails 361–2
- median nail dystrophy 362
- Mee's lines 362
- micronychia 362
- Muehrcke's nails 362
- nail–patella syndrome 362
- nevi 362–3
- onychogryphosis 363
- onychoheteropia 363
- onycholysis 363
- onychomadesis 363
- onychomycosis 363–4
- onychophagia 363
- onychorrhexis 364
- onychoschizia 364
- pachyonychia congenita 364–5
- paronychia 365
- pincer nail 365
- polyonychia 365
- Pseudomonas* nail 365–6
- psoriasis 35, 365
- pterygium 366
- racquet nail 366
- red lunulae 366
- splinter hemorrhages 366
- Terry's nails 366
- trachyonychia 366
- traumatic nail injury 366–7
- twenty-nail dystrophy 366–7
- whitlow 367
- yellow nails 367
- nail–patella syndrome 362
- naproxen 405
- nasal glioma 27–8
- neurobiosis lipoidica diabetorum 186–7
- Neisseria meningitidis* 107, 270
- neonatal defects 27–31
  - accessory tragus 30–1
  - aplasia cutis congenita 17–19
  - branchial cleft cyst/sinus 29
  - cephalic pustulosis 13–14
  - congenital dermal sinus 28–9
  - dermal erythropoiesis 21
  - encephalocele 28
  - lupus erythematosus 14–16
  - nasal glioma 27–8
  - neonatal scars 20–1
  - nevus sebaceus (of Jadassohn) 19–20
  - preauricular cyst/sinus 29–30
  - sclerema neonatorum 17
  - see also* ichthyosis
- neonatal infections 21–7
  - candidiasis 24–6
  - congenital syphilis 26–7
  - congenital varicella 23–4
  - herpes neonatorum 21–3
  - infantile herpes 23–4
- neonates 9–31
- neuroblastoma 332–3
- neurofibroma 315
- neurofibromatosis 377–9
- neutropenic dermatosis, acute febrile 191–3
- nevroid basal cell carcinoma syndrome 381
- nevus/i 316–17
  - acquired melanocytic nevi 232–3
  - araneus 293
  - basal cell nevus syndrome 381–2
  - Becker nevus 238–9
  - blue nevus 234–5
  - comedonicus 300–1
  - congenital melanocytic nevi 231
  - connective tissue 316
  - epidermal nevus 297–9
  - epithelioid nevus 297–9
  - flammeus 280–2
  - halo nevus 235–6
  - inflammatory linear verrucous epidermal (ILVEN) 298
  - lentiginous 236
  - lipomatous 306
  - nail matrix 362–3
  - nevocellular congenital 231
  - nevus achromicus 255–6
  - nevus anemicus 286–7
  - nevus depigmentosus 255–6
  - nevus fuscoceruleus ophthalmomaxillaris 243–4
  - nevus of Ito 243–4
  - nevus of Ota 243–4
  - nevus sebaceus (of Jadassohn) 19–20, 299–300
  - nevus simplex (salmon patch) 287
  - nevus spilus 236
  - organoid 299
  - speckled lentiginous 236
  - Spitz/spindle nevus 233–4
  - Sutton (halo) nevus 235–6
- niacin deficiency 195–7, 209–10
- nickel
  - contact dermatitis 59
  - detection kit 62
- Nikolsky sign 181
- nits (pediculosis), potassium hydroxide examination 6
- nodules
  - benign 302
  - defined 3
- non-opioid analgesics 405–6
- nonsteroidal anti-inflammatories, drug reactions 225
- nutritional disorders 194–8
  - acrodermatitis enteropathica 197–8
  - anorexia and bulimia nervosa-associated skin disorders 194–5
  - kwashiorkor 195
  - marasmus 195
  - vitamin deficiencies 195–7, 209–10
- nystatin 402
- oculocutaneous albinism 251–2
- oculodermal melanocytosis 243–4
- oils and oil-free products 393
- ointments 392
- onychogryphosis 363
- onychoheteropia 363
- onycholysis 363
- onychomadesis 363
- onychomycosis 156–7, 363–4
- onychophagia 363
- onychorrhexis 364
- onychoschizia 364
- opioid analgesics 405
- oral contraceptive pills 408
- orf 141
- Osler–Weber–Rendu syndrome 295
- osteoma cutis 323–5
- Ota, nevus 243–4
- oxycodone 405
- PABA/PABA esters 398
- pachyonychia congenita 364–5
- Pasini epidermolysis bullosa 92
- palmo-plantar keratoderma 376–82
  - basal cell nevus syndrome 381–2
  - neurofibromatosis 377–9
  - tuberous sclerosis complex 379–81
- palms, hyperlinearity 370
- panniculitis 308–9
- papillomatosis
  - confluent and reticulated 248
  - defined 3

- papillomaviruses 137–9  
 papular acrodermatitis 124  
 papular polymorphous light eruption 202–4  
 papular urticaria 167–8  
 papular/papulosquamous disorders 33–48  
 papules  
   benign 302  
   defined 3  
   Gottron 257  
   piezogenic pedal 307  
 papulovesical acrodermatitis syndrome 124  
 paraneoplastic pemphigus 83, 84  
 parasites, antiparasitic agents 402  
 paronychia 365  
   candidal 149  
 Parry–Romberg syndrome 264  
 pastes 393  
*Pasteurella multocida* 173  
 Pastia's lines 104  
 patch  
   defined 3  
   shagreen 381  
 patch tests (TRUE) 60–62  
 pedal papules 307  
 pediculosis 165–7  
   potassium hydroxide examination 6  
 pellagra, vitamin B3 deficiency 209–10  
 pemphigoid gestationis 84, 85  
 pemphigus 81–84  
 pemphigus erythematosus 84  
 pemphigus foliaceus 82, 84  
 penicillin  
   drug reactions 224  
   see also antibiotics  
 perforating elastosis 45–6  
 perianal streptococcal dermatitis 102–3  
 perioral dermatitis 75–76  
 periplakin 84  
 permethrin cream 164  
 pernio 210  
 petechiae, defined 3  
 PHACES syndrome 277–8  
 phenylketonuria 253–4  
 photodermatoses 199–205  
   causative drugs 222  
   drug-induced eruptions 221–2  
   photoallergic dermatitis 201–2  
   phototoxicity 199–201  
   phytophotodermatitis 202  
   polymorphous light eruption 202–4  
   solar urticaria 204–5  
   sunburn 199–201  
 photosensitizers 201  
*Phthirus pubis* 165–6  
 physical abuse 211–16  
 PIBIDS 351  
 piebaldism 252–3, 253  
 piezogenic pedal papules 307  
 pigmentary disorders 229–56  
   Blaschko lines 46–7, 229, 297–301  
   confluent and reticulated papillomatosis 248  
   drug-induced 223  
   hyperpigmented disorders 229–48  
     postinflammatory 229–30  
   hypopigmented disorders 249–56  
   whorling 245  
 pigmented purpura 272–4  
   lichen aureus 273–4  
   Schamberg disease 273  
 pili torti 348–9  
 pili triangulari et canaliculi 349  
 pilomatrixoma 303–4  
 pimecrolimus 408  
 pitted keratolysis 108–9  
 pityriasis alba 53  
 pityriasis lichenoides chronica (PLC) 39–40  
 pityriasis lichenoides et varioliformis acuta (PLEVA) 39–40  
 pityriasis rosea 38  
 pityriasis rubra pilaris 36–7  
 pityriasis versicolor 157–9  
*Pityrosporum* folliculitis 97  
 plantar warts 137  
 plaque, defined 3  
 plasters 392  
 podophyllin 404  
 poison ivy *Toxicodendron* 58–59  
 polyarteritis nodosa 267  
 polyonychia 365  
 porokeratosis 46–7  
 porphyrias 205–7  
 port wine stains 280–2  
 postinflammatory hypopigmentation 256  
 potassium hydroxide examination 4–5  
 potassium iodide 408  
   drug reactions 225  
 powders 393  
 preauricular cyst/sinus 29–30  
 primary lesions, definitions 3  
*Propionibacterium acnes* 73  
 protein C or S deficiency 270  
 protein deficiency 195  
 prurigo, actinic 203  
 pseudomonal infections  
   folliculitis 97–98  
   nails 365–6  
 pseudopseudohypoparathyroidism 324  
 pseudoxanthoma elasticum 384–5  
 psoriasis 33–6  
   nail disorders 35, 365  
   variant forms 34–5  
 psoriatic arthritis 35  
 pterygium 366  
 purpura  
   anaphylactoid 268–70  
   defined 3  
   eczematoid 272  
   fulminans 270  
   Henoch–Schonlein purpura 268–70  
   lichen aureus 273–4  
   pigmented purpura 272–4  
   Schamberg disease 273  
 purpura fulminans 270–2  
 pustular melanosis, transient neonatal 12–13  
 pustular psoriasis 34  
 pustule, defined 3  
 pustulosis, neonatal cephalic 13–14  
 pyoderma gangrenosum 189–91  
 pyogenic granuloma 291–2  
  
 Ramsay Hunt syndrome 135  
 Raynaud phenomenon 262–3  
 reaction patterns 6  
 reaction types, drug-induced 217–27  
 regional patterns, and diagnosis 5  
 renal disease, half-and-half (Lindsay)  
   nails 360  
 reticulated, defined 4  
 rhabdomyosarcoma 331–2  
 rheumatoid nodules 186  
 rickettsial diseases 144–7  
   Lyme disease 145–7  
   Rocky Mountain spotted fever 144–5, 171  
 ringworm 151  
 Ritter disease 105  
 rosacea 76–77, 404  
 roseola (exanthem subitum) 122–3  
 Rothmund–Thomson syndrome 209



- rubber/adhesives, contact dermatitis 59  
 rubella 120–2  
 rubeola 119–20  
 Rubinstein–Taybi syndrome 360  
  
 salicylates, UVB screen 398  
 salicylic acid 397  
 salmon patch 287  
 sarcoidosis 193–4  
*Sarcoptes scabiei* 163–5  
 scabies 163–5  
     potassium hydroxide examination 6  
 scale, defined 3  
 scalp preparations 397  
 scalp ringworm 154  
 scarlet fever 104–5  
 scars  
     hypertrophic scars 313  
     neonatal scars 20–1  
 Schamberg disease 273  
*Schistosoma cercariae* 174  
 sclerema neonatorum 17  
 scleroderma 262–3  
     localized 263–4  
 scrofuloderma 112  
 seabather's eruption 175–6  
 sebaceous gland hyperplasia 10–11  
 seborrheic dermatitis 66–67  
 secondary lesions, definitions 3, 142  
 segmental, defined 4  
 serpiginous, defined 4  
 serum sickness, drug-induced 220–1  
 severe combined immunodeficiency syndrome 57–58  
 sexual abuse 139, 212–16  
 shagreen patch 381  
 shake lotions 393  
 shampoos 66, 397–8  
 shawl sign 257  
 shoe contact dermatitis 59  
 signs  
     Auspitz 33  
     Crowe 378  
     Darier 320  
     Gower 257  
     Hutchinson 360  
     Nikolsky 181  
     shawl 257  
 sixth disease 122–3  
 skin area, rule of nines 391  
 skin biopsy 7  
 skin lesions, configuration 4  
  
 skin patch tests (TRUE) 60–62  
 skin phototypes 199  
 smooth muscle hamartoma 317  
 snake bites 173–4  
 soapless cleansers 54, 397  
 soaps 397  
 solar urticaria 204–5  
     see also photodermatoses  
 solitary mastocytoma 319  
 solutions (treatment) 392  
 speckled lentiginous nevus 236  
 spider angioma 293–4  
 spider bites 169–70  
 Spiegler–Brooke syndrome 326  
 spirochetal disease 115–17  
 Spitz nevus 233–4  
*Sporothrix schenckii* 159–60  
 sporotrichosis 159–60  
 sprays 392  
 staphylococcal disease 95–108  
     and HIV infection 142  
     scalded skin syndrome 105–7  
     secondary infection 50–51, 142  
*Staphylococcus aureus* 50–51  
 steatocystoma multiplex 325  
 steroids see corticosteroids  
 Stevens–Johnson syndrome (SJS) 180–2  
 stings, insect 168–9  
 strawberry hemangioma 275–80  
 streptococcal disease 95–108  
     erythema nodosum 182–3  
     perianal dermatitis 102–3  
     purpura 270  
 striae, corticosteroid drug reactions 224  
 striae distensae 313–14  
 Sturge–Weber syndrome 282–3  
 subcutaneous fat necrosis 16–17  
 sulfonamides, drug reactions 225  
 sun sensitivity  
     genodermatoses 205–10  
     photodermatoses 199–205  
 sunburn 199–201  
 sunscreens 398  
 'sweaty sock syndrome' 51  
 Sweet syndrome 191–3  
 swimmer's eruption 175–6  
 swimmer's itch 174–5  
 swimming-pool diseases 110–12  
 syphilis 115–17  
     neonatal 26–7  
 syringomas 325–6  
 systemic corticosteroids 54, 62, 395–6  
 systemic lupus erythematosus 258–60  
 systemic mastocytosis 320  
 systemic sclerosis 262–3  
  
 T-cell lymphoma 41–3  
 tacrolimus 408  
 Takayasu arteritis 267  
 tape/plasters 392  
 tar 396  
 target lesions defined 4  
 telangiectasias 294  
     eruptiva macularis perstans 320  
     generalized essential 294–5  
     hereditary hemorrhagic 295  
     spider angioma 293  
 telogen effluvium 342–3  
 terbinafine 402  
 terminology of lesions 3  
 Terry's nails 366  
 tetracyclines, drug reactions 224  
 thalidomide 408  
 therapies 391–409  
 thiazides, drug reactions 225  
 thrush 149  
 tick bites 170–2  
 tick-borne (rickettsial) diseases 144–7  
 tinea capitis 154–6  
 tinea corporis 151–3  
 tinea pedis 153–4  
 tinea unguium 156–7  
 tinea versicolor 157–9  
 tissue transglutaminase 84  
 titanium oxide 398  
 topical therapy 391  
     anesthetics 406  
     corticosteroids 62, 393–5  
     keratolytics 397  
 toxic epidermal necrolysis 180–2  
     drug-induced 219  
 toxic erythema of newborn 11–12  
*Toxicodendron* (poison ivy) 58–59  
 trachyonychia 366  
 tragus, accessory 30–31  
 transient neonatal pustular melanosis 12–13  
 treatments 391–409  
*Treponema pallidum* 116  
 trichoepithelioma 326–7  
*Trichophyton mentagrophytes* 153  
*Trichophyton rubrum* 153–7  
 trichorhinophalangeal syndrome 338  
 trichorrhexis invaginata 347–8  
 trichorrhexis nodosa 347

- trichothiodystrophy 351  
trichotillomania 344–5  
TRUE skin patch tests 60–62  
tuberculids 113  
tuberculosis 112–13  
tuberous sclerosis complex 379–81  
tumors *see* malignancies/tumors  
twenty-nail dystrophy 366–7  
Tzanck smear 6
- ulcer, defined 3  
umbilical granuloma 14  
umbilicated, defined 4  
uncombable hair syndrome 349–50  
urticaria 177–9  
    drug-induced 218–19  
    insect bite reactions 167–8  
    pigmentosa 319  
    solar 204–5
- valacyclovir 408–9  
varicella 132–5  
    neonatal 23–4  
vascular disorders 275–88  
    angiokeratoma 287–8  
    blue rubber bleb syndrome 281  
    capillary malformations 280–2  
    cutis marmorata telangiectatica  
        congenita 284–5  
    drug-induced vasculitis 223  
    glomovenous malformations  
        285–6  
    hemangioma of infancy 275–80  
    Klippel–Trenaunay syndrome  
        283–4  
    leukocytoclastic vasculitis 268  
    nevus anemicus 286–7  
    nevus simplex (salmon patch) 287  
    Sturge–Weber syndrome 282–3  
    vascular malformations 280–2  
    vasculitis 223, 266–8
- vehicles 391–3  
vellus hair cysts 304–5  
venereal warts 137–9  
venous malformations 281  
vernix caseosa 9  
verrucae 137–9  
vesicle, defined 3  
viral culture 7  
viral diseases 119–44  
    echovirus 126–7  
    erythema infectiosum (fifth disease)  
        123–4  
    Gianotti–Crosti syndrome 124–5  
    hand foot and mouth disease  
        136–7  
    hepatitis 128–9  
    herpes simplex 130–2  
    herpes zoster 135–6  
    human immunodeficiency virus  
        (HIV) 142–4  
    infectious mononucleosis 127–8  
    measles (rubeola) 119–20  
    molluscum contagiosum 139–41  
    orf 141  
    roseola (exanthem subitum, sixth  
        disease) 122–3  
    rubella 120–2  
    unilateral laterothoracic exanthem  
        125–6
- varicella 132–5  
verrucae 137–9  
vitamin deficiencies 195–7, 209–10  
vitiligo 249–51  
Vogt–Koyanagi–Harada syndrome  
    249
- Waardenburg syndrome 252  
Weber–Cockayne epidermolysis  
    bullosa 89, 90  
Wegener granulomatosis 267  
wet dressings 393  
wheal, defined 3  
whitlow 131, 367  
Wickham striae 43  
winter eczema 56  
Wiskott–Aldrich syndrome 57  
Wood’s lamp examination 7
- X-linked ichthyosis 371  
xanthogranuloma, juvenile 317–19  
xanthoma  
    eruptive 319  
    pseudoxanthoma elasticum 384  
xeroderma pigmentosum 207–8  
xerosis 56–57
- zinc 409  
zinc deficiency 197–8, 337  
zosteriform, defined 4

# Illustrated Manual of Pediatric Dermatology

## Diagnosis and Management

Susan Bayliss Mallory  
Alanna Bree  
Peggy Chern

The Illustrated Manual of Pediatric Dermatology presents straightforward approaches to problems that pediatricians and dermatologists encounter in their clinical practice on a regular basis. With more than 400 color photographs, it provides a diagnostic and treatment guide to a broad range of both common and more unique pediatric and adolescent skin diseases and disorders. The combination of photographs and practical, concise text gives dermatologists, pediatricians and family doctors a visual reference and puts the information they need right at their fingertips.

- Provides a rapid-reference guide to the diagnosis of a broad range of pediatric skin diseases
- Extensively illustrated with more than 400 color photographs to facilitate accurate diagnosis
- Includes extensive information on appropriate treatment options

Susan Bayliss Mallory MD

Professor of Internal Medicine/Division of Dermatology  
and Department of Pediatrics  
Washington University School of Medicine  
Director, Pediatric Dermatology  
St. Louis Children's Hospital  
St. Louis, Missouri, USA

Alanna Bree MD

St. Louis University  
Director, Pediatric Dermatology  
Cardinal Glennon Children's Hospital  
St. Louis, Missouri, USA

Peggy Chern MD

Department of Internal Medicine/Division of  
Dermatology and Department of Pediatrics  
Washington University School of Medicine  
St. Louis, Missouri, USA



Taylor & Francis  
Taylor & Francis Group

[www.tandf.co.uk](http://www.tandf.co.uk)

PA 7537

ISBN 1-85070-753-7



9 781850 707530